

Allergic Respiratory Inflammation and Remodeling

Alerjik Solunum Yolu İnflamasyonu ve Yeniden Yapılanma

Kawa A. M. Amin^{1,2}

¹Department of Medical Science, Respiratory Medicine and Allergology, Clinical Chemistry and Asthma Research Centre, Uppsala University and University Hospital, Uppsala, Sweden

²Department of Microbiology/Immunology, School of Medicine, Faculty of Medical Sciences, University of Sulaimani, Sulaimani, Iraq

Abstract

Özet

Asthma and rhinitis are inflammatory diseases of the respiratory tract. Respiratory inflammation of the adaptive and innate immune system is the focus of this review, and chronic inflammation is not limited to the respiratory tissue. The inflammatory response, which consists of phagocytes, eosinophils, mast cells, and lymphocytes, spreads along the respiratory tract, leading to tissue damage. Mast cells and eosinophils are commonly recognized for their detrimental role in allergic reactions on activation through the high- and low-affinity receptors for IgE FcεRI. These cells rapidly produce and secrete many of the mediators responsible for the typical symptoms of asthma and rhinitis. However, increasing amount of evidence demonstrate that mast cells and leukocytes have vital roles in host defense against pathogenesis. Histological methods are used to study leukocytes and receptor expression pattern in different respiratory tract compartments. The overall aim of this review was to understand the relationship between upper and lower respiratory tract inflammation and remodeling in patients with allergic and non-allergic asthma and rhinitis. In conclusion, this review discusses the relationship between the upper and lower airway in respiratory disease and focuses on the effect of respiratory processes on laryngeal inflammation, remodeling, function, and symptoms; however, they also have a central role in the initiation of the allergic immune response. Our findings suggest that there are differences that contribute to the development of immunopathological mechanisms of these clinically distinct forms of asthma, rhinitis, and chronic obstructive pulmonary disease.

KEYWORDS: Respiratory tract, inflammatory cells, remodeling, allergy, asthma, rhinitis

Received/Geliş Tarihi: 22.05.2015 **Accepted/Kabul Tarihi:** 01.06.2015

Astım ve rinit solunum yollarının inflamatuvar hastalıklarıdır. Adaptif ve doğal immün sistem ile solunum yolu inflamasyonu bu derlemenin odağıdır, kronik inflamasyon solunum sistemi dokusuna sınırlı değildir. İnflamasyon solunum yolu boyunca yayılır ve doku hasarına yol açabilen fagositler, eozinofiller, mast hücreleri ve lenfositlerden oluşur. Mast hücreleri ve eozinofiller genelde alerjik reaksiyonlarda IgE FcεRI reseptörlerine yüksek ve düşük afiniteleri ile aktivasyon üzerinden zararlı rolleri ile tanınırlar, astım ve rinitteki tipik semptomlardan sorumlu mediatörlerin çoğunu hızlıca üretir ve salgırlar. Bununla birlikte, artan miktarda veri; mast hücreleri ve lökositlerin patogeneze karşı konak savunmasında önemli hatta hayatı rolü olduğunu göstermektedir ve ayrıca farklı solunum yolu kompartmanlarında reseptör ekspresyon paternini ve lökositleri incelemek için histolojik metotlar kullanılmaktadır. Bu derlemenin genel amacı, alerjik ve non-alerjik astım ve rinit hastalarındaki üst ve alt solunum yolu inflamasyonu ve yeniden yapılanma arasındaki ilişkiyi anlamaktır. Sonuç olarak, bu derleme solunum yolu hastalıklarında üst ve alt havayolu arasındaki ilişkiyi tartışmaktadır ve solunum süreçlerinin laringeal inflamasyon, yeniden yapılanma, fonksiyon ve semptomlar üzerine etkisine odaklanmaktadır, bunlar ayrıca alerjik immün cevabın başlamasında merkezi bir role sahiptirler. Bulgularımız, astım, rinit ve KOAH'ın farklı klinik formlarının immünopatolojik mekanizmalarının gelişiminde ortak noktalar ve farklılıklar olduğunu göstermektedir

ANAHTAR SÖZCÜKLER: Solunum yolu, inflamatuvar hücreler, yeniden yapılanma, alerji, astım, rinit

INTRODUCTION

The principal role of the respiratory system is to permit the efficient exchange of respiratory gases (O₂ and CO₂) with the environment. The respiratory system is unique in that it is constantly exposed to a barrage of foreign substances from both the internal (at any point in time, approximately one-half of the cardiac output is received by the lungs) and external environments (with each breath, the respiratory tract is exposed to pollen, viruses, bacteria, smoke, etc.). In 2003, according to the Centers for Disease Control and Prevention, diseases of the respiratory system were the seventh and eighth leading causes of death in children aged 1–19 years [1]. Respiratory disease is the term for diseases of the respiratory system. These include diseases of the lung, pleural cavity, bronchial tubes, trachea, upper respiratory tract as well as the diseases of the nerves/muscles associated with breathing. Chronic respiratory diseases, such as asthma, chronic obstructive pulmonary disease (COPD), sarcoidosis and rhinitis, and cancer, are major components of the disease burden worldwide.

Address for Correspondence / Yazışma Adresi: Kawa A. M. Amin, Department of Microbiology/ Immunology, School of Medicine, Faculty of Medical Sciences, University of Sulaimani, Sulaimani, Iraq
Phone/Tel: +9647701958515 E-mail/E-posta: kawa.amin@medsci.uu.se

©Copyright 2015 by Turkish Thoracic Society - Available online at www.toraks.dergisi.org

©Telif Hakkı 2015 Türk Toraks Derneği - Makale metnine www.toraks.dergisi.org web sayfasından ulaşılabilir.



Every day, hundreds of millions of people suffer from chronic respiratory diseases. According to the latest WHO estimates (2009), currently, 300 million people have asthma and 210 million people have COPD, while millions have allergic rhinitis (AR) and other often under diagnosed chronic respiratory diseases. There is concern that deaths from asthma and rhinitis are also increasing, but the reasons for this are unclear. There is even suspicion that some asthma and rhinitis therapies may be contributing to the increase in deaths. Some readers may be excused for thinking that asthma and rhinitis are clearly defined disorders regarding which we can obtain information with confidence; however, this is far from the reality. Many of the same allergens are known to trigger allergic asthma and rhinitis. If AR is effectively treated, it could reduce asthma symptoms and may even help prevent asthma development.

Airway inflammation is initiated by stimuli at the epithelial surface, and cells already present in the tissue mediate acute inflammation. The stimuli cause activation of the resident leukocytes and structural cells to produce various cytokines, chemokines, and growth factors that cause inflammatory symptoms [2-6]. Chronic local inflammation with airway remodeling is observed in allergic asthma, rhinitis, and COPD; however, the location of the inflammation, the inflammatory cells involved, mediator profiles, and therapeutic response are very different [2,3,5,7,8]. This group of patients with asthma is characterized by neutrophilic inflammation, and they often experience more severe asthma that is not as steroid sensitive as allergic asthma [9]. In bronchial biopsies of patients with non-allergic asthma and rhinitis, eosinophils are scarce compared with patients with allergic asthma and rhinitis, whereas neutrophils are prominent [3,4]. Interleukin (IL)-8 appears to be the mediator of neutrophil influx because IL-8 levels are increased in sputum and connective tissue of non-allergic asthma and rhinitis and correlate to the number of neutrophils in the sputum [3,4,10].

The subsequent review focuses on common allergic conditions, including AR and asthma. This review discusses the relationship of the upper and lower airways in respiratory disease and focuses on the effect of these in terms of respiratory inflammation, remodeling, function, and symptoms.

Anatomy of the Respiratory Tract

The airway can be divided into the upper respiratory tract, which includes the nose, pharynx, and larynx, and the lower respiratory tract, which consists of the trachea, bronchi, bronchioles, and alveoli. The trachea extends from the neck to the thorax, where it divides into the right and left main bronchi, which enter the right and left lungs, respectively, breaking up as they do into smaller bronchi and bronchioles and ending in small air sacs or alveoli, where gaseous exchange occurs.

Atopy and Asthma

Asthma is a very old disease. Although descriptions resembling asthma may be traced as far back as the 28th Century B.C., it was Aretaeus, a Greek physician, who provided the first observation of asthma as we know it today in the 2nd Century B.C.

The term “atopy,” derived from the Greek word *atopia* (strangeness), was first used by Coca to describe a tendency to develop immediate-type hypersensitivity reactions to common allergens [11]. Genetically, allergies are associated with immunoglobulin E (IgE) antibody production and atopy, i.e., a hereditary predisposition to develop IgE specific for inhaled allergens [12], as shown by either elevated total serum IgE or allergen-specific IgE levels that are revealed by a positive radioimmunoassay test. There has been a lack of agreement on the definition of the term atopy. In the present study, we have used the definition of atopy proposed by an international consensus report. In this report, atopy was defined as a skin reaction to one or more allergens with a mean diameter of ≥ 3 mm and no dermatographism [13]. Affected people are sensitive to environmental allergens (e.g., pollen and house dust mites) to which most individuals are tolerant. Tolerance means that the immune system recognizes the presence of the allergen but does not react.

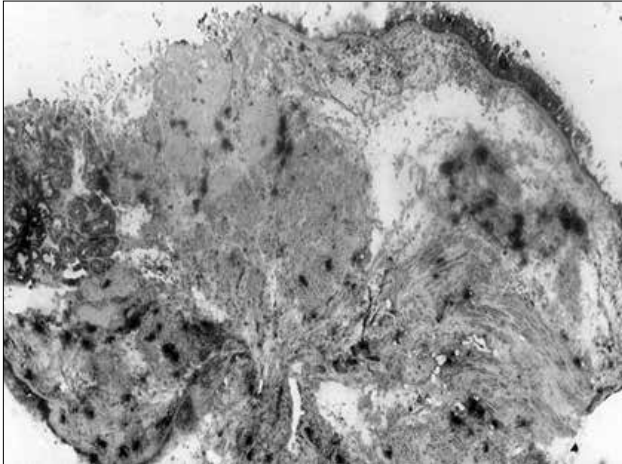
Asthma is a major chronic airway disorder that tends to increase in both prevalence and severity, affecting over 100 million people worldwide [14]. The disease affects people of all ages. Asthma was described many centuries ago as an attack due to sleeping in feather beds [15].

The current definition of asthma is as follows: “*Asthma is a chronic inflammatory disorder of the airways in which many cells play a role in particular mast cells, eosinophils, and T-lymphocytes. In susceptible individuals, this inflammation causes recurrent episodes of wheezing, breathlessness, chest tightness, and cough, particularly at night and/or in the early morning. These symptoms are usually associated with widespread but variable airflow limitation that is at least partly reversible, either spontaneously or with treatment. The inflammation also causes an associated increase in airway responsiveness to a variety of stimuli*” [16].

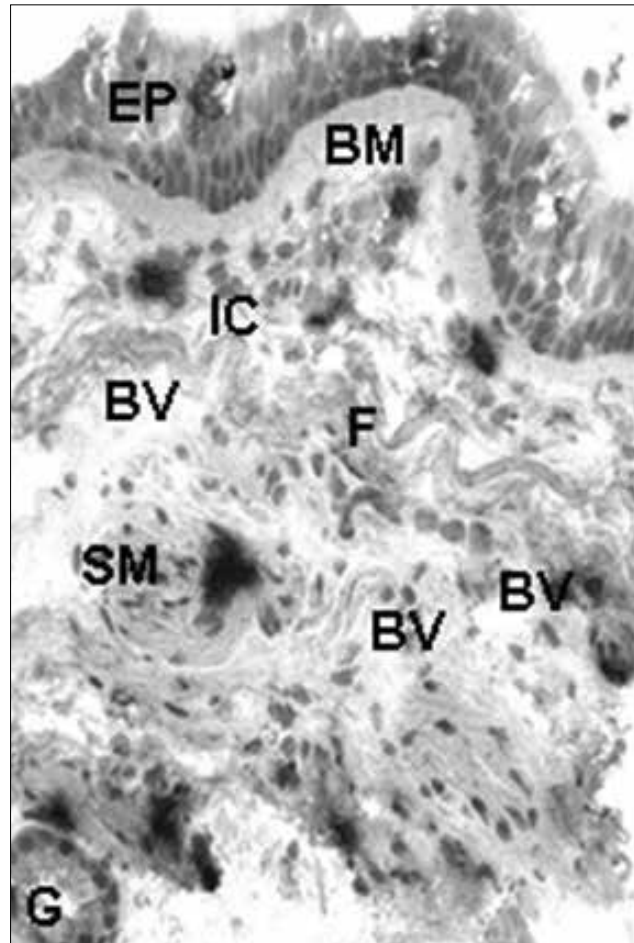
Asthma is clinically characterized by a highly variable and reversible obstruction of conducting airways and associated symptoms. The reversible components of airway obstructions that contribute to asthma are contractions of the smooth muscle in the airway (bronchospasm), swelling of the airway wall (edema), and the presence of increased secretions (mucus, serum proteins, and cell debris) [17]. Chronic inflammation of the airways is another characteristic of asthma. In common with certain other conditions in the respiratory tract, asthma is characterized by an enhanced ability of the airways to suddenly elicit changes in the muscle tone and bronchial secretion. This increased sensitivity that is referred to as bronchial hyperresponsiveness (BHR) is nearly ubiquitous among patients with asthma. Patients with BHR respond with an exaggerated form of bronchial obstruction when they are exposed to very low concentrations or levels of noxious chemical or physical stimuli. Patients with asthma have eosinophilia in their blood or sputum when the disease is active. It is well known that the bronchial epithelium of patients with asthma is damaged [18,19]. Eosinophils may be responsible for this tissue damage. However, the relationship between inflammation, bronchial hyperresponsiveness, and epithelial damage is not entirely clear. Our study has demonstrated that inflammatory cells may be responsible for this tissue damage (Figure 1).

Table 1. Comparison of individuals with atopic and non-atopic asthma [21]

	Atopic asthma	Non-atopic asthma
Asthma onset	Childhood	Adult
Allergy	Several	None
Family history	Positive	Negative
Skin tests	Positive	Negative
Serum IgE	Specific IgE	No specific IgE

**Figure 1.** Airway wall remodeling in allergic asthma

Atopy is the strongest identified risk factor for the development of asthma [20]. Asthma is frequently associated with other atopic diseases, such as eczema and AR. Despite the often found connection between atopy and asthma, not all patients with asthma are atopic. A comparison of some characteristics of atopic and non-atopic asthma is given in Table 1 [21]. A few studies have compared the inflammatory response in atopic and non-atopic asthma and found both differences and resemblances. Increased levels of IL-4 and -5 were found in bronchoalveolar lavage (BAL) in both atopic and non-atopic asthma [3,22]. Differences in the secretion profile of T lymphocytes in atopic and non-atopic asthma were observed. Increased levels of IL-2 and -5 were found in non-atopic asthma, whereas in patients with atopic asthma, increased levels of IL-4 and -5 were found in BAL and in peripheral blood; in addition, sub-epithelial membranous thickening, disruption of airway epithelium, and airway inflammation associated with mucous plugging were found in atopic asthma [23]. In atopic asthma, inflammatory changes in the airway may contribute to the characteristic pathophysiological symptoms. The inflammatory cellular infiltrate and structural changes in the mucous membrane of the airway are important factors in the development of rhinitis and asthma (Figure 1) [3,4,24]. Histological examination of the airways demonstrates diffuse infiltration of the tissue with neutrophils, eosinophils, mononuclear phagocytes, lymphocytes, mast cells, and basophilic cells. Various mediators, such as tryptase, cytokines, prostaglandins, leukotrienes, and histamine, may strongly influence immunological mechanisms either locally in the target organs or systemically in the circulation. The

**Figure 2.** Inflammatory cells and structure change of the allergic asthma. Dark colors are mast cells, EP: epithelium; BM: basement membrane; IC: inflammatory cells; BV: blood vessel; F: fibers; SM: smooth muscle; G: gland

inflammatory process in the bronchial epithelium also includes a change from a ciliated epithelium to a non-ciliated epithelium which is also a common reaction of the epithelium to carcinogens (Figure 1, 2) [3,4].

Rhinitis

Rhinitis is defined as an inflammation of the lining of the nose that is characterized by one or more of the following symptoms: itching, sneezing, rhinorrhea, and nasal congestion. Rhinitis can be broadly classified into allergic, IgE-mediated, and non-allergic forms. AR may be further subdivided into seasonal or perennial disease. The symptoms of seasonal allergic rhinitis (SAR) are mostly triggered by an allergy to pollen. Perennial allergic rhinitis (PAR) is due to sensitivity to and contact with allergens that are present in the environment throughout the year. Symptoms of non-allergic rhinitis (NAR) may perennially occur or may be temporary in character. The symptoms of perennial non-allergic rhinitis (PNAR) can be induced by infections, such as viruses, or by non-specific triggers, such as strong smells, tobacco smoke, dust, and exhaust fumes, and by changes in environmental temperature and humidity. Moreover, PNAR can be associated with nasal polyps. Rhinitis is an illness with a prevalence of 20% in all age groups worldwide. Rhinitis is often regarded as a trivial illness; however, in real-

Table 2. Differentiation of allergic from non-allergic rhinitis

	Allergic rhinitis	Non-allergic rhinitis
Onset of symptoms	Early in life	Usually after the age of 30
Family history	At least one parent affected	Negative
Seasonality	Common (pollens)	Uncommon
Triggers	Suspected allergens identifiable	Symptoms precipitated by irritants/ weather changes
Symptoms	The symptoms occur in the nose and eyes and usually occur after exposure to dust, danders, or certain seasonal pollens	Other systems (infectious origin)
On examination	Nasal turbinates moist, slightly blue	Erythematous, inflamed, often dry mucosa

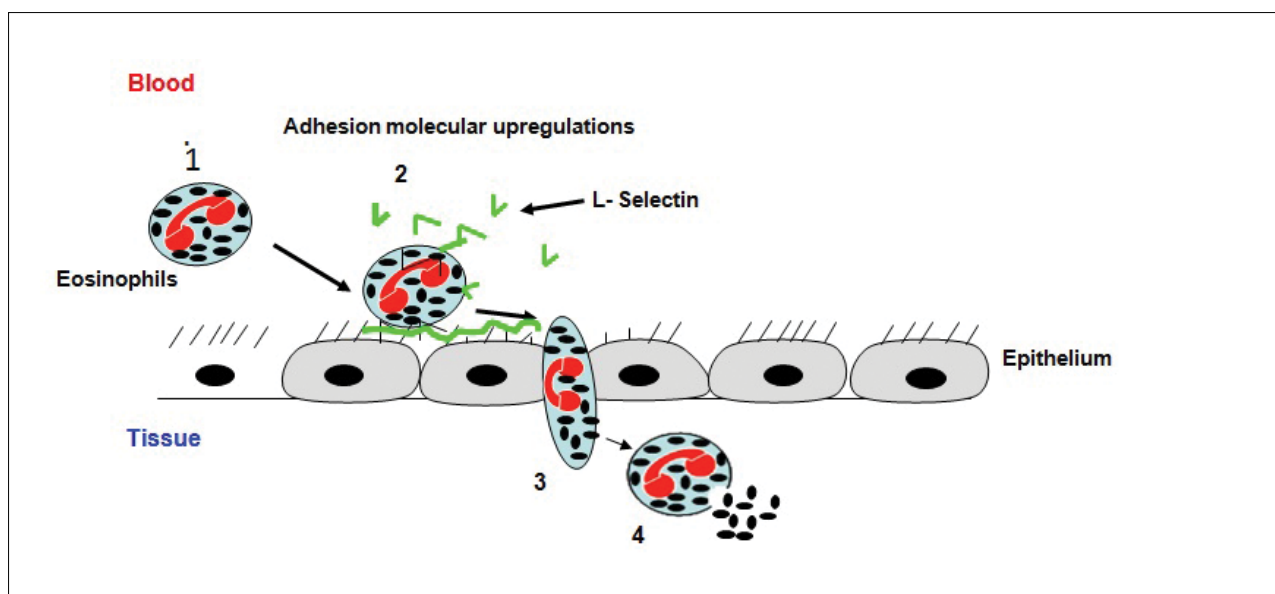


Figure 3. Eosinophils from peripheral blood to the airway wall

ity, it affects the quality of life, causing school- and work-related dysfunction [25].

Mucosal inflammation, a characteristic of rhinitis, is associated with the accumulation of inflammatory cells (eosinophils, mast cells, basophils, lymphocytes, neutrophils, monocytes, and macrophages) in the nasal mucous membrane, as has been demonstrated in biopsy studies with regard to AR [26-28] and NAR [26-29]. The selective recruitment of mast cells and eosinophils has been demonstrated to be important in the pathogenesis of rhinitis [4,30]. Furthermore, it is known that once mast cells and eosinophils are activated, they de-granulate and release their specific mediators in SAR during the pollen season [31,32]. Similar information is available with respect to mediator release in PAR [4,31,32]. A non-allergic type of rhinitis associated with eosinophilia in the secretion is the so-called non-allergic rhinitis with eosinophilia syndrome (NARES). NARES is a condition that has been recognized since 1980 [33-35] and is characterized by (1) perennial symptoms of rhinorrhea, nasal obstruction, and sneezing and (2) the appearance of high numbers of eosinophils in the nasal secretion [36,37]. It has been suggested that NARES is a precursor of the aspirin triad (characterized by intrinsic asthma, nasal polyposis, and aspirin intolerance)

[25,36]. The evolution of NARES appears to involve three stages: secretory eosinophilia with a healthy mucosa, eosinophilic mucosa infiltration, and *in situ* activation of the eosinophils. Studies regarding the degree of activation of the mediator cells in NARES are still limited. Furthermore, there is a controversy regarding the role of neutrophils in the nasal non-infectious inflammation [25,38]. There are differences between AR and NARES (Table 2) [4].

The extent of the epithelial damage in the different types of rhinitis and the correlation of the epithelial damage to the number of the various mediator cells is still not clarified. Some researchers have reported that epithelial shedding could be observed in AR [39,40] and in non-allergic rhinitis [41], whereas others have indicated that the nasal epithelium remains almost completely intact [32,42]. In AR, a chronic inflammatory disease, remodeling is still poorly understood. Although inflammation is similar in allergic rhinitis and asthma, the pathological extent of nasal remodeling and its clinical consequences may be different from those of the bronchi (Figure 3).

In asthmatic and rhinitis inflammation, eosinophils migrate from the capillary blood vessels to the epithelial cell layer of

Table 3. Inflammatory and remodeling patterns in the nasal and bronchial mucosa

	Asthma	COPD	Rhinitis
Airway smooth muscle	Increase metaplasia and hyperplasia	Less than Asthma	None?
Basement membrane	Thickened	Less than asthma	Thin as normal
Epithelium (shedding)	Common, particularly in severe disease	Less than asthma	Less than asthma
Fibrosis	Unlikely	Likely	Unlikely
Blood Vessels (BVs)	Angiogenesis	Likely	Angiogenesis
Glands	Hypertrophy	Hypertrophy	Hypertrophy
Emphysema	No	Yes	Yes
Fibroblasts	Increased numbers	Low numbers	Possibly increased numbers
Myofibroblasts	Present	?	Present
Inflammation (Increasing)	Eosinophils, mast cells, CD3, CD4/Th2, IL4, IL-5	Neutrophils, T cells (CD8), Macrophages, IL-8, TNF- α	Eosinophils, mast cells, CD3, CD4/Th2, IL-4, IL-5

COPD: chronic obstructive pulmonary disease

Table 4. Features of airway wall remodeling in asthma

- Thickening of the basement membrane
- The damage of the epithelium
- Increased number of fibroblast cells
- Increased number of submucous glands
- Increase in blood vessel number and area
- Smooth muscle hypertrophy and hyperplasia
- Increase in airway wall collagen
- Goblet cell hyperplasia

the airway wall. A cascade of events involving various activators and adhesion molecules is involved in this process. This cascade can be arbitrarily divided into four steps (Figure 3).

a) Eosinophils role along the blood vessels, mediated by reversible binding of L-selecting on eosinophils to counter structures on endothelial cells [43]. b) Cytokines and lipid mediators, which diffuse from the inflammatory site, are produced or immunobilized (e.g., PAF) by endothelial cells [44-47] as well as signaling via selectins to activate the rolling eosinophils. This results in a firmer adhesion mediated by lymphocyte function associated antigen 1, macrophage-1 antigen, and very late antigen-4 on eosinophils. The shedding of L-selectin is necessary for transendothelial migration [45,47]. c) Locally produced chemoattractants, such as IL-5 [49,50], regulated on activation T cell expressed and secreted [51], eotaxin [52], and platelet-activating factor, [47,53] induce a migratory response of eosinophils, which initiates transendothelial migration [54]. d) After transendothelial migration, the eosinophils move along the chemotactic gradient towards the airway wall [55,56].

There are similarities and differences with regard to the inflammatory and structural changes of the nasal and bronchial mucosa in rhinitis, asthma, and COPD (Table 3).

Role of the Bronchial and Nasal Epithelium

The respiratory tract, from nasal cavities to the smallest bronchi, is lined by a layer of viscous mucus, which is secreted by the epithelium with the assistance of small ducted glands. Particles that touch the wall of the tract are trapped in this mucus.

The bronchial and nasal epitheliums form the interface between the respiratory system and inspired air. With the exception of the most anterior part of the nasal cavity, where a transition takes place from a cutaneous epithelium to the respiratory epithelium (and not considering the specialized olfactory region), the basic construction of the epithelium of the respiratory tract is similar from the nasal cavity to the bronchioli. The epithelial layer rests on a connective tissue substratum comprising a basement membrane (lamina propria) and submucosa, containing smooth muscle, glands, and cartilage (Figure 1). The bronchial and nasal epithelium is composed of three main cell types that together form a pseudostratified ciliated layer containing ciliated, secretory, and basal cells.

Ciliated cells are terminally differentiated columnar cells that are thought to originate from basal or secretory cells [57,58]. Their main function is to remove particulate matter by means of the mucociliary stairway. Secretory cells, which comprise 15%–25% of the bronchial and nasal epithelium, secrete the mucus in which various particles, including viruses and bacteria, can be trapped [57,58]. There are various types of secretory cells: mucous goblet cells, secretory cells of the tracheal glands, Clara cells, and neuroendocrine cells. Clara cells produce the surfactant apoproteins A and B. In addition, these cells may participate in the clearance of noxious inhaled substances via detoxification processes [59,60]. Serous cells also produce anti-proteases [61]. Neuroendocrine cells, which often occur as ‘cluster’ in small groups, contain amines and peptide hormones [62-64] stored in small granules. Using standard stains for light microscopy, these cells are indistinguishable from basal cells; however, special techniques can be used to distinguish between the two cell types. By immunocytochemistry, it can be demonstrated that calci-

tonin is one of the several endocrine products localized to the small granule cells. While the mucous goblet cell is the predominant secretory cell in the larger airway, the Clara cell is predominant in the bronchioles [65].

Basal cells are considered as the stem cell of the bronchial and nasal epithelium, although there is still some uncertainty regarding this. Basal cells are pyramid-shaped cells with a small cytoplasmic/nuclear ratio. Below the basement membrane, the connective tissue compartment can be found. This compartment contains fibroblasts with their associated matrix, smooth muscle cells, sero-mucous glands, nerves, and capillaries. Varying numbers of granulocytes, lymphocytes, mast cells, and macrophages are observed in the stroma between sero-mucous glands and capillaries (Figure 2) [66-69].

Bronchial epithelial cells are part of the non-specific immune system and defend the airways against the entry of noxious substances [70]. For this defense, the integrity of the epithelial barrier, based on the presence of tight junctions between the epithelial cells, is a necessary prerequisite. In this way, the epithelium forms a physical barrier. Secretion of mucus and fluid in combination with ciliary activity leads to effective mucociliary clearance. The cells of the airway wall also secrete mediators, which provide protection against a range of potentially injurious agents [71].

The major differences between the nose and bronchi are that (a) the nose has venous sinusoids, which largely account for nasal blockage in rhinitis, while vasodilatation is of little significance in asthma; (b) secretions can always be cleared from the nose, whereas they can plug the lower airways; and (c) smooth muscle is present around the bronchial lumen but not around the nasal cavity. Hence, the nose can be described as two congested bronchi without smooth muscle.

Epithelial integrity may also be important in preventing the penetration of inflammatory cells. Adhesion molecules and cell contacts play a crucial role in the maintenance of this integrity, and there are indications that tight junctions and/or desmosomes or hemi-desmosomes may be affected in patients with asthma [72].

Remodeling of the Respiratory Tract

Remodeling is a critical aspect of wound repair in all organs, representing a dynamic process in reaction to an inflammatory insult. Asthma is a chronic inflammatory disease of the airways, the evolution of which follows the natural course of inflammation. Chronic inflammation is always followed by healing, beginning very early and finally resulting in repair [73]. Remodeling results in a thickening of the airway wall [74], including sub-epithelial collagen deposition [75] and sub-mucosal collagen deposition [73,76]. Several patterns of airway remodeling can be found in asthma. These include smooth muscle mass increase, mucous gland enlargement, and vascular remodeling (Table 4 and Figure 1). Growth factors and cytokines are involved in these remodeling processes [3,73,77,78].

Remodeling is the collective term used to describe the structural changes observed in respiratory disease. Structural changes have been reported in a number of conditions, although they are most commonly described in the airways

of patients with asthma. Results reveal that persistent airway inflammation and structural changes are associated with progressive impairment of lung function and probably nasal function. Prioritizing this area of research will be beneficial because the limited data available suggest that remodeling occurs earlier with significant long-term consequences. However, this is not an easy area of research in view of ethical and practical constraints. Therefore, efforts need to be made to maximize the opportunities for obtaining airway tissue from controls and subjects with disease. In addition, a better understanding of normal airway development is essential to accurately interpret the changes in the disease.

In conclusion, asthma and rhinitis are characterized by inflammation in the respiratory tract as well as varying degrees of structural change. In this paper, we have demonstrated the large differences in the characteristics of allergic and non-allergic asthma and rhinitis, respectively. Bronchial hyperreactivity is a phenomenon that clearly has several different etiologies. The function of the epithelial cells, increase in innervations, hypertrophy of the smooth muscles, presence of fibroblast and collagen, and increased vascularization of the blood vessels in patients with allergic asthma and allergic rhinitis could probably contribute to bronchial hypersensitivity. Leukocytes directly interact with bacteria and appear to play a vital role in host defense against pathogens. Drug, such as glucocorticoids, cyclosporine, and cromolyn, have been demonstrated to have inhibitory effects on different cells, such as mast cell degranulation, eosinophils, neutrophils, and mediator release. This review reveals that leukocytes play an active role in such diverse disease as asthma, rhinitis, middle ear infection, and pulmonary fibrosis. Moreover, this review discusses the relationship between the upper and lower airway in respiratory disease and focuses on the effect of respiratory processes on laryngeal inflammation, remodeling, function, and symptoms; however, they also have a central role in the initiation of the allergic immune response. Our findings suggest that there are differences, participation in the development of immunopathological mechanisms of these clinically distinct forms of asthma, rhinitis, and COPD.

Peer-review: This manuscript was prepared by the invitation of the Editorial Board and its scientific evaluation was carried out by the Editorial Board.

Acknowledgements: We thank the following institution for kindly giving us permission to publish results obtained at their sites. Images of bronchial biopsies were obtained at the Department of Respiratory Medicine and Allergology and Clinical Chemistry at Uppsala University Hospital, Uppsala, Sweden. This study was supported by Bror Hjerpstedt Foundation.

Conflict of Interest: No conflict of interest was declared by the author.

Financial Disclosure: The author declared that this study has received no financial support.

Hakem Değerlendirmesi: Bu makale Editörler Kurulu'nun davetiyle hazırlandığından bilimsel değerlendirme Editörler Kurulu tarafından yapılmıştır.

Teşekkür: Kendi sitelerinden alınmış bulguları yayınlamamıza izin verdiği için aşağıdaki kuruma teşekkür ederiz. Bronşiyal biyopsi görüntüleri İsveç, Uppsala, Uppsala Üniversitesi Hastanesi, Solunum Tıbbi ve Allerjoloji ve Klinik Kimya Departmanından temin edildi. Bu çalışma Bror Hjerpstedt Vakfı tarafından desteklendi.

Çıkar Çatışması: Yazar çıkar çatışması bildirmemiştir.

Finansal Destek: Yazar bu çalışma için finansal destek almadığını beyan etmiştir.

REFERENCES

- Martin JA, Kochanek KD, Strobino DM, et al. Annual summary of vital statistics-2003. *Pediatrics* 2005;115:619-34. [CrossRef]
- Amin K. The role of mast cells in allergic inflammation. *Resp Med* 2012;106:9-14. [CrossRef]
- Amin K, Ludviksdottir D, Janson C, et al. Inflammation and structural changes in the airways of patients with atopic and nonatopic asthma. BHR Group. *Am J Resp Crit Care Med* 2000;162:2295-301. [CrossRef]
- Amin K, Rinne J, Haahtela T, et al. Inflammatory cell and epithelial characteristics of perennial allergic and nonallergic rhinitis with a symptom history of 1 to 3 years' duration. *JACI* 2001;107:249-57. [CrossRef]
- Bystrom J, Amin K, Bishop-Bailey D. Analysing the eosinophil cationic protein--a clue to the function of the eosinophil granulocyte. *Resp Res* 2011;12:10-21. [CrossRef]
- Bystrom J, Patel SY, Amin K, Bishop-Bailey D. Dissecting the role of eosinophil cationic protein in upper airway disease. *Curr Opin Allergy Clin Immun* 2012;12:18-23. [CrossRef]
- Amin K, Janson C, Boman G, Venge P. The extracellular deposition of mast cell products is increased in hypertrophic airways smooth muscles in allergic asthma but not in nonallergic asthma. *Allergy* 2005;60:1241-7. [CrossRef]
- Amin K, Janson C, Seveus L, et al. Uncoordinated production of Laminin-5 chains in airways epithelium of allergic asthmatics. *Resp Res* 2005;6:110-21. [CrossRef]
- Douwes J, Gibson P, Pekkanen J, Pearce N. Non-eosinophilic asthma: importance and possible mechanisms. *Thorax* 2002;57:643-8. [CrossRef]
- Gibson PG, Simpson JL, Saltos N. Heterogeneity of airway inflammation in persistent asthma: evidence of neutrophilic inflammation and increased sputum interleukin-8. *Chest* 2001;119:1329-36. [CrossRef]
- Coca AF, Cooke RA. On the classification of the phenomenon of increase in non-allergic bronchial reactivity. *Clin Allergy* 1923;8:163.
- Corrigan CJ. T and B lymphocytes and the development of allergic reactions. In: *Allergy and allergic diseases*. Edited by In: Kay AB e. Oxford: Blackwell Scientific Publications; 1998:36-57.
- Dreborg S, Frew A. Allergen standardization and skin tests. *Allergy* 1993;(Suppl 14):49-54. [CrossRef]
- Lenfant C, Khaltaev N. Global strategy for asthma management and prevention; national heart, lung, and blood institute/world health organization workshop report. 1995;95:3659.
- Mann RD. Modern drug use. An inquiry on historical principles. Lancaster: MTP; 1984.
- Bousquet J, Michel FB. International consensus report on diagnosis and management of asthma. *Allergy* 1992;47:129-32. [CrossRef]
- Holgate ST, Roche WR, Church MK. The role of the eosinophil in asthma. *Am Rev Respir Dis* 1991;143(Suppl 3):66-70. [CrossRef]
- Barnes PJ. New concepts in the pathogenesis of bronchial hyper-responsiveness and asthma. *JACI* 1989;83:1013-26. [CrossRef]
- Jeffery PK, Wardlaw AJ, Nelson FC, et al. Bronchial biopsies in asthma. An ultrastructural, quantitative study and correlation with hyperreactivity. *Am Rev Respir Dis* 1989;140:1745-53. [CrossRef]
- Burrows B, Martinez FD, Halonen M, et al. Association of asthma with serum IgE levels and skin-test reactivity to allergens. *N Engl J Med* 1989;320:271-7. [CrossRef]
- Godard P, Bousquet J, Michael FB. Extrinsic and intrinsic asthma: still a matter for debate? *Clinical Asthma Reviews* 1997;1:19-22.
- Humbert M, Durham SR, et al. IL-4 and IL-5 mRNA and protein in bronchial biopsies from patients with atopic and nonatopic asthma: evidence against "intrinsic" asthma being a distinct immunopathologic entity. *Am J Resp Crit Care Med* 1996;154:1497-504. [CrossRef]
- Walker C, Bode E, Boer L, et al. Allergic and nonallergic asthmatics have distinct patterns of T-cell activation and cytokine production in peripheral blood and bronchoalveolar lavage. *Am Rev Respir Dis* 1992;146:109-15. [CrossRef]
- Borish L, Joseph BZ. Inflammation and the allergic response. *Med Clin North Am* 1992;76:765-87.
- Moneret-Vautrin DA, Wayoff M, Hsieh V, et al. NARES syndrome. A developing link in the Fernand-Widal triad. *Ann Otolaryngol Chir Cervicofac* 1989;106:47-50.
- Bachert C, Wagenmann M, Holtappels G. Cytokines and adhesion molecules in allergic rhinitis. *Am J Rhinol* 1998;12:3-8. [CrossRef]
- Durham SR. Mechanisms of mucosal inflammation in the nose and lungs. *Clin Exp Allergy* 1998;28(Suppl 2):11-6.
- Meltzer EO. The pharmacological basis for the treatment of perennial allergic rhinitis and non-allergic rhinitis with topical corticosteroids. *Allergy* 1997;52(Suppl 36):33-40. [CrossRef]
- Andersson M, Greiff L, Svensson C, et al. Allergic and nonallergic rhinitis. In: *Asthma and rhinitis*. Edited by Holgate ST. Oxford: Blackwell Scientific Publications; 1995:145-53.
- Bentley AM, Jacobson MR, Cumberworth V, et al. Immunohistology of the nasal mucosa in seasonal allergic rhinitis: increases in activated eosinophils and epithelial mast cells. *JACI* 1992;89:877-83. [CrossRef]
- Howarth PH. The cellular basis for allergic rhinitis. *Allergy* 1995;50(Suppl 23):6-10. [CrossRef]
- Rowe-Jones JM. The link between the nose and lung, perennial rhinitis and asthma--is it the same disease? *Allergy* 1997;52(Suppl 36):20-8. [CrossRef]
- Jacobs RL, Freedman PM, Boswell RN. Nonallergic rhinitis with eosinophilia (NARES syndrome). Clinical and immunologic presentation. *JACI* 1981;67:253-62.
- Moneret-Vautrin DA, Hsieh V, Wayoff M, et al. Nonallergic rhinitis with eosinophilia syndrome a precursor of the triad: nasal polyposis, intrinsic asthma, and intolerance to aspirin. *Ann Allergy* 1990;64:513-8.
- Mullarkey MF, Hill JS, Webb DR. Allergic and nonallergic rhinitis: their characterization with attention to the meaning of nasal eosinophilia. *JACI* 1980;65:122-6. [CrossRef]
- Moneret-Vautrin DA, Jankowski R, Bene MC, et al. NARES: a model of inflammation caused by activated eosinophils? *Rhinology* 1992;30:161-8.
- Mullarkey MF. Eosinophilic nonallergic rhinitis. *JACI* 1988;82:941-9. [CrossRef]
- Lee HS, Majima Y, Sakakura Y, et al. Quantitative cytology of nasal secretions under various conditions. *Laryngoscope* 1993;103:533-7. [CrossRef]
- Naito K, Takeda N, Yokoyama N, et al. The distribution of eosinophil cationic protein positive eosinophils in the nasal mucosa of the nasal allergy patients. *Auris Nasus Larynx* 1993;20:197-204. [CrossRef]
- Watanabe K, Watanabe I. Changes of nasal epithelial cells and mucus layer after challenge of allergen. *Ann Otol Rhinol Laryngol* 1981;90:204-9. [CrossRef]
- Kawabori S, Nakamura A, Kanai N. Tissue density and state of activation of eosinophils in the nasal mucosa of allergic and nonallergic rhinopathic patients. *Allergy* 1994;49:81-5. [CrossRef]
- Calderon MA, Lozewicz S, Prior A, et al. Lymphocyte infiltration and thickness of the nasal mucous membrane in perennial and seasonal allergic rhinitis. *JACI* 1994;93:635-43. [CrossRef]

43. Sriramarao P, von Andrian UH, Butcher EC, et al. L-selectin and very late antigen-4 integrin promote eosinophil rolling at physiological shear rates in vivo. *J Immunol* 1994;153:4238-46.
44. Bchner BS, Schleimer RP. The role of adhesion molecules in human eosinophil and basophil recruitment. *JACI* 1994;94:427-38. [\[CrossRef\]](#)
45. Hill ME, Bird IN, Daniels RH, et al. Endothelial cell-associated platelet-activating factor primes neutrophils for enhanced superoxide production and arachidonic acid release during adhesion to but not transmigration across IL-1 beta-treated endothelial monolayers. *J Immunol* 1994;153:3673-83.
46. Kuijpers TW, Hakker BC, Hoogerwerf M, et al. Role of endothelial leukocyte adhesion molecule-1 and platelet-activating factor in neutrophil adherence to IL-1-prestimulated endothelial cells. Endothelial leukocyte adhesion molecule-1-mediated CD18 activation. *J Immunol* 1991;147:1369-76.
47. Zimmerman GA, McIntyre TM, Mehra M, Prescott SM. Endothelial cell-associated platelet-activating factor: a novel mechanism for signaling intercellular adhesion. *J Cell Biol* 1990;110:529-40. [\[CrossRef\]](#)
48. Crockett-Torabi E, Sulenbarger B, Smith CW, Fantone JC. Activation of human neutrophils through L-selectin and Mac-1 molecules. *J Immunol* 1995;154:2291-302.
49. Ohnishi T, Kita H, Weiler D, et al. IL-5 is the predominant eosinophil-active cytokine in the antigen-induced pulmonary late-phase reaction. *Am Rev Respir Dis* 1993;147:901-7. [\[CrossRef\]](#)
50. Walsh GM, Hartnell A, Wardlaw AJ, et al. IL-5 enhances the in vitro adhesion of human eosinophils, but not neutrophils, in a leucocyte integrin (CD11/18)-dependent manner. *Immunology* 1990;71:258-65.
51. Ebisawa M, Yamada T, Bickel C, et al. Eosinophil transendothelial migration induced by cytokines. III. Effect of the chemokine RANTES. *J Immunol* 1994;153:2153-60.
52. Marleau S, Griffiths-Johnson DA, Collins PD, et al. Human RANTES acts as a receptor antagonist for guinea pig eotaxin in vitro and in vivo. *J Immunol* 1996;157:4141-6.
53. Warringa RA, Mengelers HJ, Kuijper PH, et al. In vivo priming of platelet-activating factor-induced eosinophil chemotaxis in allergic asthmatic individuals. *Blood* 1992;79:1836-41.
54. Ager A, Wood A. Downregulation of L-selectin on lymphocytes following binding to high endothelium: A prerequisite for transendothelial migration. *Lymphology* 1994;27(Suppl 1):187-92.
55. Endo H, Iwamoto I, Nakajima H, Yoshida S. In vitro interleukin-5 production of peripheral blood mononuclear cells is increased in patients with asthma. *Int Arch Allergy Immunol* 1993;101:425-30. [\[CrossRef\]](#)
56. Robinson DS, Hamid Q, Ying S, et al. Predominant TH2-like bronchoalveolar T-lymphocyte population in atopic asthma. *N Engl J Med* 1992;326:298-304. [\[CrossRef\]](#)
57. Harkema JR. Comparative aspects of nasal airway anatomy: relevance to inhalation toxicology. *Toxicol Pathol* 1991;19:321-36.
58. McDowell EM, Barrett LA, Glavin F, et al. The respiratory epithelium. I. Human bronchus. *J Natl Cancer Inst* 1978;61:539-49.
59. De Water R, Willems LN, Van Muijen GN, et al. Ultrastructural localization of bronchial antileukoprotease in central and peripheral human airways by a gold-labeling technique using monoclonal antibodies. *Am Rev Respir Dis* 1986;133:882-90.
60. Franken C, Meijer CJ, Dijkman JH. Tissue distribution of antileukoprotease and lysozyme in humans. *J Histochem Cytochem* 1989;37:493-8. [\[CrossRef\]](#)
61. Rogers AV, Dewar A, Corrin B, Jeffery PK. Identification of serous-like cells in the surface epithelium of human bronchioles. *Eur Respir J* 1993;6:498-504.
62. Boers JE, den Brok JL, Koudstaal J, et al. Number and proliferation of neuroendocrine cells in normal human airway epithelium. *Am J Resp Crit Care Med* 1996;154:758-63. [\[CrossRef\]](#)
63. Lauweryns JM, de Bock V, Verhofstad AA, Steinbusch HW. Immunohistochemical localization of serotonin in intrapulmonary neuro-epithelial bodies. *Cell Tissue Res* 1982;226:215-23. [\[CrossRef\]](#)
64. Tsutsumi Y, Osamura RY, Watanabe K, Yanaihara N. Simultaneous immunohistochemical localization of gastrin releasing peptide (GRP) and calcitonin (CT) in human bronchial endocrine-type cells. *Virchows Arch A Pathol Anat Histopathol* 1983;400:163-71. [\[CrossRef\]](#)
65. Widdicombe JG, Pack RJ. The Clara cell. *Eur J Respir Dis* 1982;63:202-20.
66. Ayers MM, Jeffery PK. Proliferation and differentiation in mammalian airway epithelium. *Eur Respir J* 1988;1:58-80.
67. Breuer R, Zajicek G, Christensen TG, et al. Cell kinetics of normal adult hamster bronchial epithelium in the steady state. *Am J Respir Cell Mol Biol* 1990;2:51-8. [\[CrossRef\]](#)
68. Petruson B, Hansson HA, Karlsson G. Structural and functional aspects of cells in the nasal mucociliary system. *Arch Otolaryngol* 1984;110:576-81. [\[CrossRef\]](#)
69. Thompson AB, Robbins RA, Romberger DJ, et al. Immunological functions of the pulmonary epithelium. *Eur Respir J* 1995;8:127-49. [\[CrossRef\]](#)
70. Rennard SI, Romberger DJ, Sisson JH, et al. Airway epithelial cells: functional roles in airway disease. *American journal of respiratory and critical care medicine* 1994;150(Suppl 5):27-30. [\[CrossRef\]](#)
71. Velden VH, Versnel HF. Bronchial epithelium: morphology, function and pathophysiology in asthma. *Eur Cytokine Netw* 1998;9:585-97.
72. Laitinen A, Laitinen LA. Airway morphology: epithelium/basement membrane. *Am J Respir Crit Care Med* 1994;150(Suppl 5):14-7. [\[CrossRef\]](#)
73. Bousquet J, Vignola AM, Chanez P, et al. Airways remodeling in asthma: no doubt, no more? *Int Arch Allergy Immunol* 1995;107:211-4. [\[CrossRef\]](#)
74. Okazawa M, Muller N, McNamara AE, et al. Human airway narrowing measured using high resolution computed tomography. *Am J Resp Crit Care Medicine* 1996;154:1557-62. [\[CrossRef\]](#)
75. Roche WR, Beasley R, Williams JH, Holgate ST. Subepithelial fibrosis in the bronchi of asthmatics. *Lancet* 1989;1:520-4. [\[CrossRef\]](#)
76. Wilson JW, Li X. The measurement of reticular basement membrane and submucosal collagen in the asthmatic airway. *Clin Exp Allergy* 1997;27:363-71. [\[CrossRef\]](#)
77. Godard P, Chaintreuil J, Damon M, et al. Functional assessment of alveolar macrophages: comparison of cells from asthmatics and normal subjects. *JACI* 1982;70:88-93. [\[CrossRef\]](#)
78. Seow CY, Schellenberg RR, Pare PD. Structural and functional changes in the airway smooth muscle of asthmatic subjects. *Am J Resp Crit Care Medicine* 1998;158(Suppl 5):179-86. [\[CrossRef\]](#)