

A Rare Cause of Spontaneous Pneumomediastinum: Ecstasy Ingestion

Spontan Pnömomediastinumun Nadir Bir Nedeni: Ekstazi Kullanımı

Ömer Önal, Leyla Hasdıraz, Fahri Oğuzkaya

Department of Chest Surgery, Erciyes University Faculty of Medicine, Kayseri, Turkey

Abstract

Öz

Ecstasy ingestion has life-threatening effects such as hyperpyrexia, rhabdomyolysis, disseminated intravascular coagulation, coma, and death. In the present report, we aimed to highlight ecstasy as a rare cause of spontaneous pneumomediastinum and its potential life-threatening effects. A 16-year-old female with dyspnea and chest pain presented to the emergency department. Chest computed tomography demonstrated pneumomediastinum at the level of the thoracic inlet and upper and posterior mediastinum. The patient was admitted to the thoracic surgery department with a preliminary diagnosis of spontaneous pneumomediastinum. She refused to answer any questions during the first visit, and a psychiatric consultation was requested. The most important finding of psychiatric consultation was ecstasy abuse, which could not be identified in the emergency department evaluation. Four days later, the symptoms resolved completely and control chest X-rays showed no complications; therefore, the patient was discharged. While investigating the etiology of spontaneous mediastinum, particularly in a young, healthy patient, ecstasy abuse should always be considered. Because the fatal complications that may develop due to ecstasy ingestion may be overlooked.

KEY WORDS: Pneumomediastinum, ecstasy, dyspnea

Ekstazi kullanımının hiperpreksi, rabdomiyoliz, yaygın damar içi pıhtılaşması, koma ve ani ölüm gibi hayatı tehdit eden etkileri olabilir. Biz bu vakada nadir bir spontan pnömomediastinum nedeni olan ekstazi kullanımı ve onun hayatı tehlike arz eden etkilerine dikkat çekmeyi amaçladık. Nefes darlığı ve göğüs ağrısı şikayeti ile acil servise başvuran 16 yaşındaki bayan hastanın çekilen toraks bilgisayarlı tomografisinde pnömomediastinum tespit edildi. Kulak-burun-boğaz, gastroenteroloji ve göğüs cerrahisi konsültasyonları ile larengoskopi, ösefagoskopi, ve bronkoskopik tetkikleri yapılan fakat bir patoloji tespit edilmeyen hasta göğüs cerrahisi servisine yatırıldı. Servis vizitlerinde doktoru ile konuşmak istemeyen hastaya psikiyatri konsültasyonu istendi. Psikiyatri konsültasyonu ile hastanın ekstazi kullanımı sonrası kusma başladığı ve arkasından nefes darlığı ve göğüs ağrısı geliştiği tespit edildi. Dört gün süre ile serviste takip edilen hastada bir komplikasyon gelişmemesi ve şikayetlerinin geçmesi üzerine hasta taburcu edildi. Özellikle sağlıklı ve genç bireylerde tespit edilen spontan pnömomediastinum vakalarında ekstazi kullanımı dikkatli bir şekilde sorgulanmalıdır. Çünkü ekstazi kullanımına bağlı gelişebilecek hayatı tehlike arz eden durumlar gözden kaçırılabilir.

ANAHTAR KELİMELEER: Pnömomediastinum, ekstazi, nefes darlığı

Received/Geliş Tarihi: 16.09.2014

Accepted/Kabul Tarihi: 01.12.2014

Available Online Date/Çevrimiçi Yayın Tarihi: 09.04.2015

INTRODUCTION

Spontaneous pneumomediastinum (SPM) is the existence of free air within the mediastinum without any known precipitating events, such as trauma, surgery, or medical procedures. Although it is a rare, usually benign, and self-limited condition, it is very important to detect the causes that trigger pneumomediastinum, such as exacerbation of asthma, tobacco, use of inhaled drugs, corticosteroids, emesis, cough, physical exercise, labor, and also abuse of recreational drugs such as cocaine and ecstasy [1,2].

CASE PRESENTATION

A 16-year-old female living in an orphanage presented to the emergency department with dyspnea and chest pain. Physical examination, electrocardiogram, routine laboratory tests, and chest radiograph were all unremarkable. Chest computed tomography established pneumomediastinum at the level of the thoracic inlet and upper and posterior mediastinum (Figure 1). The patient was evaluated by a general surgeon, otolaryngologist, gastroenterologist, and thoracic surgeon. Endoscopic evaluations (esophagoscopy, laryngoscopy, and bronchoscopy) revealed no esophageal or upper respiratory tract pathologies. The patient was admitted to the thoracic surgery department with a preliminary diagnosis

This case was presented as a poster at 22nd Annual Meeting of the Asian Society for Cardiovascular and Thoracic Surgery (3-6 April 2014, Istanbul, Turkey).

Bu vaka 22. Uluslararası Asya Göğüs-Kalp-Damar Cerrahisi Kongresi'nde (3-6 Nisan 2014, İstanbul, Türkiye) poster olarak sunulmuştur.

Address for Correspondence/Yazışma Adresi: Ömer Önal, Erciyes Üniversitesi Tıp Fakültesi, Göğüs Cerrahisi Anabilim Dalı, Kayseri, Türkiye
Phone/Tel: +90 352 207 66 66 E-mail/E-posta: omeronal@erciyes.edu.tr

©Telif Hakkı 2015 Türk Toraks Derneği - Makale metnine www.toraks.dergisi.org web sayfasından ulaşılabilir.

©Copyright 2015 by Turkish Thoracic Society - Available online at www.toraks.dergisi.org

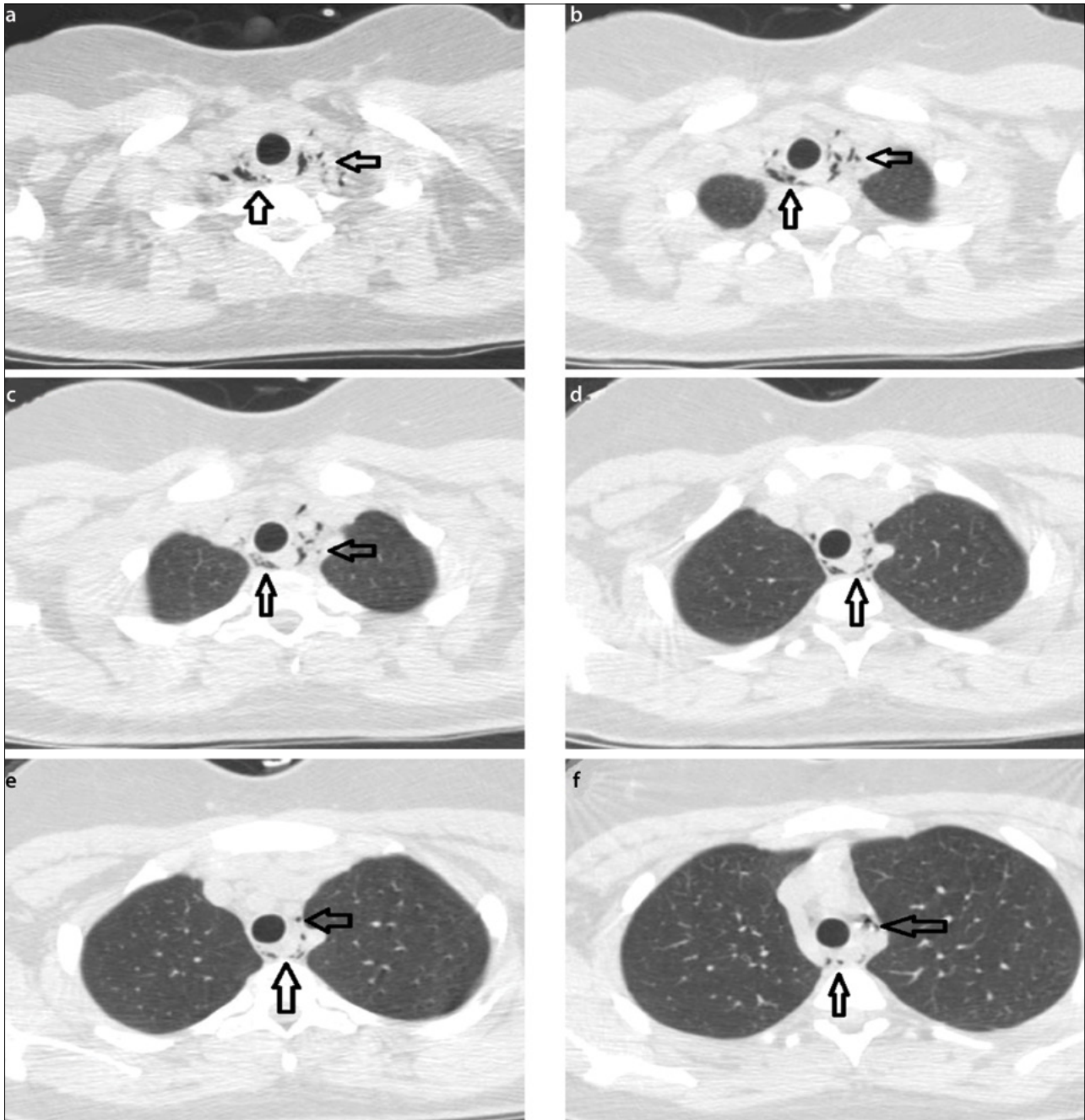


Figure 1. Axial plain computed tomography images (lung window) of the thorax. (a): thoracic inlet, (b, c): paratracheal, paraesophageal, and subcarinal (d-f): upper and posterior mediastinum demonstrate pneumomediastinum (arrows)

of SPM for follow-up. The vital signs were stable (blood pressure: 120/74 mmHg, pulse rate: 74 beats/min, temperature: 36.5°C, respiratory rate: 20 breaths/min, oxygen saturation: 95%). The patient refused to communicate with the doctor or answer any questions during the first visit, and psychiatric consultation was requested. Psychiatric consultation revealed that the patient had been placed in the orphanage 3 years ago. Since then, she would become angry at everything and damage her surroundings; she was therefore taking antidepressant drugs. The most important finding of psychiatric consultation was ecstasy abuse, which could not be identified in the emergency department evaluation. The patient informed that vomiting had begun after ecstasy ingestion and she suffered from dyspnea and chest pain an hour later.

The patient subsequently became stable; hence, we decided to treat her conservatively. Within 4 days, the symptoms resolved and the patient was discharged with a normal chest X-ray.

At a follow-up visit 1 month later, she did not present any symptoms and her chest X-ray, lung function tests, and blood gas analysis were also evaluated as normal.

DISCUSSION

Ecstasy (methylenedioxyamphetamine) is an amphetamine derivative that is abused for its effects such as euphoria and increased sense of well-being [3]. Ecstasy ingestion can lead to side effects such as psychosis (even after a single dose), convulsions, cerebral infarction, coma, and death [3].

With regard to SPM, some studies have recommended outpatient treatment and follow-up for stable patients with no complications [4]. However, if the history cannot be determined clearly, as in the present case, a short, in-hospital observation may be required. Although there are no reports of mortality directly related to SPM, the main cause of SPM, such as ecstasy ingestion, may lead to significant and potentially life-threatening complications including hyperpyrexia, rhabdomyolysis, hepatitis, ARDS, ketoacidosis, as well as disseminated intravascular coagulation resulting in acute renal failure [5].

Valsalva maneuvers known to cause SPM include coughing, sneezing, vomiting, defecation, inhalation of cocaine, giving birth, and blowing up party balloons [6]. In the present case, presence of mediastinal air was most likely due to positive pressure or prolonged Valsalva maneuvers that trigger microscopic esophageal tears, finally causing air leakage into the mediastinal space, as supported in the literature [7,8]. We believe that in the present case, the cause of SPM was not pharmacological or dose related but related to the Valsalva maneuvers associated with the vomiting induced by the drug [9,10]. No pathologies were detected to explain the cause of vomiting. The underlying mechanism remains unknown, although the direct pharmacological effects of ecstasy on the respiratory system, which increases the intrathoracic pressure, or drug-induced vomiting can be considered [2,9,10].

Usually surgical treatment is not necessary in patients with pneumomediastinum and pneumopericardium. In most cases, observation and monitoring are enough to evaluate spontaneous healing. Small pneumothoraces can resolve with oxygen therapy. However, when large pneumothoraces are detected, tube thoracostomy is mandatory to prevent tension pneumothorax. In the present case, conservative treatment was adequate for healing.

Although SPM is mostly a self-limited condition, observation is necessary until the symptoms and radiographic changes disappear. While investigating the etiology of spontaneous mediastinum, particularly in a young, healthy patient, ecstasy abuse should always be considered. This is because the fatal complications that may develop because of this drug may be overlooked.

Informed Consent: Written informed consent was obtained from patients who participated in this study.

Peer-review: Externally peer-reviewed.

Author Contributions: Concept - Ö.Ö., L.H., F.O.; Design - Ö.Ö., L.H., F.O.; Supervision - Ö.Ö., L.H., F.O.; Data Collection and/or

Processing - Ö.Ö., L.H., F.O.; Analysis and/or Interpretation - Ö.Ö., L.H., F.O.; Literature Review - Ö.Ö.; Writer - Ö.Ö., L.H., F.O.; Critical Review - Ö.Ö., L.H., F.O.

Conflict of Interest: No conflict of interest was declared by the authors.

Financial Disclosure: The authors declared that this study has received no financial support.

Hasta Onamı: Yazılı hasta onamı bu çalışmaya katılan hastalardan alınmıştır.

Hakem değerlendirmesi: Dış bağımsız.

Yazar Katkıları: Fikir - Ö.Ö., L.H., F.O.; Tasarım - Ö.Ö., L.H., F.O.; Denetleme - Ö.Ö., L.H., F.O.; Veri toplanması ve/veya işlemesi - Ö.Ö., L.H., F.O.; Analiz ve/veya yorum - Ö.Ö., L.H., F.O.; Literatür taraması - Ö.Ö.; Yazıyı yazan - Ö.Ö., L.H., F.O.; Eleştirel inceleme - Ö.Ö., L.H., F.O.

Çıkar Çatışması: Yazarlar çıkar çatışması bildirmemişlerdir.

Finansal Destek: Yazarlar bu çalışma için finansal destek almadıklarını beyan etmişlerdir.

REFERENCES

1. Levent E, Sarıman N. Pneumomediastinum and subcutaneous emphysema without pneumothorax in an asthmatic patient. *Eurasian J Pulmonol* 2008;10:131-5.
2. Sabine B, Christine A. Ecstasy induced pneumomediastinum and pneumothorax-new causes, new questions. *Resp Med Extra* 2005;1:53-5. [\[CrossRef\]](#)
3. Mutlu H, Şilit E, Pekkafulı Z, et al. 'Ecstasy'(MDMA)-induced pneumomediastinum and epidural pneumatosis. *Diagn Intervent Radiol* 2005;11:150-1.
4. Campillo-Soto A, Coll-Salinas A, Soria-Aledo V, et al. Spontaneous pneumomediastinum: descriptive study of our experience with 36 cases. *Arch Bronconeumol* 2005;41:528-31. [\[CrossRef\]](#)
5. Yeşil O, Onur Ö, Güneysel Ö. The danger we could not foresee: Extacy. *JAEM* 2008;4:14-9.
6. Koulias G, Karkolis D, Wang X, et al. Current assessment and management of spontaneous pneumomediastinum: experience in 24 adult patients. *Eur J Cardiothorac Surg* 2004;25:852-5. [\[CrossRef\]](#)
7. Haim DY, Lippmann ML, Goldberg SK, et al. The pulmonary complications of crack cocaine. A comprehensive review. *Chest* 1995;107:233-40. [\[CrossRef\]](#)
8. Seaman ME. Barotrauma related to inhalational drug abuse. *J Emerg Med* 1990;8:141-9. [\[CrossRef\]](#)
9. Levine AJ, Drew S, Rees GM. "Ecstasy" induced pneumomediastinum. *J R Soc Med* 1993;86:232-3.
10. Rezvani K, Kurbaan AS, Brenton D. Ecstasy induced Pneumomediastinum. *Thorax* 1996;51:960-1. [\[CrossRef\]](#)