

Type I Neurofibromatosis Complicated by Large Cell Neuroendocrine Carcinoma of the Lung

Akciğerin Büyük Hücreli Nöroendokrin Karsinomu ile Komplike Tip 1 Nörofibromatozis

Amangar Nadia, Zahraoui Rachida, Al Ataouna Khaoula, Soualhi Mouna, İraqi Ghali, Bourkadi Jamal Eddine

Department of Pneumology, Moulay Youssef Hospital, Ibn Sina University Hospital, Rabat, Morocco

Abstract

Özet

Neurofibromatosis 1 (NF 1), or Von Recklinghausen's disease, is one of the most common genetic diseases that are shown to be associated with several malignancies. The most common malignant tumors associated with NF are neurogenic tumors, while primary lung carcinomas are quite rare. We reported a 40-year-old patient, with a known family history of NF 1, who suffered from cough, dyspnea, and impaired general condition for the past 5 months. Radiography and CT chest showed the presence of a large left upper lobe mass measuring 13 cm in transverse diameter and 16 cm in anteroposterior diameter pressing on the trachea, left main bronchus, aortic arch, and left pulmonary artery. It was associated with multiple hilar and carinal lymph nodes, reticular nodular interstitial infiltrate on the right upper lobe, pericardial effusion, and minimal left pleural effusion; we also noted the presence of a hypodense cutaneous mass on the left upper anterior chest wall measuring 2.8 cm in diameter, and there was no lytic rib lesion. Bronchoscopy revealed the presence of several vegetations, and the biopsy was compatible with large cell neuroendocrine carcinoma. There were multiple liver, bone, and pleural-pericardial metastases. Palliative chemotherapy was indicated. The patient died 4 months after the diagnosis. Association of Von Recklinghausen's disease with lung cancer is quite rare; nevertheless, it increases disease severity and is related with poor survival. Because of its unpredictable evolution, regular supervision is necessary.

KEY WORDS: Neurofibromatosis, Von Recklinghausen's disease, lung cancer, neuroendocrine carcinoma

Geliş Tarihi/Received: 15.05.2014 **Kabul Tarihi/Accepted:** 20.08.2014

Nörofibromatozis 1 (NF 1) veya von Recklinghausen hastalığı bazı malignitelerle ilişkili olduğu gösterilen en yaygın genetik hastalıklardan biridir. NF ile ilişkili en sık görülen malign tümörler nörojenik tümörlerdir oysa primer akciğer karsinomları oldukça nadirdir. Biz son 5 aydır öksürük, nefes darlığı ve bozulmuş genel durumdan muzdarip, bilinen bir NF 1 aile öyküsü olan, 40 yaşındaki hastayı rapor ettik. Radyografi ve göğüs BT; transvers çapı 13 cm ve anteroposterior çapı 16 cm olan, trakea, sol ana bronş, aort arkı ve sol pulmoner arter üzerine bası yapan büyük bir sol üst lob kitle varlığını gösterdi. Kitle; çoklu hiler ve karinal lenf nodları, sağ üst lobda retiküler nodüler interstisyel infiltrasyon, perikardiyal efüzyon ve minimal sol plevral efüzyon ile ilişkiliydi, ayrıca 2.8 cm çapında, sol üst anterior göğüs duvarında bir hipodens kütanöz kitle varlığını kaydettik ve hiçbir litik kaburga lezyonu yoktu. Bronkoskopi birçok vejetasyon varlığını ortaya koydu ve biyopsi büyük hücreli nöroendokrin karsinom ile uyumlu idi. Çoklu karaciğer, kemik, plevra-perikard metastazları vardı. Palyatif kemoterapi endike idi. Hasta tanı konulduktan 4 ay sonra öldü. Akciğer kanseri ile von Recklinghausen hastalığının ilişkisi çok nadirdir bununla birlikte hastalığın şiddetini artırır ve kötü sağkalım ile ilişkilidir. Öngörüle-meyen gelişimi nedeniyle düzenli bir gözetim gereklidir.

ANAHTAR SÖZCÜKLER: Nörofibromatozis, von Recklinghausen hastalığı, akciğer kanseri, nöroendokrin karsinom

INTRODUCTION

Most tumors that occur in Von Recklinghausen's disease or type I neurofibromatosis (NF 1) are benign neurofibromas; malignant tumors that are associated with NF 1 increase the disease severity. The distribution of malignant tumors is very different from that of the general population of tumors: 50% of them originate from central nervous system [1,2], and the occurrence of lung cancer is rarely reported, while there are no reported cases of large cell neuroendocrine carcinomas associated with NF 1, according to our knowledge.

We report a case who was hospitalized in the Pulmonary Department of Moulay Youssef Hospital in Rabat, suffering from Von Recklinghausen's disease, in whom large cell neuroendocrine lung cancer was diagnosed.

CASE PRESENTATION

Our case was a 40-year-old man with a history of familial type 1 neurofibromatosis. He was an ex-smoker with a smoking history of 30 pack-years. He presented with a 5-month history of moderate left chest pain, radiating to the left upper limb, associated with stage II NYHA dyspnea and dry cough, accompanied by dysphonia, asthenia, anorexia, and weight



Address for Correspondence / Yazışma Adresi: Nadia Amangar, Department of Pneumology, Moulay Youssef Hospital, Ibn Sina University Hospital, Rabat, Morocco. Phone/Tel: + (212) 6 76 91 43 96 E-mail/E-posta: amangar.nadia@gmail.com

©Telif Hakkı 2014 Türk Toraks Derneği - Makale metnine www.toraks.dergisi.org web sayfasından ulaşılabilir.

©Copyright 2014 by Turkish Thoracic Society - Available online at www.toraks.dergisi.org

loss of 14 kg in 5 months. On clinical examination, the patient was poor general condition, and his saturation on room air was 94%. There was clubbing and a chest deformity and crackles on auscultation in the upper two-thirds of the left hemithorax; there was no reproducible pain by palpation.

The cutaneous examination revealed "café au lait" spots all over the trunk, multiple typical and plexiform neurofibromas (Figure 1, 2) in the right lateral-cervical region, suprasternal, in the upper limbs, in the back, and the upper anterior part of the left hemithorax, some of which were painful on palpation. There were no palpable lymph nodes, and clinical examination of the systems was within normal limits. The chest radiograph (Figure 3) showed a homogeneous opacity occupying the upper two-thirds of the left hemithorax, a left basal, round opacity with sharp borders, and nodular and micronodular opacities occupying half of the right lung. Hemoglobin was 11.4 g/dL, white blood cell count was

11,800/mm³, erythrocyte sedimentation rate was 165 mm/h, C-reactive protein was 81.10 mg/L, and renal and hepatic tests were within normal limits.

Chest CT (Figure 4) showed the presence of a large left upper lobe mass measuring 13 cm in transverse diameter and 16 cm in anteroposterior diameter pressing on the trachea, aortic arch, and left pulmonary artery and obstructing the left main bronchus. It associated with multiple hilar and carinal lymph nodes, reticular nodular interstitial infiltrates on the right upper lobe, pericardial effusion, and left pleural effusion; we also noted the presence of a hypodense cutaneous mass of the left upper anterior chest wall measuring 2.8 cm in diameter, and there was no lytic rib lesion. Transthoracic echocardiography confirmed the presence of average-abundance pericardial effusion without signs of cardiac tamponade.

Bronchoscopy found left vocal cord paralysis, with an aspect of extrinsic compression at the entry of the left main bronchus with two small vegetations and broadening of the left interlobar carina; the left upper lobe was infiltrated with vegetations. There was stenosis of the superior segmental

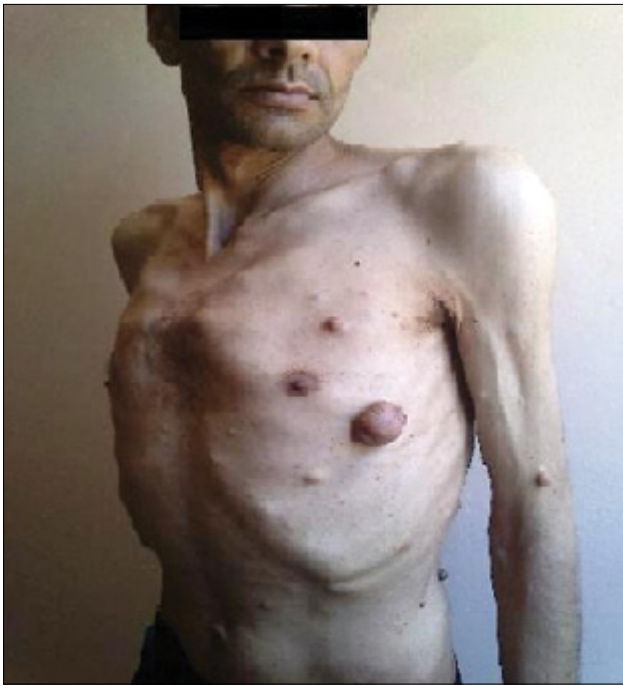

Figure 1. Cutaneous neurofibromas

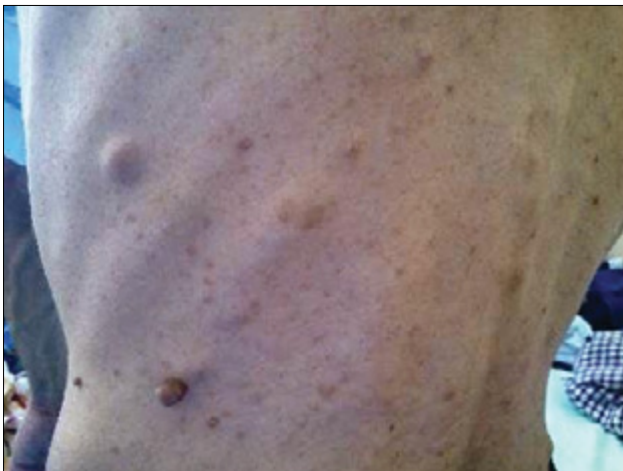

Figure 2. Café au lait spots

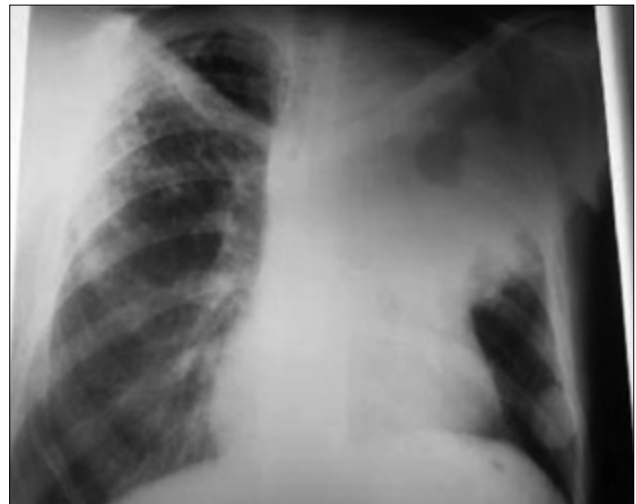

Figure 3. Chest X-ray: opacity of the upper two-thirds of the left hemithorax, associated with left basal opacity and contralateral nodular and micronodular opacities

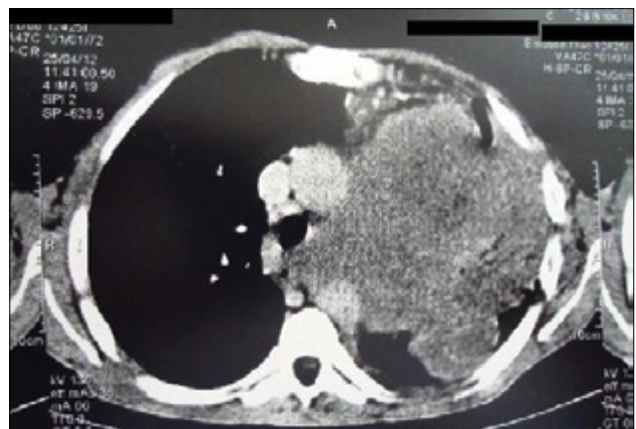


Figure 4. CT view using a mediastinal window: upper left lobe mass pushing the trachea, the left lobe bronchus, the arch of the aorta, and the left pulmonary artery

CT: computed tomography

bronchus of the left lower lobe with tumoral infiltration. The right bronchial tree was normal.

The biopsies at the protuberances and the infiltrated mucosa showed poorly differentiated non-small-cell carcinoma of gland-like origin, and the immunohistochemical examination was compatible with large cell neuroendocrine carcinoma (Figure 5). Bronchial lavage revealed neoplastic cells. The staging has objectified the presence of liver, bone, and pleural-pericardial metastases; palliative treatment with chemotherapy was indicated, but due to the hepatic cytolysis, the patient died 4 months after the diagnosis.

DISCUSSION

Neurofibromatosis 1 (NF 1), or Von Recklinghausen's disease, is one of the most common genetic diseases. This is an autosomal dominant disorder; disease expression varies, even within families [1]. The National Institutes of Health Consensus Development Conference in Bethesda, MD, USA, established seven diagnostic criteria for the diagnosis of NF 1.

The diagnostic criteria for NF 1 are met in an individual if two or more of the following are found [3]:

- Six or more café-au-lait macules over 5 mm in greatest diameter in prepubertal individuals and over 15 mm in greatest diameter in postpubertal individuals.
- Two or more neurofibromas of any type or one plexiform neurofibroma.
- Freckling in the axillary or inguinal region.
- Optic glioma.
- Two or more Lisch nodules (iris hamartomas).
- A distinctive osseous lesion, such as sphenoid dysplasia or thinning of long bone cortex with or without pseudarthrosis.
- A first-degree relative (parent, sibling, or offspring) with NF 1 by the criteria above.

The case report meets the criteria for the presence of several similar familial cases of NF 1, café au lait spots, and neurofibromas (cutaneous and plexiform). Respiratory complications of NF 1 are quite rare; the most common involvement is bullous lung dystrophy, which was reported in 6% in the series of Bukhatter et al. [4]. NF1 may also be complicated by benign tumors; malignant tumor complications are rare,

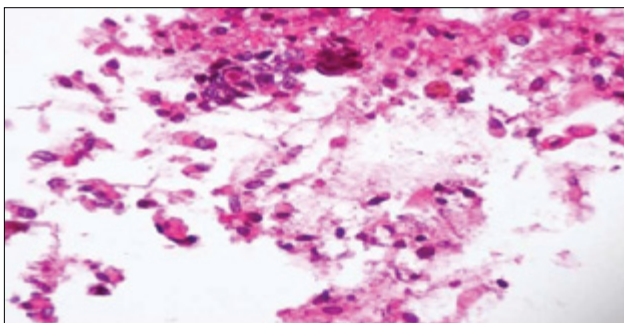


Figure 5. Histology: large cell neuroendocrine carcinoma

and malignant nerve sheath tumor (formerly neurofibrosarcoma) is the main complication of NF 1 in adulthood. Malignant tumors are very rare before the age of 10, and the risk of occurrence in the life of a patient with NF 1 is on the order of 3% to 4% [1,2]. Tumor complications are due to mutation of the NF 1 gene, leading to the deregulation of growth and/or differentiation of cells [1,5].

In a Swedish study [6] of 70 patients with NF 1 who were followed for a long period (1978-1989), the occurrence of malignancies was approximately 4 times higher than expected in the general population; carcinoma was present in 16% of cases—mostly metastatic cases. In two cases, they found two concomitant malignant tumors: a woman who had a metastatic breast cancer and two years later developed adenocarcinoma of the rectum, and another woman who had an adenocarcinoma of the small intestine and also developed rectal adenocarcinoma 10 years later. The same study found that the average age at onset of these malignancies was 52 years for men and 56 years old for women.

Lung cancers are rarely described in Von Recklinghausen's disease. Indeed, only 11 cases of neurofibromatosis associated with bronchopulmonary cancer have been reported in the Japanese literature until 1992, with a clear predominance of adenocarcinomas [7]. Neurofibromas may develop at the bronchial tree wall; their risk of malignant degeneration is not negligible, with a frequency between 3% and 5%, and this risk increases with age to 8%-13% [5]. We found only a few cases of small cell carcinoma associated with NF 1: the first case was a 36-year-old man with bullous emphysema [8] whose tumor progression was rapid despite chemoradiotherapy; he died 11 months after the diagnosis. The second case was described in Tunisia by Msaad et al. [9]: a 41-year-old patient with Von Recklinghausen's disease who presented with a chronic cough, diffuse chest pain, and deterioration of the general status. The CT scan found a large right hilar mass and mediastinal hilar lymphadenopathy associated with diffuse bilateral centrilobular emphysema. After the first cycle of chemotherapy, there was a profound alteration of the condition, with high tumor extension; the second cycle of chemotherapy was delayed due to pneumonia, and the patient died 3 months after the diagnosis [9]. Also, another case of carcinosarcoma of the lung associating with NF1 has been described by Citil et al. [10] in a 57-year-old man.

Some authors suggest that the rapid tumor progression is the result of hypersecretion of granulocyte colony-stimulating factor (GCSF) [11]. However, the association between Von Recklinghausen's disease and tumor secretion of GCSF remains controversial [4]. The association of NF1 and neuroendocrine carcinoma has been described by several authors, especially abdominal [12], duodenal [13,14], pancreatic [15], and mediastinal [16,17] tumors, but we found no cases of familiar neurofibromatosis associated with large cell neuroendocrine carcinoma in the literature.

In conclusion, association of Von Recklinghausen's disease with lung cancer is quite rare; nevertheless, it increases disease severity and is related with poor survival. Because of its unpredictable evolution, regular supervision is necessary.

Informed Consent: As the patient died, consent is obtained from the family.

Peer-review: Externally peer-reviewed.

Author Contributions: Concept - A.N.; Design - A.N.; Supervision - A.N., Z.R., S.M., I.G., B.J.E.; Funding - A.N., Z.R., A.K., S.M., I.G., B.J.E.; Materials - A.N., Z.R.; / Data Collection and/or Processing - A.N., Z.R., A.K., S.M., I.G., B.J.E.; Analysis and/or Interpretation - A.N., Z.R., A.K., S.M., I.G., B.J.E.; Literature Review - A.N., Z.R.; Writer - A.N., Z.R., A.K., S.M., I.G., B.J.E.; Critical Review - Z.R., I.G.

Conflict of Interest: No conflict of interest was declared by the authors.

Financial Disclosure: The authors declared that this study has received no financial support.

Hasta Onamı: Hastanın ölümü sebebiyle, onam aileden alınmıştır.

Hakem Değerlendirmesi: Dış bağımsız.

Yazar Katkıları: Fikir - A.N.; Tasarım - A.N.; Denetleme - A.N., Z.R., S.M., I.G., B.J.E.; Kaynaklar - A.N., Z.R., A.K., S.M., I.G., B.J.E.; Malzemeler - A.N., Z.R.; Veri toplanması ve/veya işlenmesi - A.N., Z.R., A.K., S.M., I.G., B.J.E.; Analiz ve/veya yorum - A.N., Z.R., A.K., S.M., I.G., B.J.E.; Literatür taraması - A.N., Z.R.; Yazıyı yazan - A.N., Z.R., A.K., S.M., I.G., B.J.E.; Eleştirel inceleme - Z.R., I.G.

Çıkar Çatışması: Yazarlar çıkar çatışması bildirmemişlerdir.

Finansal Destek: Yazarlar bu çalışma için finansal destek almadıklarını beyan etmişlerdir.

REFERENCES

- Pinson S, Wolkens P. La neurofibromatose 1 (NF1) ou maladie de Von Recklinghausen. *Rev Med Int* 2005;26:196-215. [\[CrossRef\]](#)
- Sorensen SA, Mulvihill JJ, Nielsen A. Long-term follow-up of von Recklinghausen neurofibromatosis: survival and malignant neoplasms. *N Engl J Med* 1986;314:1010-5. [\[CrossRef\]](#)
- National Institutes of Health Consensus Development Conference Statement: Neurofibromatosis. *Arch Neurol* 1988;45:575-8. [\[CrossRef\]](#)
- Burkhalter JL, Morano JU, McCay MB. Diffuse interstitial lung disease in neurofibromatosis. *South Med J* 1986;79:944-6. [\[CrossRef\]](#)
- Bertoletti L, Sztrymf B, Tourneux H, et al. Pulmonary complications of neurofibromatosis. *Encyc Med Chir* 2008; 6-062-D-50.
- Madeleine ET, Zöller ME, Birgitta R, et al. Malignant and benign tumors in patients with neurofibromatosis type 1 in a defined Swedish population. *Cancer* June 1997;79:2125-31. [\[CrossRef\]](#)
- Itoi K, Yanagihara K, Okubo K, Kuwabara M. A case of lung cancer in a patient with Von Recklinghausen's disease. *Nihon Kyobu Shikkan Gakkai Zasshi* 1992;30:317-21.
- Nagai H, Kurashima A, Yoneda R, et al. A case of Recklinghausen's disease associated with multiple emphysematous bullae and lung cancer. *Nihon Kyobu Shikkan Gakkai Zasshi* 1989;27:625-9.
- Msaad S, Ketata W, Yangui I, Ayoub A. Family neurofibromatosis complicated by small cell carcinoma of the lung: A case report. *Tunisian Military Health Review* 2010;12:60-2.
- Cıtlı R, Ciralik H, Karşlıgil A, et al. Carcinosarcoma of the lung associated with neurofibromatosis type 1: a case report. *Turk Patoloji Derg* 2012;28:90-4.
- Shimizu Y, Tsuchiya S, Watanabe S, Saitoh R. Von Recklinghausen's disease with lung cancer derived from the wall of emphysematous bullae. *Intern Med* 1994;33:167-71. [\[CrossRef\]](#)
- De Grez T, Lambert M, Delaere B, et al. Type I neurofibromatosis (von Recklinghausen's disease) associated with abdominal neurofibrosarcoma and pheochromocytoma. A case report. *Acta Clin Belg* 1991;46:89-93.
- Caiazza R, Mariette C, Piessen G, et al. Type I neurofibromatosis, pheochromocytoma and somatostatinoma of the ampulla. Literature review. *Ann Chir* 2006;131:393-7. [\[CrossRef\]](#)
- Cappelli C, Agosti B, Braga M, et al. Von Recklinghausen's neurofibromatosis associated with duodenal somatostatinoma. A case report and review of the literature. *Minerva Endocrinol* 2004;29:19-24.
- Jensen RT, Berna MJ, Bingham DB, Norton JA. Inherited pancreatic endocrine tumor syndromes: advances in molecular pathogenesis, diagnosis, management, and controversies. *Cancer* 2008;113:1807-43. [\[CrossRef\]](#)
- Bennis A, Ridai M, Nafidi S, et al. Malignant mediastinal schwannoma in Recklinghausen's disease presenting as cardiac tamponade. Report of two cases. *Arch Mal Coeur Vaiss* 2000;93:381-4.
- Suzuki H, Yamaguchi Y, Kimura H, et al. Malignant mediastinal schwannoma associated with von Recklinghausen's disease--a resected case. *Nihon Kyobu Geka Gakkai Zasshi* 1996;44:864-8.