

A Case of Langerhans Cell Histiocytosis with Atypical Radiological Presentation

Atipik Radyolojik Prezantasyonlu Bir Langerhans Hücreli Histiyoitoz Olgusu

Murat Türk¹, Haluk Türkteş¹, Nalan Akyürek²

¹Department of Chest Diseases, Gazi University Faculty of Medicine, Ankara, Turkey

²Department of Pathology, Gazi University Faculty of Medicine, Ankara, Turkey

Abstract

Özet

Pulmonary Langerhans cell histiocytosis (PLCH) is a rare interstitial lung disease characterized by the accumulation of histiocytes within the airspaces or parenchyma of the lung. It almost always occurs in smokers between the ages of 20 and 40. Bronchoscopic interventions, such as transbronchial biopsy (TBB) and bronchoalveolar lavage (BAL), should be performed before other more invasive procedures, but their diagnostic yield is lower. TBB is frequently nondiagnostic due to inadequate sampling. BAL cellular analysis may show alveolar macrophage predominance, and the detection of >5% of CD1a-positive cells in BAL fluid is highly suggestive and specific for the disease; however, this increase is not observed frequently. Surgical lung biopsy is the most definite modality for diagnosis. Smoking cessation must be recommended for all patients. The prognosis for most patients is relatively good, particularly if longitudinal lung function testing shows stability. Here, we presented a 48-year-old smoker with an unusual and unexpected radiological presentation.

KEYWORDS: Interstitial lung disease, Langerhans cell histiocytosis, radiological presentation

Received/Geliş Tarihi: 26.02.2014

Accepted/Kabul Tarihi: 18.07.2014

Available Online Date/Çevrimiçi Yayın Tarihi: 05.11.2014

Langerhans hücreli histiyoitoz-X, akciğer parenkim ya da havayollarında histiyosit birikimi ile karakterize nadir bir interstisyel akciğer hastalığıdır. Yirmi-kırk yaşları arasında sıklıkla sigara içen bireylerde izlenmektedir. Tanısal TBB ve BAL'ın tanı değerleri her ne kadar düşükse de, daha invaziv girişimlerden önce denenmelidirler. TBB genellikle yetersiz örnekleme nedeni ile düşük tanısal değere sahiptir. BAL hücre analizinde genellikle alveolar makrofaj hakimiyeti izlenmektedir. >5% CD1a+ hücrelerin görülmesi hastalık için yüksek spesifiteye sahiptir ancak bu hücreler sıklıkla izlenmemektedirler. Cerrahi biyopsi hastalık için kesin tanı yöntemidir. Hastalık özellikle solunum fonksiyon testleri stabil izleyen grupta iyi seyirlidir ve tüm hastalara mutlak sigara bırakımı önerilmelidir. Burada 48 yaşında, sigara içicisi, nadir ve beklenmedik radyolojik prezantasyona sahip bir olgu sunulmuştur.

ANAHTAR SÖZCÜKLER: İnterstisyel akciğer hastalığı, Langerhans hücreli histiyoitoz, radyolojik sunuş

INTRODUCTION

Pulmonary Langerhans cell histiocytosis (PLCH) is an uncommon interstitial lung disease that generally, but not always, occurs in cigarette smokers. The pathologic feature of the disease is the accumulation of Langerhans and other inflammatory cells in small airways, which results in the formation of nodular lesions. Chest computed tomography (CT) scanning may show characteristic nodular and cystic lesions. Surgical lung biopsy is the most common modality for the diagnosis. Herein, we report an atypical radiological manifestation of PLCH.

CASE PRESENTATION

A 48-year-old woman was referred to our clinic for exertional dyspnea and pathological findings in her chest imaging. She was first admitted to the hospital with dyspnea, arthralgia, and a round-shaped macular rash below her knees.

Her medical history was unremarkable. She had 22 pack-years of cigarette smoking history and stopped smoking 2 years ago. Her initial physical examination and pulse SpO₂ value were normal. Complete blood count (CBC), C-reactive protein (CRP) level, and biochemistry panel were in the normal ranges. Pulmonary function tests were in the normal ranges. Diffusion capacity was decreased (Table 1). The chest x-ray showed bilateral hazy reticular interstitial opacities in the lower lobes. The high-resolution computed tomography (HRCT) demonstrated bilateral peripheral ground-glass opacities and intralobular interstitial and interlobular septal thickening with lower lobe predominance (Figure 1). Nonspecific interstitial pneumonia was suspected on the basis of the radiological findings, and bronchoscopy was performed. Pathological findings of a mucosal punch biopsy and TBB were nondiagnostic. Cellular analysis of the bronchoalveolar lavage showed 95% macrophages and 2% lymphocytes. To obtain a definite diagnosis, the patient underwent a video-assisted thoracoscopic lung biopsy. In the microscopic examination, multiple stellate inflammatory and fibrotic nodules



Address for Correspondence / Yazışma Adresi: Murat Türk, Gazi Üniversitesi Tıp Fakültesi, Göğüs Hastalıkları Anabilim Dalı, Ankara, Türkiye Phone/Tel: +90 312 202 61 19 E-mail/E-posta: mrtrk@gmail.com

©Telif Hakkı 2015 Türk Toraks Derneği - Makale metnine www.toraks.dergisi.org web sayfasından ulaşılabilir.

©Copyright 2015 by Turkish Thoracic Society - Available online at www.toraks.dergisi.org

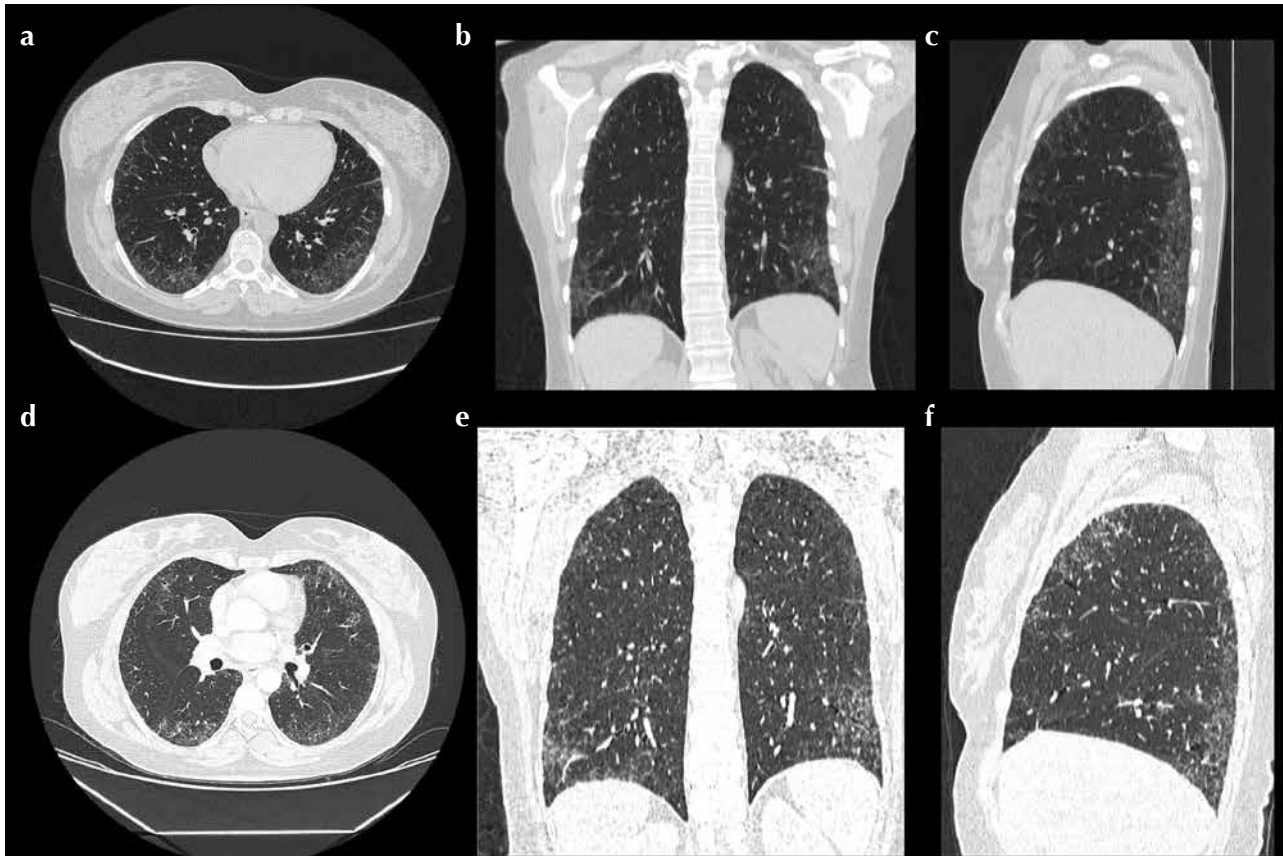


Figure 1. a-f. HRCT images of 2-year follow-up period (a, b, c in December 2011; d, e, f in October 2013). Intralobular interstitial and interlobular septal thickening with lower lobe predominance is seen.

HRCT: high-resolution computed tomography

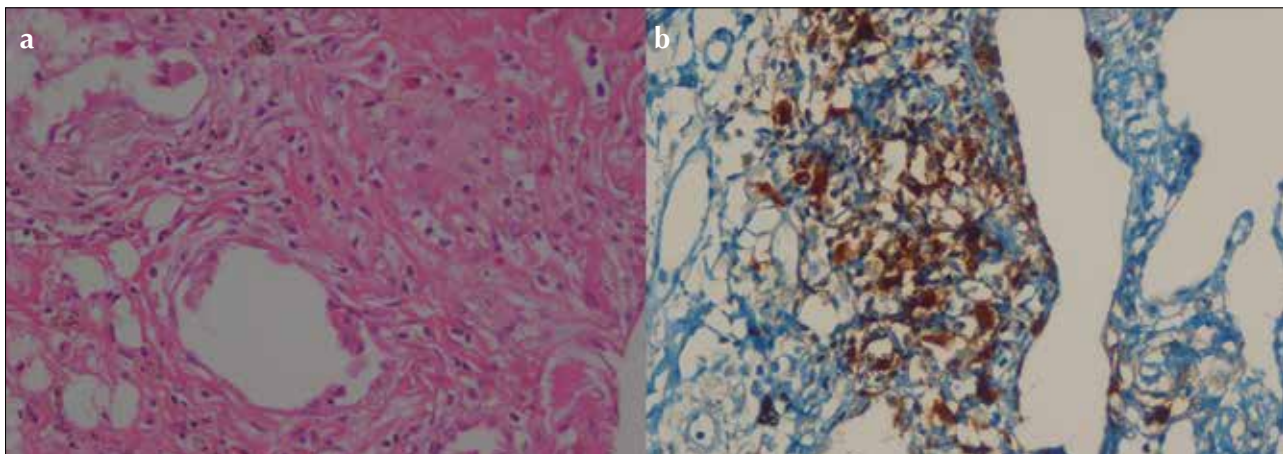


Figure 2. a, b. High power of Langerhans cells with characteristic nuclear folding and indistinct cell margins (hematoxylin and eosin, $\times 400$) (a). S-100 immunopositivity in Langerhans cells in PLCH (S-100, $\times 400$) (b)

were seen with airspace enlargement at the periphery. These nodules consisted of a variable mix of Langerhans cells, lymphocytes, eosinophils, and plasma cells, with a background of generally mild fibrosis. Immunohistochemically, CD1a, langerin, and S-100 were positive in numerous Langerhans cells, singly and in clusters (Figure 2). A diagnosis of pulmonary Langerhans cell histiocytosis was established.

The Tc-99m hydroxyl-ethylene-diphosphonate (HDP) bone scan was normal. The patient was informed about the cigarette-related course of the disease. During the outpatient follow-up period, a minimal increase was observed in forced

expiratory volume-1 and forced vital capacity (Table 1). She was stable in her daily life activities and began to be followed in the outpatient clinic.

DISCUSSION

Pulmonary Langerhans cell histiocytosis (PLCH) is a rare interstitial lung disease characterized by the accumulation of histiocytes within the airspaces or the parenchyma of the lung. It almost always occurs in smokers between the ages of 20 and 40 [1]. Dyspnea and nonproductive cough are the most common symptoms at diagnosis, but about one-third of patients are asymptomatic [2]. The most common pulmonary

Table 1. Respiratory function test results during the follow-up period

	12.2011	01.2012	02.2012	09.2012	09.2013
FEV ₁ % (cc)	86 (2270)	97 (2520)	94 (2440)	101 (2630)	99 (2390)
FVC % (cc)	90 (2770)	98 (2970)	95 (2900)	105 (3200)	101 (2870)
FEV ₁ /FVC %	82	85	84	82	83
TLC %	92	-	104	88	83
RV %	90	-	96	66	69
DLCO %	53	54	52	59	56
DLCO/VA %	69	64	64	71	76

FEV₁: forced expiratory volume; FVC: forced vital capacity; TLC: total lung capacity; RV: residual volume; DLCO: diffusion capacity; VA: alveolar volume

function test abnormality is reduced diffusion capacity for carbon monoxide (DLCO), and it is generally the first detectable functional alteration. Restrictive, obstructive, or mixed patterns may also be seen as the disease progresses [3]. Bronchoscopic interventions, such as TBB and BAL, should be performed before other more invasive procedures, but their diagnostic yield is lower. TBB is frequently non-diagnostic due to inadequate sampling. Of 29 histologically proven patients, only 6 (21%) were detected with TBB in a study [4]. Immunohistochemical staining with CD1a increases the diagnostic accuracy. BAL cellular analysis may show alveolar macrophage predominance, and the detection of >5% CD1a-positive cells in BAL fluid is highly suggestive and specific for the disease; however, this increase is not observed frequently [5]. Surgical lung biopsy is the most definite modality for the diagnosis.

Chest X-ray is almost always abnormal and suggestive of disease with upper lobe predominance of nodules or reticular lines. The CT scan shows multiple thick-walled cysts of varying size and cavitating or non-cavitating dense, centrilobular nodules distributed in upper and mid-lung fields. The costophrenic angles are almost exclusively preserved [1,6].

This is an interesting case because of the unusual and unexpected radiological presentation. Adult-type PLCH represents itself with nodules, cysts, or both in the upper and mid-lung fields, depending on the stage of disease [1,7]. In a study, multiple thin-walled cysts were seen in all 10 cases, and in 7 of the cases, both nodules and cysts were seen [7]. In another study with 29 PLCH cases, nodules were seen in 20, cysts were seen in 11, both nodules and cysts were seen in 4, ground-glass appearance was seen in 1, and both ground-glass and nodules were seen in 3 cases [4]. In the adult population, costophrenic angles and lower lobes are expected to be spared, except for end-stage disease with honeycomb and fibrosis formation. However in pediatric population, costophrenic angles and lower lobes generally demonstrate pathology. The CT findings are similar in adult and pediatric PLCH populations, except that the subpleural parenchyma in the costophrenic recess is spared in entire adult group but not in any of the pediatric patients [7].

Here, we presented a case of PLCH with an atypical radiological presentation. PLCH must be in differentials list in this regard. Although a biopsy may not be necessary for a clinically stable smoker with typical radiological manifestations, it is required for the definitive diagnosis in atypical presentations, as in this case.

Informed Consent: Written informed consent was obtained from patient who participated in this case.

Peer-review: Externally peer-reviewed.

Author Contributions: Concept - M.T., H.T., N.A.; Design - M.T., H.T., N.A.; Supervision - M.T., H.T., N.A.; Funding - M.T., H.T., N.A.; Materials - M.T., H.T., N.A.; Data Collection and/or Processing - M.T., H.T., N.A.; Analysis and/or Interpretation - M.T., H.T., N.A.; Literature Review - M.T., H.T., N.A.; Writer - M.T., H.T., N.A.; Critical Review - M.T., H.T., N.A.

Conflict of Interest: No conflict of interest was declared by the authors.

Financial Disclosure: The authors declared that this study has received no financial support.

Hasta Onamı: Yazılı hasta onamı bu olguya katılan hastadan alınmıştır.

Hakem değerlendirmesi: Dış bağımsız.

Yazar Katkıları: Fikir - M.T., H.T., N.A.; Tasarım - M.T., H.T., N.A.; Denetleme - M.T., H.T., N.A.; Kaynaklar - M.T., H.T., N.A.; Malzemeler - M.T., H.T., N.A.; Veri toplanması ve/veya işleme - M.T., H.T., N.A.; Analiz ve/veya yorum - M.T., H.T., N.A.; Literatür taraması - M.T., H.T., N.A.; Yazıyı yazan - M.T., H.T., N.A.; Eleştirel inceleme - M.T., H.T., N.A.

Çıkar Çatışması: Yazarlar çıkar çatışması bildirmemişlerdir.

Finansal Destek: Yazarlar bu çalışma için finansal destek almadıklarını beyan etmişlerdir.

REFERENCES

1. Suri HS, Yi ES, Nowakowski GS, Vassallo R. Pulmonary langerhans cell histiocytosis. *Orphanet J Rare Dis* 2012;7:16. [\[CrossRef\]](#)
2. Vassallo R, Ryu JH, Schroeder DR, et al. Clinical outcomes of pulmonary Langerhans' cell histiocytosis in adults. *N Engl J Med* 2002;346:484-90. [\[CrossRef\]](#)
3. Juvet SC, Hwang D, Downey GP. Rare lung diseases III: Pulmonary Langerhans' cell histiocytosis. *Can Respir J* 2010;17:55-62.
4. Tazi A. Adult pulmonary Langerhans' cell histiocytosis. *Eur Respir J* 2006;27:1272-85. [\[CrossRef\]](#)
5. Kulwicz EL, Lynch DA, Aguayo SM, et al. Imaging of pulmonary histiocytosis X. *Radiographics* 1992;12:515-26. [\[CrossRef\]](#)
6. Bonelli FS, Hartman TE, Swensen SJ, Sherrick A. Accuracy of high-resolution CT in diagnosing lung diseases. *AJR Am J Roentgenol* 1998;170:1507-12. [\[CrossRef\]](#)
7. Seely JM, Salahudeen S Sr, Cadaval-Goncalves AT, et al. Pulmonary Langerhans cell histiocytosis: a comparative study of computed tomography in children and adults. *J Thorac Imaging* 2012;27:65-70. [\[CrossRef\]](#)