

Peripheral Neuroectodermal Tumour (PNET) of the Chest Wall Along with Massive Pleural Effusion in a Young Adult Male

Genç Erişkin Bir Erkekte Masif Plevral Effüzyonla Birlikte Göğüs Duvarının Periferik Nöroektodermal Tümörü (PNET)

Ruchi Sachdeva¹, Sandeep Sachdeva², Sakshi Arora³, Rinki Redhu¹, Gaurav Gupta¹

¹Clinic of Chest and Respiratory Medicine and Pathology, Post Graduate Institute of Medical Sciences, Rohtak, India

²Clinic of Community Medicine, Post Graduate Institute of Medical Sciences, Rohtak, India

³Clinic of Anaesthesia, Lady Harding Medical College, Delhi, India

Abstract

Özet

A 25-year-old man presented with painful right lateral chest wall swelling of two months duration. Computed tomography showed moderate pleural effusion with extension into the lateral chest wall. Aspiration revealed frankly hemorrhagic fluid that was exudative in nature. Fine needle aspiration cytology (FNAC) and cell block preparation of the chest wall swelling revealed a malignant round cell tumour. Immunohistochemical assays, together with the clinical and radiologic findings led to the definitive diagnosis of a peripheral neuroectodermal tumour (PNET).

KEY WORDS: Askin tumour, PNET, Ewing sarcoma, pleural effusion, FNAC, cell block

Yirmi beş yaşındaki bir erkek hasta, iki aydır devam eden ağrılı sağ lateral göğüs duvarı şişmesiyle başvurdu. Bilgisayarlı tomografi, lateral göğüs duvarına uzanan orta dereceli plevral effüzyon gösterdi. Aspirasyon, eksüdatif özellikte, bariz hemorajik sıvı ortaya çıkardı. İnce iğne aspirasyon sitolojisi (İİAS) ve göğüs duvarı şişkinliğinin hücre bloku preparasyonu malign yuvarlak hücreli tümörü ortaya çıkardı. Klinik ve radyolojik bulgular ile birlikte immünohistokimyasal testler, periferik nöroektodermal tümör (PNET) kesin tanısına yol açtı.

ANAHTAR SÖZCÜKLER: Askin tümörü, PNET, Ewing sarkomu, plevral effüzyon, İİAS, hücre bloku

Received/Geliş Tarihi: 19.10.2012

Accepted/Kabul Tarihi: 17.01.2013

Available Online Date/Çevrimiçi Yayın Tarihi: 17.04.2013

INTRODUCTION

Ewing sarcoma (ES) is a highly malignant bone tumour composed of uniform round cells. It was first described by James Ewing in 1921 as a malignant tumour of the shaft of the long bones in children and young adults [1]. Later, malignant soft tissue tumours morphologically indistinguishable from ES were reported and termed extra-skeletal ES. Recently, a single entity, termed 'the ES family of tumours' was proposed that has gradually gained acceptance. This includes ES, extra-skeletal ES and finally peripheral neuroectodermal tumour (PNET) that display greater neural differentiation than ES [2]. PNETs are rare group of tumours that carry an identical chromosomal translocation (11;22) (q24; q12) to that seen in ES. Askin originally described PNETs of the chest wall (so called Askin tumours) in 1978, that are peripheral primitive neuroectodermal tumours associated with the chest wall, ribs and thoracic cavity [3]. Patients may have pulmonary involvement, but usually in association with a chest wall mass. PNETs are exceedingly rare in adults [4]. Here we report a PNET in a young adult with rapid progression.

CASE REPORT

A 25-year-old man was admitted with a two-month history of right chest wall swelling, chest pain, exertional breathlessness and dry cough (Figure 1). Chest pain was associated with progressive dyspnea on exertion. Pain was gradual in onset, sharp, continuous and non-radiating. A hot, tender and firm swelling measuring 15x10 cm in size located in the lateral chest wall was found that extended from posterior to mid-axillary line. Chest examination revealed decreased chest expansion on the right side and a dull note on percussion with decreased breath sounds. Vocal fremitus and resonance were also found to be decreased on same side only. The rest of the physical and systemic examination, including vitals, was unrevealing. Blood work revealed a haemoglobin concentration of 12 g/dL, a total leukocyte count of 10.000/mm³, and an erythrocyte sedimentation rate of 56 mm/h. Kidney and liver function tests were within normal limits. Chest radiography showed a massive effusion on right side (Figure 2). Ultrasound revealed a large heteroechoic lesion in the deep muscle plane of right lateral chest wall that seemed to communicate with the pleural cavity through the intercostal spaces, along with right massive pleural effusion. Computed tomography showed massive effusion on the right side with extension into the lateral chest wall opposite to the 6th-8th ribs, but without rib destruction (Figure 3). The pleural fluid contained 4.5 g/dL of protein, and was characterised by a lymphocyte predominance in a haemorrhagic background.



Address for Correspondence / Yazışma Adresi: Ruchi Sachdeva, Clinic of Chest and Respiratory Medicine and Pathology, Post Graduate Institute of Medical Sciences, Rohtak, India Phone: 26122888 E-mail: drsachdeva@hotmail.com

©Telif Hakkı 2013 Türk Toraks Derneği - Makale metnine www.toraks.dergisi.org web sayfasından ulaşılabilir.

©Copyright 2013 by Turkish Thoracic Society - Available online at www.toraks.dergisi.org

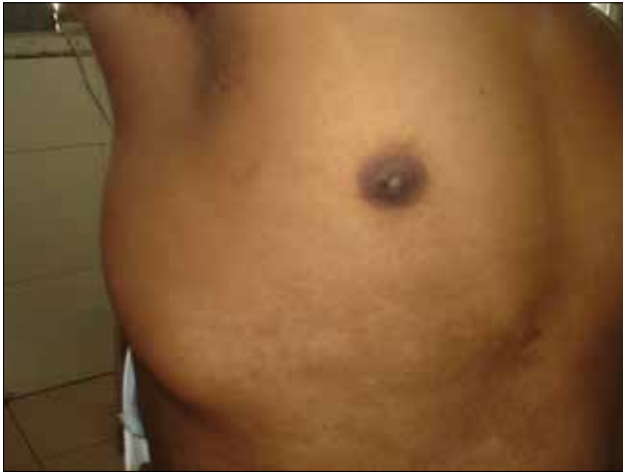

Figure 1. Young male with right chest wall swelling

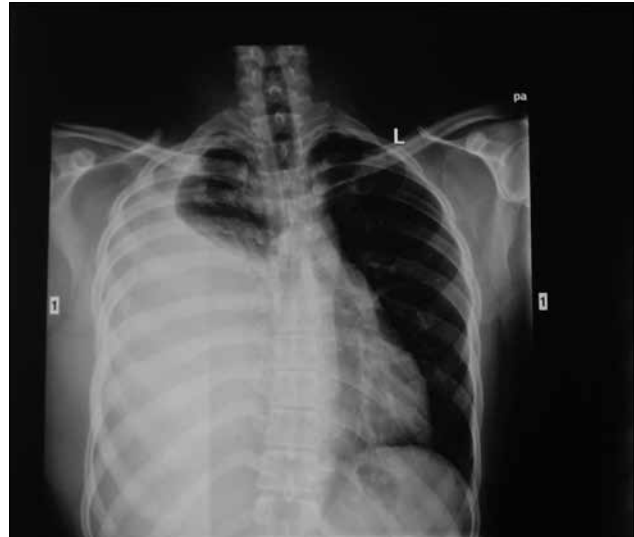

Figure 2. Chest X-ray showing massive right sided pleural effusion

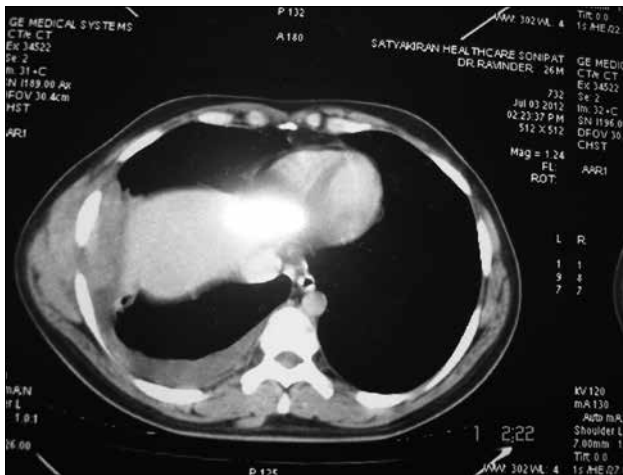


Figure 3. CECT Thorax showing right sided pleural effusion along with chest wall swelling communicating with pleural cavity

Fine needle aspiration cytology (FNAC) of the chest wall swelling suggested a round cell neoplastic lesion, however a lymphoid neoplastic lesion needed to be ruled out. A cell block was prepared that revealed groups of small round cells, consistent with the morphology of a PNET. Immunohistochemistry of the sample revealed focal positivity for cluster of differentiation-99 (CD99) and vimentin, whereas S-100, leukocyte common antigen, and myogenin were negative (Figure 4). The patient was successfully put on radio/chemotherapy.

DISCUSSION

Peripheral neuro-ectodermal tumor is a rare undifferentiated sarcoma believed to have its origin in embryonic migrating cells from the neural crest. Traditionally, distinctions were made between classic ES and PNET, but it is now accepted that these represent a spectrum of a single neoplastic entity. Overall, 27% of cases occur in first decade, 64% in the second decade and 9% in the third decade of life, while cases occurring later in life are infrequent [5]. The incidence in males is quite similar to females (1.1:1). Kushner et al. [6] reported on 54 patients with this disease in 1990. In their series, the disease arose from the chest wall (33.3%), pelvis (22.2%), paraspinal region (13.0%), retroperitoneum (11.1%), limbs (9.3%), abdomen (7.4%), neck (1.9%) or an unknown site (1.9%). Similar findings were later reported by Kennedy

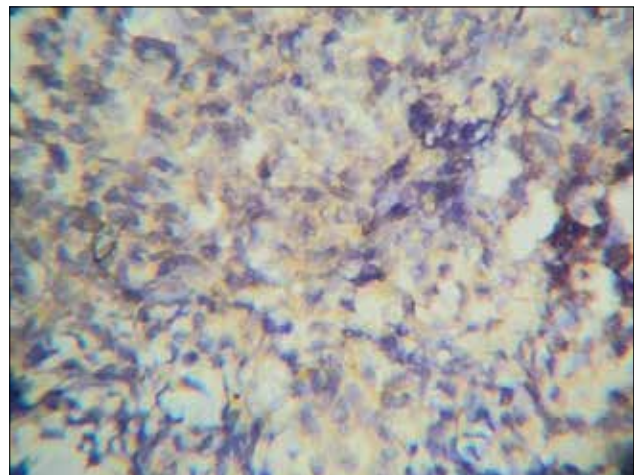


Figure 4. Round cell tumour positive for CD99

et al. [7]. At presentation, less than 25% of patients have pulmonary involvement either alone or in combination with a chest wall mass. Homer-Wright pseudorosettes are a characteristic histologic finding in PNETs. Classically, PNET has been described as a highly aggressive neoplasm. Long-term survival has been achieved with both aggressive local and adjuvant therapy in the form of multidrug chemotherapy. An overall 5-year survival rate of 60% was reported in patients with localised tumours [8].

Peripheral neuro-ectodermal tumor lesions are typically painful, in keeping with the capacity of thoracic tumours to invade the chest wall, lung or mediastinum. They are generally soft and fleshy with areas of haemorrhage and necrosis. The patient described herein presented in the third decade of life with massive haemorrhagic effusion and unresectable disease that showed the typical histological and histochemical features of PNET. The diagnosis of PNET has been greatly facilitated by the availability of antibodies such as HBA-71 MIC2 (12E7) antigen and O-13 that recognise the cell surface antigen defined by CD99 [9]. Although not specific for PNET or ES, CD99 is almost always present in these tumours. Other differentials of round cell tumour are non-Hodgkin's lymphoma, synovial sarcoma, neuroectodermal tumour, lym-

phoblastic lymphoma, rhabdomyosarcoma, neuroblastoma, and malignant melanoma. However, these can be differentiated by immunohistochemistry.

Immunohistochemical differential diagnosis of lung tumours is complicated, since CD99 can be found in small cell carcinomas and carcinoid tumours that are almost always positive for cytokeratin. The present case was CD99-positive and cytokeratin-negative which is highly suggestive of PNET. Thus, a simple investigation involving FNAC along with cell block preparation and immunohistochemistry can greatly facilitate the diagnosis. However, communication, effort and motivation are required by healthcare teams to undertake these procedures that should be a more routine affair, especially in developing countries. PNETs are aggressive and usually lethal, and must be considered in the differential diagnosis of thoracic tumours regardless of the age of the patient. Once a diagnosis of PNET has been made, it is important to have a careful staging and work-up, followed by early and wide excision of the tumour along with multimodality chemotherapy and/or radiotherapy to provide the greatest chance of a long-term cure.

Conflict of Interest

No conflict of interest was declared by the authors.

Peer-review: Externally peer-reviewed.

Author Contributions

Conception - R.S., S.S.; Design - R.S., S.S.; Supervision - R.S.; Materials - R.S.; Data Collection and/or Processing - R.S., R.R., G.G.; Analysis and/or Interpretation - R.S., R.R.; Literature Review - R.S., S.S., S.A.; Writer - R.S., S.S.; Critical Review - S.A.

Çıkar Çatışması

Yazarlar herhangi bir çıkar çatışması bildirmemişlerdir.

Hakem değerlendirmesi: Dış bağımsız.

Yazar Katkıları

Fikir - R.S., S.S.; Tasarım - R.S., S.S.; Denetleme - R.S.; Malzemeler - R.S.; Veri toplanması ve/veya işlemesi - R.S., R.R., G.G.; Analiz ve/veya yorum - R.S., R.R.; Literatür taraması - R.S., S.S., S.A.; Yazı yazar - R.S., S.S.; Eleştirel inceleme - S.A.

REFERENCES

1. Ewing J. Diffuse endothelioma of bone. Proc NY Pathol Soc 1921;21:17.
2. Isefuku S, Seki M, Tajino T, et al. Ewing's sarcoma in the spinal nerve root: a case report and review of literature. Tohoku J Exp Med 2006;209:369-77. [\[CrossRef\]](#)
3. Askin FB, Rasai J, Sibly RK. Malignant small cell tumor of the thoraco-pulmonary region in childhood. A distinctive clinicopathological entity of uncertain histogenesis. Cancer 1979;43:2438-51. [\[CrossRef\]](#)
4. Cabezali R, Lozano R, Butamnte E. Askin's tumor of the chest wall, a case report in an adult. J Tharac Cardiovas Surg 1994;107:960-2.
5. Etienne MB, Falchero L, Chalabreysse L. Primary sarcomas of lung: a clinicopathologic study of 12 cases. Lung Cancer 2002;38:283-9. [\[CrossRef\]](#)
6. Kusher BH, Hjadu ST, Gulati SC. Extracardinal primitive neuroectodermal tumors. The memorial Sloan Kettering Cancer centre experience. Cancer 1991;67:1825-79. [\[CrossRef\]](#)
7. Kennedy JG, Eustace S, Caufield R. Extraskelatal ewings sarcoma: a case report and review of literature. Spine 2000;25:1996-9. [\[CrossRef\]](#)
8. Nesbit ME Jr, Gehan EA, Burgert EO Jr, et al. Multimodal therapy for the management of primary, nonmetastatic Ewing's sarcoma of bone: a long-term follow-up of the First Intergroup study. J Clin Oncol 1990;8:1664-74.
9. Okamoto S, Hisaoka M, Daa T, Hatakeyamm K. Primary pulmonary synovial sarcoma: a clinicopathological, immunohistochemical and molecular study of 11 cases. Hum Pathol 2004;35:850-6. [\[CrossRef\]](#)