

Massive Hemoptysis due to Mild and Focal Contusion on an Emphysematous Lung

Amfizematöz Akciğer Zemininde Hafif ve Fokal Kontüzyona Bağlı Oluşan Masif Hemoptizi

Hasan Türüt

Kahramanmaraş Sutcu Imam University Medical School, Department of Thoracic Surgery, Kahramanmaraş, Turkey

ABSTRACT

We hereby present the case of a young man who had only a focal lung contusion following a low-moderate chest trauma due to a common ball-crash while playing football but presented acutely with massive hemoptysis. He had been followed-up and treated with the diagnosis of emphysema since childhood. Our case illustrates that even a low-moderate blunt trauma-related mild lung contusion may lead to massive hemoptysis. (*Tur Toraks Der 2011; 12: 44-6*)

Key words: Lung contusion, hemoptysis, blunt chest trauma, emphysema

Received: 18.03.2008

Accepted: 17.07.2008

ÖZET

Bu yazıda, futbol oynadığı sırada olağan bir top çarpması ile oluşan hafif-orta şiddeteki bir toraks travmasını takiben gelişen fokal akciğer kontüzyonu ve buna bağlı akut masif hemoptizi tablosu ile kliniğimize başvuran olgu sunuldu. Hasta çocukluk döneminden beri amfizem tanısı ile takip altında idi. Sunulan bu olgu, düşük-orta şiddetli bir toraks travmasına bağlı hafif akciğer kontüzyonunda bile masif hemoptizinin ortaya çıkabileceğini örneklemetedir. (*Tur Toraks Der 2011; 12: 44-6*)

Anahtar sözcükler: Akciğer kontüzyonu, hemoptizi, künt toraks travması, amfizem

Geliş Tarihi: 18.03.2008

Kabul Tarihi: 17.07.2008

INTRODUCTION

Understanding and identifying emergent conditions while treating the patient with blunt chest trauma is a critical skill of the advanced practice nurse [1]. Usually, pulmonary contusion (PC) induced by high-energy-related blunt chest trauma rarely requires intervention, so it is possible that low-impact trauma related PC is generally not important and may be underestimated [2]. In a review of the literature, few cases of pulmonary contusion resulting from non-severe blunt injuries are described [3,4]. On the other hand, massive hemoptysis due to localised and mild lung contusion caused by a low-moderate chest trauma on an emphysematous lung is an extremely rare condition and has not been previously described.

In this paper, we present a unique experience with a patient who had only a focal lung contusion following a low-moderate chest trauma due to a common ball-crash while playing football but presented acutely with massive hemoptysis.

CASE

A 32-year-old man presented to our emergency department with severe hemoptysis which occurred just after a ball-crash to the left anterior chest wall while playing football. Just prior to admission he had had approxi-

mately 400 cc hemoptysis induced by a low-moderate blunt chest injury. His medical history revealed that he had been in follow-up and on medical treatment for emphysematous pulmonary (panaciner emphysema) disease since childhood. He used to be a smoker with 17 package/year but had been a non-smoker for 4 years. The etiology regarding his panaciner emphysematous disease was undetermined. He had been hospitalised and received medical treatment many times before. On physical examination, he appeared healthy, in no acute distress and normal breathing. Vital signs included a blood pressure of 117/62 mm Hg, heart rate 84 beats/min. and respiration at 19 breaths/min. Breath sounds were diminished bilaterally and crepitan rales were present over the left anterior areas of the chest. No echymosis or crepitation was detected in the region of the trauma. No associated injury was observed. The hemoglobin value was 12,6 g/dL, white blood cell count was 14,000 cells/mL and platelet count was 340,000 cells/mL. Results of his coagulation profile and other laboratory survey studies were normal. With the patient breathing 2 L of oxygen by nasal cannula, the saturation level was 98%. Admission chest radiograph demonstrated pulmonary emphysema and left hilar infiltration, but no evidence of any fractured ribs, hemo/pneumothorax or any other pulmonary pathology (Figure 1). Chest com-

Presented In: 11 Annual Congress April 23-27 2008 Antalya

Address for Correspondence / Yazışma Adresi: Hasan Türüt, Rize Üniversitesi Tıp Fakültesi, Eğitim ve Araştırma Hastanesi, Göğüs Cerrahisi Kliniği, İslampaşa Mah., 53100 Rize, Turkey Phone: +90 464 213 04 91 Fax: -90 464 212 30 15 E-mail: drhasanturut@yahoo.com

doi:10.5152/ttd.2011.10

puted tomography scans revealed a panacinar emphysematous pattern predominantly in the lower lung fields associated with a ground glass opacity and alveolar hemorrhage in the left upper lobe consistent with contusion (Figure 2a-d). After the initial evaluation the conservative approach including cardiopulmonary and hemodynamic monitoring, pulmonary physiotherapy associated with medical treatment (analgesics, bronchodilators, aprotinin, N-acetylcysteine) was carried out. Shortly after, during follow-up the patient expectorated a total of 200 mL of blood over a 4 hour period. Fiberoptic bronchoscopy revealed a blood clot extending from the left upper lobe to the left main bronchus and trachea with no evidence of an active focus of bleeding. Serial bronchial washing with cold saline was performed. During the days following, his condition was improved and hemoptysis was diminished, amounting to 10-20 cc/

day. At the end of the 10-day-follow-up, hemoptysis completely disappeared and hilar infiltration improved on control chest x-ray. He was discharged and returned for control.

DISCUSSION

The clinical presentation of patients with PC varies widely and ranges from minor discomfort to life-threatening conditions. Severe contusion generally requires large forces often seen in motor vehicle accidents or falls from height, and subsequently results in pulmonary bleeding with microscopic disruption of alveoli. Intra-alveolar hemorrhage can progress to acute respiratory distress which can increase mortality due to severe hypoxia. Moreover, significant hemoptysis may be associated and ameliorate the course [1,3]. Given the fact that the presence of serious hemoptysis in PC can potentially compromise the clinical picture, in our case massive hemoptysis produced the chance of early hospitalisation of the patient.

Meese and Sebastianelli [3] reported a similar scenario which occurred while playing football and was associated with non-serious hemoptysis. However, as in our case, massive hemoptysis due to such low-moderate chest trauma related lung contusion has not been described so far. Moreover, as a quite rare coincidence, our patient had panacinar emphysema whose association we suspect might contribute and aggravate this innocent course, although contusion occurred on the upper lobe of the patient, where the ball crashed. Compared to emphysema due to cigarette smoking, panacinar emphysema may result in very dilated and damaged alveolar spaces and dilated bronchi. Hemoptysis therefore can be encountered in some patients with panacinar emphysema [5]. Our suspicion may be supported by the fact that hemoptysis in otherwise healthy subjects is a quite rare event in such cases [6].

The diagnosis of pulmonary injury due to chest trauma sometimes may be overlooked at first presentation due to the impression that the trauma is insignificant. Besides, a reasonable delay in respiratory symptoms may contribute to a misleading diagnosis [4]. There are known complications of PC that the patient and the physician must be aware of. These include pneumonia and acute respiratory distress syndrome, which will worsen the patient's clinical picture and may actually progress to death in severe cases [3]. Thus, early diagnosis and prompt management plays a vital role. In a similar paper described by Norrashidah et al. [4], blunt injury which did not produce any evidence of external body injury was reported to cause a delayed significant hemoptysis. In contrast, the onset of hemoptysis in our case had an acute character, the severity of the trauma was moderate and our patient was not otherwise healthy as he had an underlying pulmonary disease.

It is widely known that any patient who experienced a severe blunt chest injury should be evaluated for a serious

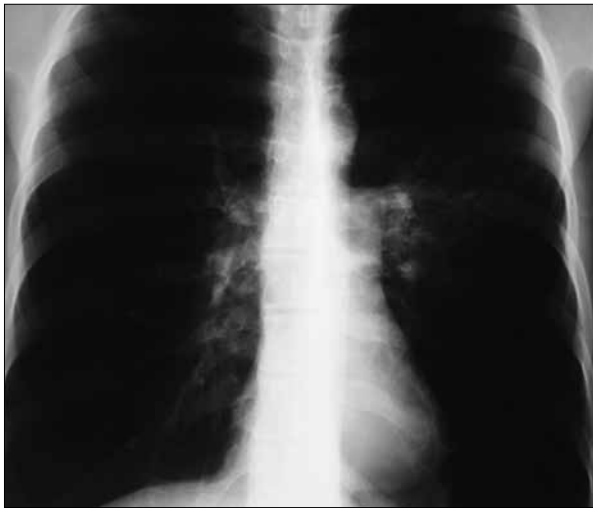

Figure 1. Postero-anterior chest x-ray showing both lungs to be markedly hyperlucent associated with low position of the diaphragm and decrease of the heart width. Notice the poorly defined infiltrate in the left hilus consistent with contusion

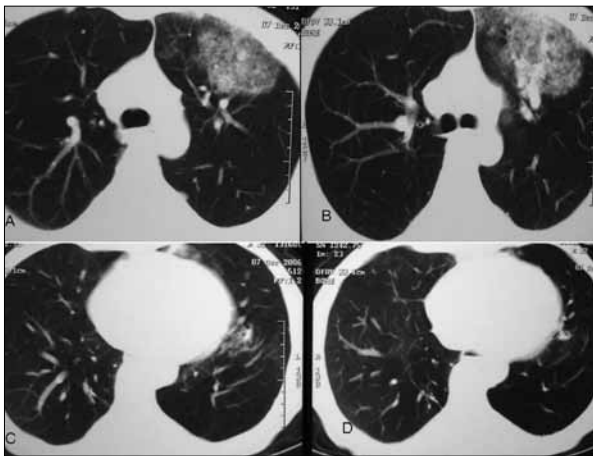


Figure 2. Thorax computed tomography scans revealing relatively oval lucency just adjacent to the area of the "ball crash". Ground glass opacity with air bronchograms and intraalveolar hemorrhage are consistent with contusion (a,b). Moderate panacinar emphysema pattern affecting predominantly the lower lobes (c,d)

pulmonary contusion, and several complications may develop. However, one should be aware of serious clinical pictures such as hemoptysis even in the presence of a low-moderate chest injury caused by a common ball crash.

REFERENCES

1. Keough V, Pudelek B. Blunt chest trauma: review of selected pulmonary injuries focusing on pulmonary contusion. *AACN Clin Issues* 2001; 12: 270-81. [\[CrossRef\]](#)
2. Hafen GM, Massie J. Lung contusion from focal low-moderate chest trauma. *Pediatr Pulmonol* 2006; 41: 1005-7. [\[CrossRef\]](#)
3. Meese MA, Sebastianelli WJ. Pulmonary contusion secondary to blunt trauma in a collegiate football player. *Clin J Sport Med* 1997; 7: 309-10. [\[CrossRef\]](#)
4. Norrashidah AW, Henry RL, Hartman S. Hemoptysis following blunt trauma: case report. *Pediatr Pulmonol* 2002; 34: 395-7. [\[CrossRef\]](#)
5. Tsushima K, Koyama S, Takematsu H et al. Massive pulmonary hemorrhage due to cytomegalovirus infection in Japanese patient with alpha-1-antitrypsin-deficient emphysema. *Respiration* 1999; 66: 373-6. [\[CrossRef\]](#)
6. Fabian MC, Smitheringale A. Hemoptysis in children: the hospital for sick children experience. *J Otolaryngol* 1996; 25: 44-5.