

The Evolution of Radiological Lesions due to Septic Pulmonary Embolism

Septik Pulmoner Emboliye Bağlı Radyolojik Bulguların Evrimi

Ender Levent, Nesrin Sarıman, Akın Cem Soylu

Department of Chest Diseases, School of Medicine, Maltepe University, İstanbul, Turkey

ABSTRACT

A 22 year-old female patient presented with septic pulmonary embolism (SPE) due to infective arthritis with demonstrative thorax CT images that provided early diagnosis and showed the evolution of radiological lesions. Thoracic CT revealed multiple nodular lesions and areas of consolidation with various sizes on both lung fields. Some of them were cavitating and some were pleurally based. Methicillin sensitive *Staphylococcus aureus* was obtained on culture as the etiologic agent. Clinical improvement was observed on the 6th day of treatment and the radiological improvement was achieved within a 2 month period.

(*Tur Toraks Der 2011; 12: 39-43*)

Key words: Septic pulmonary embolism, arthritis, radiological findings, computed tomography, methicillin sensitive staphylococcus aureus

Received: 13.01.2008

Accepted: 01.06.2008

ÖZET

İnfektif artrite bağlı septik pulmoner emboli gelişen 22 yaşındaki kadın hasta, erken tanı sağlayan demonstratif bilgisayarlı toraks tomografisi bulguları ve bu lezyonların zaman içindeki evrimini gösteren bilgisayarlı toraks tomografisi görüntüleri nedeniyle sunuldu. Bilgisayarlı toraks tomografisinde; her iki akciğerde, bir kısmı plevral tabanlı, bazıları kaviteleşme gösteren, çeşitli boyutlarda çoklu nodüler lezyonlar ve konsolidasyon alanları izlendi. Kültürlerde metisiline duyarlı *Staphylococcus aureus* etken patojen olarak saptandı. Tedavinin 6. gününde klinik düzelme gözlemlendi ve radyolojik bulguların düzelmesi 2 ay sürdü. (*Tur Toraks Der 2011; 12: 39-43*)

Anahtar sözcükler: Septik pulmoner emboli, artrit, radyolojik bulgular, bilgisayarlı tomografi, metisiline duyarlı staphylococcus aureus

Geliş Tarihi: 13.01.2008

Kabul Tarihi: 01.06.2008

INTRODUCTION

Various infectious etiologies may cause septic pulmonary emboli (SPE); among them the cardiovascular system is the main source [1]. Coagulated blood that leads to infarcts in the pulmonary vascular bed also contains microorganisms that initiate focal abscess formation [2]. Early detection of SPE and prompt administration of broad spectrum antibiotics is an important prognostic factor [3]. For this reason findings of computed tomography (CT) of the chest are of great importance [1,3,4]. In many of the articles, thorax CT findings have been well described, but the evolution of the lesions during the disease process have not been documented in detail.

To our knowledge "a case report of SPE originating from an infectious arthritis" is very rare in the literature. We present a patient with SPE and septic arthritis since it is rarely seen and had demonstrative thorax CT findings during the follow up period.

CASE

A 22 year-old female with high fever, chills, fatigue and pain in the 4th metacarpophalangeal joint of the

right hand for 5 days applied to our emergency unit upon developing sudden onset pain, dyspnea and high fever (41°C). She was not a current smoker nor intravenous drug abuser. Her physical examination were as follows; heart rate, 156 beats/min; arterial blood pressure, 130/70 mm Hg and oxygen saturation, 88% on room air. She had infective arthritis and the 4th metacarpophalangeal joint of the right hand was swollen, erythematous, and tender. Thorax auscultation revealed bilateral scattered crackles, coarse rhonchi, friction rub on the right lower lung fields and normal heart sounds. Test results included Leucocyte count, 48480/mm³; CRP, 33.8 mg/dL; ESR, 116mm/hour; ASO, 92.5 IU/ml; BUN, 19 mg/dL and creatinine, 1.1 mg/dL. She had proteinuria (75 mg/dL) and glucosuria (50 mg/dL). Urinary sediment showed erythrocytes and leucocyturia.

On chest X-ray costophrenic sinuses were bilaterally blunted, heterogenous infiltrations with multiple irregular nodular patterns were present in the lower lung fields peripherally and on both sides (Figure 1-A). Thorax CT was taken under emergency conditions (Figures 1-a₁₋₄, Figures 2-a₅₋₉) and revealed consolidations and multiple

nodular lesions with various sizes (0.5-4cm) some were pleurally based and some were cavitating, randomly dispersed on both lung fields. In the lateral basal segment of the right lung lower lobe there was a wide pleural based consolidation area. We observed minimal pleural effusion in the left hemithorax. There was no intravascular filling defect or thrombus.

Intravenous antibiotic therapy (Levofloxacin 2x500 mg daily) and subcutaneous Enoxaparin sodium (2x6000 IU/0.6 ml daily) were started empirically, depending upon the clinical and radiological findings with the diagnosis of SPE. Transthoracic echocardiography showed no evidence of endocarditis. In spite of using antipyretic drugs (paracetamol and dipyrene) and cool compress application her fever continued as (41°C) and for that reason intravenous prednisolone (60mg/day) was added and given for a period of three days. Orthopedic consultation confirmed the diagnosis of the lesion in the 4th metacarpophalangeal joint of the right hand as infective arthritis due to trauma. Some serological tests regarding connective tissue diseases were used for differential diagnosis. Laboratory tests results for an underlying probable connective tissue disease were all negative. Test results including RF were in the normal range, c-ANCA: negative, Anti-HIV: negative, Anti-HCV: negative and HBsAg: negative. Both blood culture and needle aspiration culture of the lesion of the hand revealed growth of methicillin sensitive *Staphylococcus aureus* (MSSA) as the etiological agent. Clinical improvement was observed on the 6th day of treatment.

On the 8th day of treatment, repeat laboratory findings were as follows; (Leucocyte count: 36290/mm³, CRP: 6.04 mg/dL, ESR: 117mm/hour). On her chest x-ray (Figure 1-B); two cavitory lesions on the right lung middle zone and irregular nodular lesions laterally located on the left lung middle and lower zones were observed. Costophrenic sinuses were bilaterally blunted and the density of the lesions were decreased. Thorax CT obtained simultaneously (Figures 1-b₁₋₄, Figures 2-b₅₋₉); revealed cavitation in the nodules at various degrees (0.5-3.5 cm). Nodular lesions were increased in number when compared to the first thorax-CT. Cavitory lesions were more obvious and wedge shaped pleural based consolidations were present. The level of pleural effusion in the left lung was increased. The thorax CT demonstrated a more extensive disease than the chest x-ray.

On day 22; Leucocyte count was: 11270/mm³, CRP: 1.4 mg/dL, ESR:35mm/hour. On the chest x-ray (Figure 1-C); a cavitory lesion was present in the left lung middle zone and right costophrenic sinus was blunted. In general, nodular lesions were cleared and the left costophrenic sinus was outlined. Thorax CT taken on the same day (Figures 1-c₁₋₄, Figures 2-c₅₋₉) revealed a marked decrease in the number of the lesions and many of them had subsided. Small subpleural nodules, cavitory lesions few in number and a wedge shaped pleural based con-

solidation in the lateral segment of the right lung lower lobe were observed. Pleural effusion had cleared.

On day 51; Leucocyte count: 10610/mm³, CRP: 0.01 mg/dL and ESR:13 mm/hour had fallen to normal levels. Chest x-ray was normal except a fibrotic band laterally located in the left lung middle zone (Figure 1-D). Thorax CT on the same day revealed (Figures 1-d₁₋₄, Figures 2-d₅₋₉); thin walled two cavitory lesions, a few small subpleural nodules and a fibrotic band extending to the pleural border. Furthermore; all the lesions were almost cleared.

Antibiotic therapy was given for a period of 6 weeks and the radiological findings were totally cleared in 2 months.

DISCUSSION

The main infectious etiologies that cause SPE are; infected venous catheters and pacemaker wires, infected heart valves, peripheral sites of septic thrombophlebitis and anaerobic infections of lateral pharyngeal space (predisposes to suppurative jugular vein thrombosis and Lemierre's syndrome) [3,5]. The most common cause of septic emboli is tricuspid valve endocarditis due to intravenous drug use [3]. Immunocompromised patients with acquired immunodeficiency syndrome and organ transplant recipients are at risk of developing septic emboli [3]. In our patient we detected findings of infective arthritis on the 4th metacarpophalangeal joint of her right hand. Needle aspiration culture and blood culture which were taken simultaneously, revealed MSSA as the etiological agent. Since there was no other infectious origin, septic arthritis was accepted as the source of SPE. Our patient is one of the rare cases in the literature reported as SPE due to septic arthritis.

In the detection and diagnosis of SPE; CT is found superior to chest radiography. It is also helpful to detect complications and to follow the progression of the disease [1]. This case report describes the longitudinal changes in clinical radiological appearances over time.

Miliary infections or hematogenous metastases cause nodular lesions in the secondary lobules of the lungs and are localized especially in the basal fields [6]. In SPE, we can observe bilateral peripherally located nodular lesions with various stages of cavitation and poorly defined outlines on the chest X-rays. Their numbers and sizes may vary with time and the degree of cavitation may change [4]. The main pathological findings on thorax CT are; scattered multiple pulmonary opacities. They are mostly located in the lower lobes as round nodular lesions or pleural based wedge shaped pulmonary densities. They may be nonspecific and have various sizes and frequently cavitate [1,3,4]. Cavitory parenchymal nodules are presumably due to septic occlusion of small, peripheral pulmonary arterial branches, resulting in the development of metastatic lung abscesses and air-fluid levels may present in some of these cavities [3,4].

In the series of Kuhlman et al.; in 50% of the SPE cases, cavitating nodules were seen on CT scans [3]. In

some patients air bronchogram formation (28%), feeding vessel sign (67%), pleural effusion and empyema can be observed [3,4]. Although other authors have described a feeding vessel sign as a characteristic feature of SPE,

we were able to identify this feature associated with only a minority parenchymal lesions and did not find it particularly helpful in the recognition of SPE. The feeding vessel sign is no longer considered a valid sign in CT

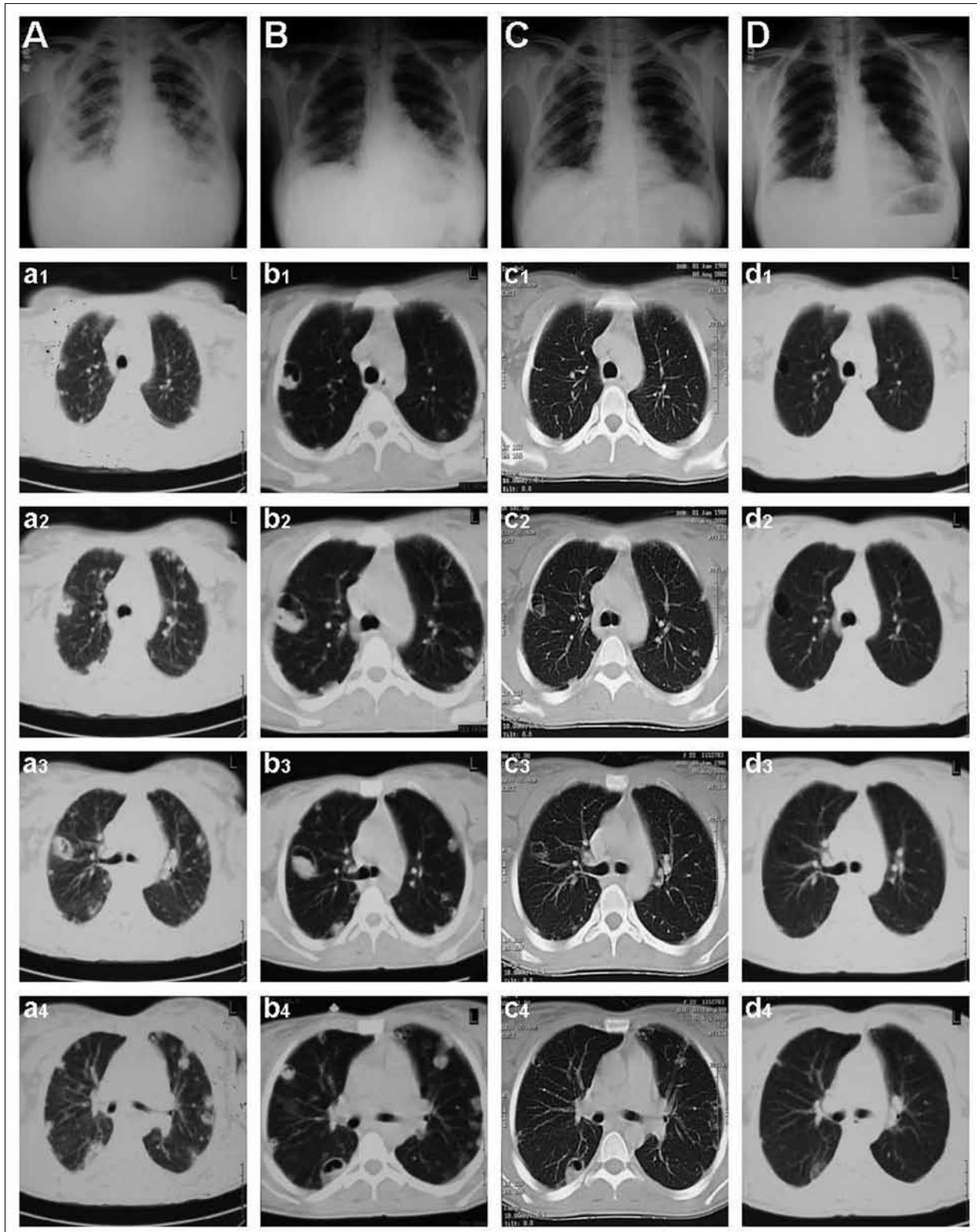


Figure 1. Chest X-ray findings of 22 years old woman with septic pulmonary embolism; on the day of diagnosis (A), on day 8th (B), on day 22nd (C) on day 51st (D) of the treatment and thorax CT scans taken on the same dates (a₁₋₄, b₁₋₄, c₁₋₄, d₁₋₄)

imaging of SPE. Dodd et al. have used high-resolution Multidetector CT to assess the relation of the pulmonary vasculature to septic emboli, with particular attention to the feeding vessel sign [7]. They have shown the vessels

entering the lesion passed around the nodules and showed that these vessels were traced to the left atrium, a finding consistent with pulmonary vein branches. Similar findings were seen in pulmonary metastatic

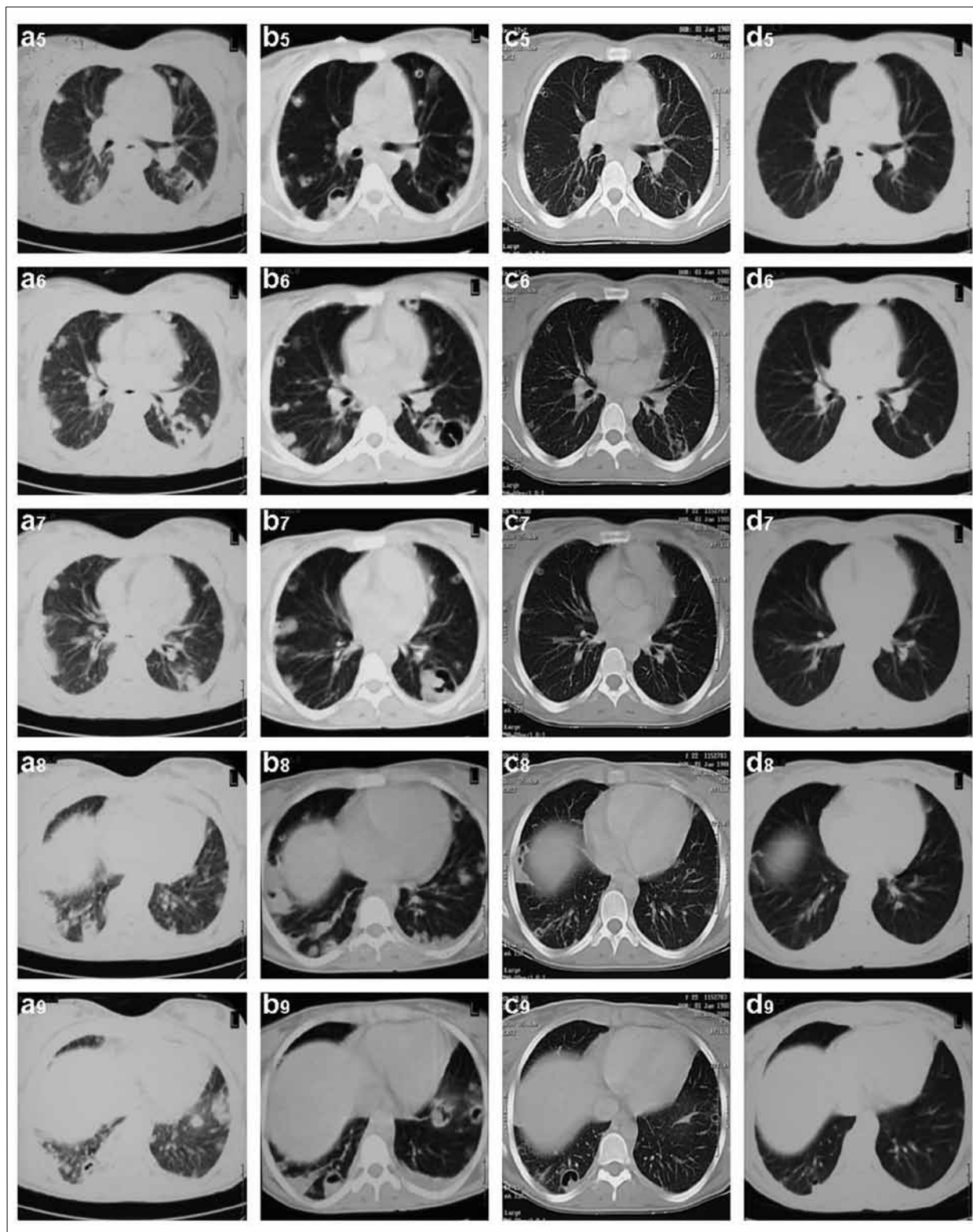


Figure 2. (continued) Thorax CT scans of 22 years old woman with septic pulmonary embolism on the day of diagnosis (a_{5g}), on day 8th (b_{5g}), on day 22nd (c_{5g}) and on day 51st (d_{5g}) of the treatment.

lesions [7]. Although pulmonary septic emboli often appear to have a feeding vessel on conventional cross-sectional images, multiplanar reconstructions show that most of these vessels course around the nodule and that the others are pulmonary veins [7].

Multiple nodular lesions on CT may be misdiagnosed as being metastatic and the differential diagnoses should be made [6]. In time nodular lesions cavitate and this period is more specific and diagnostic radiologically. Together with clinical findings, multiple peripheral cavitating nodules and wedge shaped peripheral consolidations are highly suggestive of the diagnosis of SPE [1,3,4]. Changes in the thorax CT findings in the follow up period are also helpful in the diagnosis. For example; in metastatic tumours we can not see such rapid changes. We had various thorax CT scans of our SPE patient in the follow up period, thus we could observe the evolution of the lesions, their extension and distribution and the characteristic changes with time (Figures 1, 2). Repeated radiologic examinations depend on the clinical course of the disease in the SPE patients. Thorax CT may also have a role in proved cases of SPE when clinical response to appropriate antibiotics is slow. In these cases, CT can be used to evaluate and follow the extent of the disease and detect potential complications such as lung abscess formation or empyema [3].

Cases with SPE could be treated successfully with antibiotics. In some cases, systemic anticoagulation and surgery may be necessary [8,9]. In the presence of infectious diseases; especially in urinary tract infections and respiratory tract infections, a significant transient increase had been observed in the risk of pulmonary embolism and deep venous thrombosis. This was maximal within the first 2 weeks after the initial presentation and returned to baseline after 52 weeks [10]. Our patient had a serious clinical course with hypoxemia and hyperthermia. From the beginning of the diagnosis, we treated her with low molecular weight heparin for 15 days, aiming to enhance the resolution of the disease. However, the role of anticoagulation therapy in patients with SPE is controversial. Some reports do not recommend anticoagulation because early clot dissolution may promote the risk of extending the infection and the risk of emboli and hemorrhage. Others suggest that anticoagulation, by enhancing resolution of the source of septic embolization, may expedite quicker recovery from the thrombophlebitis [9]. Retrospective analysis suggests that anticoagulation may reduce mortality in selected cases; such as septic cavernous sinus thrombosis complicated by subarachnoid abscess and SPE [11]. Short-term anticoagulation may be of value in the management of Lemierre's syndrome; one case rapidly resolved with use of anticoagulative therapy in conjunction with antibiotic

therapy [5]. Patients with thrombophlebitis and a hypercoagulable state due to malignancy or clotting factor deficiencies should be anticoagulated. However, the benefit of anticoagulation in patients with normal clotting function remains controversial [12].

Our patient had characteristic thorax CT findings specific for SPE. She was a rare case of SPE originating from a septic arthritis. We also could follow up the changes in the characteristic lesions on serial CT scans. Improvement was observed in clinical and laboratory findings in the early period with the treatment but thorax CT findings were cleared in two months. As seen in our patient, although the resolution could be slow, radiographic findings could be thoroughly cleared in the patients with SPE.

Acknowledgement

The authors wish to thank Tuna Uysal who is research assistant of Mimar Sinan Fine Arts University Department of Photography for the patient's photographs.

REFERENCES

1. Iwasaki Y, Nagata K, Nakanishi M et al. Spiral CT findings in septic pulmonary emboli. *European Journal of Radiology* 2001; 37: 190-4.
2. Cook RJ, Ashton RW, Aughenbaugh GL et al. Septic pulmonary embolism. *Chest* 2005; 128: 162-6.
3. Kuhlman JE, Fishman EK, Teigen C. Pulmonary septic emboli: Diagnosis with CT. *Radiology* 1990; 174: 211-3.
4. Huang RM, Naidich DP, Lubat E, et al. Septic pulmonary emboli: CT-Radiographic correlation. *Am J Roentgenol* 1989; 153: 41-5.
5. Hughes CE, Spear RK, Shinabarger CE, Tuna IC. Septic pulmonary emboli complicating mastoiditis: Lemierre's syndrome revisited. *Clinical Infectious diseases* 1994; 18: 633-5.
6. Raouf S, Amchentsev A, Vlahos I, et al. Pictorial essay: Multinodular disease: a high-resolution CT scan diagnostic algorithm. *Chest* 2006; 129: 805-15.
7. Dodd JD, Souza CA, Müller NL. High-resolution MDCT of pulmonary septic embolism: evaluation of the feeding vessel sign. *Am J Roentgenol* 2006; 187: 623-9.
8. Shiota Y, Arikita H, Horita N et al. Septic pulmonary embolism associated with periodontal disease: Reports of two cases and review of the literature. *Chest* 2002; 121: 652-4.
9. Morizono S, Enjoji M, Sonoda N et al. Lemierre's syndrome: *Porphyromonas asaccharolytica* as a putative pathogen. *Internal Medicine* 2005; 44: 350-3.
10. Yavin Y, Cohen AT. Venous thromboembolism prophylaxis for the medical patient: Where do we stand? *Semin Respir Crit Care Med* 2008; 29: 75-82.
11. Hoshino C, Satoh N, Sugawara S et al. Septic cavernous sinus thrombosis complicated by narrowing of the internal carotid artery, subarachnoid abscess and multiple pulmonary septic emboli. *Intern Med* 2007; 46: 317-23.
12. Chau TN, Loke TK, Leung VK, et al. Hepatic portal venous gas complicating septic thrombophlebitis of the superior mesenteric vein. *Hong Kong Med J* 2007; 13: 69-72.