

A Case of Pericardial Cyst with an Atypical Location (Paratracheal) Which was Removed by Mediastinoscopy

Mediastinoskopi ile Çıkarılan Atipik Yerleşimli (Paratrakeal) Perikardiyal Kist Olgusu

Ülkü Yazıcı, Taner Ege, Erkmén Gülhan, İrfan Tastepe

Atatürk Göğüs Hastalıkları ve Göğüs Cerrahisi Eğitim ve Araştırma Hastanesi, Göğüs Cerrahisi Kliniği, Ankara, Turkey

ABSTRACT

The incidence rate of pericardial cysts accounts for nearly 7% of all mediastinal cysts. They occur in one in 100.000 people. They may either be of congenital origin or acquired. Their most common location is the right anterior cardiophrenic angle. This is a report of a case who underwent mediastinoscopy for a 3x4 cm coelomic pericardial cyst with an atypical location in the paratracheal area. A paratracheal cyst was incidentally detected in a 41 year old male patient. The cyst was in the upper right mediastinum with a paratracheal location. The patient underwent mediastinoscopy and the cyst was completely removed. Postoperative pathology reported a coelomic pericardial cyst. The patient was discharged on the 3rd postoperative day. Mediastinoscopy is a less invasive method compared to median sternotomy, thoracotomy and VATS in a mediastinal cyst.

(*Tur Toraks Der 2010; 11: 184-6*)

Key words: Pericardial cyst, mediastinoscopy, paratracheal cyst

Received: 16.04.2008

Accepted: 21.07.2008

ÖZET

Perikardiyal kist insidansı tüm mediastinal kistlerin yaklaşık %7'sini oluşturur. Bu kistler, 100.000 kişide bir görülür. Kistler konjenital veya edinsel olabilir. En sık sağ ön kardiofrenik açıda yerleşim gösterirler. Bu, atipik olarak paratrakeal alanda yerleşim gösteren, 3x4 cm'lik bir çölemik perikardiyal kist için mediastinoskopi yapılmış bir olgunun sunumudur. Paratrakeal kist 41 yaşındaki erkek bir hastada tesadüfen tespit edildi. Kist, sağ üst mediastende paratrakeal yerleşimli idi. Hastaya mediastinoskopi uygulandı ve kist tamamen alındı. Ameliyat sonrası patolojide, bu kistin çölemik perikardiyal bir kist olduğu raporlandı. Hasta, ameliyat sonrası 3. gün taburcu edildi. Mediastinoskopi, median sternotomi, torakotomi ve VATS'a kıyasla daha az invaziv bir metottür. (*Tur Toraks Der 2010; 11: 184-6*)

Anahtar sözcükler: Perikardiyal kist, mediastinoskopi, paratrakeal kist

Geliş Tarihi: 16.04.2008

Kabul Tarihi: 21.07.2008

INTRODUCTION

Nonneoplastic mediastinal cysts comprise 20% of all primary mediastinal lesions. Of these lesions, 50-60% are bronchogenic; 20-30% pericardial, and 7-15% enteric or duplication cysts [1]. Congenital pericardial cysts are usually asymptomatic and are detected incidentally on routine pulmonary graphs [2]. The incidence rate of pericardial cysts accounts for nearly 7% of all mediastinal cysts [3,4]. The diagnosis is established in the light of the results of pulmonary graph, fluoroscopy, echography, and computer tomography. MRI may be required for differential diagnosis. Treatment is provided by complete surgical excision of the cyst.

CASE

A 41-year-old male patient was followed-up for uveitis when a paratracheal cyst was incidentally detected. The patient was referred to our clinic with this initial diagnosis for surgical treatment.

The patient had no complaints, and his familial and personal history was non-specific. The findings of the physical examination and laboratory studies were normal. The pulmonary graph of the patient revealed a minimal enlargement in the upper right mediastinal region. The thoracic CT obtained upon initial diagnosis of sarcoidosis at the previous center showed a cystic lesion of 3x4cm in the paratracheal area with liquid content and smooth contours (Figure 1).

The patient had undergone a MRI evaluation, which indicated a cyst of 3x4cm in size in the upper right mediastinum with a paratracheal location. The cyst was thin-walled, showed liquid density on all the secants, and thus was thought to be a benign bronchogenic cyst. (Figure 2).

In the light of the results of the thoracic CT and MRI evaluations, surgical excision through mediastinoscopy was decided for the treatment of the cystic lesion located in the right paratracheal area.

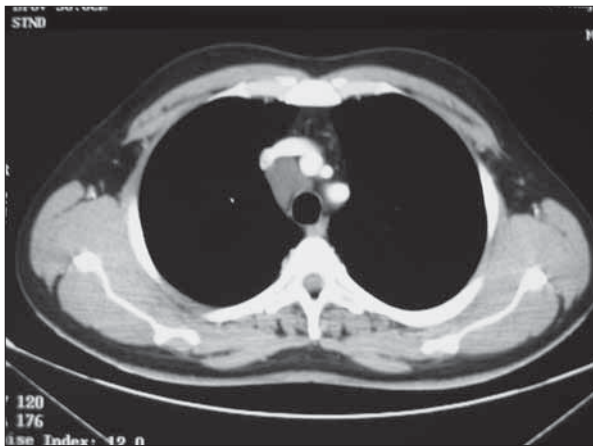


Figure 1. Preoperative chest computed tomography

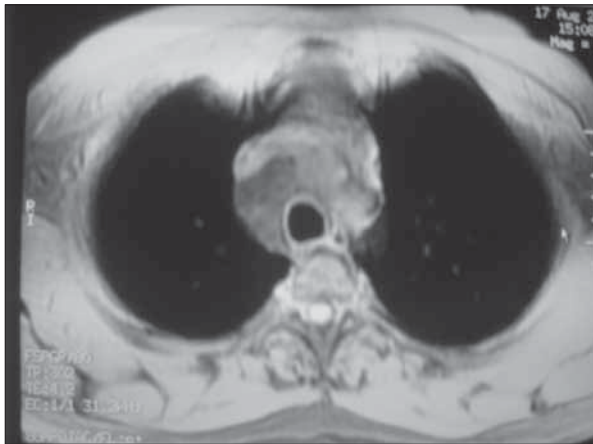


Figure 2. Preoperative chest MRI

The patient underwent mediastinoscopy while under general anesthesia. A cystic lesion of nearly 3x4cm in size was observed in the right paratracheal area. The cyst was partially dissected and freed from the adjacent tissues. The cyst was then punctured. The transparent yellowish fluid of nearly 30cc was aspirated. The cystic cavity which was emptied was drawn with forceps and its peduncle was observed. The peduncle of the cyst was held with forceps and its walls were excised (Figure 3).

The postoperative pathology report, based on the sections of 0.1cm wall thickness, was compatible with a coelomic pericardial cyst 4x3cm in size, layered with a single layer of cubic epithelium and involving lymphocytes and congested, vascular structures. The patient was discharged on the 3rd postoperative day with no complications. The clinical and radiological evaluations of the patient in the monthly follow-up were normal (Figure 4).

DISCUSSION

Coelomic pericardial cysts are rare entities, affecting one in every 100.000 person [5]. Coelomic pericardial cysts or diverticula are detected incidentally in middle age. They may be congenital or acquired.

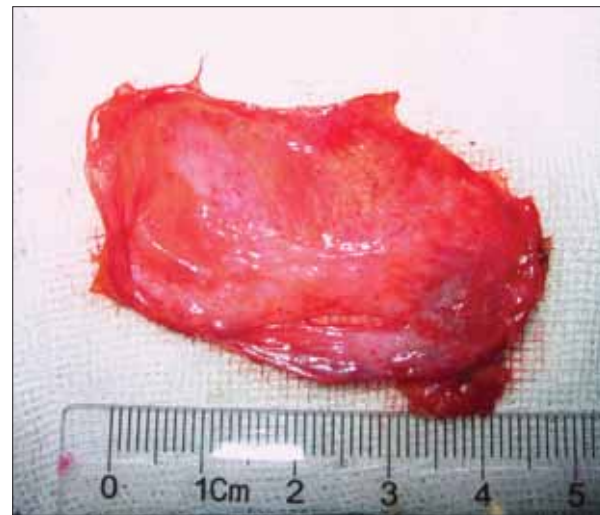

Figure 3. Specimen

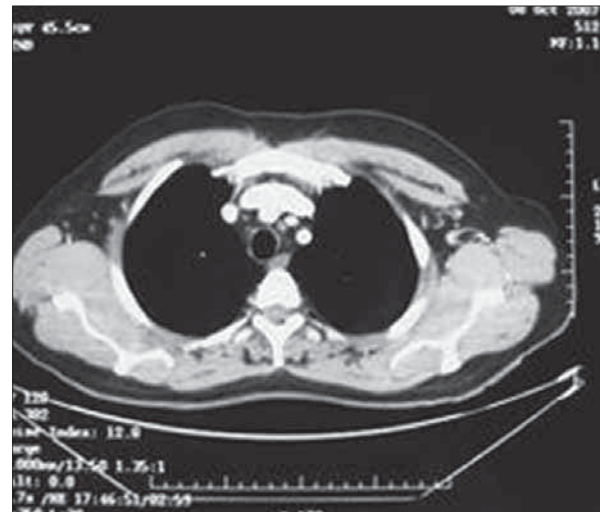


Figure 4. The second month postoperative control computed tomography of chest

They are usually located at the cardiophrenic angle, particularly on the right side [6]. The left costophrenic angle, hilus, and upper mediastinum at the level of the arcus may be listed as some other rare locations. They are observed as asymptomatic cystic lesions on routine pulmonary roentgenograms. The right cardiophrenic angle (70%) and the left cardiophrenic angle (22%) in the mediastinum have been reported to be the most common locations [7]. However, they also have an atypical location at a rate of 8-10%. Similarly, the cystic lesion in our patient was located in the paratracheal area, which is an atypical location for these cysts.

As was defined by Lambert, the pericardial coelom is formed by a series of uncombined lacunes. The pericardial space is formed by the fusion of these lacunes [8]. The cysts termed coelomic pericardial cysts have thin walls and are layered with unilocular and endothelium or mesothelium and contain clear liquid. These cysts do not originate from the pericardium but are loosely connected

to it and thus can easily be removed during the operation. In our patient, the cystic content was clear liquid and the cyst was easily dissected away from the adjacent tissues.

Only 20% of pericardial cysts produce symptoms such as dyspnea or chest wall complaints. Although most cases are asymptomatic, the most common symptom is atypical chest pain [9]. Patients may rarely suffer chest pain associated with torsion of the cyst. On the other hand, there have been reports of fatal complications such as acute right cardiac failure and tamponade due to rupture of the cyst into the pericardial space [10].

No definitive physical examination finding is detected. Pulmonary graphs, echocardiography, computer tomography, and magnetic resonance imaging are the most commonly used diagnostic tools for pericardial cysts. MRI should be the method of choice of diagnosis and monitoring particularly for the pericardial cysts of atypical location [11].

Surgery should be performed upon diagnosis of the cyst. Otherwise, the cyst may reach large dimensions and the risk of rupture and complications increase, leading to morbidity or mortality [12].

Median sternotomy, thoracotomy or VATS (video assisted thoroscopic surgery) may be applied as the surgical techniques. Pericardial cysts are nearly avascular and smooth-contoured structures. Therefore, they are vulnerable to extirpation with minimally invasive techniques [13]. In our patient, we used another minimally invasive technique, mediastinoscopy for the first time and initially vacated the cystic content through a mediastinoscope and then totally excised the resultant cystic cavity.

Through surgical extirpation, radical treatment is provided and symptoms regress. Malignancy may then be ruled out by histochemical analysis of the lesion [14]. Accordingly, even for asymptomatic patients, surgery should be performed in order to prevent potential complications and establish definite diagnosis [15]. Spontaneous resolutions of pericardial cysts have been reported rarely [16].

The mortality risk of surgical treatment is very low and the prognosis is excellent due to total excision of the cyst [17].

In conclusion, desired outcome was obtained after mediastinoscopy, a less invasive method compared to

median sternotomy, thoracotomy, and VATS recommended for the treatment of mediastinal cysts, applied on a patient with a pericardial cyst of paratracheal location. Mediastinoscopy may be considered an alternative to median sternotomy, thoracotomy, and VATS for the treatment of patients with cysts of the atypical location described above because it is a less invasive method.

REFERENCES

1. Güler M, Toker EM, Eren E, ve ark. Pulmoner hipertansiyona yol açan anormal yerleşimli perikardial kist. *Toraks Dergisi* 2006;7:209-11.
2. Chopra PS, Duke DJ, Pellet JR, Rahko PS. Pericardial cyst with partial erosion of the right ventricular wall. *Ann Thorac Surg* 1991;51:840-2.
3. Sugita T, Yasuda R, Mağara T, et al. Pericardial cyst in the midline position. *J Cardiovasc Surg* 1994;35:87-8.
4. Gurlek A, Dagalp Z, Ozyurda U. A case of multiple pericardial hydatid cyst. *Int J Cardiol* 1992;36:336-8.
5. Roober P, Maisin J, Lacquet A. Congenital pleural pericardial cysts. *Thorax* 1963;18:146-50.
6. Williamson BR, Spotnitz WD, Gay SB, Parekh S. Pericardial cyst a rare mass abutting the aorta. *J Comput Tomogr* 1988;12:264-6.
7. Feigin DS, Fenogli JJ, McAllister HA, Madewell JE. Pericardial cyst, A radiologic-pathologic correlation and review. *Radiology* 1977;125:15-20.
8. Bilgen I, Savaş R, Alper H. Atipik Lokalizasyonlu Perikardial Kist: Olgu Sunumu *Ege Tıp Dergisi* 2002;41:177-9.
9. Jarzabkowski DC, Braunstein DB. Pericardial cyst: an incidental finding. *J Am Osteopath Assoc* 1998;98:445-6.
10. Borges AC, Gellert K, Dietel M, et al. Acute right sided heart failure due to hemorrhage into a pericardial cyst. *Ann Thorac Surg* 1997;63:845-7.
11. Vinee P, Stover B, Sigmund G, et al. MR imaging of the pericardial cyst. *J Magn Reson Imaging* 1992;2:593-6.
12. Zambuido AR, Lanzas JT, Calvo MJR, et al. Non-neoplastic mediastinal cysts. *Eur J Cardiothorac Surg* 2002;22:712-6.
13. Hazeldrigg SR, Landreneau RJ, Mack MJ, Acuff TE. Thoracoscopic resection of mediastinal cysts. *Ann Thorac Surg* 1993;56:659-60.
14. Kutluay H, Yavuzer I, Han S, Cangir AK. Atypically located pericardial cysts. *Ann Thorac Surg* 2001;72:2137-9.
15. Martin KW, Siegel MJ, Chesna E. Spontaneous resolution of mediastinal cysts. *Am J Roentgenol* 1988;150:1131-2.
16. Bolton JWR, Shahian DM. Asymptomatic bronchogenic cysts: What is the best management? *Ann Thorac Surg* 1992;53:1134-7.
17. Strollo DC, Rosado-de-Christenson ML, Jett JR. Primary mediastinal tumors Part II. Tumors of the Middle and Posterior Mediastinum. *Chest* 1997;112:1344-57.