

# Solitary Bronchial Papilloma with Malignant Degeneration Presenting with Bronchiectasis and Hemoptysis

## Bronşektazi ve Hemoptizi ile Ortaya Çıkan Malign Dejenerasyon Gösteren Soliter Bronşiyal Papillom

Makbule Ergin<sup>1</sup>, Ali Yeginsu<sup>1</sup>, Ayşe Yılmaz<sup>2</sup>, Reşit Doğan Köseoğlu<sup>3</sup>

<sup>1</sup>Gaziosmanpasa University School of Medicine, Department of Thoracic Surgery, Tokat, Turkey

<sup>2</sup>Gaziosmanpasa University School of Medicine, Department of Pulmonary Medicine, Tokat, Turkey

<sup>3</sup>Gaziosmanpasa University School of Medicine, Department of Pathology, Tokat, Turkey

### ABSTRACT

We report a case of solitary squamous papilloma of the bronchus presenting with hemoptysis. Thoracic computerized tomography scans revealed bronchiectasis of the right upper lobe, mediastinal lymphadenopathy and bilateral emphysematous areas in the lung field. On bronchoscopy, a polypoid hemorrhagic lesion was seen at the orifice of the bronchus of the right upper lobe, a biopsy specimen was obtained and diagnosis was made of squamous papilloma with a malignant potential. The final histopathologic diagnosis was squamous papilloma and carcinoma in situ. In conclusion, a solitary squamous papilloma may present with bronchiectasis and hemoptysis and may show malignant degeneration with carcinoma in situ. Therefore, surgical removal of these lesions is advised.

(*Tur Toraks Der 2010; 11: 77-9*)

**Key words:** Solitary squamous papilloma, carcinoma in situ

Received: 11. 01. 2008

Accepted: 04. 03. 2008

### ÖZET

Hemoptizi ile ortaya çıkan bronşun soliter skuamoz papillomunu tanımladık. Toraks tomografi görüntülerinde sağ üst lob bronşektazisi, mediastinal lenfadenopati ve akciğerde bilateral amfizematoz alanlar görüldü. Bronkoskopide sağ üst lob girişinde polipoid hemorajik bir lezyon görüldü, biyopsi alındı ve tanısı malign potansiyel taşıyan skuamoz papillom olarak geldi. Final histopatolojik tanı skuamoz papillom ve karsinoma in situ idi. Sonuç olarak, soliter skuamoz papillom bronşektazi ve hemoptizi ile ortaya çıkabilir ve karsinoma in situ ile malign dejenerasyon gösterebilir. Bundan dolayı, bu lezyonların cerrahi olarak çıkarılması önerilir.

(*Tur Toraks Der 2010; 11: 77-9*)

**Anahtar sözcükler:** Soliter skuamoz papillom, karsinoma in situ

Geliş Tarihi: 11. 01. 2008

Kabul Tarihi: 04. 03. 2008

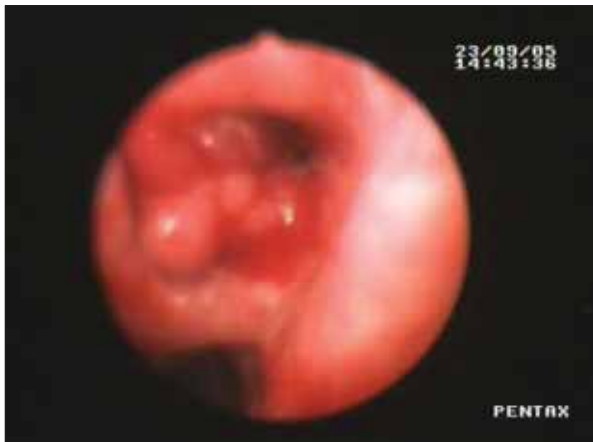### INTRODUCTION

Solitary squamous papilloma of the bronchus is a rare tumor. The incidence of this tumor is reported to be only five cases in 15000 bronchoscopies [1]. Bronchial squamous papilloma, a benign tumor originating from squamous epithelial cells, accounts for 0.38% of all lung tumors [2]. Furthermore, a solitary bronchial papilloma without coexistent pharyngeal papilloma is much rarer. Previous studies have suggested that this type of benign tumor is liable to be complicated by transformation to squamous cell carcinoma at its base and it should rather be considered as a precancerous lesion [2]. We presented a case of solitary endobronchial papilloma which was subsequently complicated by bronchiectasis, hemoptysis, and malignant degeneration.

### CASE

A 73-year-old man was referred to our hospital for further examination of recurrent hemoptysis. He had

suffered hoarseness for 10 years. He was a heavy smoker. Physical examination was unremarkable. Results of routine laboratory studies and serum tumor markers were normal. Thoracic CT scans revealed mediastinal lymphadenopathy, bilateral emphysematous areas, and the right upper lobe had bronchiectatic, fibrotic and atelectatic areas. Bronchoscopic examination identified a polypoid hemorrhagic tumor obstructing the main bronchus of the right upper lobe. The lesion was very soft, fragile and also free of coating and ulceration (Figure 1). Histopathological examination showed squamous papilloma and severe dysplasia with a malignant potential. PCR examination of human papilloma virus (HPV) was negative. The patient then underwent resection of the right upper lobe for bronchiectasis and suspected malignant degeneration. Final histopathological examination confirmed that the tumor was a squamous papilloma showing malignant degeneration with carcinoma in situ

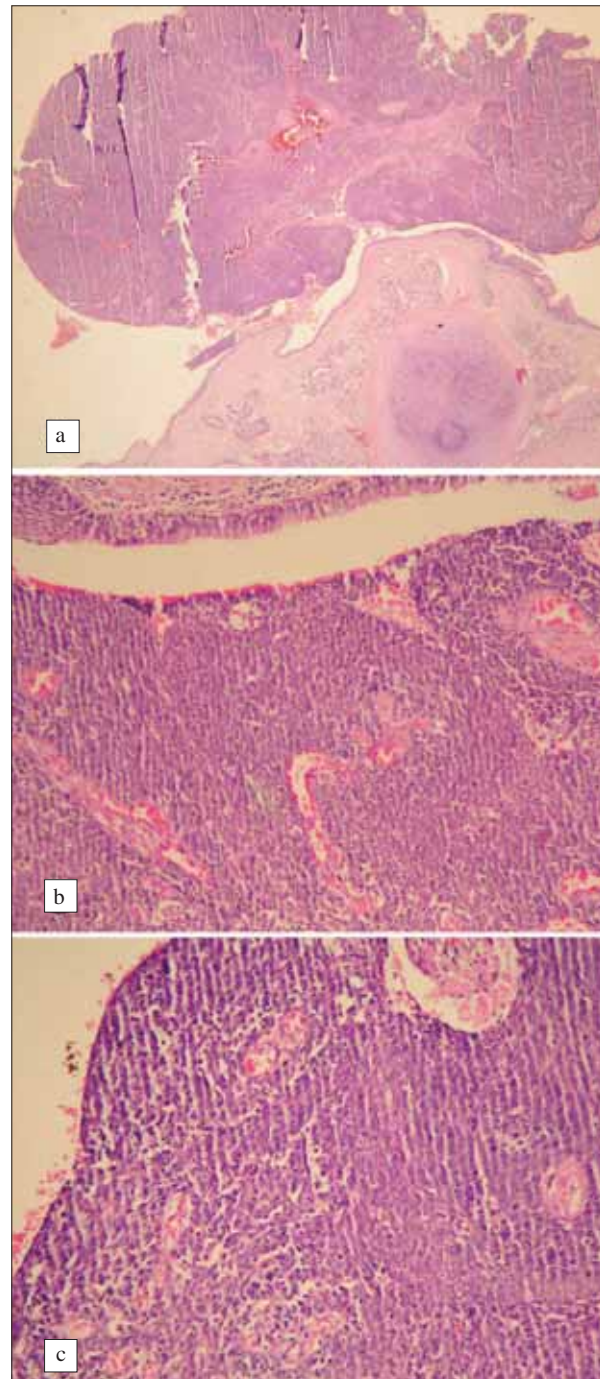


**Figure 1.** Bronchoscopic view of the bronchus of the right upper lobe showing a polypoid tumor, which was very soft fragile and also free of coating and ulceration

(Figure 2). Post-operative course was uneventfully. At the 2<sup>nd</sup> year follow-up, the patient was fully recovered and no recurrence was detected.

#### DISCUSSION

Bronchial papillomas are divided into the following three main groups; 1) multiple papillomas; 2) inflammatory polyps; 3) solitary papillomas [3]. Solitary papillomas are the rarest type. They usually present as an endobronchial mass in the segmental bronchi and may go undetected for years. Because of the rarity of these lesions, little is known about the epidemiology and clinical behaviour of solitary bronchial squamous papillomas [4]. The relationship between HPV and solitary papillomas has been reported. HPV protein E6 and E7 can bind the protein products of tumor suppressor gene p53 and the retinoblastoma protein, and can induce cellular proliferation and dysplasia. Different HPV subtypes show different binding properties. HPV type 6 and 11 are considered to be cause of papillomas [5,6]. Endobronchial foreign bodies are reported as of another etiologic origin [7]. There seems to be a very close relationship between this type of papilloma and smoking habits. Passive smoking also needs to be taken into account in female cases [2]. Our case was also a heavy smoker. The age distribution of the cases is in a very wide range of 22 to 80 years (mean, 58.3 years) and the highest incidence of solitary bronchial papilloma is seen in the 6th decade, and our patient was rather old 73 years. These tumors are six times more common in men than in women [1,2]. Most tumors were located in the segmental or more central bronchi (86%), while the remainder were in subsegmental or peripheral bronchi. The papilloma usually spreads exophytically; however rarely, it penetrates the deeper layers of the bronchial wall ("ice-mountain" type) [1]. The clinical history is characteristically short, lasting a few months to a year [3]. Cough is the commonest presenting symptom, followed by blood-stained sputum. Atelectasia, secondary pneumonia, abscess and bronchiectasis may occur due to bronchial obstruction.



**Figure 2.** Bronchial biopsy showed a squamous papilloma with carcinoma in situ: a) low power appearance of intraductal papilloma within the lumen of a major bronch structure (HE, X4), b) the surface part of squamous papilloma with prominent nuclear dysplasia and the loss of stratification and polarisation in hypercellular squamous epithelium (HE, X20). c) A high power area of the papilloma showed prominent dysplastic figures and dyskeratotic cells (HE, X50)

Malignancy usually occurs in the form of a well differentiated squamous cell carcinoma, which extends by local invasion. Squamous cell carcinomas identified within papillomas show prominent cellular pleomorphism, loss of maturation, increased dyskeratosis and hyperkeratosis and most importantly, invasion of adjacent lymphatic tissues through the bronchial wall [2]. In our patient

bronchial biopsy showed a squamous papilloma with carcinoma in situ and intraductal papilloma within the lumen of a major bronchial structure were seen at low power magnification. The surface part of the squamous papilloma with prominent nuclear dysplasia and the loss of stratification and polarisation in hypercellular squamous epithelium were seen and also the papilloma showed prominent dysplastic figures and dyskeratotic cells. Regional extrapulmonary node metastasis has been reported [8].

Thoracotomy resection was offered for the removal of solitary papillomas in most previous reports to ensure major radicality and to avoid the danger of bleeding [1,2]. Today, however, lobectomy should be avoided if the tumor can be removed completely by endoscopy [2]. For conservation of pulmonary function, segmentectomy or endoscopic resection may be employed, with a close monitoring of the clinical course after such procedure. If the lesion is limited to a small area of the bronchus, conservative treatment, such as laser techniques and coagulation methods, make it possible to remove most of the tumors by performing bronchoscopy, with little trouble to the patients and only a small risk [1-7]. Papillomas that show signs of atypia and peribronchial spreading or that cannot be reached by bronchoscopy also require later chest surgery [1]. The patient underwent resection of the right upper lobe because of a destroyed lobe due to bronchiectasis and suspected malignant degeneration was also present. Recurrence is usually caused by lack of

operative radicality rather than by malignancy. Zimmermann et al. reported recurrent papilloma of the bronchus after an incomplete endoscopic resection [2].

In conclusion, physicians must keep on mind that a solitary squamous papilloma, which is a very rare lesion, may present with bronchiectasis and hemoptysis, and may show malignant degeneration with carcinoma in situ. Because of the potential malignant degeneration, surgical removal of these lesions was offered.

#### REFERENCES

1. Barzo P, Molnar L, Minik K. Bronchial papillomas of various origins. *Chest* 1987;92:132-6.
2. Inoue Y, Oka M, Ishii H, et al. A solitary bronchial papilloma with malignant changes. *Internal Medicine* 2001;40:56-60.
3. Drennan JM, Douglas AC. Solitary papilloma of a bronchus. *J Clin Path* 1965;18:401.
4. Syrjänen KJ. HPV infections and lung cancer. *J Clin Pathol* 2002;55:885-91.
5. Katial RK, Ranlett R, Whitlock WL. Human papilloma virus associated with solitary squamous papilloma complicated by bronchiectasis and bronchial stenosis. *Chest* 1994;106:1887-9.
6. Kawaguchi T, Matumura A, Iuchi K, et al. Solitary squamous papilloma of the bronchus associated with human papilloma virus type II. *Internal Medicine* 1999;38:817-9.
7. Greene JG, Tassin L, Saberi A. Endobronchial epithelial papilloma associated with a foreign body. *Chest* 1990;97:229-30.
8. DiMarco AF, Montenegro H, Payne CB, et al. Papillomas of the tracheobronchial tree with malignant degeneration. *Chest* 1978;74:464-5.