

Diagnostic Value of EBUS in Mediastinal and Hilar Lymph Nodes

Mediastinal ve Hiler Lenf Nodlarının Tanısında EBUS'un Yeri

Sinem Nedime Sökücü¹, Erdoğan Çetinkaya¹, Sedat Altın¹, Levent Karasulu¹, Ekrem Cengiz Seyhan¹, Akif Turna²

¹Yedikule Göğüs Hastalıkları ve Göğüs Cerrahisi Eğitim ve Araştırma Hastanesi, Göğüs Hastalıkları Kliniği, İstanbul, Turkey

²Yedikule Göğüs Hastalıkları ve Göğüs Cerrahisi Eğitim ve Araştırma Hastanesi, Göğüs Cerrahisi Kliniği, İstanbul, Turkey

ABSTRACT

Objective: One of the indications for endobronchial ultrasound (EBUS) is the diagnosis of mediastinal and/or hilar lymphadenopathy. The aim of this study is to report the place of EBUS probe using a single-channel bronchoscope that allows TBNA after localisation of lymph nodes under ultrasound in the diagnosis of mediastinal and hilar lymph nodes.

Material and Method: Retrospectively, 45 patients were enrolled with a proven lymph node on CT and an indication for TBNA for diagnosis. Lymph nodes were verified under local anesthesia by EBUS and sampled using a Wang 22 gauge cytology needle. The EU-M30s model EBUS and UM-BS 20-26 R Olympus ultrasonic probe was used. Procedures were applied through Pentax EB 1970 model bronchoscope.

Results: TBNA procedures were performed using a flexible bronchoscope and a 22-gauge Wang needle in 45 consecutive patients (23 women (51.1%); mean age, 47±15 years [+/- SD] (17-74)) who had mediastinal or hilar adenopathy identified on chest CT. The average number of needle passes was 5.0±1.8 (2-9) per patient. A total of 85 lymph nodes were sampled. Adequate material was found in all of the patients (100%). In 36 (80.0%) of the cases the adequate material was diagnostic. The diagnostic value of EBUS TBNA was 82.4% in sarcoidosis, 60% in tuberculosis and 100% in small cell lung carcinoma and nonsmall cell lung carcinoma.

Conclusion: EBUS guided TBNA of mediastinal and hilar lymph nodes is a safe approach which increases the percentage of adequate material and diagnostic yield.

(*Tur Toraks Der 2009;10:167-71*)

Key words: Endobronchial ultrasound, transbronchial needle aspiration, diagnosis

Received: 12. 02. 2009

Accepted: 25. 03. 2009

ÖZET

Amaç: Endobronşiyal ultrasonun (EBUS) endikasyonlarından biri de mediastinal veya hiler lenf nodlarının tanısında kullanımıdır. Çalışmamızın amacı tek kanallı bronkoskop eşliğinde EBUS probu kullanılarak lenf nodunun lokalizasyonu sonrası yapılan TBNA'nın mediastinal veya hiler lenf nodlarının tanısında yerini göstermektir.

Gereç ve Yöntem: BT'sinde kanıtlanmış lenf nodu olan ve tanı için TBNA endikasyonu olan prospektif 45 hasta çalışmaya dahil edildi. Lenf nodları önce lokal anestezi altında EBUS ile verifiye edildi ve Wang 22 gauge sitoloji iğnesi ile örnekledi. EU-M30s model EBUS ve UM-BS 20-26 R Olympus ultrasonik probu kullanıldı. Prosedürler Pentax EB 1970 model bronkoskop ile uygulandı.

Bulgular: TBNA'ları fleksibil bronkoskop içinden 22 gauge Wang iğnesi ile uygulandı. 45 vakanın 23 tanesi (%51.1) kadını ve hastaların ortalama yaşı 47 ±15 (17-74) idi. Ortalama örneklem sayısı 5.0±1.8 (2-9) idi. Toplamda 85 lenf nodu örnekledi. Tüm hastalardan yeterli materyal elde edildi (%100). 36 (%80) vaka da yeterli materyal aynı zamanda tanısaldı. EBUS TBNA'nın tanılma değeri sarkoidozda %82.4, tüberkülozda %60, küçük hücreli akciğer kanseri ve küçük hücre dışı akciğer kanserinde %100 bulundu.

Sonuç: Mediastinal ve hiler lenf nodlarının EBUS rehberliğinde TBNA ile örneklenmesi yeterli materyal alınımının ve tanılma oranının artmasını sağlayan güvenli bir yaklaşımdır.

(*Tur Toraks Der 2009;10:167-71*)

Anahtar sözcükler: Endobronşiyal ultrason, transbronşiyal iğne aspirasyonu, tanı

Geliş Tarihi: 12. 02. 2009

Kabul Tarihi: 25. 03. 2009

INTRODUCTION

Transbronchial needle aspiration (TBNA) is a well-established bronchoscopic technique [1,2]. Conventional TBNA is a blind procedure. The accuracy of TBNA varies widely in the literature (*i.e.* 20 to 89%) [3,4]. Important factors that can influence the results of TBNA are estab-

lished lymph node enlargement on CT, lymph node size, site of the lymph node, the kind of needle used, number of aspirates performed, the ability and experience of the operators, and the availability of rapid on-site evaluation (ROSE) [5]. Recently, there has been significant interest in imaging-assisted TBNA. Procedure guidance with the

Presented In: Annual Congress of European Respiratory Society, October 4-8, 2008, Berlin, Germany

Address for Correspondence / Yazışma Adresi: Sinem Nedime Sökücü, Yedikule Göğüs Hastalıkları ve Göğüs Cerrahisi Eğitim Araştırma Hastanesi, Göğüs Hastalıkları Kliniği, İstanbul, Turkey Phone: +90 212 664 17 00 E-mail: sinemtimur@yahoo.com

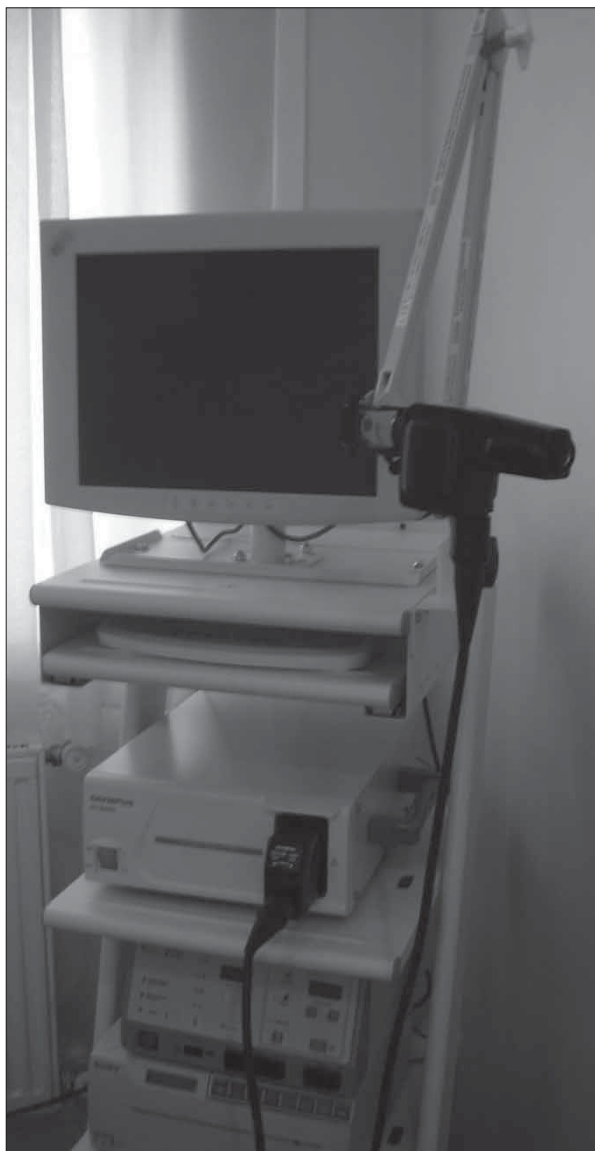

Figure 1. Ultrasonic probe with driving unit and processor

aid of CT fluoroscopy [6] as well as endobronchial ultrasound (EBUS) [7,8] has been shown to be feasible and simple to perform. Those studies suggested a significant increase in yield. In previously published studies, it was shown that endobronchial ultrasound (EBUS) with TBNA was highly accurate and cost effective as a diagnostic tool [9].

In the present study, we aimed to investigate the diagnostic value of EBUS guided TBNA performed with a 22-gauge Wang cytology needle, in patients with mediastinal and/or hilar adenopathy identified by chest CT. This study was also designed to address the question of whether EBUS-guided TBNA can increase the value of TBNA in mediastinal or hilar lymphadenopathies.

MATERIAL and METHOD

Between October 2006 and June 2007, EBUS-guided transbronchial needle aspiration (TBNA) evaluation of mediastinal lesions were carried out in 45 patients without any known diagnosis but with enlarged mediastinal lymph nodes on their CT scan. Patient selection was

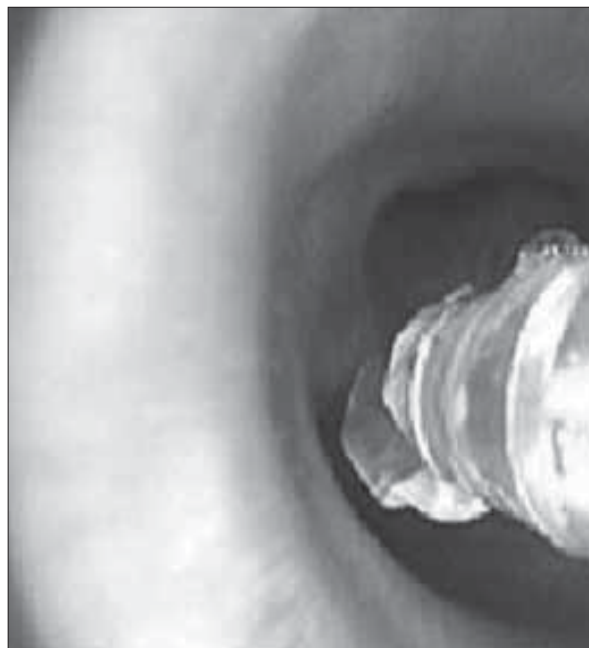

Figure 2. Probe placed in the working channel of the bronchoscope

based on CT findings showing mediastinal lymph node enlargement (>1 cm in short-axis dimension). Lymph node status was classified according to the international staging system reported by Mountain and Dressler [10]. To be included in this study, patients were required to have a mediastinal lymph node accessible by EBUS-TBNA with a short diameter of 10 to 30 mm on axial chest CT. Informed consent was obtained from all patients before the procedures. All the prospectively recorded data were evaluated retrospectively.

Bronchoscopy was performed in standard fashion under local anesthesia using xylocaine (maximum 8mg/kg) and conscious sedation using midazolam (0.07-0.1 mg/kg; maximum 5mg) for flexible endoscopy. All EBUS-TBNA procedures were performed as described below. Lymph node size on chest CT scan, number of passes, diagnosis, and complications were recorded. A positive result was either a specific diagnosis (*e.g.* malignant cells) or a lymphocyte-positive specimen, indicating that sampling of the lymph node was successfully achieved. All patients with a negative result underwent a surgical biopsy procedure (mediastinoscopy or surgical mediastinal lymph node dissection).

EBUS

EBUS technique, using a radial probe (RP) with a rotating transducer at the distal tip, which produces a 360° image to the long axis of the bronchoscope, was used. Through a bronchoscope with a 2.8-mm working channel (Pentax EB 1970 and Olympus Excera and Olympus p 40D; Olympus; Tokyo, Japan), a flexible ultrasound probe with a 20-MHz transducer (UM-BS 20-26 R Olympus ultrasonic probe with driving unit MH-240 and processor EU-M 30s; Olympus) was introduced (Figure 1). The probe was placed through a guide sheath in the working channel of the bronchoscope [11,12] (Figure 2). The probe was positioned near the target area, where a balloon surrounding the probe has to be inflated with water

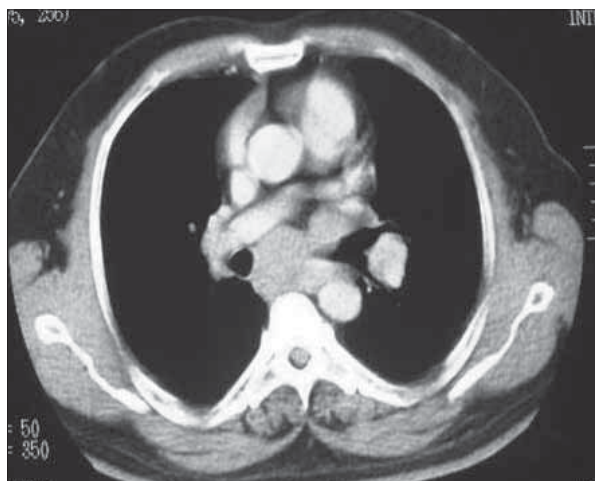

Figure 3. Location of the lymph node on Thorax CT

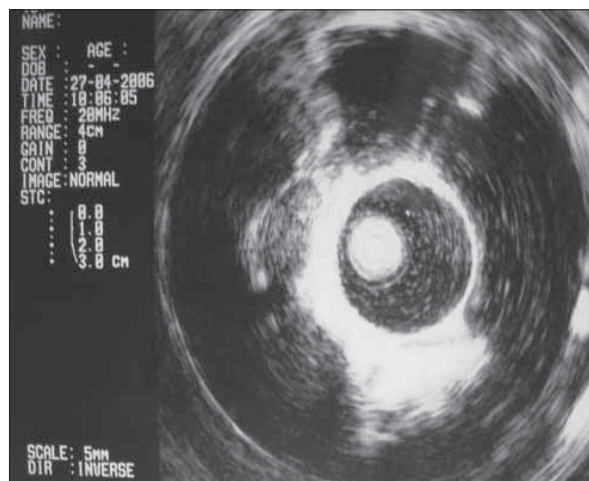


Figure 4. Visualized lymph node

Table 1. Types of sampled lymph nodes

Lymph node/ ratio	Number	Percent
Subcarinal	38	44.7%
Hilar	29	34.1%
Paratracheal	18	21.2%
Total	85	100%

Table 2. Final diagnosis of the patients and diagnostic ratios

	Nondiagnostic	Diagnostic	Total
Tuberculosis	4 (40%) 44.4%	6 (60%) 16.7%	10 (22.2%)
Sarcoidosis	3 (17.6%) 33.3%	14 (82.4%) 38.9%	17 (37.8%)
NSCLC	0 0	6 (100%) 16.7%	6 (100%)
SCLC	0 0	9 (100%) 25%	9 (20%)
Lymphoma	2 (100%) 22.2%	0	2 (4.4%)
Reactive hyperplasia	0	1 (100%) 2.8%	1 (2.2%)

in order to ensure coupling with the airway wall and transmission of the ultrasound waves. The probe was used to visualize the lesion (Figures 3 and 4). The exact location of the target lymph nodes and their relation to the tracheobronchial tree were noted. Once the target lymph node was identified, the probe was then removed from the working channel, and the needle was placed through the sheath and remained in place in order to stabilize the lesion during the TBNA [7,13]. Consequently, the actual TBNA procedure was performed without real-time needle monitoring.

RESULTS

The main indications for TBNA were in the diagnosis of enlarged lymph nodes. Forty five consecutive patients (23 women (51.1%); mean age, 47+/-15 years [+/- SD] (17-74)) who had mediastinal or hilar adenopathy identified on CT of the chest were examined.

The average number of needle passes was 5.0±1.8 [2-9] per patient and 2.56 per localization. A total of 85 lymph nodes were sampled, of whom 38 (44.7%) were subcarinal, 29 (34.1%) were hilar and 18 (21.2%) were paratracheal. EBUS-TBNA was used to sample 85 lymph nodes: thirty eight (44.7%) in station 7, eighteen (21.2%) in station 4 and twenty nine (34.1%) in station 10 (Table 1). No diagnostic difference was detected due to localization of the lymph node ($p>0.05$).

TBNA was performed in one location in 14 patients (31.1%). Most of the patients needed sampling from two locations (21 patients; 46.7%). The procedure was performed in three and four different locations in 8 and 2 patients respectively (17.8% and 4.4%). Adequate material was found in all of the patients (100%). In 36 (80.0%) of the cases the adequate material was diagnostic. All patients without a specific diagnosis, irrespective of the presence or absence of lymphocytes in the specimens, underwent a surgical biopsy procedure. End diagnoses included tuberculosis (n=10), sarcoidosis (n=17), carcinoma (n=15), lymphoma (n=2) and reactive hyperplasia (n=1). The diagnostic value of EBUS TBNA in the mediastinal and hilar lymph nodes was 82.4% in sarcoidosis, 60% in tuberculosis and 100% in small cell lung carcinoma and nonsmall cell lung carcinoma (Table 2).

Carcinoma patients had no definitive lesions by chest CT except for intrathoracic lymphadenopathy. In all of the 15 carcinoma patients (100%) and 3 patients with lymphoma, adequate materials were obtained. However, diagnosis of lymphoma could not be made by cytologic examination of TBNA. The rate of diagnostic success by TBNA was similar in tuberculosis and sarcoidosis (60% vs 82.4%), which appeared lower than for intrathoracic lymphadenopathy due to carcinoma (100%). No complications, either related to the procedure or to bronchoscopic damage, other than minimal hemorrhage, were observed with the use of EBUS TBNA.

DISCUSSION

TBNA is a well-established bronchoscopic technique but remains underutilized, and the yield varies widely [14]. This fact may be due to the long learning curve.

Additionally, conventional TBNA is a relatively blind technique preventing target visualization. This makes accessing smaller lymph nodes and nodes in some locations more difficult. Limited options currently exist to improve yield. Important factors that can influence the results of TBNA are established lymph node enlargement on CT, lymph node size, site of the lymph node, kind of needle used, number of aspirates performed, the ability and experience of the operators, and the availability of ROSE [5]. The most commonly recommended are ROSE and, recently, the passing of the needle up to seven times into one target [15]. ROSE is not available at all institutions and is expensive [16]. Also, passing a needle seven times into a nodal target is time-consuming and increases the chance of damaging the bronchoscope.

Recently, a new adjunct to bronchoscopy has been used to increase the yield. Our study evaluates this alternative to conventional procedures. EBUS offers a unique way of imaging airway and parabranchial structures during a bronchoscopy procedure [17-19]. The procedure is safe and minimally invasive, and does not require general anesthesia or hospitalization [18,19]. The complication rate is extremely low, and several studies have not reported any complications at all [8,17,18,20]. Likewise, no complications, either related to the procedure or to bronchoscopic damage, other than minimal hemorrhage in one case, were observed in our study.

Several studies have been conducted using EBUS for the localization of mediastinal nodes. In a prospective study of 242 patients with enlarged mediastinal nodes (mean diameter 1.7 cm) at chest CT, all target nodes could be identified by EBUS, independently of size or location. Adequate samples were obtained in 86% of cases and malignant lymph node involvement was assessed in 72 % of cases [7]. In our study, all target nodes were identified independently of size and location, and also adequate samples were obtained from all patients.

A randomized trial of the use of EBUS in the guidance of TBNA procedures has been reported previously [23]. In the study by Shannon, no significant difference was found between EBUS guidance and conventional TBNA. In that study ROSE was also used in all patients, potentially masking any benefit of image guidance. On the other hand, another large (n=200) randomized trial by Herth et al, between conventional TBNA and TBNA after EBUS localization for mediastinal staging of enlarged nodes, demonstrated that EBUS guidance significantly increased the yield of TBNA in all stations (84 versus 58%), [22]. In our study, significant increase was reported by EBUS guidance TBNA when compared with the conventional TBNA done by the same pulmonologist reported earlier. In that study, TBNA procedures were performed using a flexible bronchoscope and a 22-gauge Wang needle in 60 consecutive patients. Adequate lymph node sampling was obtained from 59 patients (98%) and diagnosis was made in 45 of 60 patients (75%) [24], whereas in our study, adequate lymph node sampling was made in all patients (100%) and accuracy was 90.9%.

The end diagnosis made by conventional TBNA was tuberculosis in 13 of 20 cases (65%) cytologically [24], whereas in our study the diagnostic value of EBUS TBNA was 60% in tuberculosis (6 out of 10). No significant difference was found, mainly because of the sample size. Another reason for the low diagnostic rates in both of the studies is the use of 22-gauge needles. It has been shown that using 19-gauge needles to collect samples suitable for histological examination was better than 22-gauge needles in the diagnosis of benign mediastinal lymph nodes [26-28]. Our study suggests that EBUS guided TBNA performed using a Wang 22-gauge needle is a useful and safe method in the diagnosis of HIV-negative adult patients with intrathoracic lymph nodes due to tuberculosis, which is responsible for most of the benign intrathoracic lymph node enlargements in our country [29].

Sarcoidosis is in general a benign disease; however, tissue analysis is necessary for differential diagnoses from other causes of intrathoracic lymph nodes. The usual method of obtaining diagnostic tissue is TBB. However, TBB carries significant complications [5]. In some cases, further invasive procedures might be needed, such as mediastinoscopy or open-lung biopsy. In our earlier study, 16 of 20 patients with sarcoidosis (76%) were successfully diagnosed by TBNA with a 22-gauge needle. In our study, 13 of 17 patients with sarcoidosis (82.4%) were successfully diagnosed by EBUS guided TBNA with a 22-gauge needle.

The value of EBUS guided TBNA is particularly evident in the staging and diagnosis of lung carcinoma [5,21]. In our earlier study, diagnostic material was obtained from 100% of patients with carcinoma (15 of 15 patients). Two of three patients with lymphoma provided adequate but nondiagnostic material. Likewise, in this study with EBUS guided TBNA, diagnostic material was obtained from all of the patients with carcinoma (15 of 15 patients), but from none of the two patients with lymphoma even though adequate material was taken.

In conclusion, similar to the literature, our experience with EBUS-guided TBNA showed that sampling with EBUS-guided TBNA is important for diagnosis. We consider that EBUS guidance should be considered a routine adjunct to bronchoscopy before referring the patient directly to more invasive procedures such as mediastinoscopy.

REFERENCES

1. Arroliga, AC, Matthay RA The role of bronchoscopy in lung cancer. *Clin Chest Med* 1993;14:87-98.
2. Mehta AC, Kavuru MS, Meeker DP, et al. Transbronchial needle aspiration for histology specimens. *Chest* 1989;96:1268-72.
3. Wang KP, Brower R, Haponik EF, et al. Flexible transbronchial needle aspiration for staging of bronchogenic carcinoma. *Chest* 1983;84:571-6.
4. Gasparini S, Zuccatosta L, DeNictolis M. Transbronchial needle aspiration of mediastinal lesions. *Monaldi Arch Chest Dis* 2000;55:29-32.
5. Herth FJF, Rabe KF, Gasparini S, Annema JT. Transbronchial and transoesophageal (ultrasound-guided) needle aspirations for the analysis of mediastinal lesions. *Eur Respir J* 2006;28:1264-75.

6. Garpestad E, Goldberg S, Herth F, et al. CT fluoroscopy guidance for transbronchial needle aspiration: an experience in 35 patients. *Chest* 2001;119:329-32.
7. Herth FJF, Becker HD, Ernst A. Ultrasound guided transbronchial needle aspiration (TBNA): an experience in 242 patients. *Chest* 2003;123:604-7.
8. Okamoto H, Watanabe K, Nagatomo A, et al. Endobronchial ultrasonography for mediastinal and hilar lymph node metastases of lung cancer. *Chest* 2002;121:1498-506.
9. Callister ME, Gill A, Allott W, Plant PK. Endobronchial ultrasound guided transbronchial needle aspiration of mediastinal lymph nodes for lung cancer staging: a projected cost analysis. *Thorax* 2008;63:384.
10. Mountain CF, Dresler CM. Regional lymph node classification for lung cancer staging. *Chest* 1997;111:1718-23.
11. Falcone F, Fois F, Grosso D. Endobronchial ultrasound. *Respiration* 2003;70:179-94.
12. Herth FJ, Becker HD, Eberhardt R. Endobronchial ultrasound in lung cancer. *Radiologe* 2004;44:457-64.
13. Okamoto H, Watanabe K, Nagatomo A, et al. Endobronchial ultrasonography for mediastinal and hilar lymph node metastases of lung cancer. *Chest* 2002;121:1498-506.
14. Haponik EF, Shure D. Underutilization of transbronchial needle aspiration: experiences of current pulmonary fellows. *Chest* 1997;112:251-3.
15. Chin R, Jr, McCain TW, Lucia MA, et al. Transbronchial needle aspiration in diagnosing and staging lung cancer: how many aspirates are needed? *Am J Respir Crit Care Med* 2002;166:377-81.
16. Layfield LJ, Bentz JS, Gopez EV. Immediate on-site interpretation of fine-needle aspiration smears: a cost and compensation analysis. *Cancer* 2001;93:319-22.
17. Becker HD, Herth F. Endobronchial ultrasound of the airways and the mediastinum. Bolliger, CT Mathur, PN eds. *Interventional bronchoscopy. Progress in respiratory research* 2000;vol 30, Basel, Karger:80-93.
18. Herth F, Becker HD. Endobronchial ultrasound (EBUS): assessment of a new diagnostic tool in bronchoscopy for staging of lung cancer. *Onkologie* 2001;24:151-4.
19. Kurimoto N, Murayama M, Morita K, et al. Clinical applications of endobronchial ultrasonography in lung diseases. *Endoscopy* 1998;S1:A8-A12.
20. Herth F, Becker HD. Endobronchial ultrasound of the airways and the mediastinum. *Monaldi Arch Chest Dis* 2000;55:36-44.
21. Detterbeck FC, Jantz MA, Wallace M, et al. Invasive Mediastinal Staging of Lung Cancer* ACCP Evidence-Based Clinical Practice Guidelines (2nd Edition) *Chest* 2007;132:202S-220S.
22. Herth F, Becker HD, Ernst A. Conventional vs endobronchial ultrasound-guided transbronchial needle aspiration: a randomized trial. *Chest* 2004;125:322-5.
23. Shannon JJ, Bude, RO, Orens, JB, et al. Endobronchial ultrasound-guided needle aspiration of mediastinal adenopathy. *Am J Respir Crit Care Med* 1996;153:1424-30.
24. Cetinkaya E, Yildiz P, Altin S, Yilmaz V. Diagnostic value of transbronchial needle aspiration by Wang 22-gauge cytology needle in intrathoracic lymphadenopathy. *Chest* 2004;125:527-31.
25. Rintoul RC, Skwarski KM, Murchison JT, et al. Endobronchial and endoscopic ultrasound-guided real time fine needle aspiration for mediastinal staging. *Eur Respir J* 2005;25:416-21.
26. Leonard C, Tormey V, Lennon A, et al. Utility of Wang transbronchial needle biopsy in sarcoidosis. *Ir J Med Sci* 1997;166:41-3.
27. Wang KP, Fuenning C, Johns CJ, et al. Flexible transbronchial needle aspiration for the diagnosis of sarcoidosis. *Ann Otol Rhinol Laryngol* 1989;98:298-300.
28. Morales CF, Patefield AJ, Stollo, PJ, et al. Flexible transbronchial needle aspiration in the diagnosis of sarcoidosis. *Chest* 1995;106:709-11.
29. Baran R, Tor M, Tahaoglu K, et al. Intrathoracic tuberculous lymphadenopathy: clinical and bronchoscopic features in adults without parenchymal lesions. *Thorax* 1996;51:87-9.