



Turkish Thoracic Journal

Official Journal of the Turkish Thoracic Society

SUPPLEMENT 1 APRIL 2018 VOLUME

19

21st Turkish Thoracic Society Annual Congress Abstract Book





Turkish Thoracic Journal

Official Journal of the Turkish Thoracic Society

ISSUE 2 APRIL 2018 VOLUME

19

EDITORS

Oğuz KILINÇ

Department of Chest Diseases, Dokuz Eylül University School of Medicine, İzmir, Turkey

Metin AKGÜN

Department of Chest Diseases, Atatürk University School of Medicine, Erzurum, Turkey

ASSOCIATE EDITORS

Mehmet BAYRAM

Department of Chest Diseases, Bezmialem Vakıf University School of Medicine, İstanbul, Turkey

Ufuk ÇAĞIRICI

Department of Chest Surgery, Ege University School of Medicine, İzmir, Turkey

Begüm ERGAN

Department of Chest Diseases, Dokuz Eylül University School of Medicine, İzmir, Turkey

Aslı GÖREK DİLEKTAŞLI

Department of Chest Diseases, Uludağ University School of Medicine, Bursa, Turkey

Zuhal KARAKURT

Respiratory Intensive Care Unit, Süreyyapaşa Chest Diseases and Surgery Training and Research Hospital, İstanbul, Turkey

Zeynep Pınar ÖNEN

Department of Chest Diseases, Ankara University School of Medicine, Ankara, Turkey

Özge YILMAZ

Department of Pediatrics, Celal Bayar University School of Medicine, Manisa, Turkey

BIostatistical CONSULTANT

Ahmet Uğur DEMİR

Department of Chest Diseases, Hacettepe University School of Medicine, Ankara, Turkey

PUBLICATION COORDINATOR

Hasan BAYRAM

Department of Chest Diseases, Koç University School of Medicine, Gaziantep, Turkey

Türk Toraks Derneği adına sahibi / Owner on behalf of the Turkish Thoracic Society: Fuat Kalyoncu • Yayın türü / Publication Type: Yerel süreli / Local periodical • Yayın tarihi / Publication Date: Nisan 2018 / April 2018 • Türk Toraks Derneği tarafından yayınlanmaktadır / Published by Turkish Thoracic Society, Turan Güneş Bulvarı Koyunlu Sitesi No: 175/19 Oran-Ankara, Turkey (+90 312 490 40 50)



Publisher
İbrahim KARA

Publication Director
Ali ŞAHİN

Deputy Publication Director
Gökhan ÇİMEN

Publication Coordinators
Betül ÇİMEN
Zeynep YAKIŞIRER

Gizem KAYAN
Özlem ÇAKMAK
Okan AYDOĞAN
Merve SAĞLAMER
İrem DELİÇAY

Project Assistants
Büşra PARMAKSIZ
Ecenur ASLIM

Graphics Department
Ünal ÖZER
Neslihan YAMAN
Deniz DURAN

Contact

Address: Büyükdere Cad. No: 105/9 34394
Mecidiyeköy, Şişli-İstanbul

Phone: +90 212 217 17 00

Fax: +90 212 217 22 92

E-mail: info@avesyayincilik.com



Turkish Thoracic Journal

Official journal of the Turkish Thoracic Society

INTERNATIONAL EDITORIAL BOARD

Ian M. Adcock

Cell and Molecular Biology Airways Disease Section,
National Heart and Lung Institute, Imperial College
London, United Kingdom

Piergiuseppe Agostoni

Department of Clinical Sciences and Community
Health, Cardiovascular Section, Università di Milano,
Milano, Italy

M. Selim Arcasoy

Pulmonary, Allergy, and Critical Care Division,
Department of Medicine, Columbia University New
York, USA

Philippe Astoul

Thoracic Oncology - Pleural Diseases -
Interventional Pulmonology, Hôpital Nord - Chemin
des Bourrely, Marseille, France

Ülkü Bayındır

Retired Faculty Member, Ege University School of
Medicine, İzmir, Turkey

Dominique MA Bullens

Department of Immunology and Microbiology, KU
Leuven Laboratory of Pediatric Immunology Division
of Pediatrics, Leuven, Belgium

Richard Casaburi

Rehabilitation Clinical Trials Center, Los Angeles
Biomedical Research Institute at Harbor-UCLA
Medical Center, Torrance, California, USA

Turgay Çelikel

Department of Chest Diseases, Marmara University
School of Medicine, İstanbul, Turkey

Tansu Ulukavak Çiftçi

Department of Chest Diseases, Gazi University
School of Medicine, Ankara, Turkey

Lütfi Çöplü

Department of Chest Diseases, Hacettepe University
School of Medicine, Ankara, Turkey

Çağlar Çuhadaroğlu

Acıbadem Maslak Hospital, İstanbul, Turkey

Andrew J. Ghio

US Environmental Protection Agency Chapel Hill,
North Carolina, USA

İlhan İnci

University Hospital Zurich, Department of Thoracic
Surgery, Zurich, Switzerland

Oya İtil

Department of Chest Diseases, Dokuz Eylül
University School of Medicine, İzmir, Turkey

A. Fuat Kalyoncu

Department of Chest Diseases, Hacettepe University
School of Medicine, Ankara, Turkey

Fazilet Karakoç

Department of Child Chest Diseases, Marmara
University Pendik Training and Research Hospital,
İstanbul, Turkey

Ali Kocabaş

Department of Chest Diseases, Çukurova University
School of Medicine, Adana, Turkey

Emel Kurt

Department of Chest Diseases, Osmangazi
University School of Medicine, Eskişehir, Turkey

Richard Light

Division of Allergy, Pulmonary, Critical Care,
Vanderbilt University Medical Center, Nashville, USA

Atul Malhotra

Pulmonary and Critical Care, University of California
San Diego, La Jolla, California, USA

Muzaffer Metintaş

Department of Chest Diseases, Osmangazi
University School of Medicine, Eskişehir, Turkey

Zeynep Mısırlıgil

Department of Chest Diseases, Ankara University
School of Medicine, Ankara, Turkey

Nesrin Moğulkoç

Department of Chests Diseases, Ege University
School of Medicine, İzmir, Turkey



Turkish Thoracic Journal

Official journal of the Turkish Thoracic Society

Dilşad Mungan

Department of Chest Diseases, Ankara University
School of Medicine, Ankara, Turkey

Gökhan M. Mutlu

Division of Pediatric Critical Care Medicine,
Northwestern University, Chicago, USA

Gül Öngen

Department of Chest Surgery, İstanbul University
Cerrahpaşa School of Medicine, İstanbul, Turkey

Kent E. Pinkerton

University of California, Davis, Center for Health and
the Environment, Davis, USA

Kannan Ramar

Division of Pulmonary and Critical Care Medicine,
Center for Sleep Medicine, Mayo Clinic, Rochester,
MN, USA

Joseph Roca

Instituto de Biología Molecular de Barcelona, CSIC,
Baldri Reixac, Barcelona, Spain

Israel Rubinstein

Section of Pulmonary, Critical Care, Sleep and
Allergy Medicine, Department of Medicine, College
of Medicine, University of Illinois at Chicago,
Chicago, Illinois, USA

Abdullah Sayiner

Department of Chest Diseases, Ege University
School of Medicine, İzmir, Turkey

Z. Toros Selçuk

Department of Chest Diseases, Hacettepe University
School of Medicine, Ankara, Turkey

Nadja Triller

Department of Pulmonary Medicine, University
Pulmonary Clinic Golnik, Golnik, Slovenia

Haluk Türkteş

Department of Chest Diseases, Gazi University
School of Medicine, Ankara, Turkey

E. Sabri Uçan

Department of Chest Diseases, Dokuz Eylül
University School of Medicine, İzmir, Turkey

Karlman Wasserman

Respiratory and Critical Care Physiology and Medicine,
Los Angeles Biomedical Research Institute Harbor-
UCLA Medical Center, Torrance, California, USA

Mark Woodhead

Honorary Clinical Professor of Respiratory Medicine,
Department of Respiratory Medicine, Manchester
Royal Infirmary, Manchester, England



AIMS AND SCOPE

Turkish Thoracic Journal (Turk Thorac J) is the double-blind, peer-reviewed, open access, international publication organ of Turkish Thoracic Society. The journal is a quarterly publication, published on January, April, July, and October and its publication language is English.

Turkish Thoracic Journal started its publication life following the merger of two journals which were published under the titles "Turkish Respiratory Journal" and "Toraks Journal" until 2007. Archives of both journals were passed on to the Turkish Thoracic Journal.

The aim of the journal is to convey scientific developments and to create a dynamic discussion platform about pulmonary diseases. With this intent, the journal accepts articles from all related scientific areas that address adult and pediatric pulmonary diseases, as well as thoracic imaging, environmental and occupational disorders, intensive care, sleep disorders and thoracic surgery. Clinical and research articles, reviews, statements of agreement or disagreement on controversial issues, national and international consensus reports, abstracts and comments of important international articles, interesting case reports, writings related to clinical and practical applications, letters to the editor, and editorials are accepted.

The editorial and publication processes of the journal are shaped in accordance with the guidelines of the International Committee of Medical Journal Editors (ICMJE), World Association of Medical Editors (WAME), Council of Science Editors (CSE), Committee on Publication Ethics (COPE), European Association of Science Editors (EASE), and National Information Standards Organization (NISO). The journal is in conformity with the Principles of Transparency and Best Practice in Scholarly Publishing (doaj.org/bestpractice).

Turkish Thoracic Journal is indexed in PubMed Central, Web of Science - Emerging Sources Citation Index, Scopus, EMBASE, EBSCO, CINAHL, Gale/Cengage Learning, ProQuest, DOAJ, and TUBITAK ULAKBIM TR Index.

Processing and publication are free of charge with the journal. No fees are requested from the authors at any point throughout the evaluation and publication process. All manuscripts must be submitted via the online submission system, which is available at www.turkthoracj.org. The journal guidelines, technical information, and the required forms are available on the journal's web page.

All expenses of the journal are covered by the Turkish Thoracic Society. Potential advertisers should contact the Editorial Office. Advertisement images are published only upon the Editor-in-Chief's approval.

Statements or opinions expressed in the manuscripts published in the journal reflect the views of the author(s) and not the opinions of the Turkish Thoracic Society, editors, editorial board, and/or publisher; the editors, editorial board, and publisher disclaim any responsibility or liability for such materials.

All published content is available online, free of charge at www.turkthoracj.org. Printed copies of the journal are distributed to the members of the Turkish Thoracic Society, free of charge.

Turkish Thoracic Society holds the international copyright of all the content published in the journal.

Editors in Chief:

Prof. Oğuz KILINÇ

Prof. Metin AĞÜN

Address: Turan Güneş Bulvarı, Koyunlu Sitesi No: 175/19 Oran, Ankara, TURKEY

Phone: +90 (312) 490 40 50

Fax: +90 (312) 490 41 42

E-mail: toraks@toraks.org.tr

Publisher: AVES

Address: Büyükdere Cad., 105/9 34394 Mecidiyeköy, Şişli, İstanbul, TURKEY

Phone: +90 212 217 17 00

Fax: +90 212 217 22 92

E-mail: info@avesyayincilik.com

Web page: avesyayincilik.com



INFORMATION FOR THE AUTHORS

Turkish Thoracic Journal (Turk Thorac J) is the double-blind, peer-reviewed, open access, international publication organ of Turkish Thoracic Society. The journal is a quarterly publication, published on January, April, July, and October and its publication language is English.

The aim of the journal is to convey scientific developments and to create a dynamic discussion platform about pulmonary diseases. With this intent, the journal accepts articles from all related scientific areas that address adult and pediatric pulmonary diseases, as well as thoracic imaging, environmental and occupational disorders, intensive care, sleep disorders and thoracic surgery. Clinical and research articles, reviews, statements of agreement or disagreement on controversial issues, national and international consensus reports, abstracts and comments of important international articles, interesting case reports, writings related to clinical and practical applications, letters to the editor, and editorials are accepted.

The editorial and publication processes of the journal are shaped in accordance with the guidelines of the International Council of Medical Journal Editors (ICMJE), the World Association of Medical Editors (WAME), the Council of Science Editors (CSE), the Committee on Publication Ethics (COPE), the European Association of Science Editors (EASE), and National Information Standards Organization (NISO). The journal conforms to the Principles of Transparency and Best Practice in Scholarly Publishing (doaj.org/bestpractice).

Originality, high scientific quality, and citation potential are the most important criteria for a manuscript to be accepted for publication. Manuscripts submitted for evaluation should not have been previously presented or already published in an electronic or printed medium. The journal should be informed of manuscripts that have been submitted to another journal for evaluation and rejected for publication. The submission of previous reviewer reports will expedite the evaluation process. Manuscripts that have been presented in a meeting should be submitted with detailed information on the organization, including the name, date, and location of the organization.

Manuscripts submitted to Turkish Thoracic Journal will go through a double-blind peer-review process. Each submission will be reviewed by at least two external, independent peer reviewers who are experts in their fields in order to ensure an unbiased evaluation process. The editorial board will invite an external and independent editor to manage the evaluation processes of manuscripts submitted by editors or

by the editorial board members of the journal. The Editor in Chief is the final authority in the decision-making process for all submissions.

An approval of research protocols by the Ethics Committee in accordance with international agreements (World Medical Association Declaration of Helsinki "Ethical Principles for Medical Research Involving Human Subjects," amended in October 2013, www.wma.net) is required for experimental, clinical, and drug studies and for some case reports. If required, ethics committee reports or an equivalent official document will be requested from the authors. For manuscripts concerning experimental research on humans, a statement should be included that shows that written informed consent of patients and volunteers was obtained following a detailed explanation of the procedures that they may undergo. For studies carried out on animals, the measures taken to prevent pain and suffering of the animals should be stated clearly. Information on patient consent, the name of the ethics committee, and the ethics committee approval number should also be stated in the Materials and Methods section of the manuscript. It is the authors' responsibility to carefully protect the patients' anonymity. For photographs that may reveal the identity of the patients, releases signed by the patient or their legal representative should be enclosed.

All submissions are screened by a similarity detection software (iThenticate by CrossRef).

In the event of alleged or suspected research misconduct, e.g., plagiarism, citation manipulation, and data falsification/fabrication, the Editorial Board will follow and act in accordance with COPE guidelines.

Each individual listed as an author should fulfil the authorship criteria recommended by the International Committee of Medical Journal Editors

(ICMJE - www.icmje.org). The ICMJE recommends that authorship be based on the following 4 criteria:

- 1 Substantial contributions to the conception or design of the work; or the acquisition, analysis, or interpretation of data for the work; AND
- 2 Drafting the work or revising it critically for important intellectual content; AND
- 3 Final approval of the version to be published; AND
- 4 Agreement to be accountable for all aspects of the work in ensuring that questions related to the accuracy or integrity of any part of the work are appropriately investigated and resolved.

In addition to being accountable for the parts of the work he/she has done, an author should be able to identify which co-authors are responsible for specific other parts of the work. In addition, authors should have confidence in the integrity of the contributions of their co-authors.

All those designated as authors should meet all four criteria for authorship, and all who meet the four criteria should be identified as authors. Those who do not meet all four criteria should be acknowledged in the title page of the manuscript.

Turkish Thoracic Journal requires corresponding authors to submit a signed and scanned version of the authorship contribution form (available for download through www.turkthoracj.org) during the initial submission process in order to act appropriately on authorship rights and to prevent ghost or honorary authorship. If the editorial board suspects a case of "gift authorship," the submission will be rejected without further review. As part of the submission of the manuscript, the corresponding author should also send a short statement declaring that he/she accepts to undertake all the responsibility for authorship during the submission and review stages of the manuscript.

Turkish Thoracic Journal requires and encourages the authors and the individuals involved in the evaluation process of submitted manuscripts to disclose any existing or potential conflicts of interests, including financial, consultant, and institutional, that might lead to potential bias or a conflict of interest. Any financial grants or other support received for a submitted study from individuals or institutions should be disclosed to the Editorial Board. To disclose a potential conflict of interest, the ICMJE Potential Conflict of Interest Disclosure Form should be filled in and submitted by all contributing authors. Cases of a potential conflict of interest of the editors, authors, or reviewers are resolved by the journal's Editorial Board within the scope of COPE and ICMJE guidelines.

The Editorial Board of the journal handles all appeal and complaint cases within the scope of COPE guidelines. In such cases, authors should get in direct contact with the editorial office regarding their appeals and complaints. When needed, an ombudsperson may be assigned to resolve cases that cannot be resolved internally. The Editor in Chief is the final authority in the decision-making process for all appeals and complaints.

When submitting a manuscript to Turkish Thoracic Journal, authors accept to assign the copyright of their manuscript to Turkish Thoracic So-

ciety. If rejected for publication, the copyright of the manuscript will be assigned back to the authors. Turkish Thoracic Journal requires each submission to be accompanied by a Copyright Transfer Form (available for download at www.turkthoracj.org). When using previously published content, including figures, tables, or any other material in both print and electronic formats, authors must obtain permission from the copyright holder. Legal, financial and criminal liabilities in this regard belong to the author(s).

Statements or opinions expressed in the manuscripts published in Turkish Thoracic Journal reflect the views of the author(s) and not the opinions of the editors, the editorial board, or the publisher; the editors, the editorial board, and the publisher disclaim any responsibility or liability for such materials. The final responsibility in regard to the published content rests with the authors.

MANUSCRIPT PREPARATION

The manuscripts should be prepared in accordance with ICMJE-Recommendations for the Conduct, Reporting, Editing, and Publication of Scholarly Work in Medical Journals (updated in December 2017 - <http://www.icmje.org/icmje-recommendations.pdf>). Authors are required to prepare manuscripts in accordance with the CONSORT guidelines for randomized research studies, STROBE guidelines for observational original research studies, STARD guidelines for studies on diagnostic accuracy, PRISMA guidelines for systematic reviews and meta-analysis, ARRIVE guidelines for experimental animal studies, and TREND guidelines for non-randomized public behaviour.

Manuscripts can only be submitted through the journal's online manuscript submission and evaluation system, available at www.turkthoracj.org. Manuscripts submitted via any other medium will not be evaluated.

Manuscripts submitted to the journal will first go through a technical evaluation process where the editorial office staff will ensure that the manuscript has been prepared and submitted in accordance with the journal's guidelines. Submissions that do not conform to the journal's guidelines will be returned to the submitting author with technical correction requests.

Authors are required to submit the following:

- Copyright Transfer Form,
- Author Contributions Form, and
- ICMJE Potential Conflict of Interest Disclosure Form (should be filled in by all contributing authors)

during the initial submission. These forms are available for download at www.turkthoracj.org.

Preparation of the Manuscript

Title page: A separate title page should be submitted with all submissions and this page should include:

- The full title of the manuscript as well as a short title (running head) of no more than 50 characters,
- Name(s), affiliations, and highest academic degree(s) of the author(s),
- Grant information and detailed information on the other sources of support,
- Name, address, telephone (including the mobile phone number) and fax numbers, and email address of the corresponding author,
- Acknowledgment of the individuals who contributed to the preparation of the manuscript but who do not fulfill the authorship criteria.

Abstract: An English abstract should be submitted with all submissions except for Letters to the Editor. Submitting a Turkish abstract is not compulsory for international authors. The abstract of Original Articles should be structured with subheadings (Objective, Material and Methods, Results, and Conclusion). Please check Table 1 below for word count specifications.

Keywords: Each submission must be accompanied by a minimum of three to a maximum of six keywords for subject indexing at the end of the abstract. The keywords should be listed in full without abbreviations. The keywords should be selected from the National Library of Medicine, Medical Subject Headings database (<https://www.nlm.nih.gov/mesh/MBrowser.html>).

Manuscript Types

Original Articles: This is the most important type of article since it provides new information based on original research. The main text of original articles should be structured with Introduction, Material and Methods, Results, and Discussion subheadings. Please check Table 1 for the limitations for Original Articles.

Statistical analysis to support conclusions is usually necessary. Statistical analyses must be conducted in accordance with international statistical reporting standards (Altman DG, Gore SM, Gardner MJ, Pocock SJ. Statistical guidelines for contributors to medical journals. *Br Med J* 1983; 7; 1489-93). Information on statistical analyses should be provided with a separate subheading under the Materials and Methods section and the statistical software that was used during the process must be specified.

Units should be prepared in accordance with the International System of Units (SI).

Editorial Comments: Editorial comments aim to provide a brief critical commentary by reviewers with expertise or with high reputation in the topic of the research article published in the journal. Authors are selected and invited by the journal to provide such comments. Abstract, Keywords, and Tables, Figures, Images, and other media are not included.

Review Articles: Reviews prepared by authors who have extensive knowledge on a particular field and whose scientific background has been translated into a high volume of publications with a high citation potential are welcomed. These authors may even be invited by the journal. Reviews should describe, discuss, and evaluate the current level of knowledge of a topic in clinical practice and should guide future studies. The main text should contain Introduction, Clinical and Research Consequences, and Conclusion sections. Please check Table 1 for the limitations for Review Articles.

Case Reports: There is limited space for case reports in the journal and reports on rare cases or conditions that constitute challenges in diagnosis and treatment, those offering new therapies or revealing knowledge not included in the literature, and interesting and educative case reports are accepted for publication. The text should include Introduction, Case Presentation, and Discussion subheadings. Please check Table 1 for the limitations for Case Reports.

Letters to the Editor: This type of manuscript discusses important parts, overlooked aspects, or lacking parts of a previously published article. Articles on subjects within the scope of the

Table 1. Limitations for each manuscript type

Type of manuscript	Word limit	Abstract word limit	Reference limit	Table limit	Figure limit
Original Article	3500	250 (Structured)	35	6	7 or total of 15 images
Review Article	5000	250	50	6	10 or total of 20 images
Case Report	1000	200	15	No tables	10 or total of 20 images
Letter to the Editor	500	No abstract	5	No tables	No media

journal that might attract the readers' attention, particularly educative cases, may also be submitted in the form of a "Letter to the Editor." Readers can also present their comments on the published manuscripts in the form of a "Letter to the Editor." Abstract, Keywords, and Tables, Figures, Images, and other media should not be included. The text should be unstructured. The manuscript that is being commented on must be properly cited within this manuscript.

Tables

Tables should be included in the main document, presented after the reference list, and they should be numbered consecutively in the order they are referred to within the main text. A descriptive title must be placed above the tables. Abbreviations used in the tables should be defined below the tables by footnotes (even if they are defined within the main text). Tables should be created using the "insert table" command of the word processing software and they should be arranged clearly to provide easy reading. Data presented in the tables should not be a repetition of the data presented within the main text but should be supporting the main text.

Figures and Figure Legends

Figures, graphics, and photographs should be submitted as separate files (in TIFF or JPEG format) through the submission system. The files should not be embedded in a Word document or the main document. When there are figure subunits, the subunits should not be merged to form a single image. Each subunit should be submitted separately through the submission system. Images should not be labelled (a, b, c, etc.) to indicate figure subunits. Thick and thin arrows, arrowheads, stars, asterisks, and similar marks can be used on the images to support figure legends. Like the rest of the submission, the figures too should be blind. Any information within the images that may indicate an individual or institution should be blinded. The minimum resolution of each submitted figure should be 300 DPI. To prevent delays in the evaluation process, all submitted figures should be clear in resolution and large in size (minimum dimensions: 100 × 100 mm). Figure legends should be listed at the end of the main document.

All acronyms and abbreviations used in the manuscript should be defined at first use, both in the abstract and in the main text. The abbreviation should be provided in parentheses following the definition.

When a drug, product, hardware, or software program is mentioned within the main text, product information, including the name of the product, the producer of the product, and city and the country of the company (including the state if in USA), should be provided in parenthe-

ses in the following format: "Discovery St PET/CT scanner (General Electric, Milwaukee, WI, USA)"

All references, tables, and figures should be referred to within the main text, and they should be numbered consecutively in the order they are referred to within the main text.

Limitations, drawbacks, and the shortcomings of original articles should be mentioned in the Discussion section before the conclusion paragraph.

References

While citing publications, preference should be given to the latest, most up-to-date publications. If an ahead-of-print publication is cited, the DOI number should be provided. Authors are responsible for the accuracy of references. Journal titles should be abbreviated in accordance with the journal abbreviations in Index Medicus/ MEDLINE/PubMed. When there are three or fewer authors, all authors should be listed. If there are four or more authors, the first three authors should be listed followed by "et al." In the main text of the manuscript, references should be cited using Arabic numbers in parentheses. The reference styles for different types of publications are presented in the following examples.

Journal Article: Rankovic A, Rancic N, Jovanovic M, et al. Impact of imaging diagnostics on the budget - Are we spending too much? *Vojnosanit Pregl* 2013;70:709-11.

Book Section: Suh KN, Keystone JS. Malaria and babesiosis. Gorbach SL, Barlett JG, Blacklow NR, editors. *Infectious Diseases*. Philadelphia: Lippincott Williams; 2004.p.2290-308.

Books with a Single Author: Sweetman SC. *Martindale the Complete Drug Reference*. 34th ed. London: Pharmaceutical Press; 2005.

Editor(s) as Author: Huizing EH, de Groot JAM, editors. *Functional reconstructive nasal surgery*. Stuttgart-New York: Thieme; 2003.

Conference Proceedings: Bengisson S, Sothemin BG. Enforcement of data protection, privacy and security in medical informatics. In: Lun KC, Degoulet P, Piemme TE, Rienhoff O, editors. *MEDINFO 92. Proceedings of the 7th World Congress on Medical Informatics*; 1992 Sept 6-10; Geneva, Switzerland. Amsterdam: North-Holland; 1992. pp.1561-5.

Scientific or Technical Report: Cusick M, Chew EY, Hoogwerf B, Agrón E, Wu L, Lindley A, et al. Early Treatment Diabetic Retinopathy Study Research Group. Risk factors for renal replacement therapy in the Early Treatment Diabetic Retinopathy Study (ETDRS), Early Treatment Diabetic Retinopathy Study Kidney Int. 2004. Report No: 26.

Thesis: Yılmaz B. Ankara Üniversitesindeki Öğrencilerin Beslenme Durumları, Fiziksel Aktiviteleri ve Beden Kitle İndeksleri Kan Lipidleri Arasındaki İlişkiler. H.Ü. Sağlık Bilimleri Enstitüsü, Doktora Tezi. 2007.

Manuscripts Accepted for Publication, Not Published Yet: Slots J. The microflora of black stain on human primary teeth. *Scand J Dent Res*. 1974.

Epub Ahead of Print Articles: Cai L, Yeh BM, Westphalen AC, Roberts JP, Wang ZJ. Adult living donor liver imaging. *Diagn Interv Radiol*. 2016 Feb 24. doi: 10.5152/dir.2016.15323. [Epub ahead of print].

Manuscripts Published in Electronic Format: Morse SS. Factors in the emergence of infectious diseases. *Emerg Infect Dis* (serial online) 1995 Jan-Mar (cited 1996 June 5): 1(1): (24 screens). Available from: URL: [http:// www.cdc.gov/ncidod/EID/cid.htm](http://www.cdc.gov/ncidod/EID/cid.htm).

REVISIONS

When submitting a revised version of a paper, the author must submit a detailed "Response to the reviewers" that states point by point how each issue raised by the reviewers has been covered and where it can be found (each reviewer's comment, followed by the author's reply and line numbers where the changes have been made) as well as an annotated copy of the main document. Revised manuscripts must be submitted within 30 days from the date of the decision letter. If the revised version of the manuscript is not submitted within the allocated time, the revision option may be cancelled. If the submitting author(s) believe that additional time is required, they should request this extension before the initial 30-day period is over.

Accepted manuscripts are copy-edited for grammar, punctuation, and format. Once the publication process of a manuscript is completed, it is published online on the journal's webpage as an ahead-of-print publication before it is included in its scheduled issue. A PDF proof of the accepted manuscript is sent to the corresponding author and their publication approval is requested within 2 days of their receipt of the proof.

Editors in Chief:

Prof. Oğuz KILINÇ
Prof. Metin AKGÜN
Address: Turan Güneş Bulvarı, Koyunlu Sitesi No: 175/19 Oran, Ankara, TURKEY
Phone: +90 (312) 490 40 50
Fax: +90 (312) 490 41 42
E-mail: toraks@toraks.org.tr

Publisher: AVES

Address: Büyükdere Cad. 105/9 34394 Mecidiyeköy, Şişli, İstanbul, Turkey
Phone: +90 212 217 17 00
Fax: +90 212 217 22 92
E-mail: info@avesyayincilik.com
www.avesyayincilik.com

[Abstract:0007] SS-050 [Accepted:Oral Presentation] [Thoracic Surgery]

Investigation of the Effects of Progressive Muscle Relaxation Training Program on Sleep and Life Quality in Patients Undergoing Pulmonary Resection

Neriman Temel Aksu¹, Abdullah Erdoğan²

¹Department of Physiotherapy and Rehabilitation, Akdeniz University Antalya Health College, Antalya, Turkey

²Department of Thoracic Surgery, Akdeniz University Hospital, Antalya, Turkey

Objectives: The inadequate quality and nature of sleep is a commonly reported problem among hospitalized patients. The purpose of this study is to examine the effects of progressive muscle relaxation training program on sleep quality, sleep state, pain and life quality of patients who underwent pulmonary resection.

Methods: Our study was planned as a single blind prospective randomized controlled trial. The study was conducted on 26 patients who underwent surgery by using posterolateral thoracotomy method. Progressive muscle relaxation training were given to the training group with a therapist 2 times a day. Sleep quality, daytime sleeping, pain, and quality of life were respectively evaluated in the morning before the surgery and 1 week after the surgery by using Pittsburgh Sleep Quality Index, Epworth Sleepiness Scale, visual analogue scale and Euro Quality of Life-5D.

Results: There is no significant difference between preoperative groups in the total The Pittsburgh Sleep Quality Index, Epworth Sleepiness Scale, Euro Life Quality-5D, visual analogue scale scores ($p>0.05$). The intra-group change in the study group showed a significant deterioration in the Euro Life Quality-5D, visual analogue scale scores ($p<0.05$). There was a significant deterioration in total Pittsburgh Sleep Quality Index, Epworth Sleepiness Scale, EQ-5D, visual analogue scale scores in the control group ($p<0.05$). The intergroup analysis showed that patients in the study group had better The Pittsburgh Sleep Quality Index, Epworth Sleepiness Scale and EQ-5D scores after treatment at 1 week ($p<0.05$).

Conclusion: The inadequate quality and nature of sleep is a commonly reported problem among hospitalized patients. Different psychological indicators should be focused on to understand which psychological method is effective in improving postoperative outcomes. Psychological interventions are cheap and are welcomed by patients. Relaxation exercises are not a routinely applied method after pulmonary resection, however they are thought to make contributions to postoperative recovery. It should be tried to reduce the effects of the factors deteriorating sleep and patients who suffer from sleep problems should be identified on time. Progressive muscle relaxation exercises are a practice that improves sleep quality after pulmonary resection and is non-invasive, affordable, effective and easy to apply during the hospitalization period starting from the intensive care phase after surgery. Therefore, the healthcare team should involve such practices in treatment plan.

Keywords: Relaxation therapy, sleep disorders, thoracic surgery, quality of life

[Abstract:0008] EPS-171 [Accepted: E-Poster] [Sleep-related Disorders]

Evaluation of Sleep Quality in Patients Undergoing Pulmonary Resection

Neriman Temel Aksu¹, Abdullah Erdoğan²

¹Department of Physiotherapy and Rehabilitation, Akdeniz University Antalya Health College, Antalya, Turkey

²Department of Thoracic Surgery, Akdeniz University Hospital, Antalya, Turkey

Objectives: The study aims to evaluate the sleep quality of patients who underwent lung resection by posterolateral thoracotomy and to determine the factors affecting their sleep.

Methods: This study was carried out between May 2017 and August 2017 in the Chest surgeon Clinic and 70 patients between the ages of 18-75 who were admitted to surgery with posterolateral thoracotomy were taken. Data were collected using the Personal Information Form, a Form of Factors Affecting Sleep Pattern (FFASP) and the Pittsburg Sleep Quality Index (PSQI). Data analysis was performed at 95% confidence interval using number, percent, mean, standard deviation, student t test, paired t test, Mann-Whitney U, Kruskal Wallis, One way ANOVA and $p<0.05$ was considered significant.

Results: A total of 70 patients participated in the study. The mean age of the patients was 56±9.84. FFASP score average 82.84±4.61; The mean PSQI score was found to be 8.54±0.30. Differences in personal and surgery characteristics of the patients did not significantly affect the FFASP and PSQI score averages ($p>0.05$). The factors that most affect sleep quality were the excessively bright room, the pain, the heat of the room and the lack of air.

Conclusion: Patients with lung resection with posterolateral thoracotomy are experiencing intensive sleep problems after surgery. Sleep quality of patients should be determined after surgery, sleep pattern changes should be identified, evaluations should be performed to evaluate the patient's sleep adequacy.

Keywords: Lung resection, sleep quality, factors affecting sleep pattern

[Abstract:0013] SS-001 [Accepted:Oral Presentation] [Asthma and Allergy]

Last Station in the Eosinophilic Asthma with Chronic Rhinosinusitis and/or Nasal Polyposis March: Eosinophilic Asthma with Thorax CT Findings Associated with Blood Eosinophilia

İnsu Yılmaz¹, Sakine Nazik Bahçecioğlu¹, Murat Türk¹, Nuri Tutar², Fatma Sema Oymak², İnci Gülmez²

¹Department of Chest Diseases, Division of Immunology and Allergy, Erciyes University School of Medicine, Kayseri, Turkey

²Department of Chest Diseases, Erciyes University School of Medicine, Kayseri, Turkey

Objectives: Eosinophilic asthma with chronic rhinosinusitis and/or nasal polyposis is a subphenotype of adult-onset eosinophilic asthma. It is known that blood eosinophil levels in this phenotype patients are highly elevated that is potential for tissue infiltration. Therefore, we aimed to determine the patients who have a blood eosinophil level above 10% and have radiological features which may be related with blood eosinophilia in thorax CT and to investigate their clinical, physiological, laboratory characteristics and prognosis.

Methods: The severe asthmatic patients followed in 2012-2017 years in our clinic were retrospectively evaluated.

Characteristics of the patients		Laboratory, functional and radiological data at the time of diagnosis of patients	
	N=36		N=36
Female gender n (%)	23 (64)	Parameters	Results
Age, mean±SD, years	44.9±11	Blood eosinophil count, mean±SD, %	19±9.9
Current smokers, n (%)	1 (2.8)	Blood eosinophil count, mean±SD, cell/mm ³	1828.6±1428.8
Atopy, n (%)	9 (25)	Total IgE, median (min-max), IU/mL	333.5 (9-1400)
Nasal polyps, n (%)	29 (80.6)	ESR, mean±SD, mm/h	11.4±9.6
NSAIDs hypersensitivity, n (%)	17 (47.2)	CRP, mean±SD, mg/L	5.1±3.2
Asthma duration before diagnosis [median, (min-max)], years	5.5 (1-30)	ANCA positivity	None
Nasal polyposis duration before diagnosis, [median, (min-max)], years	8 (1-20)	ANA positivity	7 (19.4)
Hospitalization due to asthma in last year, mean±SD	0.6±0.8	Urine abnormality	Normal
Admission to emergency room due to asthma in last year, mean±SD	2.1±2.9	FEV1, mean±SD, %	64.5±18.2
Use of systemic corticosteroids due to asthma in last year, mean±SD	2.3±1.8	Thorax CT, n (%)	36 (100)
		Ground-glass opacities	24 (%67)
		Centrilobular nodules	8 (22)
		Bronchial wall thickening	10 (28)
		Alveolar consolidation	12 (33)

SD: standard deviation; NSAID: non-steroid anti-inflammatory drug

SD: standard deviation; IgE: immunoglobulin E; ESR: erythrocyte sedimentation rate; CRP: C-reactive protein; ANCA: antineutrophil cytoplasmic antibody; ANA: antinuclear antibodies; FEV1: forced expiratory volume in first second; Thorax CT: computerized tomography of thorax

Inclusion criteria**Eosinophilic severe asthma**

- 1) Eosinophilia >10%
- 2) Chronic sinusitis and / or nasal polyps
- 3) Patients with pathologic thorax CT findings
- 4) Regularly monitored for at least 1 year

Exclusion criteria:

- 1) thorax CT findings except those with ground- glass opacity, centrilobular nodule, bronchial wall thickening, and airway consolidation which may be the finding of parenchymal and intraluminal eosinophil infiltration
- 2) Those who use systemic steroid within 1 month before thorax CT
- 3) Pulmonary infection and other eosinophilic pulmonary diseases with potential for pulmonary infiltration

Results: Thirty-six patients were included in the study. The mean age was 45 years and women represented 64% of the patients. Most of the patients (78%) did not have smoking history. Chronic rhinosinusitis was present in all patients, and 81% and 47% of the patients had nasal polyps and AERD, respectively. Atopia was present in a quarter of the patients. The characteristics of the patients are presented in Table 1. Nasal polyposis had been diagnosed 8 years ago and asthma 5.5 years ago on average. The laboratory characteristics, functional parameters and thoracic imaging features of the patients are shown in Table 2.

Conclusion: We defined an asthma phenotype with predominant centrilobular nodules and ground glass appearance together with chronic rhinosinusitis/nasal polyps where the upper lobe shows dominant involvement and is accompanied by a thoracic CT appearance consistent with eosinophilic infiltration in this study. We believe this phenotype is the final stage of the allergic march of the eosinophilic severe asthma phenotype with chronic rhinosinusitis/nasal polyps. It is an eosinophilic asthma phenotype that is more severe than the severe asthma phenotypes with AERD and chronic rhinosinusitis/nasal polyps, and is steroid-dependent, has high eosinophil values, and atopy is less common. In our study also have been shown that this asthma phenotype did not evolve into eosinophilic granulomatous polyangiitis vasculitic form in the following years and was a specific asthma phenotype.

Keywords: Eosinophilic asthma, nasal polyposis, chronic rhinosinusitis, aspirin-exacerbated respiratory disease, thorax CT, phenotype

[Abstract:0014] EPS-055 [Accepted: E-Poster] [COPD]

Ranitidine-Induced Anaphylaxis in a Patient with Acute COPD Exacerbation

İnsu Yılmaz, Murat Türk

Department of Chest Diseases, Division of Allergy and Clinical Immunology, Erciyes University Faculty of Medicine, Kayseri, Turkey

Ranitidine is a well-tolerated H₂-receptor antagonist commonly used in peptic ulcer treatment and stress ulcer prophylaxis. Anaphylaxis is rarely observed with ranitidine. We report the case of a patient who developed anaphylaxis after intravenous injection of ranitidine for acute COPD exacerbation. This article underlines the importance of awareness that in COPD acute exacerbation treatment, ranitidine, which is usually administered with methylprednisolone, also has anaphylaxis potential.

Keywords: Drug allergy, ranitidine, anaphylaxis

[Abstract:0020] EPS-041 [Accepted: E-Poster] [Clinical Problems - Pulmonary Vascular Diseases]

Takayasu Arteritis, Pulmonary Vascular Involvement

Nazlı Deniz Atik¹, Nesrin Moğulkoç¹, Selen Bayraktaroğlu², Yasemin Kabasakal³

¹Department of Pulmonology, Ege University School of Medicine, İzmir, Turkey

²Department of Radiology, Ege University School of Medicine, İzmir, Turkey

³Department of Romatology, Ege University School of Medicine, İzmir, Turkey

Takayasu arteritis is a chronic large-vessel vasculitis which involves primarily the aorta and its main branches, with granulomatous inflammation of vessel walls. It is predominantly seen in young women in the third decade of life. At the onset of disease, constitutional symptoms are seen; latterly various symptoms manifest according to the location of the involved

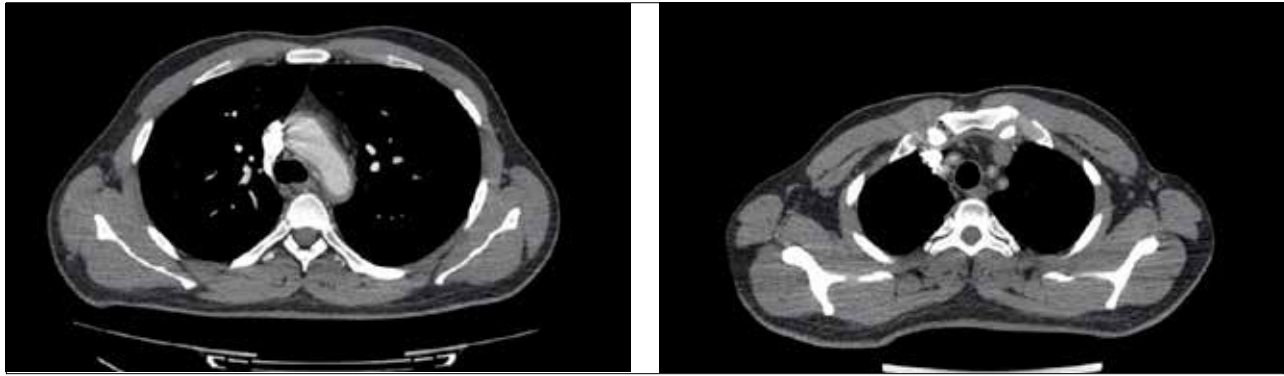


Figure 1. BT Scanning

vessels. We present a case of Takayasu arteritis with pulmonary vascular involvement. A thirty years old man, with no previous medical history, presented with a dry cough of one year's duration and haemoptysis for one month. He was hospitalized for further examination. His CT showed diffuse thickening of vessel walls in the arch of the aorta and its major branches, with intermittent thickening of pulmonary arteries. His pulmonary function tests and CO₂ diffusion tests were normal. His inflammatory markers (serum amyloid A and CRP) were high. He was diagnosed as having Takayasu arteritis. PET/CT examination was performed to assess disease activity; there was vessel wall thickening and narrowing of the lumen of the left subclavian artery, and a filling defect and luminal narrowing in the pulmonary arteries. We plan immunosuppressive therapy with cyclophosphamide and methylprednisolone.

Keywords: Takayasu arteritis, pulmonary vascular involvement, haemoptysis

[Abstract:0021] PS-239 [Accepted:Poster Presentation] [Tobacco Control]

Smoking Cessation Clinic: Our One-Year Results

Sibel Sultan Baysal

Department of Chest Diseases, Smoking Cessation Unit, Health Sciences University, Adana, Turkey

Objectives: Smoking addiction is considered as a disease that should be treated across the world. In this study, demographic distribution, smoking cessation success rate, and factors affecting smoking cessation were examined in patients who consulted to Adana Numune Hospital between 2016 and 2017.

Methods: The data of this cross-sectional study were obtained through a questionnaire applied on 483 patients who consulted smoking cessation outpatient clinic between the years of 2016 and 2017. The data were analyzed by using SPSS software and mean, standard deviation, frequency values, and Chi-square test were used. The value of $p < 0.05$ was accepted as significant.

Results: Of the cases, 307 (63.6%) were male and 176 (36.4%) were female. The mean age was 38 ± 12.01 years (min=18, max=76). Of patients whose mean smoking pack-year was 28.06 ± 4.41 , 382 (79.1%) were married, 164 (34.0%) were primary school graduate, 148 (30.6%) were high school graduate, 85 (17.6%) were university graduate, 68 (14.1%) were secondary school graduate, and 18 (3.7%) were illiterate. Considering the distribution of jobs, 279 of them were self-employed, which was the highest distribution. Then, it was followed by 125 housewives, 52 civil servants, 18 farmers, and 9 students. The mean age to start smoking was found to be 17.07 ± 4.41 years. 441 patients (91.3%) were given behavioral education (BE) +bupropion, 23 (4.8%) were given varenicline+BE, and 19 (3.9%) were given NRT+BE. At the end of one-year follow-up, it was found that 41.7% gave up smoking and 58.2% continued to smoke. While 78.1% did not have any comorbid diseases, 21.9% had comorbid diseases. The most common comorbid disease was COPD at the rate of 7.2%, which was followed by COPD at the rate of 6.0% and then diabetes mellitus at the rate of 4.6%. Although the rate of smoking cessation was high in those who were male, married, and self-employed, and in those not having comorbid diseases, the difference was not statistically significant ($p > 0.05$). It was observed that as the educational level increased, the success of smoking cessation also increased, but the difference was not statistically significant ($p > 0.05$).

Conclusion: Smoking cessation is a difficult and time-consuming process. It has been found that demographic data such as gender, education, and marital status are not effective. In addition to BE, appropriate pharmacological treatment should be given to all smokers.

[Abstract:0023] EPS-235 [Accepted: E-Poster] [Thoracic Surgery]

Spontaneous Pneumomediastinum After Seizure

Cenk Balta¹, Şamil Günay², İbrahim Can Kürkçüoğlu²¹Şanlıurfa Training and Research Hospital, Şanlıurfa, Turkey²Harran University School of Medicine Hospital, Şanlıurfa, Turkey

Pneumomediastinum is free air of mediastinum and commonly in relation with respiration and gastrointestinal system organs perforation. Primary spontaneous pneumomediastinum is rare, benign and the reason is periferical pulmonary alveolar rupture. We present a SPM case which is detected after a tonic-clonic seizure.

Keywords: Epilepsy, pneumomediastinum, thorax

[Abstract:0024] EPS-271 [Accepted: E-Poster] [Thoracic Surgery]

Mediastinal hamartoma, Extremely rare presentation

Gökay Reyhan¹, Yasin Ekinci²¹Department of Thoracic Surgery, Medical Sciences University Sultan Abdülhamid Han Training and Research Hospital, İstanbul, Turkey²Denizli Goverment Hospital, Denizli, Turkey

Introduction: We report here a case of mediastinal hamartoma because of its extreme rarity.

Case Presentation: A 63 year-old male was referred to us for evaluation of difficulties when swallowing foods. Computed tomography (CT) of his chest showed a solid lesion with calcification measuring 48x53 mm in the posterior mediastinum. Magnetic Resonance Imaging (MRI) of his chest showed a lesion measuring 58x43x44 mm which pushed esophagus lateraly. Positron emission tomography (PET-CT) didn't give any clue for malignancy. Radiology didn't find appropriate for needle aspiration. We applied right thoracotomy and excised the hole mass. Pathologic examination showed us diagnosis of chondroid hamartoma. Hamartomas are benign tumors that are most often found in the liver and lungs. It accounts for approximately 8% of all pulmonary neoplasms. Most hamartomas are located in the lung parenchyma and only a few are found in the bronchi. Hamartoma occurring in the mediastinum is extremely rare. These are benign tumors with a peak incidence in the seventh decade of life and they are more common in males. The most common location is the lung parenchyma, just beneath the pleura, and usually it is solitary, but can be multiple. Radiologically a characteristic popcorn pattern of calcification is seen in one-third of the cases.

Conclusion: Pulmonary hamartoma is a relatively common lesion that is usually discovered as an incidental, rounded focus of radio opacity on a routine chest film. Needle aspiration is appropriate in determining the diagnosis of hamartomas. They can rarely became giant lesions. Theatment is surgical operation.

Keywords: Mediastinal hamartoma, rare, swallowing difficulty

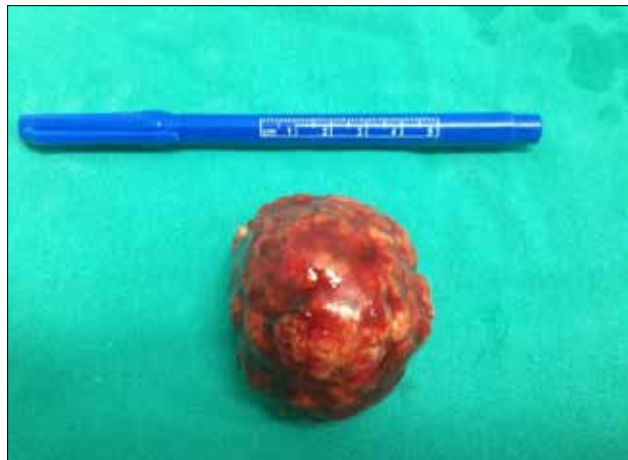


Figure 1. Operation Material

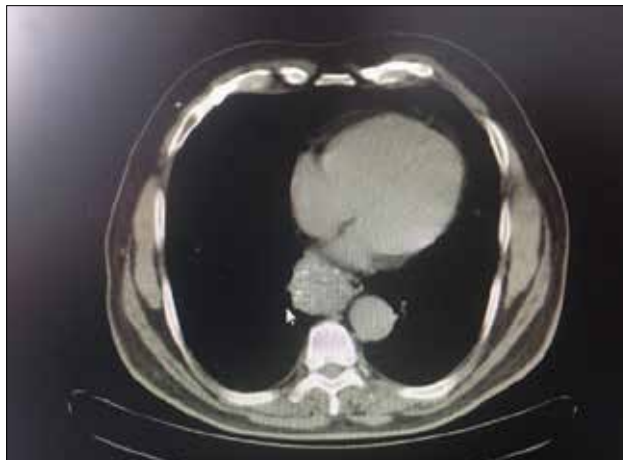

Figure 2. Thorax CT

[Abstract:0028] EPS-144 [Accepted: E-Poster] [Respiratory Failure and Intensive Care]

The Effect of Positive Fluid Balance on Lung and Extrusion in Intensive Care Patients in Intensive Care

Deniz Sönmez

Akdeniz University School of Medicine, Antalya, Turkey

Objectives: The aim of this study was to evaluate the demographic information of patients who require mechanical ventilation support for at least 72 hours in the Intensive Care Unit I-II-III, Internal Medicine Intensive Care and Thoracic Surgery Intensive Care Unit of Akdeniz University Medical Faculty Hospital and clinically diagnosed with sepsis and septic shock, ventilation periods, fluid balances and mortality.

Methods: Demographic data, medications, invasive mechanical ventilation duration and parameters, sedation support, vital findings, daily blood gas and laboratory values, and daily follow-up assessments were evaluated from the patient's medical files, nurse observations, hospital and intensive care unit electronic registration files (positive, negative, equilibrium). APACHE II, SOFA score and GCS values were recorded.

Results: Twenty-six (52.00) male (E) and 24 (48.00) female (K) of the total 50 patients included in the study. The mean age was 66.58 ± 16.25 . Chronic disease was detected in 40 (80%) patients and 13 (13.50%) of them were hypertension, 11 (27.50%) diabetes mellitus, 8 (20.00%) COPD, 8 (20%) was found. When the fluid balances of 50 patients were examined, 42 (84.00%) were positive, 6 (12.00%) were negative and 2 (4.00%) were balanced. Of these 50 patients, 42 (84.00%) were not fed, 1 (2.04%) was enteral, and 6 (12.24%) were parenteral. Patients' stay in intensive care unit was found to be 9.80 ± 7.14 days. The APACHE II score was 25.99 ± 4.68 , the GKS score was 6.73 ± 2.21 , and the SOFA score was 7.85 ± 1.86 . Thirty-seven patients (82.23%) were enrolled in the intensive care unit and eight (17.78%) were served emergency services. It was found that ARDS developed in 11 (22%) of 50 patients included in the study.

Conclusion: Mechanical ventilation is an indispensable treatment method for intravenous fluid therapy sepsis and septic shock patients in intensive care units, and increases risk of complication and mortality rate. In our study, patients with positive fluid balance were found to have longer mechanical ventilation and mortality than patients with negative fluid balance, and 11 of the positive fluid-loaded patients developed ARDS.

Keywords: Intensive care, mechanical ventilation, sepsis-septic shock, fluid balance

[Abstract:0032] EPS-044 [Accepted: E-Poster] [COPD]

Blood Eosinophilia in the Exacerbation of Chronic Obstructive Pulmonary Disease

Figen Aslantaş, İnci Gülmez

Department of Chest Diseases, Erciyes University School of Medicine, Kayseri, Turkey

Objectives: Although the pathogenesis of chronic obstructive pulmonary disease (COPD) is classically neutrophilic and Th1-mediated, various phenotypes of COPD are defined. Eosinophilic inflammation was observed in blood and sputum cultures of patients with stable and exacerbated COPD. It was hypothesized that 'eosinophilic' COPD patients could constitute a different phenotype that would give positive responses to ICS and systemic steroids. This study was planned for the purpose of investigating the state of blood eosinophilia in patients consulting with the exacerbation of COPD.

Methods: Electronic records of patients with severe COPD exacerbation, who needed to be hospitalized, in a 5-year period from January 2011 to December 2014 were evaluated retrospectively. Their blood eosinophilia values were examined and put into 3 groups as: 1st group with eosinophilia value of $<150/\text{mm}^3$, 2nd group with eosinophilia value of 150-300, and 3rd group with eosinophilia value of $>300/\text{mm}^3$.

Results: A total of 1415 patients who were hospitalized due to COPD exacerbation in Erciyes University Hospital between January 2011 and December 2014 were detected. Blood eosinophilia value was found to be $>150/\text{mm}^3$ in 209 of these patients. The number of detected patients was 1206 in the 1st group, 168 in the 2nd group, and 41 in the 3rd group.

Discussion: The 1st group blood eosinophilia of $<150/\text{mm}^3$ was found to be in 1206 patients (86.0% of all patients), the 2nd group blood eosinophilia of $150\text{-}300/\text{mm}^3$ was found in 168 patients (11.8% of all patients), and the 3rd group blood eosinophilia of $>300/\text{mm}^3$ was found in 41 patients (2.2% of all patients).

Conclusion: COPD attacks are associated with decreased lung functions, impaired quality of life, hospitalization, and increased mortality. The exacerbations of COPD are costly for health care systems. Therefore, the prevention of exacerbations is a key target in the management of COPD. Only 2.2% of COPD patients have eosinophilic exacerbation of $>300/\text{mm}^3$. In these patients with $>300/\text{mm}^3$ eosinophilia, the frequency of exacerbations is examined prospectively.

Keywords: COPD, eosinophilia, exacerbation

[Abstract:0036] SS-126 [Accepted:Oral Presentation] [Lung and Pleura Malignancies]

Electrophysiological and Clinical Findings in Cases of Polyneuropathy due to Chemotherapy in Lung Cancer Treatment

Şenay Aydın

Department of Neurology, Yedikule Chest Diseases and Thoracic Surgery Training and Research Hospital, İstanbul, Turkey

Objectives: Toxic neuropathies due to chemotherapy regimens in lung cancer treatment are frequently observed in clinical practice. In patients, it can be more observed axonal-type polyneuropathy in which thick fibers including sensory, motor or both modalities or thin fibers are affected. In our study, it was aimed to determine electrophysiologically the presence of polyneuropathy, type and clinical symptoms in patients with lung cancer who underwent electromyography for the diagnosis of toxic neuropathy. In our study, it was aimed to identify common points between clinical symptoms and presence of polyneuropathy electrophysiologically and type of polyneuropathy in patients with lung cancer who underwent electromyography with pre-diagnosis of toxic neuropathy.

Methods: In this study, it was retrospectively reviewed that demographic data, symptoms, neurological examinations and electromyography findings of patients diagnosed with lung cancer who were referred to the neurology department of Yedikule Chest Diseases and Chest Surgery Training and Research Hospital between January 2012 and December 2017 and underwent electromyography examinations for the diagnosis of toxic neuropathy. Patients with neuropathy who had begun to study chemotherapy treatment and who did not have accompanying disease that could cause neuropathy were included. Patients who had neuropathy clinic after chemotherapy treatment and who did not have concomitant disease that could cause neuropathy were included in the study.

Results: A total of 371 (Male:315, 84.9%) patients were included in the study. Polyneuropathy was detected clinically and electrophysiologically in 250 (67.4%) of the patients with neuropathy symptoms. Sensory fibers in 160 (43.1%) patients, motor fibers in 5 (1.3%) patients and both sensory and motor fibers in 85 (22.9%) patients with presence of electrophysiologically polyneuropathy were observed to be affected. When the symptoms of these patients are evaluated, it was observed that positive sensory symptoms in 203 (54.7%), negative sensory symptoms in 247 (66.6%) and motor symptoms in 81 (21.8%). There were positive sensory symptoms in 70 (57.9%), negative sensory symptoms in 58 (47.9%) and motor symptoms in 10 (8.3%) of the patients with symptoms of polyneuropathy not supported by electromyographic findings. In the case of polyneuropathies confirmed by electromyography, motor and negative sensory symptoms were found to be statistically significant but there was no difference in terms of positive sensory symptoms (respectively, $p:0.001$, $p:0.001$, $p:0.437$).

Conclusion: Chemotherapy-induced toxic neuropathy can affect different fibers and can come into conflict with different clinical tables. In chemotherapy-treated patients with lung cancer, follow-up of clinical symptoms during treatment may provide early detection of neuropathy and early taken of measures, and therefore this can significantly affect the morbidity of the disease.

Keywords: Chemotherapy regimens, electromyography, lung cancer, toxic neuropathies

[Abstract:0038] SS-016 [Accepted:Oral Presentation] [COPD]

The Effect of Fatigue and Dyspnoea on the Quality of Life in Patients with COPD

Naile Alankaya¹, Hülya Bulut²

¹Department of Nursing, Faculty of Health Sciences, Cyprus Science University, Girne, TRNC

²Health Sciences University, Dr. Suat Seren Chest Diseases and Surgery Training and Research Hospital, University of Health Sciences, İzmir, Turkey

Objectives: Chronic Obstructive Pulmonary Disease (COPD) is a progressive, not fully reversible, but preventable and treatable chronic failure. Accurate identification of symptoms of dyspnea and fatigue in COPD is important in planning medical treatment, providing effective care, and increasing quality of life. The aim of this study was to determine the effect of dyspnea and fatigue on the quality of life in patients with COPD.

Methods: This cross-sectional and descriptive study was conducted with COPD patients in Dr. Suat Seren Chest Diseases and Surgery Training and Research Hospital between October-December 2017. 304 patients agreed to participate and were included in the study. Data were collected using the "Patient Identification Information Form", "Modified Medical Research Council Dyspnea Scale (mMRC)", "COPD and Asthma Fatigue Scale (CAFS)" and "SF-36 Quality of Life Scale". Necessary written permissions were obtained from the local ethics committee, the hospitals where the study was conducted, and the patients who voluntarily agreed to participate in the study. All analyses were performed using SPSS (Chicago, Illinois) for Windows version 22.0. Analysis of data using the Kolmogorov-Smirnov test indicated a non-normal distribution, and therefore non-parametric tests were used. Data were analyzed using counts, percentage distribution, means, the Mann-Whitney U test and the Kruskal-Wallis test.

Results: The patients mean age was 64.46±1.25 years. Of the respondents were found; 62.5% were men, 37.2% a primary school graduates, 71.4% had used cigarettes, and 76.0% did not any exercise/exercise. In our study, the mean mMRC score was 2.81±1.16 and the mean CAFS score was 37.30±8.75. The mean of the SF-36 subscales scores were physical function 15.96±5.32, physical role 4.98±1.53, pain 5.52±1.97, general health perception 11.09±3.27, vitality 12.63±3.70, social function 5.68±3.70, mental role 3.70±1.14 and mental health 17.71±3.84. It was found that there was a negative correlation between all subscales of SF 36 with mMRC and CAFS mean scores ($p < 0.01$). In our study, men experienced more dyspnea than women ($t = 5.86$; $p = 0.00$), but there was no relationship between fatigue and gender. Those who could not work due to illness were found to have higher fatigue than those who did not work with non-COPD ($p = 0.002$; $p < 0.05$).

Conclusion: These data show a relationship between fatigue and dyspnea and quality of life in patients COPD.

Keywords: Chronic Obstructive Pulmonary Disease (COPD), dyspnea, fatigue, quality of life

[Abstract:0047] PS-211 [Accepted:Poster Presentation] [Asthma and Allergy]

The Effect of Vitamin D Deficiency on Asthma

Fatih Üzer¹, Ömer Özbudak²

¹Department of Chest Diseases, Discipline of Intensive Care, Marmara University School of Medicine, İstanbul, Turkey

²Department of Chest Diseases, Akdeniz University School of Medicine, Antalya, Turkey

Objectives: The relationship between vitamin D and the development of asthma is still investigated. Some researchers have obtained data about that vitamin D supplement is a cause of asthma. In some studies, a negative correlation has been demonstrated between vitamin D and asthma. Because of the presence of a conflicting relationship between vitamin D and asthma, we aimed to investigate the effects of serum vitamin D and vitamin D deficiency on clinical features of asthma in this study.

Methods: This research is a retrospective study. The study included patients at the age of 18 years and over, who were admitted to the Outpatient Clinic of Chest Diseases in Akdeniz University Medical Faculty Hospital between January 2014 and December 2014 and who were diagnosed with asthma according to the GINA guideline. Patients diagnosed with COPD, bronchiectasis, pneumonia, and tuberculosis were not included in the study. Data on age, sex, respiratory function test results, smoking history, bronchodilator drugs that they used, comorbid diseases, and total numbers of attacks and hospitalizations in a year were recorded for all patients who were included in the study. Serum vitamin D levels of the patients were measured. Asthma control test was performed in accordance with the GINA 2014 guideline. The diagnosis of asthma exacerbation was defined as the occurrence of progressive dyspnea, coughing, wheezing, or chest tightness in an asthma patient and coexistence of impairments in respiratory function tests (RFT) such as decreased PEF and FEV1 with these complaints according to the GINA guideline.

Results: A total of 2445 patients with the diagnosis of asthma were scanned. Of these patients, 158 patients fulfilling inclusion criteria for the study were included. The main features of patients are presented in Table 1. The drug combination most fre-

quently used by patients was found to be the combination of inhaler corticosteroid+long-acting beta2 agonist+montelukast. The sequence of the patients according to their vitamin D levels is shown in Figure 1. Vitamin D level was sufficient (>30 ng/mL) in 27 patients (17.08%), but insufficient in 131 patients (82.92%). The patients were divided into two groups as those with sufficient vitamin D level and those with insufficient vitamin D level. While FEV1 (lt) and FVC (lt) were statistically significantly high in the group with sufficient vitamin D level, no statistically significant difference was found between two groups in terms of all other parameters that were examined (Table 2). When the patients were put into 4 groups according to their vitamin D levels, it was observed that as vitamin D levels decreased, the number of hospitalization increased significantly. No statistically significant difference was detected in all other parameters (Table 3).

Conclusion: As a result of this study, it was found that serum vitamin D level and its deficiency in asthma patients were not different from those in the control group, but they were significantly associated with decreased pulmonary functions and hospitalization. Further well-planned studies are needed for revealing the effect of vitamin D on asthma control.

Keywords: Asthma, asthma control, vitamin D

[Abstract:0048] SS-035 [Accepted:Oral Presentation] [Respiratory Failure and Intensive Care]

The Correlation Between PaO₂/FiO₂ and SpO₂/FiO₂ Ratios in Patients Diagnosed with ARDS in Respiratory Intensive Care Unit

Esra Bahçivan¹, Pervin Korkmaz Ekren¹, Hatice Uluer², Feza Bacakoğlu¹

¹Department of Chest Diseases, Ege University Hospital, İzmir, Turkey

²Department of Biostatistics and Medical Informatics, Ege University Hospital, İzmir, Turkey

Objectives: While Acute Respiratory Distress Syndrome (ARDS) is uncommonly seen in intensive care units, its treatment and management are difficult and its mortality is high. The PaO₂/FiO₂ ratio is used for both diagnosing ARDS and determining its severity and it requires to take arterial blood gas, which is an invasive method. In this study, it was aimed to investigate the correlation between the PaO₂/FiO₂ ratio and the SpO₂/FiO₂ ratio, which is based on recording oxygen saturation in non-invasive pulse oximeter, in patients diagnosed with ARDS.

Methods: In this study, patients who were followed for at least 24 hours in the Respiratory Intensive Care Unit at Ege University Medical Faculty, Department of Chest Diseases between January 2015 and December 2017 were evaluated retrospectively. In patients diagnosed with ARDS according to the Berlin definition, the correlation between the SpO₂/FiO₂ ratios that were recorded at the time of diagnosis and in the first 4 days and the PaO₂/FiO₂ ratios that were calculated from arterial blood gases taken at the same hours was evaluated. The place of the SpO₂/FiO₂ ratio in the classification of ARDS and in the prediction of mortality was investigated.

Results: The most common cause of ARDS was found to be pneumonia in 39 patients (94.9%) (the median age: 70.5 years, 41% female, the median APACHE II score: 24) included in the study. Invasive mechanical ventilation was performed to 24 cases (61.5%). In the analyses, a significant correlation was detected between all PaO₂/FiO₂ ratios and SpO₂/FiO₂ ratios (p<0.001, r=0.87). According to the ARDS severity classification that was carried out with PaO₂/FiO₂ ratios at the beginning, the SpO₂/FiO₂ ratios were also found to be significantly different between the groups (p<0.001). The SpO₂/FiO₂ ratios that can be used for differentiating severe, moderate, and mild ARDS groups according to the PaO₂/FiO₂ ratios were found to be 125 (AUC:0.917, p<0.001, sensitivity 83.7%, specificity 86.9%, positive predictive value 83%, negative predictive value 86%) and 225 (AUC:0.886, p<0.001, sensitivity 75.4%, specificity 87.1%, positive predictive value 92%, negative predictive value 64%), respectively. The mortality rate was 69.2% in the study group. In the classification carried out according to both PaO₂/FiO₂ and SpO₂/FiO₂ ratios, the highest mortality rates were found in the groups with severe ARDS, but the differences between the groups were not statistically significant (p=0.206, p=0.411, respectively).

Conclusion: It has been demonstrated that non-invasively calculated SpO₂/FiO₂ ratio can be safely used instead of PaO₂/FiO₂ ratio for ARDS classification and for the prediction of mortality.

Keywords: ARDS, PaO₂/FiO₂, SpO₂/FiO₂

[Abstract:0052] PS-048 [Accepted:Poster Presentation] [Lung and Pleura Malignancies]

Presentation of A Small-Cell B-Cell Non-Hodgkin's Lymphoma Case with Endobronchial and Lung Parenchymal Involvement

Betül Cengiz, Neşe Dursunoğlu

Department of Chest Diseases, Pamukkale University School of Medicine, Denizli, Turkey

Introduction: Lymphomas are clonal tumoral formations that are derived from lymphocytes (T/B) or NK (natural killer) cells, which are among the cells of the immune system. In lymphomas, lung parenchymal involvement and endobronchial spread are rarely encountered. While the rate of lung parenchymal involvement is 12% in Hodgkin's lymphoma (HL), it is 4% in non-Hodgkin's lymphoma (NHL).

Case Presentation: A 40-year-old male patient was admitted to the outpatient clinic of chest diseases due to the complaints of fatigue, coughing, and dyspnea that were continuing for one month. In the physical examination, the results of all system examinations were found to be normal. His blood pressure was 110/70 mm Hg, pulse was 80/min, respiratory rate was 18, and temperature was 36.5°C. No abnormality was found in his medical history and familial history. The history of smoking was evaluated as 30 packs/year. His PA chest radiography revealed a nodular density measured as 40x45 mm in the lower medial zone of the right lung (Figure 1). Upon that, thoracic CT was performed to the patient and it revealed lymph nodes, the largest of which was 18x12 mm, with fatty hilus in their centers and with the localizations of 2R, 4R, 4L, 6, and 7 stations in the mediastinum. A 45x43 mm well-circumscribed solid mass was detected in the lower lobe superior segment of the right lung (Figure 2). Patchy ground-glass areas were observed in the upper lobe posterior segment of the right lung. PET CT was ordered for the patient due to the prediagnosis of primary lung malignancy. In PET-CT, a 43x40 mm lesion in posterobasal segment of the right lung lower lobe (SUV max:8.8), lymphadenopathy, the largest of which was about 17x15 mm in the right upper paratracheal region (SUV max: 1.4), lesions in the right iliac crest posterior (SUV max: 7.2), in the right iliac crest inferoposterior (SUV max:5.6) and in the right acetabulum inferior (SUV max 8.1) were detected (Figure 3).

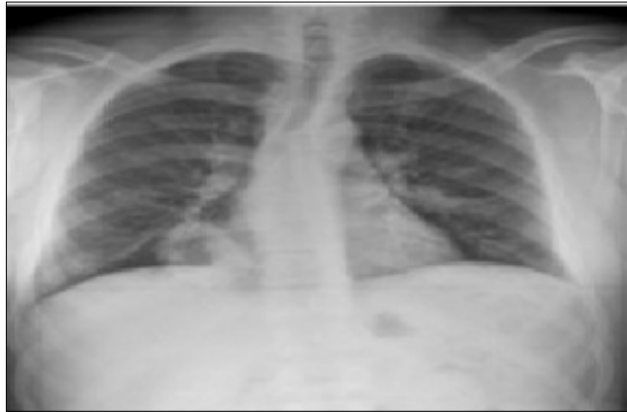

Figure 1.

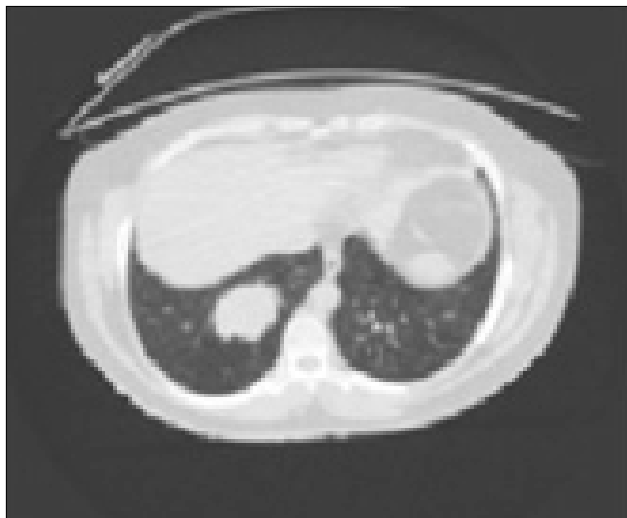


Figure 2.

In PET-CT, a 43x40 mm lesion in posterobasal segment of the right lung lower lobe (SUV max:8.8), lymphadenopathy, the largest of which was about 17x15 mm in the right upper paratracheal region (SUV max: 1.4), lesions in the right iliac crest posterior (SUV max: 7.2), in the right iliac crest inferoposterior (SUV max:5.6) and in the right acetabulum inferior (SUV max 8.1) were detected (Figure 3).

Conclusion: Fiberoptic bronchoscopy was performed to the patient and blunting and edema were observed in the carina between the upper lobe segments of the right lung. Biopsy was taken from this area. The patient, who did not have an apparent endobronchial change, was performed transthoracic fine-needle aspiration biopsy from the 43x40 mm mass in the lower lobe superior segment of the right lung for diagnostic purpose. The results of both biopsies, which were bronchoscopic biopsy of carina between the segments of the right lung upper lobe and transthoracic fine-needle aspiration biopsy, were reported as small-cell B-cell non-Hodgkin's lymphoma. The patient was referred to the department of

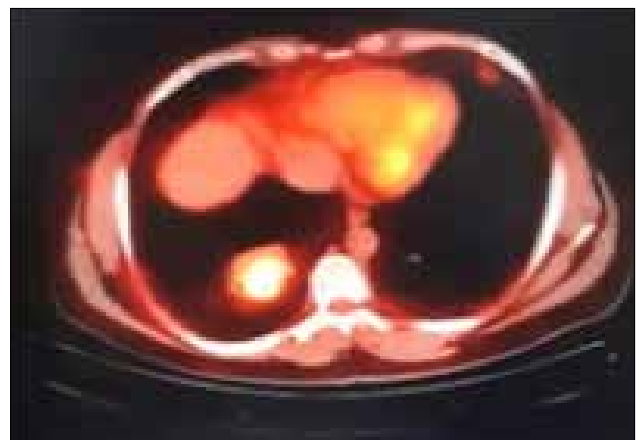

Figure 3.

hematology for chemotherapy and he is still followed up. This case has been presented because endobronchial and parenchymal involvements of non-Hodgkin's lymphoma are rarely encountered.

Keywords: Non-hodgkin's lymphoma, endobronchial lesion, lung parenchymal involvement

[Abstract:0054] SS-019 [Accepted:Oral Presentation] [Diagnostic Methods]

Does the Decrease in KCO Go Typically with DLCO Decrease in Obstructive Pulmonary Diseases? the Relationship With DLCO, KCO, VA and VA/TLC in Patients with COPD

Gökhan Erdoğan¹, Esra Sönmez¹, Hişam Alahdab¹, Mehmet Atilla Uysal², Kemal Tahaoğlu¹

¹Anadolu Medical Center Hospital, Kocaeli, Turkey

²Health Sciences University, Yedikule Chest Diseases and Thoracic Surgery, Training and Research Hospital, İstanbul, Turkey

Objective: DLCO is a measure of conductance the CO transfer from inhaled air to the red blood cells in capillaries. The alveolar volume (VA) can be considered the number of contributing alveolar units and is measured during the single breath DLCO with by use of a tracer gas (e.g., helium). Kroug factor (KCO) is an index of the efficiency of alveolar transfer of carbon monoxide. We aimed to evaluate the relationship between the results of single breath diffusion capacity and body plethysmographic lung volumes in COPD patients.

Methods: Patients with pulmonary disease who were admitted to our clinic between 2008-2017 and diagnosed as COPD were studied retrospectively. The patients with ≥ 40 years old, $< 70\%$ post-bronchodilator FEV1/FVC and ≥ 10 smoking pack-year were accepted as COPD. 160 patients who had spirometry and single breath diffusion capacity test, measured by body plethysmography and had adjusted blood Hb (gr/dL) and COHb%, who fulfilled the criteria A and B of spirometry and diffusion test and who had no other comorbidity were studied. Patients with COPD were categorized as 32 mild (20.0%), 79 moderate (49.3%) and 49 severe (31,7%) according to FEV1 percentages.

Results: Of 160 patients, 138 (86.3% were male). Mean age was 65.22 ± 10.63 . Although the DLCO values significantly decreased from mild to severe COPD ($p < 0.05$, $p < 0.001$, $p < 0.001$, respectively), there was no significant decrease among the KCO values regarding COPD severity ($p > 0.05$, $p > 0.05$, $p > 0.05$, respectively). VA/TLC-PI value significantly decreased as COPD severity increased ($p < 0.001$, $p < 0.001$, $p < 0.001$, respectively). In all patients, there was a significant negative correlation between VA/TLC-PI and RV/TLC-PI ($r = -0.71$, $p < 0.001$). There was also a significant correlation between VA/TLC-PI and FEV1 ($r = 0.68$, $p < 0.001$). Multiple linear regression models were used to identify independent predictors (FEV1, FEV1/FVC, VA, VA/TLC-PI, RV/TLC-PI, TLC-PI%, and KCO for dependent DLCO or DLCO for dependent KCO variables) of DLCO and KCO as dependent variables. The model fit was assessed using appropriate residuals and goodness of fit statistics. The full model R^2 for DLCO was significantly greater than zero ($R^2 = 0.96$, $p < 0.001$). The other linear regression model with dependent variable KCO was also significant ($R^2 = 0.94$, $p < 0.001$).

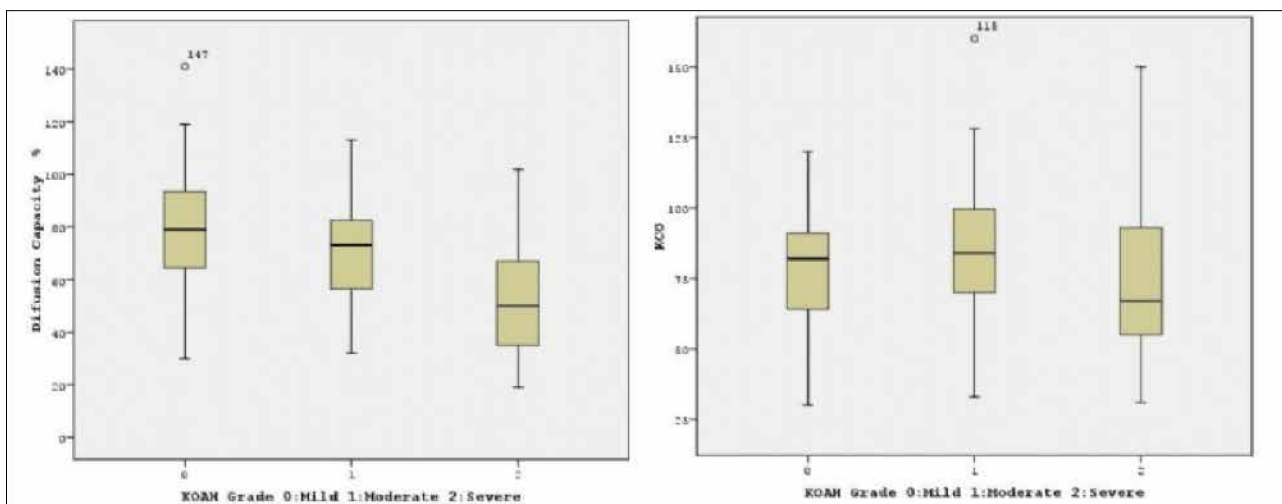


Figure 1. Between Groups DLCO and KCO Chart

Table. Spirometry, Diffusion and Body Plethysmograph values according to COPD severity.

	I (FEV ₁ ≥80%) Hafif KOAH (n=32)	II (50≥FEV ₁ >80) Orta KOAH (n=79)	III (FEV ₁ <50) Ağır KOAH (n=49)	Toplam (n=160)	P
FVC (ml)	3983,13±787,05	3100,00±821,97	2438,16±639,35	3073,93±931,93	I-II p<0,001 II-III p<0,001 I-III p<0,001
FVC, %	107,47±7,73	85,24±11,76	67,24±12,40	84,17±17,00	I-II p<0,001 II-III p<0,001 I-III p<0,001
FEV ₁ (ml)	2626,56±544,14	1789,62±446,00	1084,49±283,20	1741,06±686,55	I-II p<0,001 II-III p<0,001 I-III p<0,001
FEV ₁ , %	88,28±7,48	63,37±7,83	38,57±8,52	60,75±19,24	I-II p<0,001 II-III p<0,001 I-III p<0,001
FEV ₁ /FVC	65,86±3,20	58,56±7,44	45,62±10,96	56,06±11,02	I-II p<0,001 II-III p<0,001 I-III p<0,001
DLCO, %	80,31±22,27	69,71±19,86	53,39±21,74	66,83±22,04	I-II p<0,05 II-III p<0,001 I-III p<0,001
VA (ml)	6114,69±1164,22	5251,14±1088,42	4561,63±1052,07	5212,68±1214,32	I-II p<0,001 II-III p<0,01 I-III p<0,001
KCO	80,00±21,42	85,10±22,65	76,20±30,31	81,35±25,18	I-II p>0,05 II-III p>0,05 I-III p>0,05
TLC-PI (ml)	6759,69±1138,28	6558,48±1109,72	6686,12±1320,87	6637,81±1179,10	I-II p>0,05 II-III p>0,05 I-III p>0,05
TLC-PI%	110,34±9,38	103,78±13,85	107,27±18,71	106,16±14,95	I-II p>0,05 II-III p>0,05 I-III p>0,05
VA/TLC-PI	91,84±6,97	82,30±11,42	70,67±14,43	80,65±13,91	I-II p<0,001 II-III p<0,001 I-III p<0,001
RV/TLC-PI	42,44±7,97	55,00±8,71	61,94±8,89	54,61±10,95	I-II p<0,001 II-III p<0,001 I-III p<0,001
IC%	84,72±15,37	67,39±18,30	49,04±14,34	65,24±20,78	I-II p<0,001 II-III p<0,001 I-III p<0,001

Conclusion: In this study, we found that when the COPD severity increased, the DLCO was significantly decreased, but KCO did not. Alveolar volume measured in single breath diffusion test may be underestimated due to maldistribution of ventilation in COPD patients. For the interpretation of diffusion capacity, KCO may not be sufficient to define the pulmonary function abnormality. We suggest that additional parameters like VA/TLC ratio should be considered especially in COPD patient with ventilation maldistribution.

Keywords: Diffusing capacity, KCO, COPD

[Abstract:0055] PS-041 [Accepted:Poster Presentation] [Lung and Pleura Malignancies]

A Rare Case of Severe Subcutaneous Emphysema During Radiotherapy for Cavitory Lung Cancer and Treatment with Percutaneous Intracavitary Otolog Blood Patch Application

Ekrem Şenturk¹, Cenk Ahmet Şen²

¹Department of Chest Surgery, Yakın Doğu University School of Medicine, Nicosia, Turkish Republic of Northern Cyprus

²Medicalpark Hospital, İzmir, Turkey

Bronchocutaneous fistula and subcutaneous emphysema are rare complication of lung cancer during radiotherapy. A 74-year-old male patient was administered to our hospital due to sudden onset of shortness of breath and subcutaneous emphysema on the right side after radiotherapy. Chest computed tomography revealed a cavitory lesion in the right upper lobe in connection with the subcutaneous emphysema on the right side through chest wall. We present a rare case of severe subcutaneous emphysema due to cavitation of lung cancer with a radiotherapy, and treatment by percutaneous intracavitary otolog blood patch application (PIOBA). We performed a rare case of severe SE due to cavitation of lung cancer with a radiotherapy and treatment by PIOBA (Figure 1). The cavitation filled by 80 cc blood injection. After the application, shortness of breath was treated. Saturations of O₂ was 92 % and SE is decreased (Figure 2). This technique for the management of SE must be used on an individualised basis, depending on the clinical context and severity of the symptoms, although it cease of use, high effectiveness, low cost, minimal invasiveness and low risk of complications make it a good option in selected cases.

Keywords: Subcutaneous emphysema, cavitory lung cancer, percutaneous intracavitary otolog blood patch application

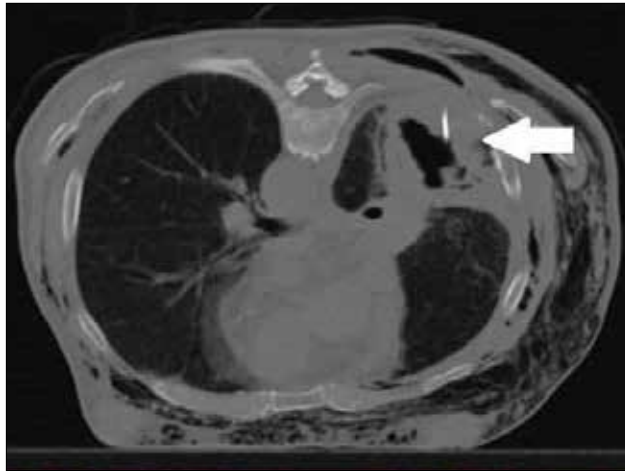

Figure 1. CT-guided percutaneous intervention

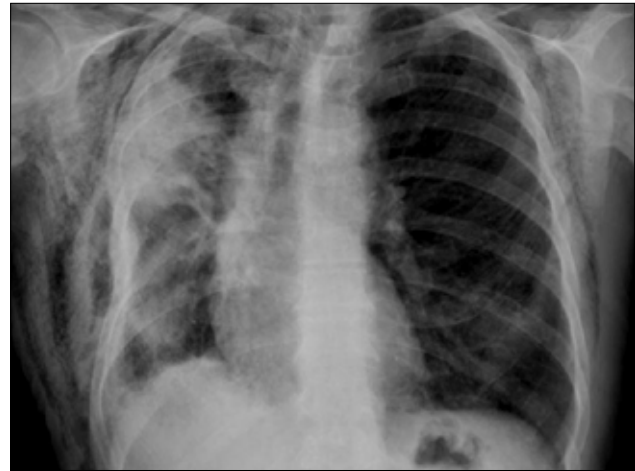

Figure 2. Chest radiography after procedure

[Abstract:0056] EPS-269 [Accepted: E-Poster] [Thoracic Surgery]

An Extraordinary Path of Gunshot: Bullet Embolism

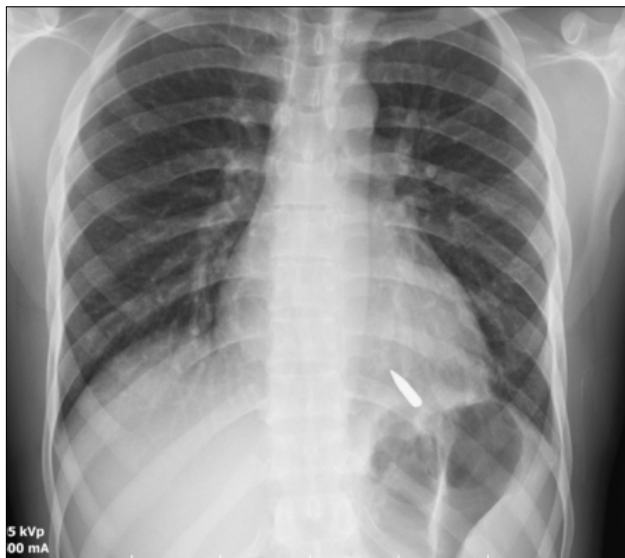

Figure 1.

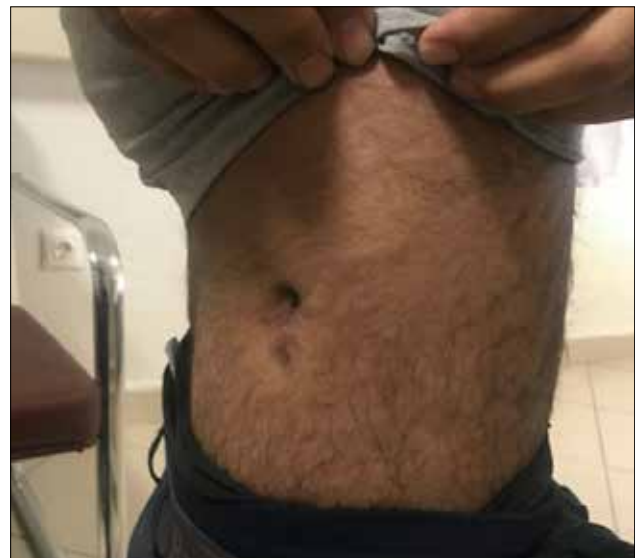

Figure 2.

Cenk Balta

Department of Thoracic Surgery, Şanlıurfa Training and Research Hospital, Şanlıurfa, Turkey

Injuries depended on gunshot are the second reason of death following motor vehicle accidents. Because of the high risk of death in thoracic traumas the treatment is conservatively approach without causing any complications. Embolus of gunshot bullet is a rare clinical entity with few published cases in the literature. In this case report we present a 20 years old male patient who shoted on his upper leg one year ago in Syrian civil war and determined a bullet in chest by radiological scan.

Keywords: Gunshot, bullet embolism, trauma**[Abstract:0060] SS-127 [Accepted:Oral Presentation] [Pulmonary Rehabilitation and Chronic Care]****First Results of Easy Breath Project**Sabri Serhan Olcay¹, Havva Turan¹, Canan Kart¹, Sevinç Sütü²¹Department of Pulmonary Rehabilitation, Burdur State Hospital, Burdur, Turkey²Burdur State Health Care Department, Burdur, Turkey

Objective: The aim of the Easy Breathe Project is to consolidate and standardize the training part which is the most important component of Pulmonary Rehabilitation (PR) program of patients with Asthma and Copd and to improve the motivation of the participants. Turkish Toracic Society (TTS) and Burdur State Health Departments are partners of this project which is planned to last for a year.

Methods: Those who volunteered from PR program were separated according to their diagnosis by groups consisting of at least 5 people and were given one day education with written and visual materials prepared by TTS. Trainings were held once a month. Contents of the education include: information about Copd and asthma, inhaler device usage control and training, information about flu and pneumonia vaccination, and the introduction of the TTS Public Health Page. A questionnaire was applied to participants before and after the training (Figure 1). Survey results are recorded and the patients files are sorted according to their diagnosis. The files were scanned retrospectively and statistical analyzes of the obtained data were performed by SPSS program.

Results: Twenty-six patients were included in the study (asthma:16, copd:10). The copd patient group consisted of male dominant (100%) and older (average age: 63) according to the asthma patient group (Table 1). In asthmatic patients, the pre-training inhaler misuse rate was 37.5%, while in the copd group this rate was similarly 40%. The proportion of patients who still continue to use tobacco before the training was 12.5% in the asthma group and 10% in the copd group (Table 1). According to the answers given in the questionnaire, 80% of our patients thought that they had sufficient knowledge about their diseases before the training. 33% of both groups do not use their medication during the period when they felt good. The proportion of those who knew that the drugs were not addictive was 31% in the asthmatic group, but this ratio after the training was 100% which is statistically significant. In both groups, the ratio of those who knew that there is safe web site where they could get information about the disease online before the training was 15%, which was statistically significantly increased to 81% in the asthma group.

Participatory Questionnaire		
Age:	Gender:	Tobacco
Please choose one answer below. Thank you		
1- I have enough information about my disease and treatment of this disease.		
a) Yes	b) No	c)uncertain
2- When I feel better there is no need to use my drugs/inhalers.		
a) Yes	b) No	c)uncertain
3- The drugs/inhalers that I use can become addictive		
a) Yes	b) No	c)uncertain
4- Walking or exercising will be harmful to my illness		
a) Yes	b) No	c)uncertain
5- I know the reliable websites that I can follow from the internet for new information and developments about my disease		
a) Yes	web site	b) No

Table 1. Demographic Data

	Asthma	Copd
n	16	10
Age	51,25 (38-72)	63.1 (38-80)
Gender	Female 16 100%	Male 10 100%
Inhaler tec.	6 37,5%	4 40%
Tobacco	2 12,5%	1 10%

Table 2. Survey Results

	Asthma before education	Asthma after education	p	Copd before education	Copd after education	p
Question 1	0: 13 81% 1: 1 6% 2: 2 13%	0: 15 94% 1: 1 6%	0,343	0: 8 80% 1: 1 10% 2: 1 10%	0:10 100%	0,329
Question 2	0: 6 38% 1: 10 62%	0: 1 6% 1: 15 94%	0,083	0: 3 30% 1: 5 50% 2: 2 20%	0: 1 10% 1: 9 90%	0,126
Question 3	0: 2 13% 1: 5 31% 2: 9 56%	1: 16 100%	<0,001*	0: 2 20% 1: 7 70% 2: 1 10%	0: 2 20% 1: 8 80%	0,587
Question 4	0: 1 6% 1: 13 81% 2: 2 13%	1: 16 100%	0,191	0: 1 10% 1: 9 90%	1: 10 100%	1
Question 5	0: 2 13% 1: 14 87%	0: 13 81% 1: 3 19%	<0,001*	0: 2 20% 1: 8 80%	0: 5 50% 1: 5 50%	0,350

Conclusion: At policlinic crowd at Turkey, there is not enough time for patient education. Following individual training with in the PR program, repetitive training with visual material in groups can be reinforcing.

Keywords: Asthma, COPD, rehabilitation, Health Education

[Abstract:0061] PS-103 [Accepted:Poster Presentation] [Pulmonary Rehabilitation and Chronic Care]

Experience of First Year in Pulmonary Rehabilitation Unit at a State Hospital

Sabri Serhan Olcay, Canan Kart, Havva Turan

Department of Pulmonary Rehabilitation, Burdur State Hospital, Burdur, Turkey

Objectives: To compare the results of patients with Asthma and Copd treated in 2017 at Burdur State Hospital Pulmonary Rehabilitation Unit.

Methods: Patients who completed the Pulmonary Rehabilitation (PR) program, including 15 session chest physiotherapy, treadmill, cycling, upper and lower extremity strengthening exercises were divided according to the diagnosis of the files. Files were scanned retrospectively. Statistical analyzes of the obtained data were performed with the SPSS program.

Results: Twenty-seven patients; 17 patients with asthma and 10 patients with Copd were included in the study. Patients in the Copd group were male dominant (100%), heavy smokers [35 (0-50)] and less overweight [26 (22-34)] compared to the asthma group (Table 1). After PR, pulmonary function test value of PEF, six minute walking test distance, asthma control test (ACT) score, health - related quality of life parameters of social function, physical function, emotional function, physical role limitations, general health, mental health and vital-



Figure 1. Pulmonary Rehabilitation Unit

Table 1. Demographic Data

	Asthma	COPD
n	17	10
Age (year)	53 (38-79)	63 (38-80)
BMI (kg/m2)	32 (18-43)	26 (22-34)
Gender (F/M)	15/2	0/10
Duration of Disease (year)	7 (1-25)	6,5 (2-40)
Tobacco (p/year)	16 (0-60)	35 (0-50)

Table 2. Patients data before and after PR

	Asthma before PR	Asthma after PR	p	COPD before PR	COPD after PR	p
FEV1 (%)	75 (28-97)	84 (34-96)	0,078	57 (17-78)	58 (31-69)	0,575
FEV1/FVC	78 (58-95)	82 (47-100)	0,414	65 (54-77)	66 (56-75)	0,042*
PEF (%)	71 (21-129)	84 (47-141)	0,016*	51 (34-92)	55 (29-75)	0,799
6MWT Distance (meter)	435 (280-620)	524 (300-795)	<0,001*	464 (267-586)	553 (296-804)	0,008*
Borg ^	2 (0-6)	0 (0-2)	0,001*	1 (2-3)	0 (0-1)	0,359
SGRQ symptom	57 (23-83)	45 (11-73)	0,034*	60 (25-65)	42 (11-70)	0,214
SGRQ activity	59 (20-88)	34 (0-60)	0,002*	52 (34-100)	39 (26-58)	0,011*
SGRQ impact	82 (30-91)	57 (24-82)	0,003*	80 (56-91)	72 (47-89)	0,173
SGRQ total	65 (38-78)	50 (33-63)	0,001*	67 (48-83)	61 (44-70)	0,021*
SF 36 social function	52 (12-100)	87 (12-100)	0,009*	62 (38-100)	87 (50-100)	0,093
SF 36 physical func.	65 (5-95)	75 (0-100)	0,003*	65 (15-75)	85 (50-95)	0,028*
SF 36 physical role limitations	0 (0-100)	75 (0-100)	0,003*	50 (0-100)	75 (25-100)	0,040*
SF 36 emotional function	0 (0-100)	66 (0-100)	0,007*	33 (0-100)	100 (0-100)	0,207
SF 36 general health	25 (10-60)	47 (0-67)	0,015*	30 (8-65)	42 (15-62)	0,441
SF 36 mental health	48 (20-80)	80 (40-96)	0,001*	56 (40-84)	80 (36-92)	0,181
SF 36 pain	62 (22-100)	84 (0-100)	0,103	100 (0-100)	100 (22-100)	0,395
SF 36 vitality	50 (20-70)	70 (45-90)	0,001*	55 (20-80)	70 (40-80)	0,138
HAD (A)	9 (1-14)	6 (2-14)	0,043*	7 (1-11)	4 (1-11)	0,292
HAD (D)	7 (2-17)	3 (0-8)	0,003*	5 (3-8)	4 (1-8)	0,348
MMRC	1 (0-4)	1 (0-1)	0,002*	2 (1-3)	2 (0-3)	0,063
ACT	14 (10-21)	22 (16-25)	0,001*	17 (7-30)	12 (6-27)	0,058

ity scores increased significantly and anxiety score, depression score, dyspnea and disease-specific quality of life parameters of symptom, activity, impact and total scores were reduced significantly in Asthma group (Table 2). After PR; pulmonary function test value of FEV1, six minute walking test distance, health - related quality of life parameters of physical function, physical role limitation scores increased significantly and disease-specific quality of life parameters of activity and total scores were reduced significantly in Copd group (Table 2).

Conclusion: Pulmonary Rehabilitation program applied to asthmatic patients can improve exercise and quality of life, ACT scores, decrease anxiety and depression scores and dyspnea. Prospective, randomized controlled trials are needed to determine which phenotype benefit most from PR in asthma.

Keywords: Asthma, COPD, rehabilitation, quality of life

[Abstract:0062] SS-104 [Accepted:Oral Presentation] [Clinic Problems - Others]

Complications Seen in Patients Using Anti-TNF: Retrospective Evaluation of 355 Cases

Serhat Erol, Sümeyye Ayöz, Kübra Türkel, Fatma Çiftçi, Aydın Çiledağ, Akın Kaya,
Özlem Özdemir Kumbasar

Department of Chest Diseases, Ankara University School of Medicine, Ankara, Turkey

Objectives: Tumor necrosis factor-alpha (Tnf- α) is important for the formation of granuloma and the protection of its integrity. Therefore, Tnf- α inhibiting agents (anti-TNF drugs) increase the risk of viral and fungal infections, particularly tuberculosis (Tb) and nontuberculous mycobacterial infections. Moreover, these agents have some side effects such as injection site reactions, allergy, and hepatic toxicity. An increase in the risk of cancer, particularly lymphoma, is controversial. However, some studies have demonstrated increased risk of nonmelanoma skin cancer.

Methods: In this study, the complications that developed in patients using anti-TNF drugs were evaluated retrospectively.

Results: A total of 355 patients whose ages varied between 20 and 80 years were included in the study. Of these patients, 55.8% were female and 44.2% were male. The patients were receiving treatments due to ankylosing spondylitis, rheumatoid arthritis, inflammatory bowel diseases, psoriasis, and uveitis associated with Behcet’s disease for a period of 1-13 years. Complications associated with anti-TNF drugs developed in 8.2% of patients. Elevated LFT and allergic reaction occurred in 3 and 23 patients, respectively. Neutropenia was found in one case, epileptic attack in one case, and increased findings of interstitial fibrosis in the lung in one case. Of these patients, drug was discontinued in 6, drug was changed in 8, and desensitization was carried out in 5. The treatment was continued without any change in other cases. Cancer developed in 5 patients (colon, prostate, thyroid, chronic myelocytic leukemia, clear-cell renal cancer). Urinary tract infection occurred in 14 cases. Non-tuberculosis mycobacteria growth was observed in one patient. Lymphadenopathy (LAP) was detected in 15 cases, one of whom had axillary LAP and was diagnosed with castleman disease. In another case, the result of biopsy was reported as granulomatous inflammation. No necrosis was found and ARB was negative. The examinations of the patient for malignancy continue because of accompanying nodule in the breast. On the other hand, Tb was found in 2 patients with mediastinal LAP. 71.8% of cases were begun treatment for latent tuberculosis infection (LTBE). Of them, 5.1% (13/255) gave up the treatment due to various reasons. Isoniazid (INH) -induced complications developed in a total of 14 patients. Elevated liver function test (LFT) occurred in 10 patients, gastric intolerance in 1 case, peripheral neuropathy in 1 patient, and allergic reaction in 2 patients. Rifampicin (RIF) was begun in one patient with elevated LFT, one patient with allergic reaction, and one case developing peripheral neuropathy. In two of other 9 patients developing elevated LFT, the treatment was continued in the same way. The treatment was paused and restarted in 4 of them, and the treatment was discontinued in 3 cases. Tb developed in 1.1% (4/355) of the cases. Of them, one was genitourinary system, one was mediastinal Tb lymphadenitis (MTLA), one was pulmonary, and the other was pulmonary+MTLA. Two of these patients received LTBE treatment, but two did not.

Conclusion: According to the results of our study, LTBE treatment decreases the risk of active Tb, but it does not completely disappear it. For this reason, patients using anti-TNF drugs should be followed up closely. Tb should be kept in mind particularly for patients developing pulmonary symptoms or mediastinal LAP in the follow-up.

Keywords: Latent tuberculosis, anti-TNF, mycobacteria

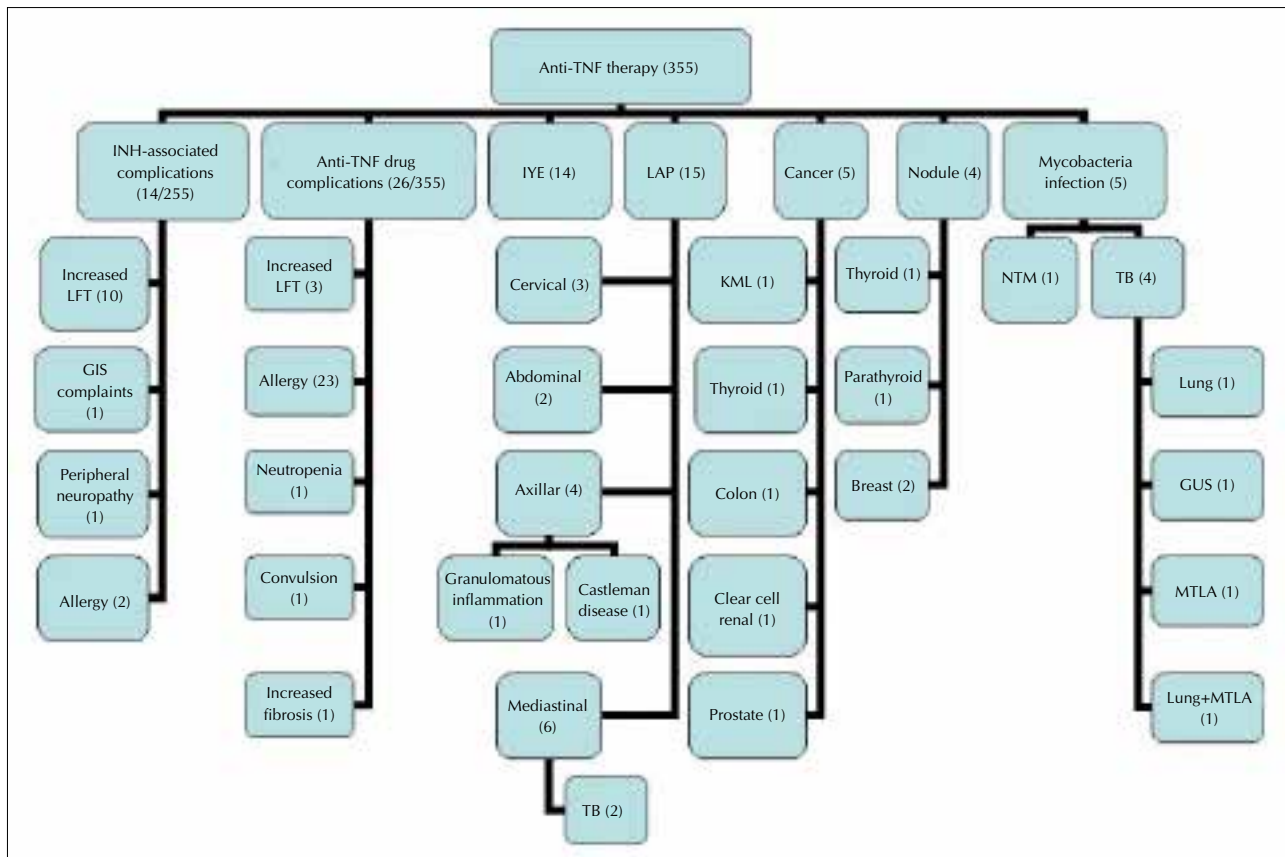


Figure 1. Problems Related to Anti-TNF Therapy

[Abstract:0065] PS-310 [Accepted:Poster Presentation] [Respiratory Infections]**Rare Cause of Delayed Resolution in Pneumonia: a Case of Pulmonary Actinomycosis**

Gülstan Karadeniz, Gülru Erbay Polat, Fatma Demirci Üçsular, Enver Yalnız

Department of Pulmonology, Dr. Suat Seren Chest Disease and Surgery Training and Research Hospital, İzmir, Turkey

Pulmonary Actinomycosis is a rare chronic lung infection caused by *Actinomyces* species bacteria. Clinically present pneumonia with delayed resolution, lung abscess or mass in the lung. We would like to present our case of pulmonary actinomycosis in the context of the literature because of the fact that resolution-delayed pneumonia should be considered and rarely seen. A 49-year-old male patient presented to our polyclinic with complaints of cough and hemoptysis. The patient with stable vital signs and reduced breath sounds had tube thoracostomy for right spontaneous pneumothorax 7 years ago. Thoracic CT was requested upon detection of infiltration of the left lower zone paracardiac site in the chest X-ray of the patient. Emphysematous changes in both lung parenchyma and consolidation with bronchiectasis in the size of 6x2.5 cm adjacent to the left lower lobe fissure were detected. Endobronchial lesions and bleeding points were not observed in fiberoptic bronchoscopy (FOB). Bronchial aspiration ARB direct examination and PCR did not show acidoresistant bacillus and bronchial aspiration ARB culture and nonspecific culture did not show reproduction, bronchial aspiration cytology was benign and submucosal nonspecific inflammatory infiltration was observed in bronchial biopsy. Transthoracic needle aspiration performed after nonspecific antibiotic (Gemifloxacin) treatment. The result came in line with 'squamous metaplasia'. With the suspicion of malign lesion, PET / CT performed. Parenchymal lesion (SUVmax 4.8) with a size of 4.2x2.2 cm accompanied by air bronchograms in the left lower lobe mediobasal segment, band-like atelectasis in the distal region, and and subcarinal lymph nodes (SUVmax 4.2) were observed. Transbronchial lymph node biopsy made with endobronchial ultrasonography (EBUS) from 7 and 11R stations, was assessed as 'benign cytology, reactive hyperplasia'. Left lower lobectomy was performed because no regression was observed at 4th month of follow-up. Pathologic outcome 'Lung abscess in the background of bronchiectasis; The bronchial epithelial proliferation, regenerative and dysplastic epithelial proliferation and alveolar lymphocyte infiltration were observed in the middle of the 4 cm diameter necrotic area. Bacteria were found to have gram positive bacterial colonies of the PAS (+) flap structures and the findings were consistent with *Actinomyces* infection. The patient was given amoxicillin 1 gr 3x1 (PO) for 3 months. In conclusion; pulmonary actinomycosis is rare, radiologically mimicking other infections and neoplasms, difficult to diagnose, and often requiring surgery and must be kept in mind in the differential diagnosis of delayed resolution of the pneumonia.

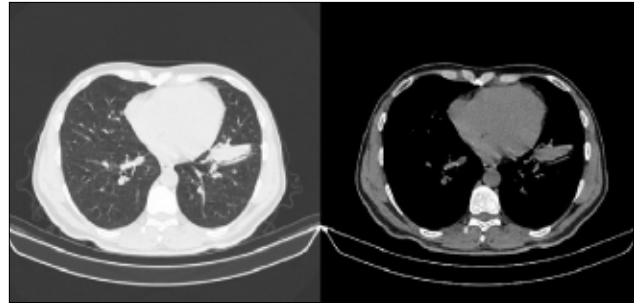
Keywords: Pneumonia, pulmonary actinomycosis, diagnosis

Figure 1. Thoracic computerized tomography (CT): Consolidation with bronchiectasis in the size of 6x2.5 cm adjacent to the left lower lobe fissure

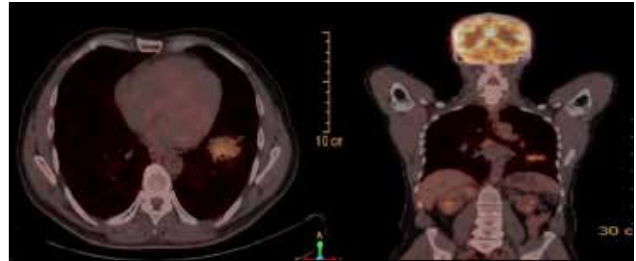


Figure 2. Positron emission tomography (PET): Parenchymal lesion (maximal standardized uptake value (SUVmax) 4.8) with a size of 4.2x2.2 cm accompanied by air bronchograms in the left lower lobe mediobasal segment, band-like atelectasis in the distal region, and and subcarinal lymph nodes (SUVmax 4.2) were observed

[Abstract:0066] SS-075 [Accepted:Oral Presentation] [Lung and Pleura Malignancies]**Liquid Biopsy in Lung Cancer: Tepecik Experience**Altuğ Koç¹, Tuncay Göksel², Berna Kömürçüoğlu³, Özge Özer Kaya¹, Berk Özyılmaz¹, Pınar Gürsoy⁴, Yaşar Bekir Kutbay¹, Özgür Kırbıyık¹, Taha Reşid Özdemir¹, Kadri Murat Erdoğan¹, Merve Saka Güvenç¹, Gizem Çalıbaşı Koçal⁵, Yasemin Baskın⁵¹Health Sciences University, Tepecik Training and Research Hospital, Genetic Diagnosis Center, İzmir, Turkey²Department of Chest Diseases, Ege University School of Medicine, İzmir, Turkey

³Health Sciences University, Dr. Suat Seren Training and Research Hospital of Chest Diseases and Surgery, İzmir, Turkey

⁴Health Sciences University, Policlinic of Oncology, Dr. Suat Seren Training and Research Hospital of Chest Diseases and Surgery, İzmir, Turkey

⁵Department of Basic Oncology, Dokuz Eylül University, Institute of Oncology, İzmir, Turkey

Objectives: About 80% of lung cancer cases are classified as “Non-Small Cell Lung Cancer (NSCLC)”. Case specific, targeted therapies (precision medicine) are developed for advanced NSCLC. The main targets are the mutations of EGFR gene which are found in 10-30% of cases. Tyrosine kinase inhibitors (erlotinib, gefitinib, afatinib, osimertinib) are offered if the tumor has the mutations. Although, the molecular analysis is frequently performed on old tissue biopsy samples from pathology archives and solid biopsy does not reveal the actual genotype of tumor in most of the cases. In fact, cancer progresses with new mutations because of its nature. In addition, anticancer therapies also create new mutations. At the 9-13th months of targeted tyrosine kinase therapy, drug resistance related EGFR T790M mutation may occur. Our goal is to identify the effect of liquid biopsy in the management of NSCLC and share the results of genetic diagnosis center.

Methods: We have examined 42 mutations of EGFR gene, in 114 NSCLC cases that referred to our center in 2017. Plasma derived cell-free DNA (cfDNA) samples are used to identify 42 mutations of EGFR gene including exon 19 (Ex19del), exon 20 (T790M), exon 21 (L858R) variants by “Real-Time Quantitative PCR” (RT-PCR) method.

Results: The EGFR mutations are found in 23 liquid biopsy cases (20%). Eleven of the cases (9.6%) have single sensitivity related mutation: Five cases have Ex19del, 4 cases have L858R, 2 cases have Ex20ins. In addition, one case has “Ex19del and G719X” together. The remaining 11 (9.6%) have the drug resistance related T790M mutation in addition to a sensitivity mutation: Six cases have “Ex19del ve T790M”, 4 cases have “L858R ve T790M”, 1 case has “L858R, S768I ve T790M”. The 11 cases with normal liquid biopsy result actually have a EGFR mutation in solid tissue biopsy.

Conclusion: The liquid biopsy is successfully took its place in the identification of EGFR mutations of advanced NSCLC cases.

Keywords: EGFR, liquid biopsy, lung cancer

[Abstract:0069] EPS-008 [Accepted: E-Poster] [Clinic Problems - Others]

Results of Neurology Consultation in Hospitalized Patients in the Tertiary Chest Disease Hospital

Şenay Aydın¹, Cengiz Özdemir²

¹Department of Neurology, Yedikule Chest Diseases and Thoracic Surgery Training and Research Hospital, İstanbul, Turkey

²Department of Chest, Yedikule Chest Diseases and Thoracic Surgery Training and Research Hospital, İstanbul, Turkey

Objectives: Accompanied neurological diseases following chronic diseases are frequently observed in clinical practice. Concomitant neurological diseases can significantly affect the progress of the existing lung disease, the duration of the treatment, and therefore the length of hospital stay. In this study, it was aimed to determine neurological diseases in chest clinics, to identify common points between accompanying neurological diseases and hospital clinics and lung diagnoses of patients and to show the importance of consultation neurology in patient follow-up.

Methods: In this study, neurology consultations for hospitalized patients in Yedikule Chest Diseases and Chest Surgery Training and Research Hospital between January 2011 and January 2017 were retrospectively reviewed. The age, gender, hospitalization and neurological diagnosis of the patients, consultation requested clinical, consultation request reasons and hospital exit cases were recorded.

Results: A total of 2193 patients and 3439 requested consultations were evaluated, including 1552 (70.4%) male and 641 (29.6%) female patients with an average age of 64.91±17.75 (17-104). Consultation requests have been made for a total of seven different clinic including 11 chest diseases department (n:2307, 67.1%), 3 chest surgeons department (n: 55, 10.3%), respiratory intensive care unit (n:265, 7.7%), chest surgery intensive care unit (n:148, 4.3%), emergency department (n:95, 2.8%), tuberculosis department (n:126, 3.7%) and transplantation department (n:143, 4.2%). As a result of neurological evaluation, headache (n:957, 27.8%), cerebrovascular disease (n:793, 23.1%), epilepsy (n:583, 17.0%), peripheral nerve disease (n:378, 11.0%), delirium (n:244, 7.1%) and consciousness change (n:151, 4.4%) were diagnosed most frequently in patients. In terms of pulmonary diseases, neurological evaluation was more frequent in patients with chronic obstructive pulmonary disease (COPD), lung cancer and pneumonia. From the point of view of lung diseases, it was found that more requests were made for neurological evaluation than Patients with chronic obstructive pulmonary disease (COPD), lung cancer and pneumonia.

Conclusion: The data we obtained in our study shows that the incidence of cerebral vascular disease, epilepsy and headache in patients with chest disease units is high and the importance of consultation neurology following the patient.

Keywords: Consultation neurology, lung diseases, neurology

[Abstract:0071] PS-113 [Accepted:Poster Presentation] [Pulmonary Rehabilitation and Chronic Care]

Effects of pulmonary rehabilitation on respiratory functions, respiratory muscle force, perception of dyspnea and exercise capacity in a case of pulmonary langerhans cell histiocytosis (Histiocytosis X)

Furkan Ozdemir¹, Neslihan Duruturk¹, Sule Akcay²

¹Department of Physiotherapy and Rehabilitation, Faculty of Health Sciences, Başkent University, Ankara, Turkey

²Department of Pulmonary Diseases, Başkent University School of Medicine, Ankara, Turkey

Objectives: Pulmonary langerhans cell histiocytosis (Histiocytosis X) is an idiopathic interstitial lung disease which causing langerhans cell infiltration on lungs. The disease which clinical symptoms are variable and mostly seen in young population, seen in smokers oftenly. There is only a case report about effects of aerobic exercise training on Histiocytosisxpatients and there is no research about effects of pulmonary rehabilitation programme on this patients. Our aim is evaluating effects of pulmonary rehabilitation programme on respiratory functions, respiratory muscle force and exercise capacity in a case of Histiocytosis X.

Methods: Twenty two years old female patient consulted our hospital's chest disease clinic with cough and dyspnea (especially increasing with effort) symptoms. Our case was referred in order to decreasing symptoms to pulmonary rehabilitation as well as medical treatment. Before pulmonary rehabilitation, patient's pulmonary functions (FEV1:1.46 L, FEV1:49%, FVC:3.3 L, FVC:96%, FEV1/FVC:51% and PEF:3.85 L/sec), respiratory muscle force (S-Index:51 cmH2O, Flow:3 L/sec, Volume:2.2 L), exercise capacity with 6 minute walk test (6 Minute Walk Distance (6MWD) :230 m) and cardiopulmonary exercise test with bicycle ergometer (VO2peak:16.9 mL/kg/min, VEpeak:34.3 L/min, HRpeak:132 stroke/min, Work Loadpeak:59 watt) and perception of dyspnea (modified Medical Research Council Dyspnea Scale (mMRC) :3) was evaluated. Pulmonary rehabilitation programme continued for 8 weeks. Aerobic exercise programme applied to our case with bicycle ergometer at 50-75% of VO2peak three times a week and 30-45 minute per session. Breathing exercises (diaphragmatic breathing, chest breathing and thoracal expansion exercises) applied under supervising of a physiotherapist for every session.

Results: After 8 weeks pulmonary rehabilitation programme there were improvements obtained on respiratory functions (FEV1:1.54 L, FEV1:52%, FVC:3.39 L, FVC:99%, FEV1/FVC:52% and PEF:4.62 L/sec), respiratory muscle force (S-Index:65 cmH2O, Flow:3.8 L/sec, Volume:2.2 L), exercise capacity (6MWD:478 m, VO2peak:24 ml/kg/min, VEpeak:47.1 L/min, HRpeak:149 stroke/min, Work Loadpeak:75 watt) and perception of dyspnea (mMRC:1) than before pulmonary rehabilitation.

Conclusion: Histiocytosisxcauses restrictive respiratory problems because of damage that created on interstitial area. Results of this study showing that pulmonary rehabilitation can be a treatment method for decreasing perception of dyspnea, which is main symptom of patinets'as increasing exercise capacity and respiratory muscle force. There is a need for more comprehensive and randomise controlled researches about effects of pulmonary rehabilitation on Histiocytosisxpatients with more sample.

Keywords: Aerobic exercise, breathing exercises, exercise test, histiocytosis X, langerhans cell histiocytosis, rehabilitation

[Abstract:0072] PS-209 [Accepted:Poster Presentation] [Asthma and Allergy]

Omalizumab Treatment in Atopic Severe Persistent Asthma: a Single Center Real-Life Experience with Thirty Eight Patients

Murat Türk¹, Sakine Nazik Bahçeciler¹, Nuri Tutar², Fatma Sema Oymak², İnci Gülmez², İnsu Yılmaz¹

¹Department of Chest Diseases, Division of Allergy and Clinical Immunology, Erciyes University School of Medicine, Kayseri, Turkey
²Department of Chest Diseases, Erciyes University School of Medicine, Kayseri, Turkey

Objectives: Omalizumab is a monoclonal antibody that is used as an add-on therapy in moderate to severe persistent allergic asthma in patients with persistent symptoms and frequent exacerbations despite step 4 treatment. Real life studies on this treatment option for our country is limited. For this reason, this study aims to assess the clinical efficacy, safety and change in controller medication use of omalizumab in atopic severe persistent asthma.

Methods: Patients with allergic severe persistent asthma that were treated with omalizumab between 2009-2017 were retrospectively evaluated. We noted and compared baseline and last results of; symptom scores (GINA categorical), controller medications, blood eosinophil levels, FEV1 and the number of exacerbations that were treated at least 3 days with systemic corticosteroids. Step-down of other asthma medications were tried in patients with symptom control and without exacerbation history within last 6 months.

Table 1. General characteristics of the patients

	N=38
Age	50±1.8
Female gender; n (%)	30 (79)
Median IgE Level	173 (101.8-410)
Basal blood eosinophil count	503.8±524.8
Upper respiratory tract disease:n (%)	
None	5 (13)
Chronic rhinitis	29 (76)
AERD	4 (11)
Duration of treatment; month	30±22.1
Allergen sensitization	
Mite	31 (82)
Pollen	11 (29)
Dander	2 (5)
Mold	15 (40)
Single allergen sensitization	17 (45)

Table 2. Comparison of patients' final and basal symptom scores under omalizumab therapy, rates of attacks, respiratory function tests, and blood eosinophil values

	Before omalizumab	After omalizumab	Mean change	p
Symptom score	3.6±0.5	0.5±0.7	-87%	
Full control	0	26 (68)		<0.001
Partial control	0	12 (32)		
Non-controlled	38 (100)	0		
Number of attacks requiring systemic steroid in the last one year	8.7±8	1.7±1.5*	-78%	<0.001
FEV1	77±18.9	86.9±21.2	15%	0.001
FEV:cc	2075±729	2321±800	14%	0.001
Blood eosinophil count	503.8±524.8	370.8±314.5	-13%	0.134

- Within last one year or since the beginning of omalizumab

Results: Thirty-eight patients (mean age 50 years, 30 were female) were included in the study. After treating with a mean time of 30±22.1 months, 26 (68%) became controlled and 12 partly-controlled (32%) of whom all were uncontrolled before. Mean exacerbation rates within last 1 year were 78% decreased (8.7±8 vs 1.7±1.5; p<0.001) and FEV1 levels were 14% increased (2075±729cc vs 2321±800cc; p=0.001) as compared to baseline levels. Mean inhaled corticosteroid dose (budesonide eq. 1063±397 mcg vs 958±439; p=0.084), number of other controller medications and long-term systemic steroid need were partly decreased after omalizumab therapy. No serious adverse events were recorded during the follow-up period.

Conclusion: Our results confirmed that omalizumab significantly improves disease control and is a safe add-on therapy. Also in appropriate patients with controlled disease over time, step-down of other medications can be tried.

Keywords: Severe persistent asthma, omalizumab, asthma exacerbation, therapy management

[Abstract:0076] EPS-069 [Accepted: E-Poster] [Diagnostic Methods]

Reactivation Lung Tuberculosis Case developed in a Patient Diagnosed with Small Cell Lung Cancer

Şerif Kurtuluş¹, Rukan Karaca², Zafer Hasan Ali Sak³, İclal Hocanlı³

¹Department of Chest Diseases, Ceylanpınar Government Hospital, Şanlıurfa, Turkey

²Department of Radiological, Ceylanpınar Government Hospital, Şanlıurfa, Turkey

³Department of Chest Diseases, Harran University School of Medicine, Şanlıurfa, Turkey

Introduction: Lung cancer (LC) can be seen with many diseases. One of the rare cases of these coexistence is lung tuberculosis (TB) with LC. While the incidence of LC in TB is 0.7-2.32%, the rate of incidence in LC is 1.9-4%.

Case Presentation: A 71-year-old male patient presented to our clinic with complaints of cough, weight loss, fatigue. In his story, it was learned that his complaints started 15-20 days ago. Smoking is 50 p/y. His history included COPD and Tuberculosis. Physical examination revealed a blood pressure of 110/70 mmHg, heart rate of 98 / min, fever at 37.5°C. There was a decrease in bilateral breath sounds in auscultation. In laboratory, hematocrit 43%, hemoglobin 13.7 gr / dl, WBC 13000 / mm³ and ESR 85 mm/h. In blood biochemical assays, CRP 6.7 mg / dl and creatinine 1.36 mg / dl. An infiltration in the right upper zone and a lesion similar to mass in the left upper zone were observed in the chest X-ray of the patient. In the computer assisted tomography of the thorax, an irregular fibrotic lesion was present in the right upper lobe of the lung. Calcification in the lesion, bronchiectasis and adjacent granulomas were observed. In the left lung, a pattern compatible with an irregularly limited mass located centrally, located adjacent of the left main pulmonary artery was observed. Fiberoptic

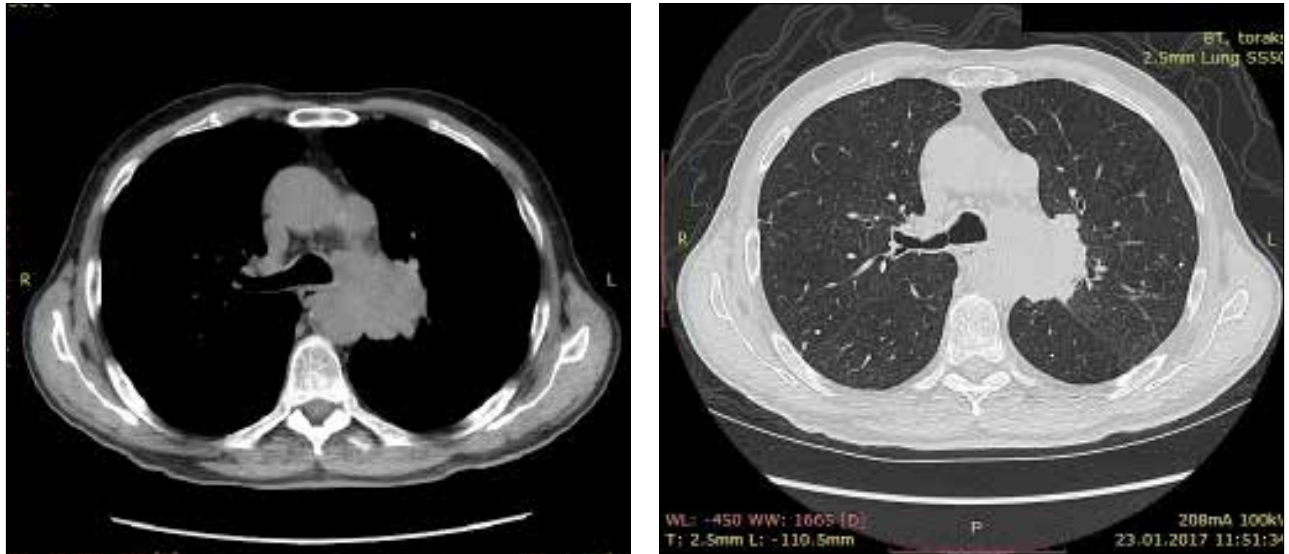


Figure 1. Axial CT images in mediastinal (A) and lung (B) windows. In the left lung, a pattern with an irregularly limited mass located centrally, located adjacent of the left main pulmonary artery is observed. Small cell lung carcinoma was diagnosed through transbronchial needle biopsy.

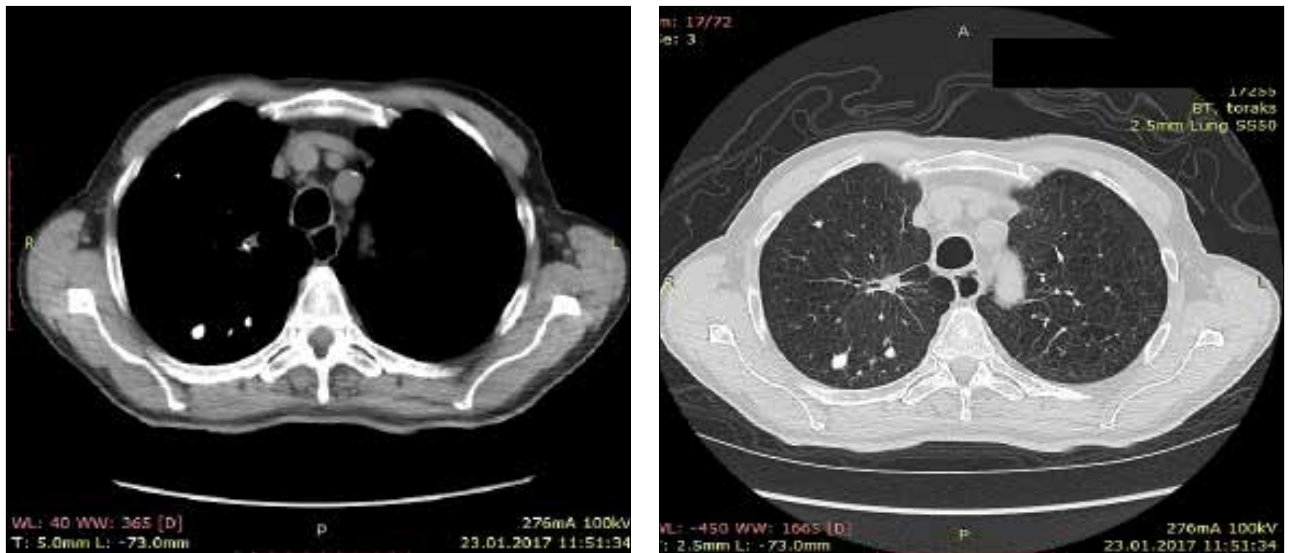


Figure 2. TB sequellae. Axial CT images in mediastinal (A) and lung (B) windows. An irregular fibrotic lesion was present in the right upper lobe of the lung. Calcification in the lesion, bronchiectasis and adjacent granulomas are observed.

bronchoscopy (FOB) was planned with prediagnosis of LC and TB. In the FOB performed, the upper lobe of the left lung was hemorrhagic in appearance and was almost fully obstructed with tumor tissue. Biopsy, lavage cytology and lavage Asido Resistance Staining (ARS) was sent. Lavage ARS was resulted as (++) . HRZE (isoniazid, Rifampicin, Pirazinamid, Etambutol) was initiated in patient with diagnosis of positive pulmonary tuberculosis. Lavage cytology was reported as blood cells and alveolar macrophages, while biopsy was reported as Small Cell Carcinoma. The patient was evaluated as stage 4 due to large vessel invasion. The patient was directed to oncology.

Conclusion: TB can interfere with LC and cause delays in diagnosis and treatment. No radiologic findings can be considered specific to tuberculosis because the tuberculosis can mimic any disease on the chest X-ray and give similar radiological findings. TB should also come to mind in the differential diagnosis of diseases that hold lungs. It should be kept in mind that Lung TB may be accompanied in patients with LC

Keywords: ARS, small cell lung cancer, tuberculosis

[Abstract:0081] PS-151 [Accepted:Poster Presentation] [Clinic Problems - Others]

The Knowledge Level of Hospital Staff About Influenza and Pneumococcal Vaccination

Hakan Evren¹, Emine Evren¹, Selin Bardak Özdemir², Züleyha Özer Yazgan³, Serap Argun Barış⁴, Füsün Yıldız⁵

¹Department of Infectious Disease, Dr Suat Günsel Girne University Hospital, Kyrenia, Turkish Republic of Northern Cyprus

²Department of Infectious Disease, Near East University School of Medicine, Nicosia, Turkish Republic of Northern Cyprus

³Department of Internal Medicine, Dr Suat Günsel Girne University Hospital, Kyrenia, Turkish Republic of Northern Cyprus

⁴Department of Pulmonary Disease, Kocaeli University School of Medicine, Kocaeli, Turkey

⁵Department of Pulmonary Disease, Dr Suat Günsel Girne University Hospital, Kyrenia, Turkish Republic of Northern Cyprus

Objectives: The aim of this study is to evaluate the knowledge of influenza and pneumococcal vaccine in individuals who work in Dr Suat Günsel Kyrenia University Hospital and Near East University School of Medicine.

Methods: A questionnaire about influenza and pneumococcal vaccination was administered to the health care personnel (nurses, laboratories, technicians) and to the administrative staff. The demographic characteristics of participants were also recorded.

Results: A total of 225 subjects were included in the study; there were 180 women (80%) and 45 (20%) men. The mean age was 32,8±11,6 years for women and 28,1±9,5 years for men and the difference was statistically significant (p = 0,001). 73.5% of the respondents stated that adult vaccination was effective. There was no statistically significant difference between genders regarding the effectiveness of adult vaccination (p =0,5). Pneumococcal vaccination (58,7%) was less well known, although 86,2% of respondents indicated that they had information about influenza vaccination. Similarly, the level of knowledge about the effect of pneumococcal vaccine on the reducing risk of infection (40,9%) was lower than that of influenza vaccination (63,4%). Only 28,4% of respondents indicated that they had influenza vaccine; the rate of those who had influenza vaccination in women was higher than that of men but the difference was not significant (29,4% vs 24,4%, p = 0,51). None of the cases had pneumococcal vaccination. In 75% of influenza vaccinated participants, the vaccination proposal was made by a physician. Among influenza vaccinated participants; the proportion of people who thought that vaccination was beneficial was 54.4%. However, 33.8% thought it was not beneficial and 11,8% had no idea. Not believing the efficacy of vaccination (38,7%) and the belief about not being in risk group (36,1%) were the most common reasons for not vaccinating in all participants. The most common reasons for not being vaccinated were; not believing the efficacy of vaccination in women while the belief about not being in risk group in men.

Conclusion: It has been shown that the rate of flu vaccination among hospital staff is low and the level of knowledge about pneumococcal vaccination is low. It is thought that educational programs on vaccination should be organized in order to increase the awareness of the hospital staff who are in risk group for infection due to the working environment.

Keywords: Health workers, influenza vaccination, knowledge, pneumococcal vaccination

[Abstract:0082] PS-148 [Accepted:Poster Presentation] [Clinic Problems - Others]

The Knowledge Level of Physicians About Influenza and Pneumococcal Vaccination

Emine Evren¹, Hakan Evren¹, Selin Bardak Özçem², Züleyha Özer Yazgan³, Serap Argun Barış⁴, Füsün Yıldız⁵

¹Department of Infectious Disease, Dr Suat Günsel Girne University Hospital, Kyrenia, Turkish Republic of Northern Cyprus

²Department of Infectious Disease, Near East University School of Medicine, Nicosia, Turkish Republic of Northern Cyprus

³Department of Internal Medicine, Dr Suat Günsel Girne University Hospital, Kyrenia, Turkish Republic of Northern Cyprus

⁴Department of Pulmonary Disease, Kocaeli University School of Medicine, Kocaeli, Turkey

⁵Department of Pulmonary Disease, Dr Suat Günsel Girne University Hospital, Kyrenia, Turkish Republic of Northern Cyprus

Objectives: The aim of this study was to evaluate the knowledge level of influenza and pneumococcal vaccine in physicians.

Methods: A questionnaire including questions about influenza and pneumococcal vaccine were performed to physicians who work in Dr. Suat Günsel Kyrenia University Hospital and Near East University School of Medicine.

Results: There were 38 female (56,7%) and 29 male (43,3%), totally 67 physician were enrolled. The mean age was 39,3±12,5 years. Eighty one percent of physicians stated that adult vaccination is effective. There was no significant difference in gender about the efficacy of adult vaccination ($p = 0,2$). Although 92.5% of the respondents indicated that they had knowledge about influenza vaccination, the pneumococcal vaccine (76.1%) was less well known. Similarly, the pneumococcal vaccine (73.1%) was less known than the influenza vaccine (92.5%) in reducing the risk of infection. Fifty-eight percent of the physicians had influenza vaccination and the rate of influenza vaccination was similar in both gender. Only 3 (4.5%) of the physicians had pneumococcal vaccine and all were female. There were 24 (35.8%) general practitioners and 43 (64.2%) specialist in the study. 83.7% of specialists and 79.2% of general practitioners thought that adult vaccines were effective ($p = 0.6$). The rate of influenza vaccination among specialists was higher than that of general practitioners (67.4% vs 41.7%, $p = 0.04$). However, the rates of pneumococcal vaccination were low and similar in both groups ($p = 0,3$). All of the influenza vaccinated specialists indicated that their colleague had recommended the vaccination but the colleague recommendation was 70% in the general practitioners and the difference was significant ($p = 0.009$). Among vaccinated specialists and general practitioners, the proportion of people who thought that vaccination was beneficial found similar (72.4% vs 70%, $p = 0.6$). In both specialists and general practitioners, the most common reason for not having the vaccine was the belief of not being in the risk group ($p = 0.9$). While the knowledge level of influenza vaccination was similar between practitioners and specialists, the knowledge level of pneumococcal vaccination in general practitioners was found to be statistically lower than specialists ($p < 0.05$).

Conclusion: Although influenza vaccine and the effect of vaccine in reducing the incidence of infection are well known among physicians, the pneumococcal vaccine is not well known. This is especially true for general practitioners. It is suggested that training about vaccination for both specialists and general practitioners are important for preventive medicine.

Keywords: Influenza vaccination, knowledge, physician, pneumococcal vaccination

[Abstract:0087] EPS-002 [Accepted: E-Poster] [Asthma and Allergy]

Relationship between obesity and asthma in adults

Füsün Fakılı¹, Türkan Mete²

¹Şehitkamil Public Hospital, Gaziantep, Turkey

²Samsun Training and Research Hospital, Samsun, Turkey

Objectives: The relationship with chronic diseases such as asthma has begun to investigated along with increased obesity worldwide. Several studies have shown that differences asthma control, hospitalizations, due to quality of life among obese-asthmatic and normal body mass index-asthmatics. The aim of this study was to investigate the asthma frequency and respiratory functions and accompanying comorbidities in obese men and women who applied to the endocrinology and metabolism clinic for obesity.

Methods: 50 female and 46 male patients with a body mass index (BMI) of 30 kg /m² or more not a known asthma diagnosis between the ages of 18 and 65, who were admitted to the outpatient clinic, were included in the study. 32 women, 22 men with a BMI of 16-24 kg / m² were included in the control group. All participants were enrolled by a chest physician and spirometry tested by the pulmonary department nurse. Asthma diagnosis was made according to the Global Initiative for Asthma 2015 recommendations. The height and weight were measured. The blood pressure arterial values were recorded. Fasting blood glucose, lipid profiles and oxygen free pulse oximeter values were evaluated.

Results: 96 obese and 54 normal-BMI of the 150 patients included in the study. Mean BMI was 38.2 kg/m² (SD 6.44) in obese and 21.1 kg/m² (SD 3.12) nonobese group (P<0.001). The patients in the obese group were significantly older than those in the nonobese group (P<0.001). 88.2 % of the patients were obese aged 40 and over and the difference was significant. Although the rate of smoking in the normal group was higher, there was no significant difference (P=0.150). Hypertension and diabetes were significantly higher in the obese group as expected. In spirometric measurements, there was no significant difference in mean FEV1 as percent predicted (P=0.227) in both groups. The mean forced vital capacity (FVC) was 86.72% (SS: 10.17) in the non-obese group and 77.55% (SS: 14.75) in the obese group and the difference was significant (P= 0.001). Mean FEV1/FVC ratio was 79.45% (SS: 12.27) in the non-obese group and 83.79% (SS: 9.62) in the obese group and the difference was found to be significantly lower (P=0.048). The frequency of asthma diagnosis was 39 (40.6%) in obese group and 22 (40.7%) in normal group. There was no significant difference between these rates (p = 0.989).

Conclusion: Although our study is subject to the limitations of cross-sectional studies, obesity was not associated with asthma in a population of adults from the Adiyaman.

Keywords: Asthma, obesity, spirometry, epidemiology

Table 1. Demographic Features and comorbidities

	Obese group (N=96)	Non-obese group (N=54)	P
BMI, kg/m ²	38.21 (6.44)	21.19 (3.12)	<0.001
Age,y	42.69 (12.87)	31.66 (11.66)	<0.001
Sex (M/F)	46/50	22/32	P=0.397
Smoking	34.4%	46.3%	P=0.150
Hypertension	37 (38.5%)	8 (14.8%)	<0.002
Diabetes	34 (35.4%)	4 (7.4%)	<0.001

[Abstract:0088] SS-041 [Accepted:Oral Presentation] [Respiratory Infections]

Predictors of Increased Mortality in Renal Transplant Patients with Invasive Pulmonary Aspergillus Infection

Baran Balcan¹, Aylin Özsanckalı Uğurlu²

¹Department of Pulmonary Medicine and Intensive Care, Marmara University School of Medicine, İstanbul, Turkey

²Department of Pulmonary Medicine, Başkent University School of Medicine, Ankara, Turkey

Objectives: Renal transplantation is the most effective and preferred definite treatment option in patients with end-stage renal disease (ESRD). Due to long-term immune-suppressive treatment, renal transplant recipients become vulnerable to opportunistic infections, especially to fungal infections. Calcineurin inhibitors (tacrolimus and sirolimus) are the primarily preferred immune-suppressive treatments in renal transplant patients, and use of these drugs also result in susceptibility to fungal infections. In this study, we evaluated outcomes and mortality of renal transplant patients with IPA infections. Moreover, factors that affected mortality, and the association of mortality with delayed anti-fungal treatment were evaluated.




Figure 1.

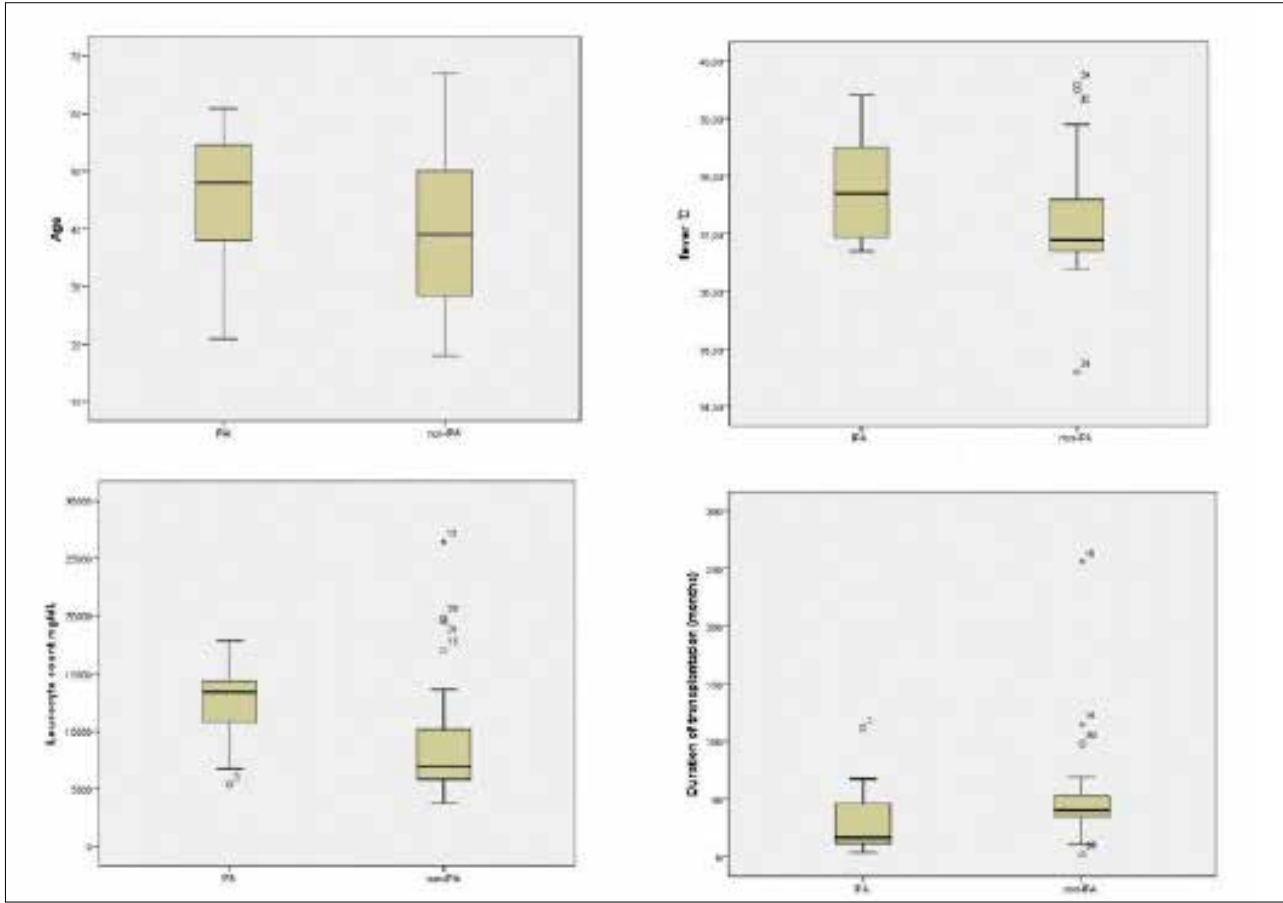


Figure 2.

Methods: This was a single center, retrospective observational study of 438 patients who underwent renal transplantation between 2010 and 2016. Aspergillus diagnosis was based on clinical presentation, radiologic findings, unresponsiveness to anti-bacterial treatment, microbiologic evaluation, and biopsy.

Results: Thirty-eight renal transplant recipients who had lower respiratory tract (LRT) infection with median age of 41.5 years were evaluated. 52.6% were female, most of them (84.2%) had renal transplantation from an alive donor. Eleven of 38 pneumonia patients were accepted as having invasive pulmonary aspergillus (IPA) infection. Five of these patients were classified as proven IPA. CT results were classified as clear (13.2%), nodular opacity (18.4%), nodular opacity + infiltration (10.5%), and infiltration only (57.9%). In comparison of IPA and non-IPA patients it was observed that; IPA patients were older, they had higher degree of fever and leucocyte count at baseline, and mortality was higher in those subjects. Having fever at the baseline, and IPA infection was significantly associated with mortality in univariate logistic regression analysis. IPA infection remained significant in multivariate analysis.

Conclusion: Fungal infections of lung in immune-suppressive patients should be diagnosed immediately in order to avoid the life threatening complications and may greatly improve prognosis.

Keywords: Invasive pulmonary aspergillus, mortality, renal transplant

[Abstract:0091] EPS-060 [Accepted: E-Poster] [Diagnostic Methods]

Two Cases of Pulmonary Thromboembolism Incidentally Diagnosed by Endobronchial Ultrasound

Ezgi Demirdöğen Çetinoğlu, Ahmet Ursavaş, Aslı Görek Dilektaşlı, Özge Aydın Güçlü, Mehmet Karadağ

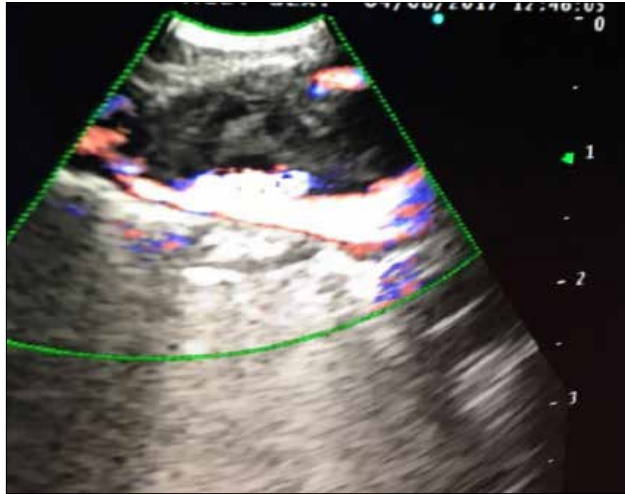

Figure 1a). Case 1: EBUS power doppler image. Echogenic filling defect in the left pulmonary artery branch.

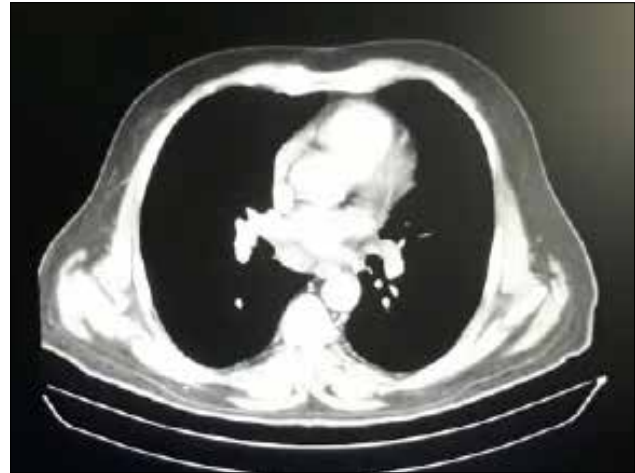

Figure 2a). Case 1: Contrast enhanced thorax computed tomography image. Thrombus formation in left lower pulmonary artery

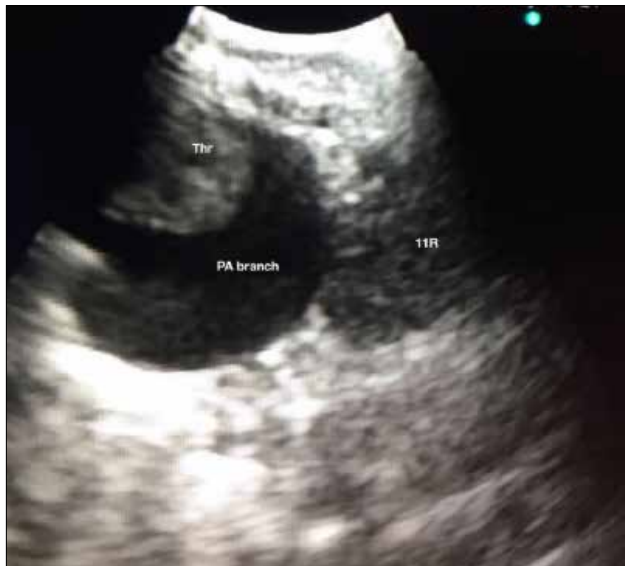

Figure 1b). Case 2: EBUS gray-scale image. Images of thrombus adjacent to 11R lymph node on the EBUS

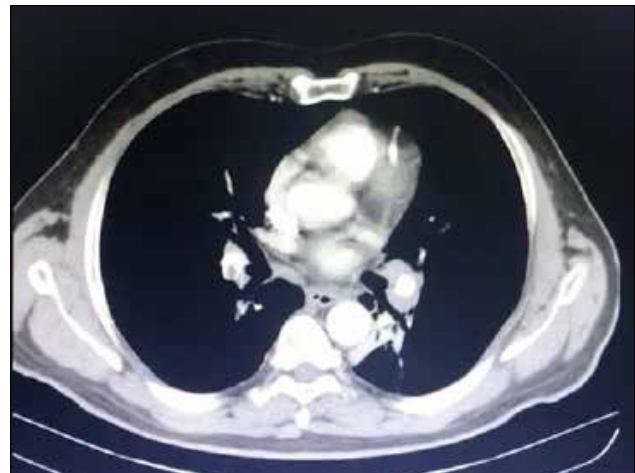


Figure 2b). Case 2: Contrast enhanced thorax computed tomography image. Thrombus formation leading to partial obstruction in pulmonary artery branch of right lower lobe

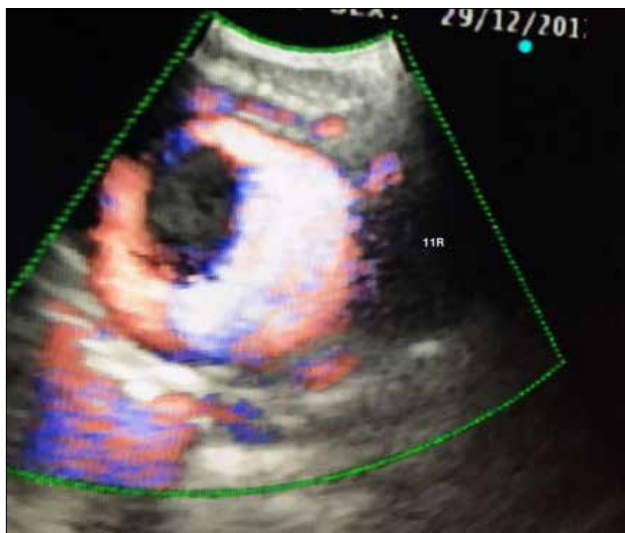

Figure 1c). Case 2: EBUS power doppler image. Echogenic mass in the left pulmonary artery without blood flow in right pulmonary artery branch

Endobronchial ultrasound (EBUS) is a very important diagnostic tool in patients with mediastinal/hilar lymph nodes and masses. We performed 302 convex probe (CP) -EBUS (BF-UC180F; Olympus, Tokyo, Japan) procedures between May 2016 and Dec 2017 with different indications. We present two of these patients, 62 and 54-year-old male, incidentally diagnosed with pulmonary thromboembolism (PTE) during the procedure. Symptoms were unremarkable, except mild effort dyspnea. One of these patients has operated colon adenocarcinoma (case 1) and the other one has been followed with bladder cancer (case 2). The EBUS indication was the same in both cases, suspicion of mediastinal metastasis. Thrombus formation in left (case 1- Fig1a) and right central pulmonary artery branch (case 2- Fig 1b-c) were obtained incidentally on view of EBUS gray-scale sonograms and power doppler images. We confirmed the diagnosis with contrast enhanced thorax CT, (Fig 2a and Fig 2b) and started to treatment of submassive pulmonary embolism with low-molecular-weight heparin (LMWH) as recommended by the guidelines. EBUS- transbronchial needle aspiration (TBNA) smear and cell block results were found with compatible urothelial carcinoma metastasis in patient with bladder carcinoma. Important point that bronchoscopists should be carefully examined vascular structures as well as the mediastinal lymph nodes with CP-EBUS, especially in patients with malignancy.

Keywords: Endobronchial ultrasound, convex probe, pulmonary thromboembolism, diagnosis

[Abstract:0092] PS-101 [Accepted:Poster Presentation] [Pulmonary Rehabilitation and Chronic Care]

Is There an Association Between Disability Level Caused By Low Back Pain And Respiratory Muscle Force And Respiratory Functions?

Furkan Özdemir¹, Melis Çayır², Neslihan Durutürk¹

¹Department of Physiotherapy and Rehabilitation, Faculty of Health Sciences, Başkent University, Ankara, Turkey

²Department of Physical Medicine and Rehabilitation, Başkent University Ankara Hospital, Ankara, Turkey

Objectives: Basic function for keeping both during activity and static positions at body starts with core region's stabilization. This function provide by muscles that are surrounding core region which are especially diaphragm and musculus transversus abdominus on besides pelvik floor muscles and lumbar extensor muscles. Researchs indicate a relationship between poor core stabilization and chronic non-specific low back pain and disordered stability function may cause failure at these muscles activity, breathing pattern, pulmonary functions and mechanichs of diaphragm. It is reported that low back pain and diaphragm dysfunction are coexistent oftenly and patients with low back pain are more sensitive to fatigue of diaphragm at literature, at the same time. It is showed that there is an association between decreased stabilization and increased respiratory demand. Considering these informations, our aim is exploring that is there an association between disability level caused by low back pain and respiratory muscle force, respiratory functions.

Methods: Fifteen patients with low back pain (9:F/6:M) included this research. Participants'disability level caused by low back pain assessed with Turkish version of "Oswestry Disability Index" (ODI). Participants'respiratory functions measured by pulmonary function test, respiratory muscle force assesed with maximal inspiratory mouth pressure measurement.

Results: Results of statistical analysis showed statistically significant correlation between ODI score and sub parameters of respiratory muscle force (S-Index and Flow (both $p<0.01$)). Correlation between ODI score and pulmonary functions test results is not statistically significant.

Conclusion: It is reported that low back pain causes impairment on diaphragm mechanics and respiratory function at literature but there ise another research about effects of disability caused by low back pain on respiratory system's function. Our results showed that as ODI score increases, respiratory muscle force may decrease critically. It should research that relation with more participants and different disease.

Keywords: Low back pain, respiratory function test, respiratory muscle

[Abstract:0093] PS-168 [Accepted:Poster Presentation] [Tuberculosis]

Evaluation of Three Cases with Beijing Strains of Mycobacterium Tuberculosis

Merve Karaman¹, Aylın Babalık¹, Fatma Kutluhan¹, Begüm Oğur¹, Ayşe Rümeyza Hazine¹, Kaya Köksalan²

¹Health Sciences University İstanbul Süryapaşa Pulmonary Diseases and Chest Surgery Training and Research Hospital, İstanbul, Turkey

²İstanbul University Aziz Sançar Research Institute for Experimental Medicine, İstanbul, Turkey

Objectives: Beijing strain of Mycobacterium tuberculosis was first described 20 years ago in the Chinese capital. Beijing strain is mostly associated with multiple drug resistance.

Methods: Three tuberculosis cases with Beijing strain of Mycobacterium tuberculosis were evaluated in terms of age, gender, nationality, microbiological, drug susceptibility test, radiology and treatment.

Results:

Case 1: A 38-year-old female patient from Uzbekistan was admitted with complaints of cough, sputum and weight loss for about 4 months. The new case of smear-positive pulmonary tuberculosis was found HRES resistant with phenotypic drug resistance test, rifampicin-resistant Beijing strains with molecular drug resistance test in the DETAE (Research Institute for Experimental Medicine). In TULSA, HR and ethionamide resistance was detected. Treatment started moxifloxacin, thioamide, cycloserine, pyrazinamide, amikacin, PAS.

Case 2: A 69-year-old female patient from TR, was admitted with complaints of cough, night sweats, weakness, weight loss, loss of appetite, nausea and vomiting for 6 months. The new case of smear-negative, culture-positive pulmonary tuberculosis was found HRES-resistant with phenotypic drug resistance test, rifampicin-resistant Beijing strains with molecular drug resistance test in DETAE. In TULSA, HR and ethionamide resistance was detected. Treatment was started moxifloxacin, amikacin, thionamid, cycloserine, pyrazinamide, PAS.

Case 3: A 46-year-old woman from TR was admitted with a complaint of cough for 3 months. Mycobacterium tuberculosis was isolated in bronchial lavage bacterial culture. The smear negative culture-positive lung tuberculosis new case was found to be HRES resistant with phenotypic drug resistance test, rifampicin-resistant Beijing strain with molecular drug resistance test in DETAE. In the TULSA, HR and ethionamide resistance was detected. Treatment started moxifloxacin, amikacin, cycloserine, thionamid, PAS, prazinamide

Conclusion: Beijing strains has recently spread globally and also in our society.

Keywords: Bejiin, MDR, TB

[Abstract:0095] PS-285 [Accepted:Poster Presentation] [Respiratory Failure and Intensive Care]

Preoperative Incentive Spirometry Exercise Reduces the Risk of Atelectasis in Obese CABG Patients

Özlem Erçen Diken¹, Adem İlkey Diken²

¹Department of Chest Diseases, Hitit University School of Medicine, Çorum, Turkey

²Department of Cardiovascular Surgery, Hitit University School of Medicine, Çorum, Turkey

Objectives: General anesthesia, accumulation of secretions, impaired ciliary activity, alterations of surfactant metabolism and suspended ventilation during perfusion result in atelectasis development in cardiac surgery. Obese patients are particularly at high risk for the development of atelectasis. We sought to evaluate the influence of preoperative precautions for atelectasis, such as incentive spirometers, on postoperative pulmonary outcome.

Methods: Hemodynamically stable patients scheduled for elective isolated coronary artery bypass surgery with a body mass index over 30 kg/m² and without previous pulmonary disease were enrolled into the study. All patients performed pulmonary function tests prior to surgery and results were considered in normal limits. Patients who do not have willingness to participate into the study or have limitations for spirometry (orthopedically handicapped, incorporated, etc.) were excluded. A total of 108 patients were included into the study. Of them, 58 patients were underwent CABG by standard preoperative care (Group 1) while remaining 50 patients had pulmonary exercise with incentive spirometer (Triflo) in preoperative period (Group 2). Incentive spirometer was used at least 10 times every hour during daytime. Postoperative follow up data and chest X-rays were investigated for the presence of atelectasis.

Results: Preoperative characteristics including age, gender, mean BMI, comorbid conditions were similar between the two groups. Mean extubation time (7,02±1,2 vs. 6,91±0,9 hours), SpO₂ (93% vs. 94%) and PCO₂ (38,3±3,2 vs. 36,1±2,7) values were also similar in postoperative period. Atelectasis was diagnosed in 23,14 % of the study population. Patients with atelectasis were predominantly higher in Group 1 (18 vs. 7 patients, P=0,036). 2 patients had pneumonia and needed prolonged antibiotherapy on postoperative course in Group 1.

Conclusion: Atelectasis is a major problem following general anesthesia, particularly in cardiac surgery. Breathing exercise with incentive spirometer in obese patients prior to surgery revealed lower rate of atelectasis and pneumonia. This benefit may be higher in high pulmonary risk patients which must be evaluated in further studies.

Keywords: Atelectasis, incentive spirometry, CABG, obesity

[Abstract:0096] PS-164 [Accepted:Poster Presentation] [Tuberculosis]

Extensively Drug-Resistant Tuberculosis: 9 Cases

Aylin Babalık¹, Tülin Kuyucu¹, Olga Akkan¹, Gül Dönmez¹, Fatma Kutluhan¹, Kaya Köksalan²

¹Health Sciences University İstanbul Süreyyapaşa Chest Diseases and Chest Surgery Training and Research Hospital, İstanbul, Turkey

²Aziz Sancar Institute of Experimental Medicine, İstanbul, Turkey

Objectives: Globally in 2016, XDR-TB was detected 6.2% of MDR TB. Extensively drug-resistant TB (XDR-TB) is defined as MDR-TB plus resistance to at least one drug in both of the two most important classes of medicines in an MDR-TB regimen: fluoroquinolones and second-line injectable agents (amikacin, capreomycin or kanamycin).

Methods: In our study, we evaluated the patients who were diagnosed and treated as XDR TB between the years 2014-2017 in our hospital. Patients' age, gender, nationality, resistance patterns, treatments regimens, treatment results, sputum and culture conversion were evaluated.

Results: 9 XDR TB Patients who were diagnosis and treated were included in our research. Average age of patients was 31. 4 of 9 patients were male. Patients' nationality was reported; Azerbaijan: 4, Turkmenistan: 3, Republic of Turkey: 2. 7 of 9 cases were from İstanbul, 2 of 9 cases were from Bursa. 7 of 9 cases were previously treated with first and second line tuberculosis drugs. Average of number resistant tuberculosis drugs were found 7. Planned treatment duration was 24 month. Linezolid was used in all of patients' treatment. Clofazimine was used in 8 of 9 patients. Capreomycin was used 8 of 9 patients. Bedaquiline was used 2 of 9 patients. Culture conversion average month was detected 2.8 month. Treatment result was evaluated, cure: 4, treatment default: 1, under treatment: 4.

Conclusion: XDR TB threatens global TB control. Due to migration from countries with high resistance rates, XDR TB cases have begun to appear in our society. The lack of medication and new treatment regimens make it difficult to treat XDR-TB. New drugs and treatment regimens are needed.

Keywords: Extensively drug-resistant, TB, treatment

[Abstract:0097] PS-284 [Accepted:Poster Presentation] [Respiratory Failure and Intensive Care]

A New Diagnostic Approach in Non-Resolving ARDS: Cryobiopsy

Begüm Ergan¹, Kutlay Aydın², Kemal Can Tertemiz³, Duygu Gürel⁴, Eyüp Sabri Uçan³

¹Department of Pulmonary and Critical Care, Division of Intensive Care, Dokuz Eylül University School of Medicine, İzmir, Turkey

²Intensive Care Unit, Dokuz Eylül University School of Medicine, İzmir, Turkey

³Department of Pulmonary and Critical Care, Dokuz Eylül University School of Medicine, İzmir, Turkey

⁴Department of Pathology, Dokuz Eylül University School of Medicine, İzmir, Turkey

Introduction: Diffuse alveolar damage is the classical pathologic finding in acute respiratory distress syndrome (ARDS). The open lung biopsy may be helpful in the differential diagnosis in non-resolving ARDS. Herein, we present the diagnostic approach with fiberoptic bronchoscopy and cryobiopsy in a patient with non-resolving ARDS.

Case Presentation: A 66-year-old female with a history of mitral valvuloplasty and hypothyroidism presented to emergency room with the complaint of progressive dyspnea. The clinical and radiological signs were consistent with pneumonia and she was started on levofloxacin and oseltamivir with the diagnosis of community-acquired pneumonia. During follow up, she deteriorated and her oxygen saturations were dropped under high flow nasal oxygen. She was then intubated and transferred to intensive care unit (Figure 1). She was diagnosed with ARDS according to Berlin criteria and ventilated with lung protective strategy. Antibiotherapy was modified and vasopressor therapy was initiated due to septic shock. On the 6th week, her clinical status was improved however a new tomography scan was ordered because diffuse infiltrations on chest x-ray did not respond to therapy (Figure 2). Fiberoptic bronchoscopy was performed but the result of broncho-alveolar lavage was non-diagnostic. For differential diagnosis, a second fiberoptic bronchoscopy and cryobiopsy from the lung tissue was performed. The pathologic evaluation of the biopsy specimens showed organizing pneumonia pattern. The patient was started on corticosteroid treatment. Her clinical status and radiologic findings improved dramatically and the patient was transferred

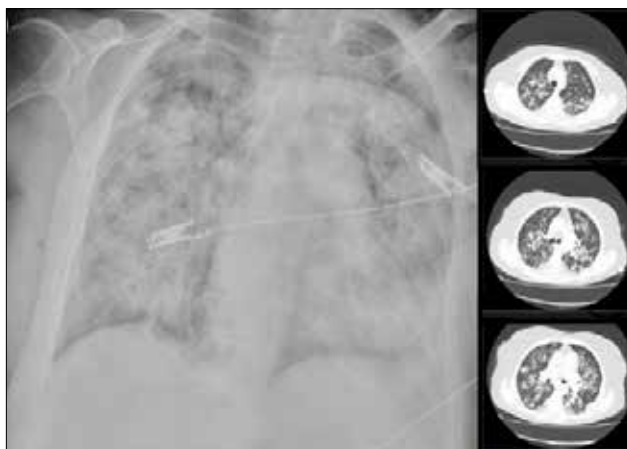


Figure 1. Radiologic images before intensive care unit admission

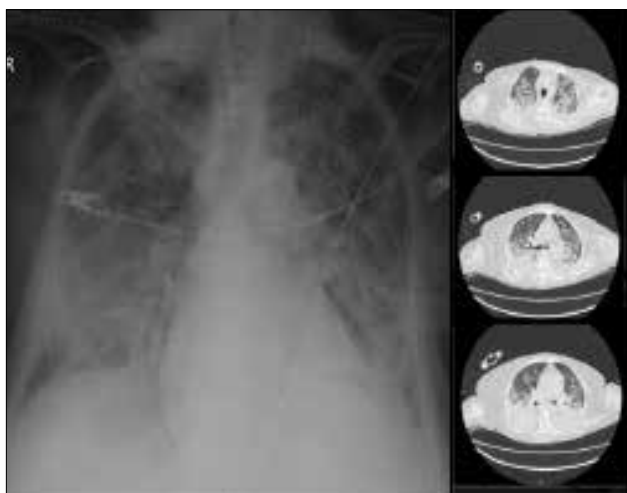


Figure 2. Radiologic images before cryobiopsy

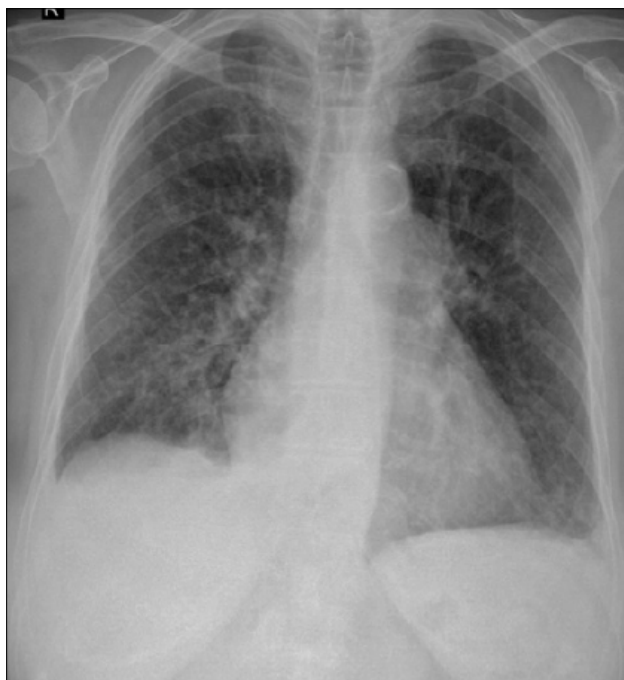


Figure 3. Control chest x-ray after 2 months of discharge

to the ward after successful weaning from the ventilator. Following discharge, she was well in her outpatient clinic control (Figure 3).

Conclusion: The reason of non-resolving ARDS is thought to be due to organizing pneumonia in this case. This is supported by the full response to corticosteroid therapy, which was started according to cryobiopsy result. Cryobiopsy may be a promising tool in the intensive care unit setting for the differential diagnosis in selected patients.

Keywords: ARDS, organized pneumonia, cryobiopsy

[Abstract:0098] SS-007 [Accepted:Oral Presentation] [Clinic Problems - Others]

An Observational Registration Study in Adult Non-Cystic Fibrosis Bronchiectasis Patients: Real Life Data

Derlen Özgeç, Serir Özkan, İhsan Topaloğlu, Türkan Dizdar, İlker Özdemir, Mehmet Gülpek

Dr. Suat Seren Thoracic Diseases and Surgery Training and Research Hospital, İzmir, Turkey

Objectives: In this study, epidemiological, clinical, microbiological and radiological characteristics, quality of life and survival of patients with NCFB were investigated. The results of two prognostic scoring systems associated with NCFB (BSI and FACED) were compared. The patients with high risk of exacerbation, hospitalization, and mortality were described. The severity of bronchiectasis was also assessed.

Methods: In this prospective observational study, 101 patients over 18 years of age who diagnosed NCFB were included. Demographic, clinical, radiographic, physiological, laboratory and therapeutic properties were investigated. All patients were questioned for the mMRC dyspnea scale, number of exacerbations during the last one year, hospitalization status for the last two year, vaccination status, pulmonary rehabilitation and respiratory physiotherapy stories. To assess the severity of bronchiectasis and quality of life, FACED and BSI Score, SF-36 Quality of Life Questionnaire were administered and survival analysis was performed. The results of the BSI and FACED Scores were compared in terms of correlation.

Results: In this study 52 (51.5%) of the patients were female and 49 (48.5%) were male. The number of patients with at least 1 exacerbation in a previous year was 98 (97%) and the number of patients with at least 3 exacerbation was 28 (27.7%). The number of patients hospitalized in the last two years was 48 (47.5%). The mean number of hospitalizations was 0.86 ± 1.18 . The microorganisms leading to chronic bronchial colonization were; 16 (15.8%) *P. Aeruginosa*, 1 (0.9%) *E. Coli*, 1 (0.9%) *H. Influenza*, 1 (0.9%) *S. Pneumonia* and 3 (%2,9) NTM. According to FACED Score; 49 (48.5%) patients were mild, 48 (47.5%) were moderate and 4 (4%) patients were in severe bronchiectasis. According to BSI Score; 35 (34.7%) were mild, 15 (14.9%) were moderate and 51 (50.4%) were in severe bronchiectasis. The correlation between the two scoring systems was found low according to the Kappa statistical method. There was a significant association between the frequency of exacerbation and the worsening of quality of life. The cumulative survival rate of this cohort is 90.2 ± 3.8 at the first year. The cumulative survival rate of severe cases according to the BSI was 81.5 ± 6.7 at the first year. The cumulative survival rate of cases with chronic bronchial *Pseudomonas* colonization was 79.1 ± 13.8 at the first year.

Conclusion: Approximately half of the cohort has been hospitalized due to illness in the last two years. The mortality of patients at severe group according to the BSI is worse than the general cohort. Chronic bronchial colonization was detected in 21,7% of the patients and the main causative microorganism was *Pseudomonas aeruginosa*. The mortality in patients with *Pseudomonas* colonization is worse than the general cohort. According to the BSI or FACED score, NCFB cases with severe group and *Pseudomonas* colonization should be monitored more closely.

Keywords: Non-cystic fibrosis bronchiectasis, bronchiectasis severity index, FACED score

Table. Demographic, clinical and radiological features in patients with NCFB

Features	Patient (n=101)
Female	52
Male	49
Mean age	54,73±16,24
Mean BMI kg.m ⁻²	23,79±3,5
Smoking n (%)	
never smoked	53 (52,5)
ex-smoker	42 (41,6)
still smoking	6 (5,9)
Comorbid diseases n (%)	
COPD	36 (35,6)
Asthma	19 (18,8)
Hypertension	28 (27,7)
Diabetes Mellitus	4 (3,9)
Congestive Heart Failure	2 (1,9)
Gout	1 (0,9)
Familial mediterranean fever	1 (0,9)
Number of exacerbations in last one year (mean)	1,95±1,27
Number of hospitalization in last 2 years (mean)	0,86±1,18
Radiological prevalence <3 lobe	66 (%65,3)
≥3 lobe	35 (%34,7)

[Abstract:0100] PS-272 [Accepted:Poster Presentation] [Sleep-related Disorders]

Evaluation of Dynamic Thiol/Disulfide Homeostasis in Patients with Obstructive Sleep Apnea

Gülgün Çetintaş Afşar¹, Fatma Merve Tepetam², İsmet Bulut², Saraç Sema², Özgür Bilgin Topçuoğlu¹, Murat Alişık³, Özcan Erel³

¹Department of Sleep Laboratory, Health Sciences University Süreyyapaşa Chest Diseases and Thoracic Surgery Training and Research Hospital, İstanbul, Turkey

²Department of Immunology and Allergy, Health Sciences University Süreyyapaşa Chest Diseases and Thoracic Surgery Training and Research Hospital, İstanbul, Turkey

³Department of Clinical Biochemistry, Yıldırım Beyazıt University School of Medicine, Ankara, Turkey

Objectives: Hypoxia-reoxygenation cycles may cause oxidative stress in Obstructive sleep apnea (OSA). Dynamic thiol/disulfide homeostasis is play a role in detoxification, apoptosis, regulation of signaling pathways and enzymatic reactions. But increasing release of oxygen-free radicals beyond physiological antioxidant capacity, abnormal thiol/disulfide concentrations can be seen associated with oxidative stress in OSA. We aimed in the study to evaluate the OSA association with oxidative stress, using thiol-disulfide homeostasis method. We also evaluated the correlations between oxygen desaturation index (ODI) and oksidative stress.

Methods: Patients with OSA group described as obstructive apnea/hypopnea index (AHI) ≥ 5 . Healthy control group were chosen from our outpatient clinic who never snored with AHI < 5 . Patients with smoking history, infectious disease, comor-

Table. Thiol/disulphide levels and ratios between the OSA and control groups

	OSA group (n = 20)	Control group (n = 17)	p value*
-SH mmol l ⁻¹	314.34±45.65	303.17±50.72	0.48
-SH + -SS- mmol l ⁻¹	354.75±42.16	328.25±54.46	0.10
-SS- mmol l ⁻¹	20.20±8.07	12.53±4.89	0.002*
-SS-/ -SH,%	6.72±3.20	4.17±1.66	0.006*
-SS-/ -SH + -SS-,%	5.79±2.43	3.81±1.40	0.006*
-SH /-SH + -SS-,%	88.41±4.87	92.37±2.81	0.006*

Abbreviations: -SH: Native Thiol; -SH + -S-S-: Total Thiol; -S-S-: Disulfide. Results were given as mean±sd. *P value < 0.05 considered statistically significant.

bidities that increase oxidative stress and using any antioxidant agent were excluded. After excluded patients with high BMI (≥ 31 kg/m²) which may affect the thiol-disulfide homeostasis and matched the groups in terms of mean age, sex and BMI in the final study population there were 20 patients with OSA and 17 patients with controls.

Results: The disulfide level and ratios were significantly higher and mean native/total thiol ratio was significantly lower in the OSA group than in the control group ($p < 0.01$). When we compare AHI < 30 and AHI ≥ 30 while native thiol was significantly higher ($p = 0.034$), disulfide ratios were lower in severe group but not statistically significant ($p = 0.052$). Although we did not find any correlation between AHI and thiol/disulfide homeostasis we explored negative correlations between the ODI and the disulfide level, ratios and positive correlations between the ODI and the native/total thiol ratio.

Conclusion: Thiol/disulfide homeostasis can be an indicator of oxidative stress in OSA. But most of the OSA patients may have high BMI so it should not be forgotten that the measurements may be affected by this situation. By increasing of OSA severity reduction of oxidative stress, was shown in our study, suggests that some factors like duration of disease and compensation in early time that influence the thiol levels might be.

Keywords: Thiol, disulfide, oxidative stres, OSA.

[Abstract:0103] EPS-127 [Accepted: E-Poster] [Pediatric Pulmonary Diseases]

Use of Computer Programs in The Diagnosis of Small Bronchial Diseases in Children

Ilgar Almas Mustafayev¹, Lale İsmayıl Allahverdiyeva², Alevtina Viktor Bogdanova³, Artyom Valeriy Tişkov⁴

¹Research Institute of Lung Diseases, Baku, Azerbaijan

²Medical State University, Baku, Azerbaijan

³Research Institute of Pulmonology, Sankt-Petersburg, Russia

⁴The First Medical University, Sankt-Petersburg, Russia

Objectives: Severity and frequency of chronic bronchial diseases in early and preschool years. The leading clinical finding of bronchoobstructive syndrome, which is the cause of diagnostic errors. Low level of diagnostic complexity at the level of primary health care, inadequate access to specialized medical care. Prevention of financial costs in diagnosing and conducting therapeutic rehabilitation activities. Implementation of electronic system for the diagnosis of small bronchial diseases

Methods: 112 children with bronchial asthma (male-96, female-16), 139 patients with obliterated bronchiolitis (male-82, female-57) and 103 children with bronchopulmonary dysplasia in (male-58, female-45) were under the control. A questionnaire consisting of 37 questions for each patient was completed and included in the electronic database. The card reflects the results of genetic, perinatal history, manifestation of disease and clinical course, radiological, functional, laboratory findings. In order to obtain the possibility of these diseases, collected material was analyzed with Microsoft Access program.

Results: 4 to 10 responses were prepared for each question.

Example 1: How birth has passed: norm-1, premature birth (25-26 weeks) -2, fast birth-3, prolonged anhydrous period -4, stimulation at birth-5, cesarean 6-, other birth methods-7.

Example 2: Characteristics of the first four weeks of life: norm-1 was treated in the neonatal pathology section-2, intensive care unit -3, artificial ventilation (RDS indication) -4

Example 3: First year of life feature: not patient-1, patient (shortness of breath, coughing, distant popping, sleep and malnutrition) - 2, presence of cutaneous signs of allergy - 3, seizures - 4, gastrointestinal disturbances - 5, regurgitation presence / vomiting-6, constipation tendency-7, diarrhea tendency-8, perephivaniya-9

Example 4: Radiographic changes: reversible signs-3, irreversible-4, hyperinflation-5, rough ventilation findings-6, atelectasis findings -7, increased interstitial pattern-8, peribronchial changes- 9, bronchiectasis-10

The greatest number of points allowed to diagnose the presence of one of the three forms of bronchopulmonary pathology

Conclusion:

1. The diagnosis of computerized diagnosis in primary health care facilities usually removes diagnostic errors from the diagnosis of broncho-obstructive syndrome
2. It is possible to enlighten the diagnosis of diseases without using expensive diagnostic methods and to start the relevant, early, adequate therapy
3. Using the surveys, it is possible to monitor the disease dynamically and monitor the course of the disease and its prognosis
4. It is possible to predict the full recovery of childhood or the development of chronic non-specific pulmonary pathology in these patients

Keywords: Bronchial asthma, bronchiolitis obliterans, bronchopulmonary dysplasia

[Abstract:0105] EPS-168 [Accepted: E-Poster] [Sleep-related Disorders]

The Effect of Unilateral Forced Nostril Breathing on Sleep Physiology

Ömer Araz¹, Deniz Öztürk², Elif Yılmazel Uçar¹, Metin Akgun¹

¹Department of Pulmonary Diseases, Atatürk University School of Medicine, Erzurum, Turkey

²Atatürk University, Health Services Vocational School, Erzurum, Erzurum, Turkey

Objectives: Although we spend about one-third of our lives in sleep and recognize its necessity for good health, sleep physiology has only been partially elucidated in the last century. The nasal cycle of congestion and decongestion during sleep

Table 1.

	Normal Sleep (n=21)	Right Nasal Obstruction (n=21)	Left Nasal Obstruction (n=21)
Sleep Latency (minutes/night)	6.29±7.02	8.09±5.26	7.52±5.88
REM Latency (minutes/night)	74.48±50.95	98.86±50.30	72.62±51.33
Sleep Efficiency (%)	90.95±5.65	87.81±7.37	91.76±5.69
Total Sleep Time (hours/night)	6.14±0.73	6.00±0.55	6.23±0.77
Apnea hypopnea index	1.52±1.22	3.33±3.41	1.81±1.44
Average Heart Rate (beats/min)	57.14±5.85	55.52±4.03	58.76±6.32
Periodic Limb Movements (number/min)	8.52±11.98	21.10±27.21	7.19±11.45
Average Waking SaO ₂ (%)	94.43±1.12	93.86±2.90	94.86±1.24
Average O ₂ desaturation (%)	2.71±1.45	2.90±1.37	2.24±1.14

Sleep parameter values obtained during normal sleep and right and left nasal obstruction (mean±SD)

has various effects on human physiology. The aim of the present study was to investigate the effect of unilateral forced nostril breathing on sleep physiology.

Methods: Twenty-one healthy male volunteers aged 18-24 years were included in the study. Only individuals with right-hand dominance were included. Subjects were observed during sleep for three nights under different conditions: no obstruction (normal sleep) on the first night, right nasal obstruction on the second night, and left nasal obstruction on the third night.

Results: The main findings of our study are that sleep efficiency, NREM stage III, and total sleep duration were greater during left nasal obstruction (right nostril dominant respiration), while apnea-hypopnea index (AHI), frequency of periodic limb movements, and oxygen desaturation were higher during right nasal obstruction (left nostril dominant respiration). The data are summarized in Table 1.

Conclusion: The nasal cycle has a significant impact on sleep physiology which is reflected in sleep recordings. Our result support that nasal obstructions, due to deviations, concha hypertrophy or congestion/decongestion, might affect the physiology of respiration and sleep. Nasal obstruction should be taken into consideration when evaluating patients in sleep laboratories and further studies are required elucidate the situation in the patients with nasal obstruction.

Keywords: Sleep, nasal cycle, forced nostril breathing

[Abstract:0108] PS-165 [Accepted:Poster Presentation] [Tuberculosis]

Evolution of Three Cases with Disseminated Tuberculosis

Begüm Oğur, Aylin Babalık, Merve Karaman, Fatma Kutluhan, Ayşe Rümeyza Hazine, Tülin Kuyucu

Health Sciences University Istanbul Süryapaşa Chest Diseases and Chest Surgery Training and Research Hospital, İstanbul, Turkey

Objectives: Disseminated tuberculosis is a form of progressive disease with progressive hematogenous spread.

Methods: Three disseminated tuberculosis cases were evaluated in terms of age, gender, nationality, microbiological, drug susceptibility test, radiology and extrapulmonary findings.

Results:

Case 1: A 26-year-old female patient from Uzbekistan was diagnosed with pleuritic effusion with complaints of cough, fever, chest pain and left hip pain. Pleural effusion with lymphocyte predominance in the exudate is treated by nonspecific treatment. After 7 months later patient re-evaluated with increased complaints, miliary lesions were detected in thorax CT. Sputum smear and bronchial lavage were negative for ARB, M.tuberculosis complex was found to be sensitive to rifampicin in the molecular rapid resistance test. Coxicofemoral MR was compatible with tb sacroileitis (infectious arthritis) Compatible lesions with Miliary tb + sacroileit tb disseminated tuberculosis treatment was planned.

Case 2: A 19-year-old college student male patient from Nigerian was admitted to the right scrotum and groin swelling in June 2016. Scrotal abscess caseous drainage result in the molecular rapid resistance test M.tuberculosis was detected. Chest x-ray showed a consolidated area with right upper bronchial contained air bronchograms. Brain MR end result nodule compatible with tuberculoma in right lateral ventricle junction. Thoracolumbar MRI is compatible with Pott disease. Findings compatible with genitourinary tuberculosis + pulmonary tb + CNS involvement + and findings consistent with Pott's disease evaluated as disseminated tb treatment was planned.

Case 3: A 32-year-old dental technician male patient from TR was admitted with complaints of cough, phlegm, face and leg numbness. Chest X-ray showed infiltration in bilateral upper zones and ARB positivity was detected of sputum samples. Brain MRI was assessed as a 20x19 mm nodular lesion in the right parasagittal region consistent with tuberculoma. Right septic sacroiliitis was detected in coxofemoral MRI. Rapid resistance test revealed M. tuberculosis susceptible to rifampicin. Disseminated tuberculosis treatment was started with lesions compatible with pulmonary tb + MSS tb + Sacroileit tb.

Conclusion: Early diagnosis and early treatment are necessary for the diagnosis of disseminated TB.

Keywords: Disseminated, tuberculosis, miliary

[Abstract:0109] EPS-053 [Accepted: E-Poster] [COPD]

Mounier-Kuhn Syndrome: Case Presentation

Can Çolakoğlu, Serdar Berk

Department of Thoracic Diseases and Tuberculosis, Cumhuriyet University School of Medicine, Sivas, Turkey

Mounier-Kuhn syndrome is characterized by abnormal dilation of the trachea and main bronchi and it is also called tracheobronchomegaly. It was firstly defined in 1932 and it is rarely encountered. Although its etiology is not well known, there are some studies specifying that it is an autosomal recessive disorder. It is more commonly seen in the third and fourth decades and in men. Patients are susceptible to ineffective coughing and lower respiratory tract infections recurring due to impaired mucociliary activity. In most of cases presented in literature, the presence of bronchiectasis, which is a result of recurring respiratory tract infections, draws attention. In the measurements by thoracic computed tomography, trachea diameter of >30 mm, right main bronchus diameter of >20 mm, and left main bronchus diameter of >18 mm are diagnostic values. Bronchial and tracheal diverticulum can coexist with tracheobronchomegaly.

Our case is a 66-year-old male patient who was followed up due to the diagnosis of COPD. Tracheobronchomegaly was viewed in the thoracic computed tomography and the diagnosis of Mounier-Kuhn syndrome was established. This case was presented because of the presence of a few published cases in literature and its coexistence with obstructive respiratory dysfunction.

Keywords: COPD, Mounier-Kuhn syndrome, tracheobronchomegaly

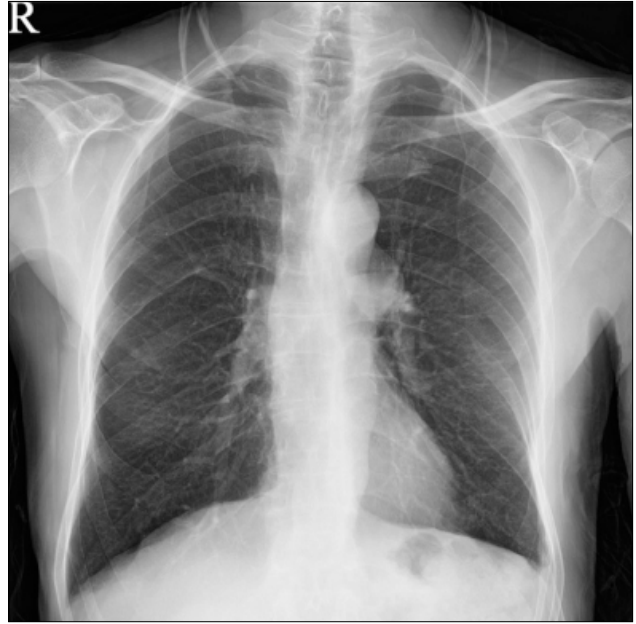


Figure 1. Expansion of the tracheal air column

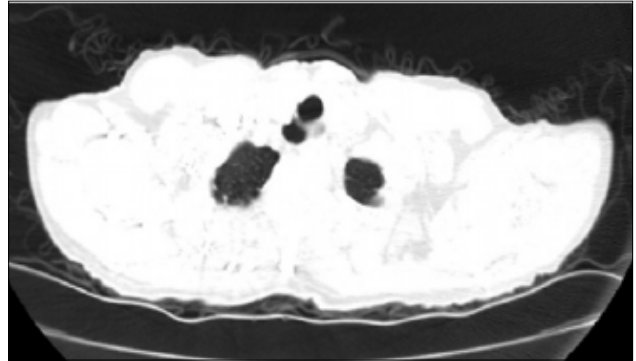


Figure 3. Tracheal diverticulum

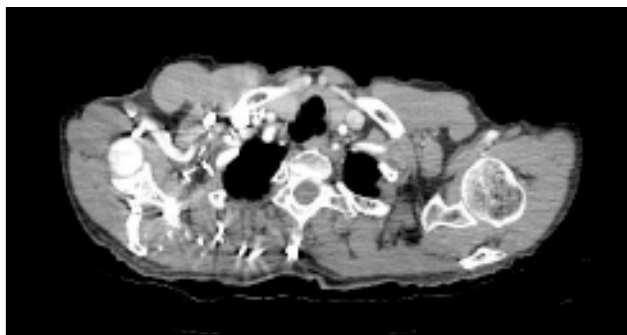


Figure 2. Tracheal Diverticulum

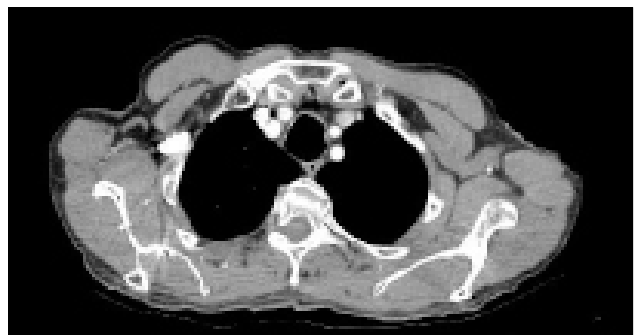


Figure 4. Tracheomegaly

[Abstract:0110] PS-222 [Accepted:Poster Presentation] [COPD]

The Relationship Between the Obestatin Level in COPD and the Severity of the Disease and the Frequency of Exacerbation

Fatma Özdemir¹, İnci Gülmez¹, Eser Kılıç², Nuri Tutar¹, Fatma Sema Oymak¹, İnsu Yılmaz¹

¹Department of Chest Disease, Erciyes University School of Medicine, Kayseri, Turkey

²Department of Biochemistry, Erciyes University School of Medicine, Kayseri, Turkey

Objectives: Obestatin is a 23 amino acid peptidyl isolated from rat guts in 2005 by Zhang et al. for the first time. The post-translational modification of the 117 amino acid preproghrelin peptide encoded by the Ghrelin gene results as obestatin. We had found only one study on obestatin 2014, Yi Lei and colleagues suggested that obestatin levels increase in COPD. Our aim is to investigate the relationship between obestatin levels in patients with COPD stage and the frequency and severity of the exacerbations.

Methods: Five cc blood samples were taken from peripheral arteries after 12 h fasting to study obestatin levels in 60 patients with COPD diagnosed according to 2014 GOLD. The serum was stored at -70 ° C until the assay was run, by centrifuging at 2000 rpm for 20 min at + 4 ° C. The patients' emergency application for the exacerbation of COPD; intensive care hospitalizations and / or hospital admissions were followed for a year. Control group was formed by age, gender, height, weight balance; the control group was followed for one year on the same parameters. Obestatin levels of patients staged according to the 2014 GOLD stage were studied after Kit supply.

Results: SPSS software (Statistical Package for the Social Sciences, version 15.0; SSPS Inc., Chicago, Illinois, USA) was used for statistical analysis. There was no significant difference between obestatin levels and COPD stages in our study. When the relationship between the number of exacerbations and obestatin levels was evaluated, no significant correlation was observed. There was no significant difference between obestatin levels in COPD groups and control groups.

Conclusion: In our study, significant correlation was not be found between the severity of COPD, frequency of exacerbation of COPD. However, further studies involving large patient groups are needed to clarify the subject.

Keywords: COPD, obestatin, COPD exacerbation

[Abstract:0114] SS-102 [Accepted:Oral Presentation] [Thoracic Surgery]

Do Atypical Hydatid Cysts Result from Perforated Hydatid Cysts or Previous Cyst Surgery?

Menduh Oruç, Funda Öz, Ali Birak, Fatih Meteroglu, Serdar Onat, Refik Ülkü

Department of Thoracic Surgery, Dicle University School of Medicine, Diyarbakır, Turkey

Objectives: Although hydatid cysts are encountered in every tissues, they are mostly seen in the liver and lungs. They rarely occur in bone and soft tissue out of the lung parenchyma. In this study, we aimed to investigate the factors affecting the recurrence of perforated or operated hydatid cysts.

Methods: Medical data of 171 patients with hydatid cysts, who were operated for pulmonary hydatid cyst between January 2010 and July 2017, were evaluated retrospectively. As a result of this evaluation, 13 patients having hydatid cysts with atypical localization or features were examined. Age, sex, physical examination findings, locations and sizes of cysts, previous surgeries, surgical procedures that were applied, medical treatments that were given, history of hydatid cyst (preoperative and postoperative treatments), and length of hospitalization were recorded for all patients. The diagnosis was supported by chest radiography (X-ray), computed tomography (CT), and ultrasonography (USG). The sizes of cysts were measured with CT and USG and the cysts were evaluated as those below 4 cm and those above 5 cm.

Results: Of the patients, 7 were male (53.8%) and 6 were female (46.1%). The mean age was 40.38 (17-65) years. Their complaints include pain, feeling of fullness, dyspnea, and swelling in the chest wall. The mean diameter of cysts was 4.3 (3-9) cm. According to the sizes of cysts, 9 patients had cysts of 4 cm and below (2-4 cm) and 4 patients had cysts of 5 cm and above (5-7 cm). The localization was in soft tissue in 7 cases (53.8%) and in muscle and bone tissue in 6 cases (46.15%) (Table 1). Seven of cases (53.8%) underwent an operation due to hydatid cyst and received postoperative medical treatment (Albendazole) for hydatid cyst for at least 3 months. No history of any operation was found in 4 patients (30.8%). Four (57.1%) of patients having surgery for cyst had perforated hydatid cyst. The mean length of hospitalization was found to be 6.6 days.

Conclusion: Perforated hydatid cysts or carelessness during surgery can cause cysts to localize in another region out of the lungs. Contamination should be paid attention during surgery and the frequency of control examinations should be increased for these patients despite medical treatment.

Keywords: Surgery, hydatid cyst, perforated cyst

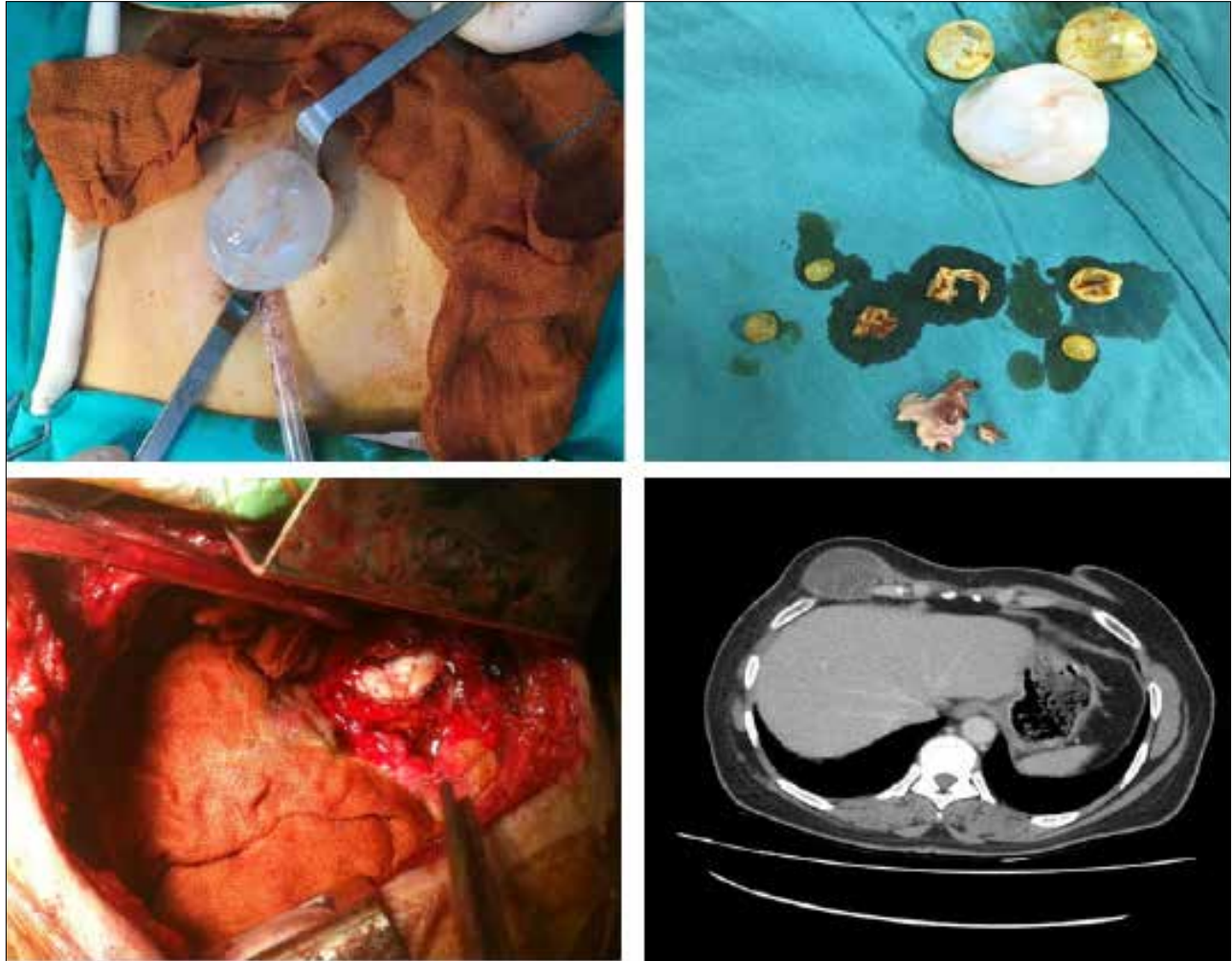


Figure 1. Different atypical hydatid cyst views

Table. Clinical Features

Age	Sex	Diameter (cm)	Surgical history	Diagnosis of cyst in the previous surgery	Localization
36	Male	4*5	Yes	Yes	Under the skin, above the sternum
24	Male	4.5*5	Yes	None	Right ventricle wall
44	Male	2*3	Yes	Yes	Apex of the heart
65	Female	3*3	Yes	None	Above the diaphragm
17	Male	2*2	Yes	None	Above the diaphragm
36	Male	4*4	Yes	Yes	Above the 1st rib
56	Female	3*3	Yes	Yes	Under the skin and above the 6th rib
54	Female	4*5	Yes	Yes	In the 6th thoracic vertebra
45	Male	6*8	Yes	Yes	Adherent to the aorta wall out of the lung
19	Female	3*4	Yes	Yes	Above the 7th rib
56	Female	10*8	Yes	None	Cyst passing the diaphragm and reaching the liver
44	Female	3*2	None	None	Above the sternum
29	Male	4*5	None	None	In the mediastinum

[Abstract:0115] PS-137 [Accepted:Poster Presentation] [Clinical Problems - Pulmonary Vascular Diseases]

Drug-Induced ANCA-Associated Vasculitis

Gökhan Çoraplı¹, Prof Dr.ayşe Füsün Topçu¹, İbrahim Baran¹, Mazlum Dursun¹, Gülhan Boğatekin²

¹Department of Chest Diseases Dicle University School of Medicine, Diyarbakır, Turkey

²Diyarbakır Gazi Yaşargil Training and Research Hospital, Diyarbakır, Turkey

Some drugs can induce ANCA-associated vasculitis. Most of patients with drug-induced ANCA-associated vasculitis have very high titers of MPO-ANCA+. The strongest relationship between drugs and ANCA-associated vasculitis has been defined

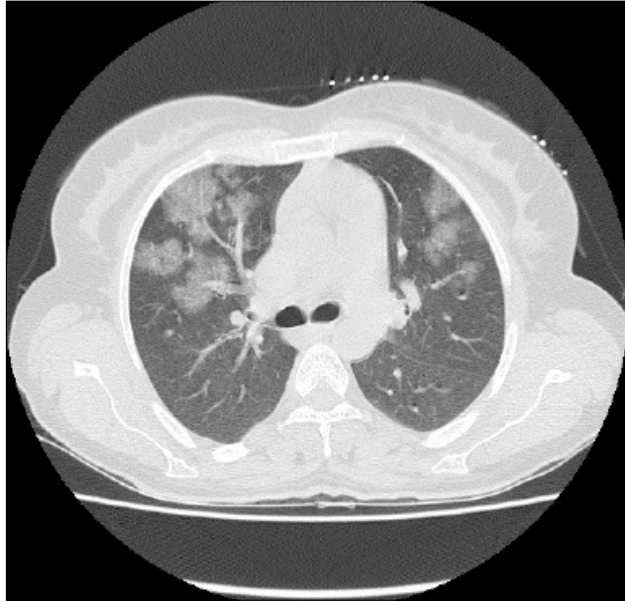


Figure 1. CT before treatment

for drugs that are used in the treatment of hyperthyroidism (propylthiouracil, methimazole, and carbimazole). While only ANCA seropositivity (p-ANCA, MPO-ANCA) is found in patients using propylthiouracil, ANCA-associated vasculitis develops in some cases. The main findings in patients with drug-induced ANCA-associated vasculitis are arthralgia, arthritis, and cutaneous vasculitis. However, severe organ involvements such as crescentic glomerulonephritis and alveolar hemorrhage can also be seen. Our case was a 35-year-old female patient. She was using propylthiouracil due to the diagnosis of hyperthyroidism for 6 years.

She had the complaints of swelling and pain in her hands, wrists, elbows, and knees for one year. For 15 days, she had the complaint of bleeding of about one tea glass a day while coughing. Because her complaints did not regress, she consulted to our university hospital. The patient was given non-specific antibiotics and symptomatic treatment. Her thoracic CT revealed diffuse alveolar patchy infiltrates that combined each other. In the analyses of the patient, ESR was 41 mm/h, CRP was 0.34 mg/dl, Hb was 7.7 g/dL, and Hct was

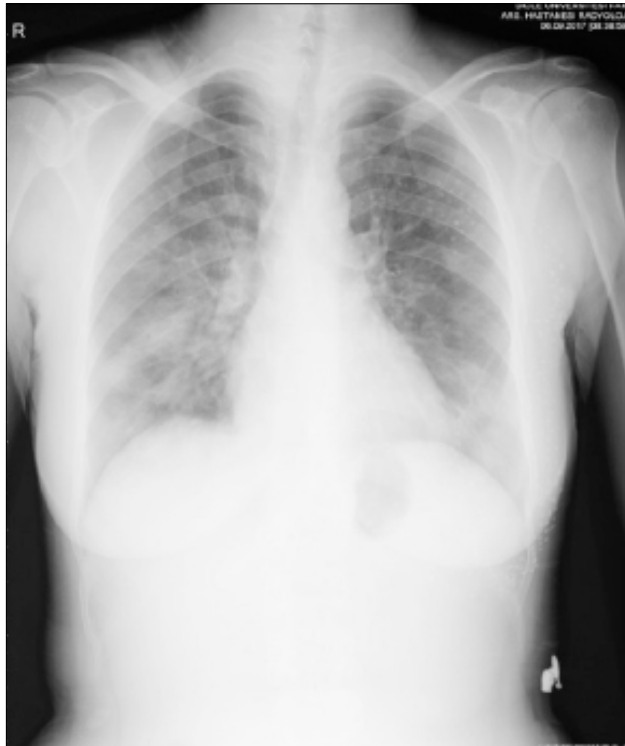

Figure 2. CT before treatment

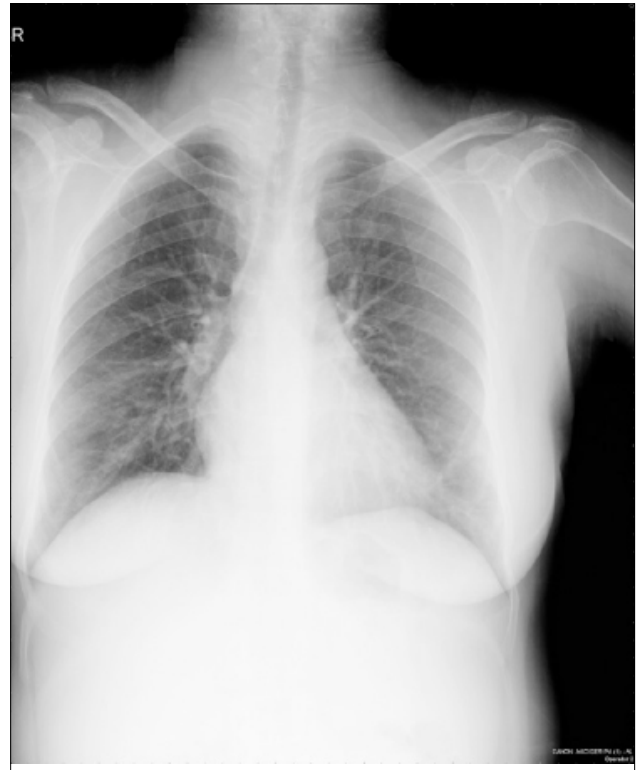

Figure 3. PAAC before treatment

25.2%. Diffuse alveolar hemorrhage was considered for the pre-diagnosis of the patient who had diffuse alveolar infiltrates, hemoptysis, and anemia. Considering drug-induced ANCA-associated vasculitis, the use of propylthiouracil was stopped and methimazole was begun. D-ECHO was performed to the patient and no pathology was found. In the bronchoscopic examination, no endobronchial lesion was detected and the presence of blood was observed in both main bronchi. BAL was applied in the right Ac upper lobe anterior and lower lobe posterior basal segments.

In BAL, the hemosiderin-laden macrophage / total macrophage ratio was found to be 90/100. Collagen tissue-vasculitis panel was ordered for the patient. Until obtaining the results, no regression occurred in the symptoms of the patient. While P-ANCA (MPO) was +++, others were detected as negative. The Department of Dermatology was consulted for the skin involvement of vasculitis and no pathological skin finding was found. Moreover, the Department of Physical Treatment and Rehabilitation and any rheumatic disease was not considered. The patient was given 80 mg/day methylprednisolone. Despite a radiological improvement in the follow-ups, her hemoptysis continued and she was administered 500 mg/day pulse steroid therapy for 5 days. Then, the treatment was continued with 80 mg/day methylprednisolone. Because her bleeding began again, PAAC revealed new formations of infiltrations, and her hemoglobin-hematocrit levels decreased, she was begun IV pulse 1000 mg/day cyclophosphamide. Hemoptysis of the patient disappeared in the follow-ups and her infiltrations in PAAC were regressed. The patient was given IV pulse 1000 mg/day cyclophosphamide in one-month periods for three times. The patient is under our supervision. We preferred to present a patient diagnosed with drug-induced ANCA-associated vasculitis, which is a rare cause of diffuse alveolar hemorrhage.

Keywords: ANCA, propylthiouracil, vasculitis

[Abstract:0116] PS-145 [Accepted:Poster Presentation] [Clinic Problems - Others]

Ortner's syndrome in a patient with giant left atrium

Gökhan Perincek¹, Sema Avcı², Ferdi Kahraman³

¹Department of Pulmonology, Kars Harakani State Hospital, Kars, Turkey

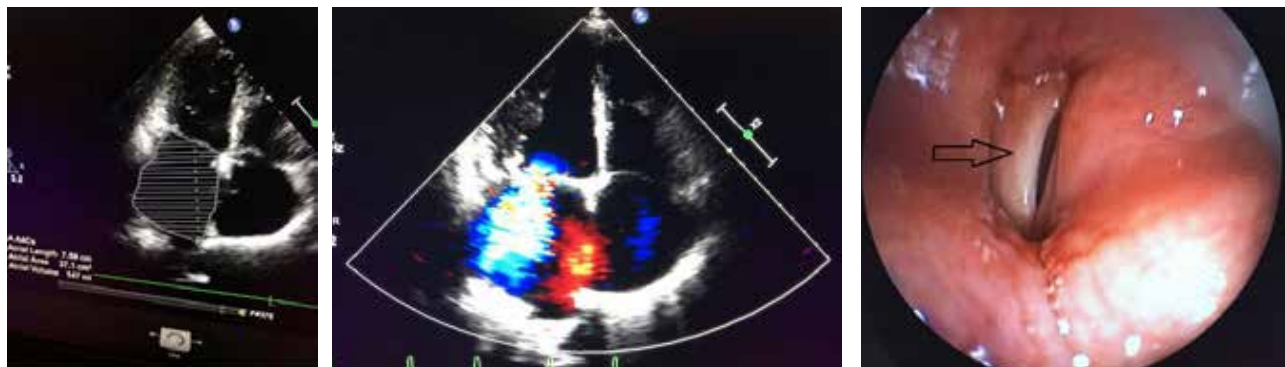
²Department of Emergency Medicine, Kars Harakani State Hospital, Kars, Turkey

³Department of Cardiology, Kars Harakani State Hospital, Kars, Turkey

An 67-year-old woman admitted to emergency department with long-standing history of dyspnea and progressive vocal hoarseness for about six months. Chest radiography showed cardiomegaly and computed tomography confirmed a massive dilated left atrium. Transthoracic echocardiography examination showed moderate-severe mitral regurgitation, mild to moderate tricuspid regurgitation and pulmonary arterial pressure was calculated 45mmHg via tricuspid regurgitation velocity. Left ventricular ejection fraction was measured 57% according to Simpson's method. Maximum left atrial volume was found more than 1.5 fold higher than left ventricular end-diastolic volume and measured 147 ml. Atrial four chamber view and moderate-severe mitral regurgitation left atrial volume Figure A and Figure B. A left vocal cord paralysis was confirmed on bronchoscopy (Figure C). Recurrent laryngeal nerve paralysis or paresis of cardiovascular origin known as Ortner's syndrome secondary to a massive dilated left atrium was diagnosed. Ortner's syndrome is hoarseness of voice due to recurrent laryngeal nerve involvement and accompanying with cardiovascular diseases. This syndrome also known as cardiocaval syndrome. Ortner's syndrome was described in patients with severe mitral stenosis causing left atrial enlargement. It can be seen in patients with aortic aneurysms, aortic dissection and cardiac tumors. Cardiovascular causes of recurrent laryngeal nerve palsy have been described in the literature. When Ortner's syndrome symptomatic, they usually present with chest pain, dyspnea or hoarseness. This case reports show Ortner's syndrome in a patient with giant left atrium.

Keywords: Left atrium, hoarseness, dyspnea

[Abstract:0118] PS-035 [Accepted:Poster Presentation] [Clinic Problems - Others]



Figure

Incidentally Detected Nasopharyngeal Sarcoidosis Case

Songül Özyurt¹, Neslihan Özçelik², Bilge Yılmaz Kara¹

¹Department of Chest Diseases, Recep Tayyip Erdoğan University School of Medicine, Rize, Turkey

²Department of Chest Diseases, Kaçkar State Hospital, Rize, Turkey

Introduction: Sarcoidosis is a multisystemic disease with an unknown etiology. Although genetic, environmental, and immunological factors are considered in the etiology, definite cause and pathogenesis of sarcoidosis are not understood exactly. Sarcoidosis rarely occurs in the upper respiratory tract and can cause hoarseness, dysphagia, and obstruction in the upper respiratory tract. In this study, a case of incidentally detected nasopharyngeal sarcoidosis in a patient who consulted for the complaints of cough and postnasal drip was presented.

Case Presentation: A 57-year-old female patient was admitted to the outpatient clinic of ENT due to the complaints of cough and postnasal drip. Because her endoscopic examination revealed a lesion raising from the mucosa in the posterior part of the nasopharynx, a biopsy was performed and its result was found to be consistent with non-caseating non-necrotizing granulomatous reaction. In the paranasal sinus tomography of the patient, who was referred to our department with the pre-diagnosis of sarcoidosis, it was observed that the left frontal recess was completely closed and maxillary sinus mucosae were thickened. In the computed tomography of the lungs, approximately 2 cm mediastinal hilar lymph nodes were found in the right and left sides and nodular lesions were detected in the right lung lower lobe, medial lobe, and posterior basal segments. The result of mediastinal lymph node sampling was consistent with non-caseating granulomatous reaction. The level of serum ACE was found to be 79. Collagen tissue markers and sputum and biopsy ARBs of the patient were negative. The result of respiratory function test was normal. The patient was begun local steroid treatment for nasopharyngeal sarcoidosis. She benefited from the treatment and she was followed up due to the diagnosis of pulmonary and extrapulmonary sarcoidosis.

Conclusion: Sarcoidosis is a multisystemic disease that often affects the lungs. Pulmonary sarcoidosis can also be incidentally detected in patients applying with extrapulmonary involvements. Nasopharyngeal sarcoidosis is a rarely encountered condition. It should be kept in mind for patients having cough and hoarseness. Local steroid therapy can be sufficient for patients without respiratory symptoms.

Keywords: Sarcoidosis, nasopharynx, local steroid

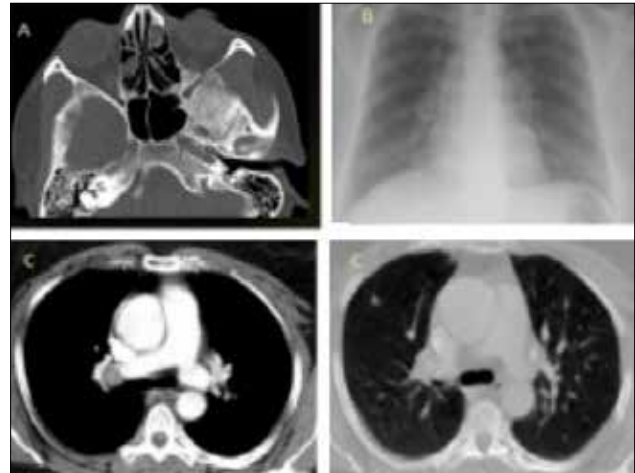


Figure 1. a) Nasopharyngeal ct of the patient, b) ac graph: bilateral hilar lap c) right hilar lap d) solitary nodule in the right upper lobe

[Abstract:0119] EPS-297 [Accepted: E-Poster] [Tuberculosis]

Tuberculosis and Hypermetabolic Mass

Yağmur Kaptan, Abdullah Sayiner

Department of Chest Diseases, Ege University School of Medicine, İzmir, Turkey

A 45-year-old female patient, who had no comorbidity except vertigo, was examined in an external center due to the complaint of dyspnea and she was given ceftriaxone and azithromycin treatments by considering pneumonia and parapneumonic effusion in the right lung, but no response was obtained. The patient consulted to our department with the complaints of fever and dyspnea and she was hospitalized. In the examinations, right pleural effusion was detected. After fluid sampling, piperacillin-tazobactam therapy was initiated. Fluid biochemistry analysis was resulted as consistent with exudate. No bacteriological growth was found. Samples for pleural fluid adenosine deaminase (ADA) level and mycobacterial culture were sent for analysis. Fluid ADA level was found as 118.4 U/L and ARB and PCR were reported as negative in the mycobacterial samples. The results of fluid pathology samples were reported as lymphocyte-rich inflammatory effusion. Because of no response of fever despite antibiotherapy, increased ADA level in the fluid sample, and the detection of lymphocyte-rich inflammatory effusion, tuberculosis pleurisy was considered and quadruple antituberculosis therapy was begun and the

patient was referred to the tuberculosis control dispensary. The patient visited the hospital for control examination two months later and *M. tuberculosis* complex growth was detected in her mycobacterial cultures. Therefore, the treatment was continued. Because a 6x5.5 cm pleura-based mass lesion with partially irregular margins was detected in the right lower lobe in thoracic computed tomography (CT) that was performed in an external center due to the complaint of chest pain in the 4th month of the treatment, she consulted to us again (Figure 1). No endobronchial lesion was found in the bronchoscopy and pathological examination of samples that were taken was reported as benign. Due to the prediagnosis of malignancy, positron emission tomography (PET-CT) was performed. This PET-CT revealed 7 and 8 mm two mild hypermetabolic lesions in the right supraclavicular fossa (SUV:2.6), multiple hypermetabolic lesions extending to the celiac truncus and with precaval localization (SUV: 4-6), lymphadenopathies with right upper and lower paratracheal, left prevascular, left lower subcarinal and bilateral hilar localization, some of which partly displayed calcific changes, but most could be consistent with non-calcified and hypermetabolic metastasis (SUV: 6-8.5), and a 64x35x51 mm mass lesion having peripheral localization and leaning towards the pleura in the posterior basal segment of the right lower lobe (SUV: 9.6) (Figure 2).

Endobronchial ultrasonography (EBUS) sampling was performed and the presence of lymphohistiocytic infiltrations including epithelioid giant cells and having tendency to form granuloma were reported. Ultrasound-guided tru-cut biopsy was carried out and its result was reported as granulomatous lung disease. Considering that the mass of the patient was associated with tuberculosis, anti-tuberculosis treatment was prolonged by 9 months. In the tomography performed at the end of the treatment, it was observed that the mass lesion was apparently regressed (Figure 3) and mediastinal lymphadenopathies were stable.

Cases of tuberculosis presenting with hypermetabolic mass that appears under an effective treatment have been reported in literature very rarely.

Keywords: Tuberculosis, mass, hypermetabolic

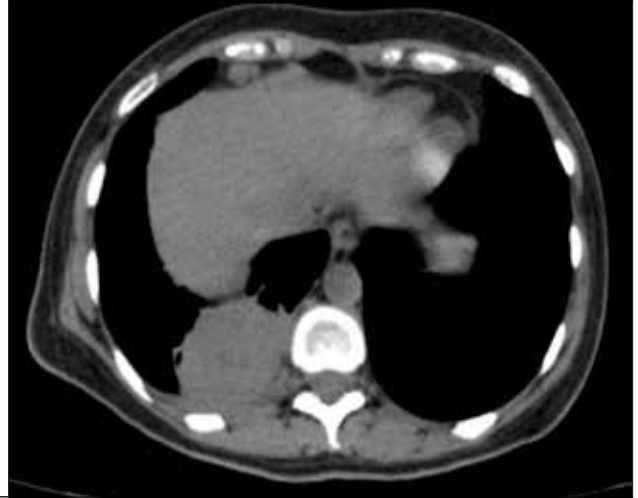


Figure 1.

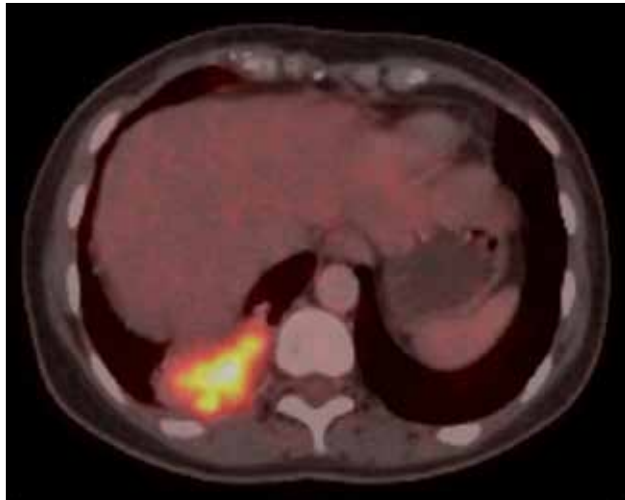


Figure 2.

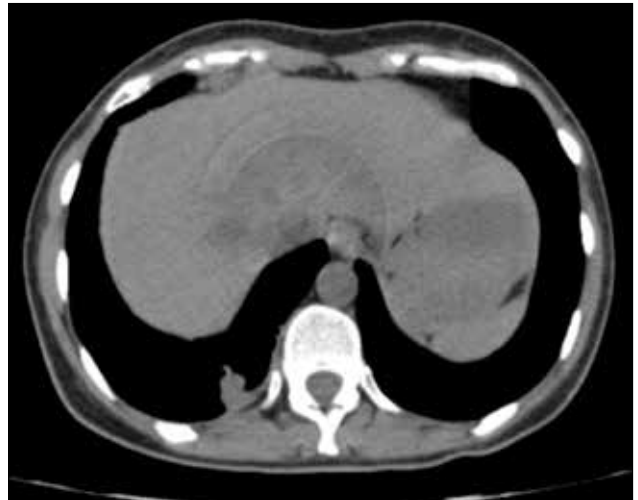

Figure 3.

[Abstract:0120] EPS-152 [Accepted: E-Poster] [Respiratory Infections]

Etiology of Pleural Effusion: A Case of Cyst Hydatid

Yağmur Kaptan, Abdullah Sayiner

Department of Chest Diseases, Ege University School of Medicine, İzmir, Turkey

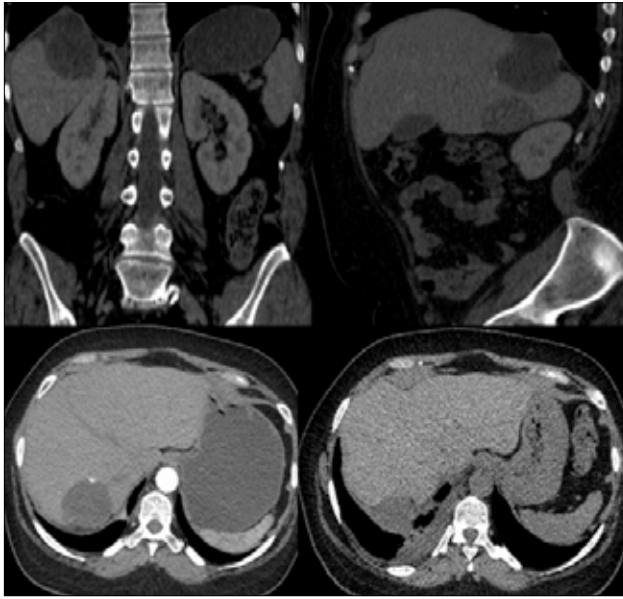


Figure 1.

patient was diagnosed with hepatic cyst hydatid. Because there were findings related to transdiaphragmatic passage in the axial and sagittal images of CT (Figure 2), the patient was considered to have demonstrative feature.

Keywords: Cyst hydatid, liver, transdiaphragmatic

ined in an external center due to the complaint of chest pain and her examinations revealed pleural effusion in the right lung. She was given oral antibiotic therapy, but no response was obtained. Then, she consulted to our department and pleural friction rub was auscultated in the right side and bilateral 2+ pretibial edema was found in her physical examination. In chest radiography and thoracic US, slight pleural effusion was detected in the right side but it could not be sampled. EFs in ECHO that was performed for cardiac failure and NT-proBNP level in the biochemical analysis were normal. The results of examinations that were carried out for systemic vasculitides were found to be negative. The patient was performed computed tomography (CT). Multiple nodular lesions, some of which were calcified, were observed in the left lung. Moreover, right pleural effusion, a lesion in favor of cyst hydatid, causing irregularity on the margin of diaphragm in right subdiaphragmatic region and having subcapsular localization at the level of segment 7 in the liver, and a defect in the diaphragm were found (Figure 1). Pleural fluid that was detected in the right hemithorax was thought to be associated with the transdiaphragmatic extension of the lesion. Due to the suspicion of cyst hydatid, serological test was ordered for the patient and significant positivity was found in the ELISA IgG and indirect hemagglutination tests. The

[Abstract:0121] EPS-013 [Accepted: E-Poster] [Clinic Problems - Others]

Spontan Hemorrhage on the Neck due to Warfarin Overdose

Ahmet Erođlu¹, Hüseyin Serdar Yerlikaya², Sema Avcı¹, Gökhan Perinçek³

¹Department of Emergency Medicine, Kars Harakani State Hospital, Kars, Turkey

²Department of Otolaryngology, Kars Harakani State Hospital, Kars, Turkey

³Department of Pulmonology, Kars Harakani State Hospital, Kars, Turkey

A 75-year-old female patient admitted to the emergency department with the dysphonia, dyspnea and swelling on the neck for about 12 hours. There was any trauma history. She stated that swelling on the neck started suddenly. The patient was using warfarin 5 mg three times a day and acetylsalicylic acid 100 mg one a day for cardiac valve disease. The patient denied epistaxis, melena or hematuria. The other bleeding spots were excluded. Examination in the emergency department revealed widespread ecchymosis on the neck and thorax (Figure 1). Her vital signs were stable as blood pressure of 120/70 mm-Hg, pulse rate of 98/min and oxygen saturation of 97%. Blood examinations revealed elevated international normalized ratio (INR) of 13, increased prothrombin time 150 second and activated partial thromboplastin time 147 second with normal platelet counts. In physical examination there was no an acute bleeding. The patient was immediately referred to otorhinolaryngologist. The warfarin treatment was stopped and 3 units fresh frozen plasma were given. The patient is still in the intensive care unit in our hospital. The warfarin treatment is associated with increased incidence of hemorrhagic complications. The overall incidence of bleeding in patients on warfarin is about 6.8%. The doctors should be careful about warfarin treatment.

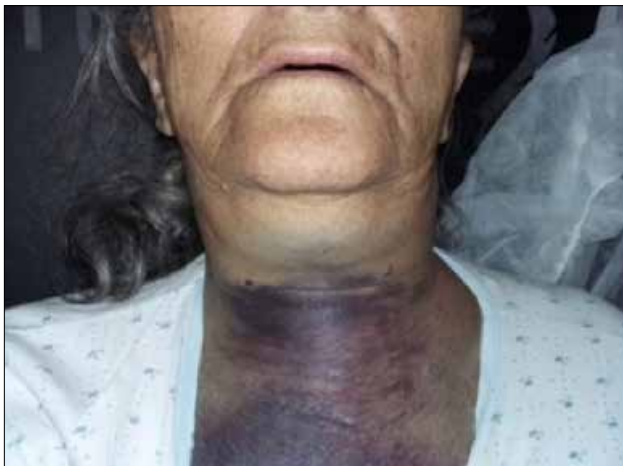

Figure 1.

examinations revealed elevated international normalized ratio (INR) of 13, increased prothrombin time 150 second and activated partial thromboplastin time 147 second with normal platelet counts. In physical examination there was no an acute bleeding. The patient was immediately referred to otorhinolaryngologist. The warfarin treatment was stopped and 3 units fresh frozen plasma were given. The patient is still in the intensive care unit in our hospital. The warfarin treatment is associated with increased incidence of hemorrhagic complications. The overall incidence of bleeding in patients on warfarin is about 6.8%. The doctors should be careful about warfarin treatment.

Keywords: Warfarin, ecchymose, neck

[Abstract:0122] SS-038 [Accepted: Oral Presentation] [Respiratory Infections]

The Rate of Influenza Vaccination in Hospital Staff and Its Results

Yağmur Kaptan¹, Özlem Limoncu¹, Tuğçe Türk¹, Hacer Esra Çakmak¹, Sinem Aslan¹, Enes Aldemir¹, Furkan Kara¹, Merve Akbaşoğlu¹, Ömer Faruk Akçay¹, Aylin Aydılek¹, Gamze Ekin¹, Meral Türk², Abdullah Sayiner¹

¹Department of Chest Diseases, Ege University School Medicine, İzmir, Turkey

²Department of Public Health, Ege University School Medicine, İzmir, Turkey

Objectives: Influenza leads to epidemics every year, particularly in winters. Annual influenza vaccine is an important public health precaution taken for the prevention of influenza infection. The action of this vaccine is based on the formation of antibodies that neutralize virus against viral hemagglutinin. Especially the elderly people, immunosuppressed patients, pregnant women, individuals with chronic diseases, and health staff are recommended to have this vaccine done regularly every year. In this study, it was aimed to determine the rate of vaccinated health staff, the reasons for vaccination/non-vaccination, and the effectiveness of vaccination in these individuals in a university hospital.

Methods: The study included 92 individuals (nurses, interns, and physicians) who were determined to be vaccinated for influenza by the staff health unit of a university hospital, but only 60 of them were reached (study group). On the other hand, 61 individuals at the same ages and sex, who worked at the same units, were included in the study as the control group. All participants were applied a questionnaire including questions to investigate the effectiveness of vaccination, which were verbally asked.

Results: The reasons for vaccination were stated as; thinking it to be protective (n=32, 53.3%), thinking himself/herself to be included in the risk group for himself /herself and patients (n=16, 26.7%), its being a free application (n= 6, 10%), and routine vaccination (n=6, 10%). The reasons for non-vaccination were stated as; finding it unnecessary (n=22, 36.1%), missing its time/forgetting it/finding no time for it (n=3, 21.3%), thinking himself/herself in the low risk group (n=5, 8.2%) or thinking it to be ineffective (n=5, 8.2%), preferring natural immunity (n=5, 8.2%), having a history of allergy/autoimmunity and side effect (n=4, 6.6%), and its not being recommended by doctor/having no knowledge (n=2, 3.3%). Five participants (8.2%) did not state any reason. Of the vaccinated individuals, 48.3% (n=29) were vaccinated regularly and 45% were vaccinated for at least once previously. Of non-vaccinated individuals, 32.8% (n=20) stated that they were vaccinated previously but 63.9% (n=39) stated that they were never vaccinated. The rate of participants who wanted to be vaccinated in the next year was 75% (n=45) in the vaccinated group and 19.7% (n=12) in the non-vaccinated group. 66.7% of the vaccinated group and 77% of the non-vaccinated group had respiratory tract infection in the following year (p=0.20) (Figure 1). The rate of antibiotics usage was 66.7% in the vaccinated group and 77% in the non-vaccinated group (p=0.20) (Figure 2). The rate of receiving health report due to respiratory tract infection was 6.7% in the vaccinated group and 11.3% in the non-vaccinated group. The rates of disease-induced inability to work were 20% and 26.2% in the vaccinated and non-vaccinated groups, respectively (p=0.42).

Conclusion: The main finding of this study is the low rate of influenza vaccination in the health staff of a tertiary care hospital (approximately 3%). While the rates of having upper respiratory tract infection, using antibiotics, and receiving health report were lower in the vaccinated individuals, the differences were not statistically significant.

Keywords: Influenza, vaccine, health staff

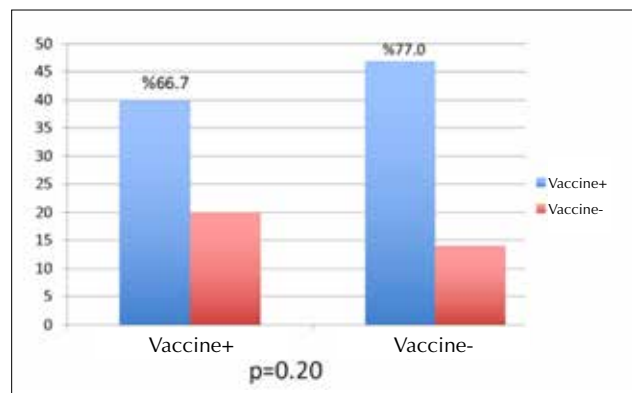
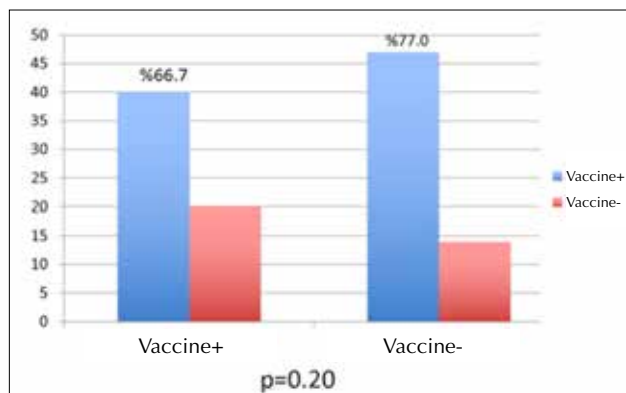


Figure 1. Respiratory tract infection

Figure 1. Use of Antibiotics

[Abstract:0123] EPS-052 [Accepted: E-Poster] [COPD]

Retrospective Evaluation of Patients with Chronic Obstructive Pulmonary Disease

Gökhan Perincek¹, Sema Avcı²

¹Department of Pulmonology, Kars Harakani State Hospital, Kars, Turkey

²Department of Emergency Medicine, Kars Harakani State Hospital, Kars, Turkey

Objectives: Chronic obstructive pulmonary disease (COPD) acute exacerbations result in high rates of admission to hospital and hospitalization. This disease has serious clinical, economical, and social results as well as increased mortality risk. The aim of this study was to evaluate the data of COPD patients who consulted to a secondary care hospital.

Methods: This study was conducted in Kars Harakani State Hospital after receiving approval from Kafkas University Ethics Committee. A total of 414 patients, who were diagnosed with COPD between 2010 and 2017 and who were admitted to the Emergency Service and Outpatient Clinic of Chest Diseases and then hospitalized in the Department of Chest Diseases between these years, were included.

Results: Of the patients, 157 were female. They were mostly admitted to the hospital in November at the rate of 13.5%. The mean age was 69.6±9 years for female patients and 68.1±9.9 for male patients. While the mean body mass index was 30.1±6.8 for female patients, it was 25.5±5.5 for male patients. The mean FEV1 value of the patients was found to be 38.8±14.5. In patients, the mean white blood cell count (WBCx10³) was 11.36±5.61; the mean platelet volume (MPV) was 8.23±1.04; the mean platelet count (x10³) was 246.2±81.9; the mean lymphocyte count (x10³) was 1.58±1.37; and the mean neutrophil count (x10³) was 8.77±4.73. Normal upper respiratory tract flora was more commonly detected in the sputum cultures of the patients (n=359, 87.35%). The level of FEV1 was found to be associated with smoking (p<0.001) and the presence of comorbidity (p=0.001). While decreased FEV1 was at moderate and severe levels in patients with comorbidities, it was at severe and extremely severe levels in those without comorbidities (p=0.001). The mean FEV1 values of patients who currently smoked and patients who used to smoke were similar (p=0.486). The FEV1 values of patients who used to smoke were lower than those who never smoked (p<0.001).

Conclusion: In conclusion, further more studies should be conducted on COPD acute exacerbations in our country.

Keywords: COPD, demography, acute attack

[Abstract:0126] SS-139 [Accepted:Oral Presentation] [Tobacco Control]

Evaluation of Compliance to the Hookah Ban in Closed Areas of Private Businesses in İstanbul

Pınar Ay¹, Osman Elbek², Tanzer Gezer², Füsün Yıldız², Elif Dağlı², Murat Güner², Murat Ceyhan²

¹Department of Public Health Marmara University School of Medicine, İstanbul, Turkey

²Sağlığa Evet Derneği

Objectives: In Turkey, in the framework of the Law for the Prevention of Harms of Tobacco Products, smoke-free zone has been implemented in indoor areas of private businesses of food sector since July 2009. On the other hand, according to the provision of related law, every kinds of products that do not include tobacco but imitates tobacco products are also accepted as tobacco products. In this study, it was aimed to determine the rates of compliance to the implementation of smoke-free zone in private places offering hookah in seven districts of İstanbul.

Methods: In İstanbul, there are 428 businesses providing food service, which have got license for hookah. The study included the districts of Kadıköy, Fatih, Bakırköy, Beşiktaş, Sarıyer, Üsküdar, and Şişli. Private places having license for hookah in these districts constitute 51.2% of all places in İstanbul. Considering violation rate as 50%, confidence level as 95%, error margin as 0.05, and closure rate of businesses as 10%, 141 places were evaluated to be included in the sampling. The plac-

es were selected from seven districts through the simple random sampling method and each place was visited for 10 minutes after 15.00 o'clock in order to evaluate the rate of violation by direct observation method.

Results: Of 141 places that were included in the study, 128 (90.8%) were reached. 68.8% of these places were detected to be cafes. It was observed that only 57.0% of the places had outdoor areas and 68.8% had areas with panels that could be opened and closed. It was found that 15.6% of the places were located near educational institutions, private teaching institutions, and student dormitories at a distance less than 100 meters. Only 50.7% had warnings about the ban for using tobacco products in indoor areas and these warning plates were suitable in terms of their size and content only in 61.5% of them. The rates of violation of smoking cigarettes and hookah in closed areas were found to be 73.4% and 78.1%, respectively. According to the regulations, health warnings must cover 65% of hookah bottles. However, it was found that the bottles had health warnings only in four places and the size and content of these warnings were appropriate only in two of them.

Conclusion: A great number of places with license for hookah are not in compliance with the legislation provisions. Besides that, the violation rate of the implementation of smoke-free zones is very high in these non-compliant places (78.1%). Therefore, the licenses of all places for hookah should be reviewed and the licenses of those that do not comply with the regulations should be cancelled.

Keywords: Hookah, cigarette, violation, food and drink businesses

[Abstract:0129] PS-011 [Accepted:Poster Presentation] [Clinical Problems - Diffuse Parenchymal Lung Disease]

Incidence and Primary Disability due to Sarcoidosis in Belarus

Halina Baradzina

Belarusian State Medical University, Minsk, Belarus

Objecives: Numerous epidemiological studies indicate an increase in the incidence of sarcoidosis worldwide. The aim was to analyze the dynamics of the incidence and primary disability rate of sarcoidosis in Belarus.

Methods: The epidemiological indicators were analyzed from 1977. An analysis of the indicators was carried out on the basis of the state register "Disability".

Results: Since 1977 the incidence of sarcoidosis increased 6.15 times and amounted to 8.0 per 100 000 population, mainly due to improved diagnostics. The average annual growth rate was 4.4%. According to the forecast the incidence will reach 10.1 per 100 000 population in 2018. The highest incidence is in the capital (61-100% higher than the national average) and the capital region (+ 30-60%). The incidence of urban population is 1.5 - 3.3 times higher than that of rural (4.3-16.0 and 1.7 -4.8 per 100.000 population). There is tendency to increase of the urban population proportion from 64.8±2.1% to 72.1±4.3%, amount of female patients from 53.4±2.4% to 61.2±4.9% and average age of patients from 25,2±3,1 to 34,2±4,7 years for the 20 years. The proportion of people over 44 years old among women is 20.67±1.6%, while sarcoidosis was not recorded in patients older than 44 years in 1977-1979. The level of primary disability due to sarcoidosis is 2.53-0.35% of the total number of newly diagnosed patients. Among the 66.9% recognized for the first time by invalids are people aged 30-54. The disability rate at the age of 20-24 was 7.5 times higher in men. The maximum levels of disability are observed in the 35- 39 years in men and in the periods of 35-39 years and 50-54 years in women. The index of primary disability due to sarcoidosis gradually increased from 1991, reached its maximum in 1995, and then began to steadily decline. It was revealed that the level of primary disability due to sarcoidosis is not directly related to epidemiological factors.

Conclusion: The introduction of modern therapeutic and diagnostic tactics led to decreasing the primary disability rate by 2.4% per year, the general level of disability by 10.9% per year and the increasing of the average age of the disabled due to sarcoidosis from 40.1±2.1 to 45.4±2.5 years for the last 10 years.

Keywords: Sarcoidosis, incidence, primary disability

[Abstract:0136] SS-131 [Accepted:Oral Presentation] [Pulmonary Rehabilitation and Chronic Care]

Could Functional Inoperability in Lung Cancer Patients Be Changed by Pulmonary Rehabilitation?

Esra Pehlivan, Arif Balcı, Lütüye Kılıç

Department of Pulmonary Rehabilitation, Health Sciences University, Yedikule Chest diseases and Thoracic Surgery Training and Research Hospital, İstanbul, Turkey

Table. The effect of Pulmonary Rehabilitation on functional exercise capacity, dyspnea, respiratory functions and respiratory muscle strenght.

Variables	Before PR Mean±SD	After PR Mean±SD	Δ Mean±SD	p
6MWD (m)	458.91±92,05	520,83±112,33	61,91±43,76	p<0,0001
mMRC (0-4)	2 (1-4)	1 (1-3)	1 (0-1)	0.01
FVC (L)	2.15±0,50	2.29±0,50	0.13±0,26	0.10
FVC (%)	58.21±12.72	63.10±12.82	4,89±8,94	0.08
FEV1 (L)	1.42±0.38	1.61±0,38	0,18±0,19	0.006
FEV1 (%)	49.07±10.39	56.35±11,96	7.27±7.32	0.005
MIP (cmH2O)	71.16±26.76	88.66±26.54	17.50±17.01	0.004
MEP (cmH2O)	134.66±34.87	138.91±40.35	1.41±5.08	0.46

PR: Pulmonary Rehabilitation, 6MWD: 6 minute walking distance, mMRC: modified medical research association dyspnea score, FVC: Forced Vital Capasite, FEV1: First Forced Expiration Volume, MIP: Maksimum Inspiratory Pressure, MEP: Maksimum Ekspiratory Pressure. *Pair sample t test, ** Wilcoxon rank test, significance level p<0.05. Data are expressed as Mean±SD or Median (min-max) .

Objectives: To our knowledge, there is not any research that investigated if functional or medical inoperability could be changed by Pulmonary Rehabilitation (PR). To contribute to the literature, in this study, we aimed to investigate the effects of short-term intense PR on respiratory function in lung cancer patients who were admitted to the hospital because of the functional inoperable that insufficient pulmonary reserve.

Methods: Patients who were histologically diagnosed as non-small cell lung carcinoma (NSLC) and considered functionally inoperable (due to respiratory function) were included in this study if they were suitable for surgical resection according to tumor stage. Patients received breathing exercise, free-walking and Inspiratory Muscle Training (IMT) for two weeks. Pulmonary Functions (FEV1, FVC), dyspnea perception (mMRC), exercise capacity (6 Minute Walking Distance-6MWD) and respiratory muscle strength (MIP, MEP) were examined.

Results: A total 22 patients were enrolled in this study. Nine patients were excluded due to the follow-up problems. After PR, there was statistically significant improvement in the 6MWD (p<0.0001), mMRC (p=0.01), MIP (p=0.004), FEV1 (Δ=180ml, p=0.006; Δ FEV1max:570 ml) and FEV1% (p=0.005). 50% of the patients who underwent PR were operated.

Conclusion: The short-term intensive PR, improves the lung functions, exercise capacity and also beneficial to decrease of dyspnea perception in lung cancer patients with limited pulmonary functions. In our study, thanks to the gains derived from the exercise, approximately half of the patients was able to be operated. Our findings suggest that it will be useful to refer the patient to the Pulmonary Rehabilitation center before the inoperability decision is taken.

Keywords: Inoperable, lung cancer, FEV1, exercise, pulmonary rehabilitation

Table. Diagnostic and operability distributions of the patients.

Cancer Stage* n,%	Operability (n)	Total Operability (n,%)
1A	1 (8.3)	1
2A	1 (8.3)	1
3A	6 (50)	2
1B	1 (8.3)	1
2B	1 (8.3)	1
3B	1 (8.3)	0
		6 (50)

*According to AJCC (American Joint Committee on Cancer) Cancer Staging Manual, 8th edition, Amin MB, Edge SB, Greene FL et al (Eds) , Springer, Chicago 2017.

[Abstract:0137] PS-075 [Accepted:Poster Presentation] [Thoracic Surgery]

Conjunction of Fungus Ball and Pulmonary Tumourlet in Bronchiectatic Cavity

Serkan Yazgan¹, Soner Gürsoy¹, Figen Türk¹, Zekiye Aydoğdu Dinç²

¹Department of Thoracic Surgery, University of Health Sciences, Dr. Suat Seren Chest Diseases and Surgery Medical Practice and Research Center, İzmir, Turkey

²Department of Pathology, University of Health Sciences, Dr. Suat Seren Chest Diseases and Surgery Medical Practice and Research Center, İzmir, Turkey

Objectives: Pulmonary tumourlet is a rare pathology and defined as nodular proliferation of neuroendocrine cells less than 0.5 cm in diameter. It is usually detected incidentally in destroyed lung removed surgically or bronchiectasis. Coexistence of fungus ball and pulmonary neuroendocrine tumourlet were presented because of rarely observed.

Case Presentation: This is a case description of a female patient of 67 years-old, who presented with cough and hemoptysis. The chest computer tomography revealed destruction of left lower lobe and multiple fungus balls in the bronchiectatic cavity (Figure 1). Left lower lobectomy was performed by thoracotomy. Histopathological examination of the lung showed comitative aspergilloma and multiple tumorlets in the large bronchiectatic cavity. No radiologic abnormality were found on CT control, and after 7 months from the operation, she is still alive without problems.

Conclusion: There is also no consensus regarding the timing of surgery and the type of surgery needed for aspergilloma. Surgical resection is risky and difficult due to the occurrence of an underlying chronic disease and the negative effects of infection on the lung. However, coexistence of a large bronchiectatic cavity, aspergilloma and tumourlet in our case suggests that such lung diseases also provide a basis for premalignant lesions, as well as complications such as haemoptysis and recurrent infections. In conclusion, surgical treatment will therefore prevent both recurrent symptoms and development of premalignant lesions.

Keywords: DIPNECH, tumourlet, aspergilloma, fungus ball, mycetoma

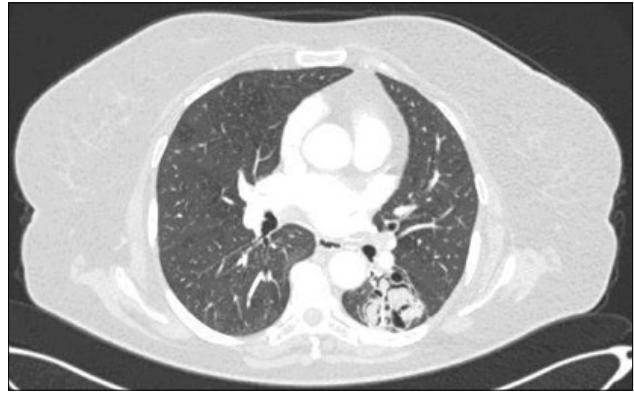

Figure 1. The fungus balls in the large cavity and destruction located in the left lower lobe

[Abstract:0139] PS-102 [Accepted:Poster Presentation] [Pulmonary Rehabilitation and Chronic Care]

An Assessment of the Physical Activity Levels of Individuals with Adult Asthma or COPD

Filiz Özdemir¹, Tuba Tülay Koca², Nurcan Berber³, Şelale Şahin⁴

¹Department of Physiotherapy Rehabilitation, İnönü University Faculty of Health Sciences, Malatya, Turkey

²Department of Physical Medicine and Rehabilitation, İnönü University Faculty of Health Sciences, Malatya, Turkey

³Clinic of Pulmonology, Malatya Training and Research Hospital, Malatya, Turkey

⁴Malatya Provincial Directorate of Health, Malatya, Turkey

Objectives: Advanced technology and modern lifestyles lead people to become more sedentary. Physical inactivity is an important risk factor for many chronic diseases including coronary artery illness, obesity, non-insulin-dependent diabetes, hypertension, respiratory diseases, stroke, cancer, depression and osteoporosis. Individuals continue to have inactive lives despite the benefits of physical activity and exercise in the prevention and treatment of chronic diseases. In our society, chronic diseases put a burden on healthcare and health expenditures. Individuals with COPD and asthma need to be informed about their levels of physical activity before they become more active. The goal of this study is to determine the levels of physical activity of individuals with COPD and asthma.

Methods: This cross-sectional study included 97 patients (44 with COPD and 53 with asthma). Patients' socio-demographic characteristics and awareness about asthma or COPD were determined. The COPD and asthma patients' regular exercise habits and level of participation in physical activities were assessed using the short form of the International Physical Activity Questionnaire (IPAQ). The Mann-Whitney U test was used for statistical analysis of the variables that did not have normal distribution.

Results: The mean age of patients with COPD was 65.3 ± 3.4 years, and their mean body mass index value was 25.8 ± 2.5 kg/m². The mean age of asthmatic patients was 50.7 ± 5.1 years, and their mean body mass index value was 29.2 ± 3.4 kg/m². There was a significant difference between the mean body mass index values of adult asthma and COPD patients ($p=0.01$). The weekly energy expenditure of patients with COPD due to physical activity was $1,564.2 \pm 615$ MET-min, and it was $2,130 \pm 842$ MET-min for individuals with asthma. In this study, no statistically significant difference was found between the physical activity levels of adult asthma and COPD individuals ($p=0.09$).

Conclusion: Physical activity levels of adult asthma and COPD patients were found to be low. Regular physical activities can increase the functional capacities of individuals with asthma or COPD. Individuals should be informed and encouraged to live more active and healthy lives. Therefore, our goal should be increasing asthma and COPD patients' functional capacities and reducing their levels of addiction through the preparation of individualized regular physical activity programs.

Keywords: COPD, asthma, physical activity

[Abstract:0141] EPS-119 [Accepted: E-Poster] [Pediatric Pulmonary Diseases]

Urgent Bronchoscopy for Foreign Body Aspiration in Children with Asphyxia

Alper Avci¹, Zehra Hatipoğlu², Serdar Onat³

¹Department of Thoracic Surgery, Çukurova University School of Medicine, Adana, Turkey

²Department of Anesthesiology and Reanimation, Çukurova University School of Medicine, Adana, Turkey

³Department of Thoracic Surgery, Dicle University, Diyarbakır, Turkey

Objectives: Foreign body aspiration (FBA) is one of the common cause of accidental death in children. Although recognition and management has improved, FBA remains a life-threatening emergency. Children with FBA have a wide range of presentation, depending on the anatomic location of the FB, the degree of airway obstruction. The anamnesis is the most sensitive predictor. Physical examination findings are more specific. Aim of study is to evaluate the results of urgent bronchoscopy of the children who had severe respiratory failure

Methods: Between January 2005 and December 2016, total of 1096 children underwent rigid bronchoscopy in Cukurova and Dicle University. Forty-eight patients with severe respiratory failure were included in this study. Family anamnesis and hypoxia were main indications for RB. We exception of endotracheal intubation for respiratory stabilization, RB was given priority over fasting period completion, radiologic examinations. Patient's age, sex, physical examination, endotracheal intubation, SpO₂ values, bronchoscopy results, type and location of FB, intra- and postoperative complications and mortality, chest X-ray, length of hospital stay were recorded. RB's were done under general anesthesia in the operation room.

Table 1. Demographic Characteristics of the Patients

Characteristics	
Gender (F/M)	14/34
Age (month)	
Mean \pm SD	26.92 \pm 23.10
Median (IQR)	18 (17.5)
Hospital arrival time (min)	
Mean \pm SD	108.96 \pm 85.86
Median (IQR)	90 (105.0)

Table 2. Preoperative Evaluations of The Patients

	Foreign body		Total (n = 48)
	Positive (n = 39)	Negative (n = 9)	
Chest X-ray			
None	24 (66.7 %)	5 (41.7 %)	29 (60.4 %)
Normal	6 (16.7 %)	5 (41.7 %)	11 (22.9 %)
Atelectasis	1 (2.8 %)	0 (0.0 %)	1 (2.8 %)
Consolidation	0 (0.0 %)	2 (16.7 %)	2 (4.2 %)
Asymmetric hyperinflation	5 (13.9 %)	0 (0.0 %)	5 (10.4 %)
Auscultation findings			
Stridor	16 (44.4 %)	4 (33.3 %)	20 (41.7 %)
Wheezing	7 (19.4 %)	6 (46.2 %)	13 (27.1 %)
Unilateral diminished breath sounds	12 (33.3 %)	2 (16.7 %)	14 (29.2 %)
Physical examinations			
Tachypnea	39 (100.0 %)	9 (100.0 %)	48 (100.0 %)
Intercostal retractions	27 (75.0 %)	5 (41.7 %)	32 (66.7 %)
Nasal flaring	24 (66.7 %)	5 (41.7 %)	29 (60.4 %)
Cough	27 (75.0 %)	6 (50.0 %)	33 (68.8 %)

Results: All patients underwent rigid bronchoscopy (RB) within 30 minutes. Twenty-four of 48 patients were intubated. Demographic characteristics are shown in Table 1. Symptoms and examination findings are shown in Table 2. The result of bronchoscopy was negative in 9 patients. Most of the FB's were food nature. FB localizations were shown in Table 3. At the end of surgery 6 patients were intubated and received mechanical ventilation. Postop operative X-rays showed abnormality in 6 patients (atelectasis, pneumonia and pneumothorax). Laryngotracheitis, pneumonia and intoxication were diagnosed in RB negative patients. Complications are shown in Table 4. Mortality was seen in 3 patients. No statistical differences were found between intubated and non-intubated patients in terms of intra-and post-operative complications. Additionally, there were no statistical differences between patients with negative and positive results for bronchoscopy in terms of intra-and postoperative complications. The average hospital length of stay was 2 days

Conclusion: The diagnosis requires clinical suspicion, especially in the presence of hypoxia. All patients had low SpO₂ values. In children with severe respiratory distress endotracheal intubation should not be disregarded because it can provide effective ventilation.

Despite negative FB results, urgent bronchoscopy should be implemented in suspicious cases; because early recognition and management leads to improved outcomes for patients. The procedure should be applied by experienced physicians in equipped hospitals.

Keywords: Foreign body, aspiration, pediatric, urgent bronchoscopy

Table 3. Localizations of the FB's

	n (%)
None	9 (18.8%)
Right main bronchus	16 (33.3%)
Left main bronchus	4 (8.3%)
Bilateral bronchus	10 (20.8%)
Trachea	6 (12.5%)
Esophagus	2 (4.2%)
Oropharynx	1 (2.1%)

Values are presented as number (n) and percentage (%).

Table 4. Intra- and Post operative Complications

	n (%)
Intraoperative	
None	42 (87.5%)
Right pneumothorax	1 (2.1%)
Cardiac arrest-death	2 (4.2%)
Bleeding	1 (4.2%)
Tracheostomy	2 (4.2%)
Postoperative	
None	43 (89.6 %)
Bilateral pneumothorax	1 (2.1%)
Pneumonia	1 (2.1%)
Death	1 (2.1%)

[Abstract:0144] PS-091 [Accepted:Poster Presentation] [Pulmonary Rehabilitation and Chronic Care]

Relationship between the DOSE Index and Respiratory and Peripheral Muscle Strength, Activities of Daily Living and Quality of Life in Patients with Chronic Obstructive Pulmonary Disease

Ebru Çalık Kütükcü¹, Hülya Arıkan¹, Naciye Vardar Yağlı¹, Melda Sağlam¹, Deniz İnal İnce¹, Çiğdem Öksüz², Sema Savcı³, Tülin Düger¹, Lütfi Çöplü⁴

¹Department of Physiotherapy and Rehabilitation, Hacettepe University, Faculty of Health Sciences, Ankara, Turkey

²Department of Ergotherapy, Hacettepe University, Faculty of Health Sciences, Ankara, Turkey

³Dokuz Eylül University, School of Physiotherapy and Rehabilitation, İzmir, Turkey

⁴Department of Chest Medicine, Hacettepe University School of Medicine, Ankara, Turkey

Objectives: Composite measures have the potential to account for many of the facets of disease in chronic obstructive pulmonary disease (COPD). The purpose of this study was to investigate the relationship between the DOSE (Dyspnea, Obstruction, Smoking, Exacerbation) index which is a multi-component assesment tool and respiratory and peripheral muscle strength, activities of daily living (ADL) and in health-related quality of life in patients COPD.

Methods: Forty-five patients with COPD (30 males, 15 females, mean FEV₁=50.6±16.0%) were included in the study. The DOSE index was calculated using the MRC dyspnoea scale, FEV₁%, smoking status, and exacerbation rate. Respiratory muscle strength (MIP-MEP) was measured with mouth-pressure device, peripheral muscle strength was measured by Jamar hand

dynamometer. Activities of daily living was evaluated with London Chest ADL questionnaire and quality of life was assessed by disease-specific COPD Assessment Test (CAT).

Results: DOSE index score was related with MIP ($r=-0.323$, $p=0.033$), right and left hand grip strength ($r=-0.397$, $r=-0.371$ respectively, $p<0.05$), London Chest ADL-physical activity score ($r=0.314$, $p=0.038$), London Chest ADL-leisure activities score ($r=0.397$, $p=0.008$) and CAT score ($r=0.435$, $p=0.003$).

Conclusion: This study demonstrates that inspiratory and peripheral muscle strength, physical activity and leisure time activities of daily living and health-related quality of life decreases in COPD patients as multi-component disease severity increases. The DOSE index, a simple disease severity assessment tool, is convenient and practical in pulmonary rehabilitation programs.

Keywords: COPD, activities of daily living, DOSE index, quality of life, muscle strength.

[Abstract:0150] PS-179 [Accepted:Poster Presentation] [Tuberculosis]

Tumor Necrosis Factor Alpha Inhibitors and Tuberculosis

Nazlı Deniz Atik, Nesrin Moğulkoç

Department of Chest Diseases, Ege University School of Medicine, İzmir, Turkey

Tumour necrosis factor (TNF) -alpha inhibitors increase the risk of tuberculosis (TB). Cases of TB occurring in association TNF-alpha inhibitors have a higher likelihood of involving extrapulmonary sites and of being disseminated at presentation compared with TB in the absence of immunosuppression. Patients treated with TNF-alpha inhibitor should be educated on the pulmonary and the extrapulmonary symptoms of TB. All patients being considered for TNF-alpha inhibitor therapy should be screened for latent TB infection (LTBI). Appropriate screening includes a careful history focused on epidemiologic risk factors for prior TB exposure, physical examination, the use of screening tests such as tuberculin skin tests (TST) or interferon gamma releasing assay (IGRA), and a chest radiograph in those with a positive TST or IGRA, or with a history or physical exam suggestive of TB. Patients diagnosed with LTBI who are planning to take TNF-alpha inhibitor should be treated with 9 months of isoniazid (INH). There should be some delay between starting LTBI treatment and starting the TNF-alpha inhibitor. We present a case of extrapulmonary TB despite the patient having received treatment of LTBI with INH. A forty-two-year-old woman with ankylosing spondylitis was prescribed adalimumab. In view of her TST results, she took INH therapy before commencing adalimumab therapy. Two years later, she presented with abdominal distension and abdominal pain of three months duration. She lost ten kilograms weight in two months. She was initially diagnosed as having ovary carcinomatosis. On pelvic magnetic resonance imaging (MRI), there were signs of peritonitis carcinomatosa with diffuse abdominal fluid. She was referred to general surgery; peritoneal incisional biopsy and liver biopsy were performed, which showed granulomatous peritonitis and granulomatous hepatitis. She came to our clinic with her results. Following her biopsy results and clinical assessment, we start her on anti-TB therapy for extrapulmonary tuberculosis.

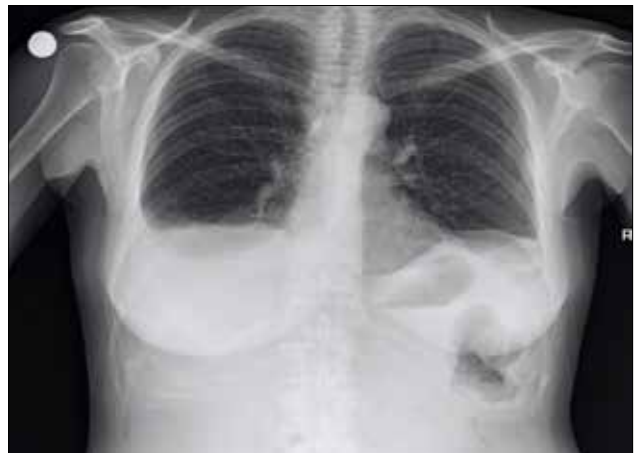

Figure. Chest x-ray

Keywords: Tumor necrosis factor-alpha inhibitor, adalimumab, tuberculosis, extrapulmonary tuberculosis

[Abstract:0152] SS-058 [Accepted:Oral Presentation] [Environmental and Occupational Lung Diseases]

A Group of Student's Determination of Air Pollution Knowledge The Perception and Sensitivity Levels for Air Pollution

Remziye Can¹, Şerif Kurtuluş²¹Pınar Vocational and Technical Anatolian High School, Public Health Nursing, Şanlıurfa, Turkey²Department Chest Disease, Ceylanpınar Governmental Hospital, Şanlıurfa, Turkey

Objectives: Air pollution is an important public health problem that leads to a decrease in the quality of life with its disease and economic burdens, a serious shot of mortality and morbidity. One of the most important sources of air pollution is human-based activities.

To investigate medical high school students' knowledge, the perception and sensitivity levels for air pollution.

Methods: The study were conducted with total 513 volunteer student in health high school in Eskişehir province center in December 2017. Descriptive designed this study, To collect of data the participants' socio-demographic characteristics, knowledge of the diseases caused by air pollution, basic pollutants and sources of air pollution intended the air pollution on survey with perception and sensitivity of air pollution was used "The Air Pollution Perception and Sensitivity Scale" (TAPPSS). TAPPSS developed by the Akkurt 2011, Cronbach's alpha values: 0.85.

Results: The participants of the study group ranged from 14-18 years old with a mean of 15.80±1.05. The class level and TAPPSS score founded a significant difference (p<0.05). The participants 81.9% (n=420) were living in the city center. There

Table 1. TAPPS Score Difference According to Sociodemographic Characteristics of Student's TAPPSS: The Air Pollution Perception and Sensitivity Scale

Characteristic(N:513)	n (%)	TAPPSS Median(Percentiles25-75)	Test Value: p (z/KW)
Gender			
Female	359(70)	145(135.0-153.5)	556;0.578
Male	154(30)		
Age Groups			
>14	62(12.1)	145(135.0-153.5)	1.749;0.417
15-16	301(58.7)		
17<	150(29.2)		
Class Level			
9	125(24.4)	145(135.0-153.5)	10.527;0.015
10	150(29.2)		
11	139(27.1)		
12	99(19.3)		
Habitation			
Province	420(81.9)	145(135.0-153.5)	1.590;0.451
Distirct	51(9.9)		
Village	42(8.2)		
Maternal Training State			
Not to Read -write	10(1.9)	145(135.0-153.5)	0.805;0.669
Primary School	228(44.4)		
Preparatory- High School	250(48.7)		
Academy and upper	25(4.9)		
Paternal Training State			
Not to Read -write	2(0.4)	145(135.0-153.5)	1.622;0.444
Primary School	116(22.6)		
Preparatory- High School	346(64.7)		
Academy and upper	49(9.6)		
Family Income Level			
Bad	19(3.7)	145(135.0-153.5)	1.185;0.553
Middle	369(71.9)		
Good	125(24.4)		

Table 2. TAPPS Score Difference For The Environmental Issue of The Student's TAPPS:The Air Pollution Perception and Sensitivity Scale

<u>Characteristic(N:513)</u>	<u>n(%)</u>	<u>TAPPS Median(Percentiles25-75)</u>	<u>Test Value z; p</u>
<u>Do you have environmental education throughout your learning</u>			
<u>Yes</u>	185(36.1)	145(135.0-153.5)	2.067;0.039
<u>No</u>	328(63.9)		
<u>Have you heard of any environmental agency?</u>			
<u>Yes</u>	306(59.6)	145(135.0-153.5)	0.838;0.402
<u>No</u>	207(40.4)		
<u>Are you members of the environmental organization?</u>			
<u>Yes</u>	64(12.5)	145(135.0-153.5)	0.130;0.896
<u>No</u>	449(87.5)		

was no significant difference between residing and TAPPS score. However, it was determined that those who live in the rural area had higher scores on the TAPPS than those living in the urban area. The participants 36.1% (n=185) had environmental education during their education life, and there was found a statistically significant difference between their environmental education status and TAPPS score. ($p<0.05$). The participants 56.9% (n = 306) are heard to any environmental organization. While the participants of the study ranged score from 40 to 200 TAPPS, mean total score was 144.88 ± 16.64 . The participants had a score of 0-6 for air pollution questions and the total score was 4.77 ± 1.25 . It was found a statistically significant correlation between the TAPPS score and total score of the participants in the air pollution questions ($p<0.001$).

Conclusion: It is an issue which should be addressed to the public health to increasing air pollution perception and sensitivity that the trainings, which will be given for preventing air pollution, one of the most important problem not being noticed in our age and raising because of the activities based on human, integrated into the education and training curriculum.

Keywords: Air pollution, education, perception and sensitivity, student

Table 3. TAPPS Total Score With Total Information for Air Pollution Correlation TAPPS:The Air Pollution Perception and Sensitivity Scale

<u>Total Score Information for Air Pollution</u>	<u>TAPPS Total Score</u>	
	<u>r_s</u>	.138
	<u>p</u>	.002

[Abstract:0157] EPS-104 [Accepted: E-Poster] [Lung and Pleura Malignancies]

A Lymphoma Case with Lung Involvement

Abdulvahap Göktürk¹, Ayşe Füsün Topçu¹, Cihan Akgül Özmen², İbrahim Baran¹, Gökhan Çoraplı¹, Serdar Keskin¹, Emine Çelik¹, Mazlum Dursun¹, Veysi Tekin¹

¹Department of Chest Diseases Dicle University School of Medicine, Diyarbakır, Turkey

²Department of Radiology, Dicle University School of Medicine, Diyarbakır, Turkey

Case Presentation: Lung parenchymal involvement is rarely encountered during the presentation of lymphoma. It is seen more commonly in Hodgkin's Lymphoma (HL) than in Non-Hodgkin's Lymphoma (NHL). Large B-cell lymphoma, which is one of NHL subtypes, constitutes 30-50% of all NHLs. While the mean diagnostic age is 70 years, it is rarely seen in children and young adults. Mediastinal lymph node packet was detected in the thoracic computed tomography (CT) of a 23-year-old female patient on June 2016. She was histopathologically diagnosed with anaplastic variant of large B-cell lymphoma according to the result of supraclavicular lymph node excisional biopsy. She was administered 8 doses of Rituximab, Cyclophosphamide, Doxorubicin, Vincristine, Prednol (R-CHOP) for 5 months and then radiotherapy for one month. Radiotherapy was terminated on January 2017 and then she had the complaint of dry cough following it. When parenchymal

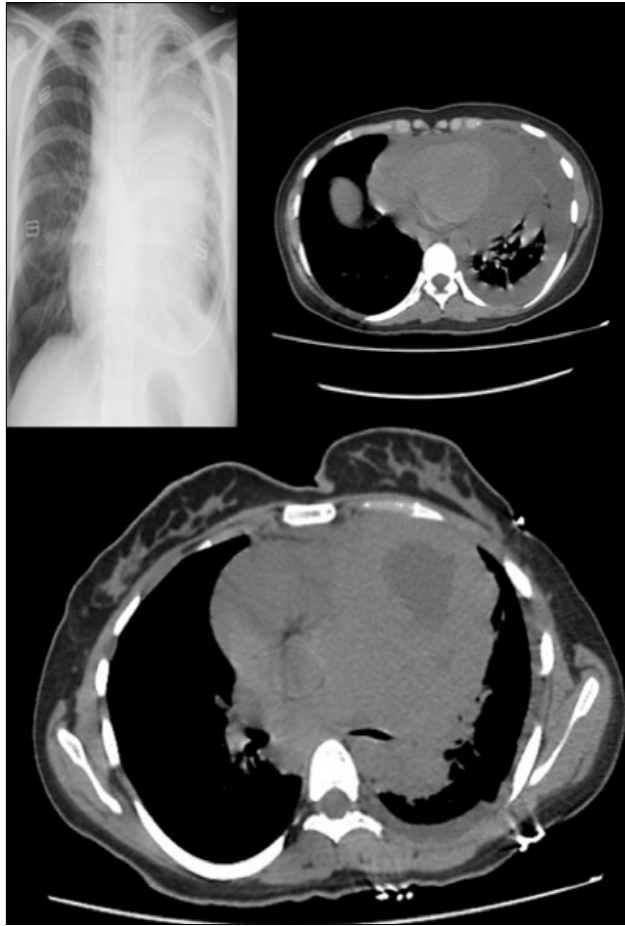


Figure 1. Mediastinal view at the time of diagnosing lymphoma for the first time

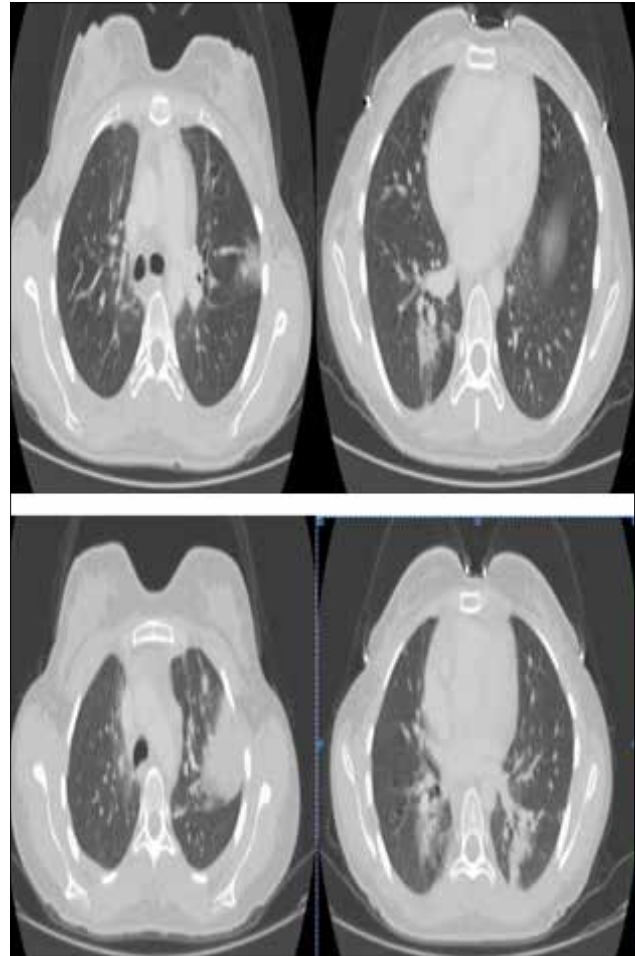


Figure 2. Lung parenchymal involvement after one year

consolidated areas were detected in the control CT of the patient on August 2017, she was referred to our outpatient clinic and she was given antibiotics therapy and recommended to visit for control after treatment. However, she did not come for control examination. In thoracic CT that was performed in the outpatient clinic of oncology after 3 months, a progression was detected in the lesions in her lung and PET-CT was performed. The patient, who was referred to our outpatient clinic because of involvement in consolidated areas in the lung, was hospitalized for the purpose of examination and treatment. The only complaint of the patient was dry cough. Her laboratory findings were as follows: WBC: 7.000 10⁹/L, CRP: 0.9 mg/dL, sedimentation:17 mm/hour, Hb:11 g/dL, Htc: 35%, Plt:265.000 cell/mm³. Transthoracic biopsy was planned for the patient and its histopathological result was reported as the anaplastic variant of diffuse large B-cell lymphoma. It was decided to apply quinary R-CHOP combined treatment by medical oncology and it was begun.

Conclusion: We wanted to present this patient because of rare occurrence of diffuse large B-cell lymphoma, which is a subgroup of NHL, and lung parenchymal involvement in young individuals.

Keywords: Lymphoma, non-hodgkin, lung

[Abstract:0159] EPS-301 [Accepted: E-Poster] [Tuberculosis]

Evaluation of Drugs Against Tuberculosis in Terms of Their Additional Effects in Various Age Groups

Nazile Mammad Murquzova, Hagigat Gadirova Gadirova, İlham Gasimov Gasimov

Republic of Azerbaijan, Training and Research Hospital for Chest Diseases, Azerbaijan

Objectives: Recent difficulties that emerge in the treatment of tuberculosis cause increased mortality in these patients. One of the most important thing in the treatment of tuberculosis is to determine the sensitivity levels of all patients to AFB rugs on time. At present, the effectiveness of treatment for tuberculosis is not more than 60%. There are many other factors affecting the results of treatment in addition to the identification of chemotherapy regime. These factors include those: patients' avoiding examination, not continuing the treatment in order, not taking drugs in proper doses, smoking, being narcomania, alcoholism, and socioeconomic status. High resistance levels of mycobacteria to drugs are recorded. Considering the complications in middle-aged and elderly patients who have received chemotherapy, the dose of drugs should be adjusted according to the weight of each patient due to the toxic effect of drugs.

Methods: Fifty patients with destructive pulmonary tuberculosis were selected for examination. The patients were between the ages of 40 and 60 years. Of them, 37 were male and 13 were female. Their clinical findings, posterior-anterior chest radiography, laboratory values, and bacteriological results were evaluated. The patients were put into two groups according to their clinical courses and complications. Group 1 included patients who received irregular chemotherapy for 3 years and had complications and group 2 included patients who received irregular chemotherapy for 7 years and more and had complications.

Results: In Group 1, infiltrative tuberculosis was at the stage of cavity at the rate of 42%, in the right lung at the rate of 28%, in the left lung at the rate of 20%, and in both lungs at the rate of 52%. Cough, sticky sputum, chest pain, loss of appetite, fatigue, and skin rashes were clinically observed in these patients.

In group 2, cavitary appearance was observed in PAAC at the rate of 58%, in the right lung at the rate of 34%, in the left lung at the rate of 23%, and in both lungs at the rate of 43%. Moreover, fibroplasia and other morphological changes (pneumo-sclerosis and bronchiectasis) were found. In these patients, biochemical analyses results including 83% ALT, AST, thymol, bilirubin, creatinine, and uric acid were high. With these recorded clinical signs, the patients were hospitalized for treatment again. After revealing tuberculosis with the help of molecular methods for the determination of resistance to drugs, treatment is initiated with related chemotherapy regimes. In these patients, treatment is begun earlier by revealing the sensitivity of two proprietary drugs (bactericide, bacteriostatic effect) against tuberculosis through GenXpert, MGIT, and HAIN methods of AFB and successful results can be obtained.

Conclusion: According to the results of our study, it can be suggested that toxic-allergic reactions of patients at the age group of 40-60 years weaken their immune systems much more and the presence of comorbidities (cardiopulmonary insufficiency, amyloidosis, profuse bleeding, laryngeal tuberculosis, and oncological diseases) causes the conditions of patients to be more severe and even death. Therefore, toxic effects of drugs should be taken into consideration in treatment and each patient should be given an individual drug dose. Pathological changes should be revealed and resolved on time.

Keywords: Tuberculosis treatment, additional effects of drugs, GenXpert

[Abstract:0161] PS-120 [Accepted:Poster Presentation] [Pulmonary Rehabilitation and Chronic Care]

Comparison of Respiratory Functions and Physical Fitness in Patients with Liver Transplantation and Healthy Subjects

Bilge Taşkın¹, Naciye Vardar Yağlı¹, Ebru Çalık Kütükçü¹, Melda Sağlam¹, Deniz İnal İnce¹, Hülya Arıkan¹, Ahmet Bülent Doğrul²

¹Hacettepe University Faculty of Health Sciences Department of Physiotherapy and Rehabilitation, Ankara, Turkey

²Hacettepe University Faculty of Medicine Tissue and Organ Transplantation Center. Ankara, Turkey

Objectives: In the literature, it has been shown that the functional capacity of patients with liver transplant is reduced. The aim of our study was to compare the respiratory functions and physical fitness levels of healthy subjects and liver transplant patients.

Methods: Nine liver transplantation patients (mean age: 39.9±13.7 years, mean time after transplantation: 7±5.9 years) and seven age and gender matched healthy controls participated in this study. Respiratory function testing was performed. Physical fitness parameters were assessed with The Senior Fitness Test.

Results: There was no significant difference between the groups in terms of respiratory function testing ($p>0.05$). The number of 30-second chair stand, the number of right and left arm curl and the six-minute walking test distance were significantly

lower in patients with liver transplantation when compared with controls ($p<0.05$). The time of eight foot-up and go was significantly higher in patients with liver transplantation as compared with healthy subjects ($p<0.05$)

Conclusion: Respiratory functions are preserved in patients with chronic liver transplantation. Patients' lower and upper extremity strength, functional capacity, dynamic balance and agility are affected negatively compared to healthy subjects. The parameters of physical fitness should be assessed comprehensively in rehabilitation of liver transplantation patients.

Keywords: Liver transplantation, physical fitness, respiratory function

[Abstract:0162] PS-252 [Accepted:Poster Presentation] [Environmental and Occupational Lung Diseases]

Silicotuberculosis in a dental prosthesis technician

Fadime Sultan Albez, Metin Akgün

Department of Pulmonary Disease, Atatürk University School of Medicine, Erzurum, Turkey

Silica exposure in fibrogenic forms can lead to silicosis, which can result in progressive and irreversible damage, in the lungs. Silicosis, which is an occupational disease with a high morbidity and mortality rate, is seen in a various occupational setting including quarries, mining, foundry, pottery making, and sandblasting. It can be seen in relatively new occupational areas, including dental technician. Silica exposure increases tuberculosis (TB) risk but the diagnosis of TB sometimes can be challenging because of the confusion of radiological findings and the difficulty of detecting the bacilli. The aim of this report is to draw attention to the importance of the association of silicosis-tuberculosis in a dental technician who had silica exposure. A 31-year-

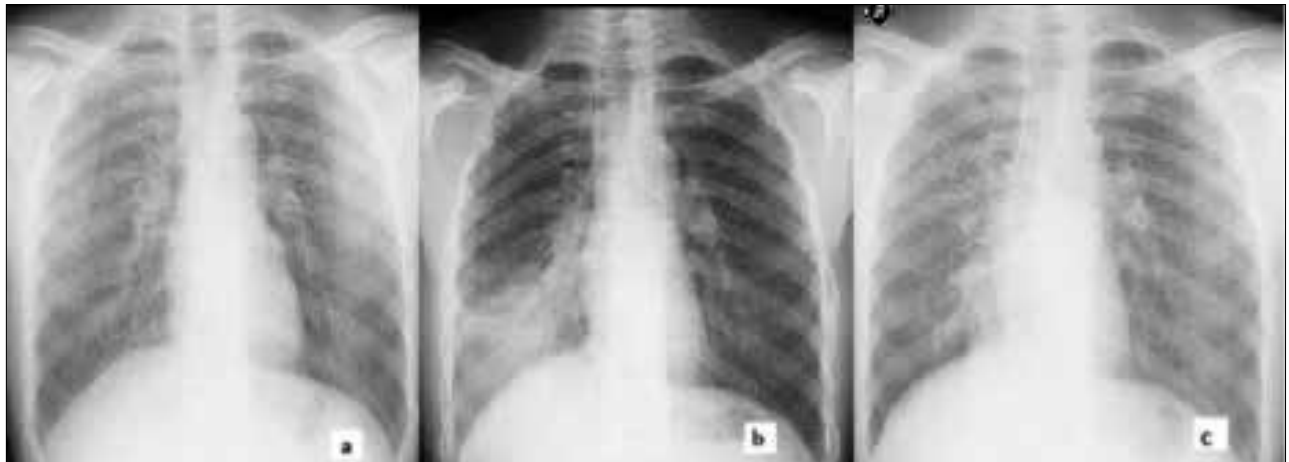

Figure 1. Chest x-rays, 1a: Bilateral diffuse nodular opacities. 1b: Consolidation at the right low zone. 1c: Atelectasis at the right low zone

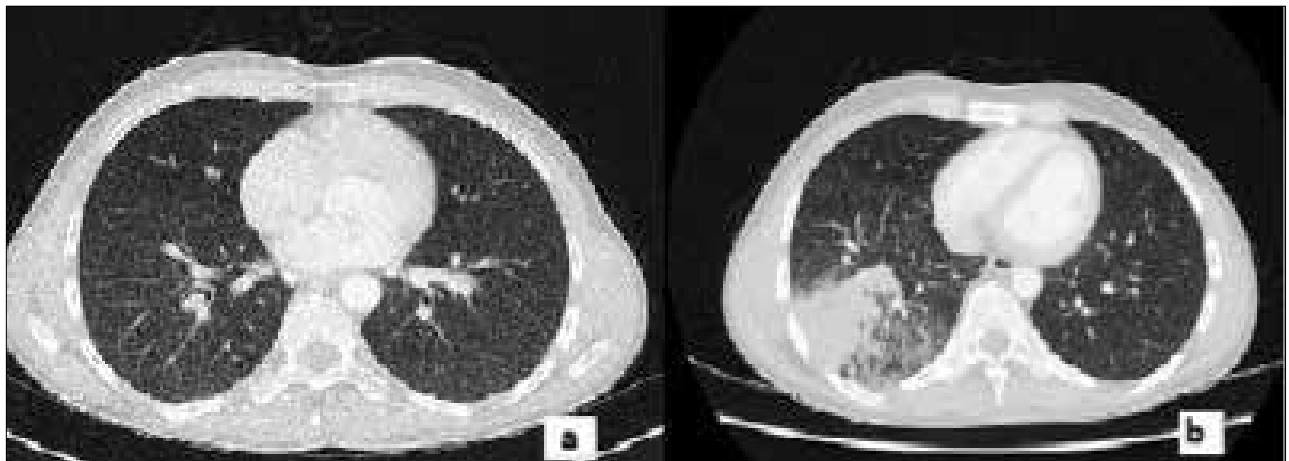


Figure 2. Bilateral diffuse nodular opacities in HRCT, 2b:Consolidation

old male dental technician for 8 years applied to our outpatient clinic for a routine check-up. He was smoker, 8-pack-year, and his family history had no traits. Physical examination and laboratory findings were unremarkable, except for a mild cough. His chest x-ray revealed pulmonary nodular infiltration throughout the lungs and hilar lymph nodes. His tuberculin skin test was positive, 14 mm, and scary. Induced sputum examination and cultures were negative for TB. The patient was diagnosed as silicosis based on typical history, clinical and radiological findings. He was advised to change his job. A year later, he admitted again with the complaints of cough, sputum, fever, and sweating. His chest x-ray showed heterogeneous pneumonic consolidation in the lower right zone and sputum examination was positive for TB. The TB diagnosis confirmed with culture results. He was prescribed anti-TB treatment for 9 months according to the 2011 Guideline of Health Ministry. Treatment success was achieved in the 9th month of treatment and treatment stopped. Dental Technician has silicosis risk and silicotuberculosis should be kept in mind in presence of symptoms such as sputum, cough, weakness, fever, and anorexia in patients with silicosis.

Keywords: Dental technician's pneumoconiosis, silicosis, tuberculosis

[Abstract:0163] EPS-149 [Accepted: E-Poster] [Respiratory Infections]

Roles of Real-Time Polymerase Chain Reaction and High-Resolution Computed Tomography in the Diagnosis of Pneumocystis Jiroveci Infection and Pulmonary Pneumonia

Aysel Elman Aslanova¹, Aysel Elman Aslanova², Elcan Nazim Mamedbeyov¹, Aziz Musayev¹, Gulzar Aliyeva¹, Ilham Gasimov¹, Nuriyye Salimova¹, Hadiyya Hasratova¹, Zaur Hacimammadli¹, Chinara Pashayeva¹

¹Republic of Azerbaijan, Training and Research Hospital for Chest Diseases, Azerbaijan

²Science Development Foundation under the President of the Republic of Azerbaijan, Azerbaijan

Objectives: Pneumocystis jiroveci is a disease that particularly presents with pulmonary involvement in patients with suppressed immune system (HIV positive in our case). In Pneumocystis jiroveci pneumonia, the most common clinical findings are dyspnea, tachypnea, cough, fever, and cyanosis. Cough is non-productive. In the physical examination of patient, rales can be auscultated in the lungs or the lung sounds can be completely normal. Diffuse, bilateral interstitial or alveolar infiltrates can be found in chest radiography. In 50% of AIDS patients, the results of chest radiography can be normal. While there are other medication alternatives, trimethoprim-sulfamethoxazole (TMP-SMZ) prophylaxis is recommended as the first choice for treatment. If it is not treated, the disease can result in death.

Interstitial pneumonia appears radiologically. In the postero-anterior chest radiography, bilateral diffuse infiltrative appearance beginning from the perihilar region is observed in 90% of cases. Besides that, atypical radiological views including cavitation, consolidation, pneumatocele, and pneumothorax can be detected. While the findings of posterioranterior chest radiography are found to be normal, ground-glass appearance and cystic lesions can be observed in high-resolution computed tomography (HRCT), which is a more sensitive method. In the diagnosis of pneumocystis jiroveci, molecular diagnostic

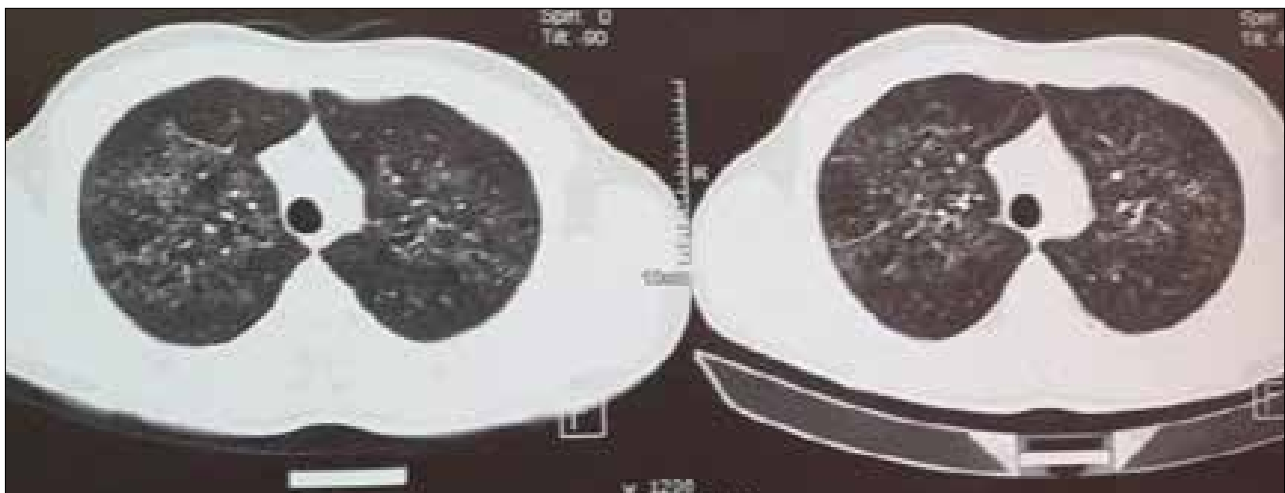


Figure 1. Pneumocystis Jiroveci infection and pulmonary pneumonia

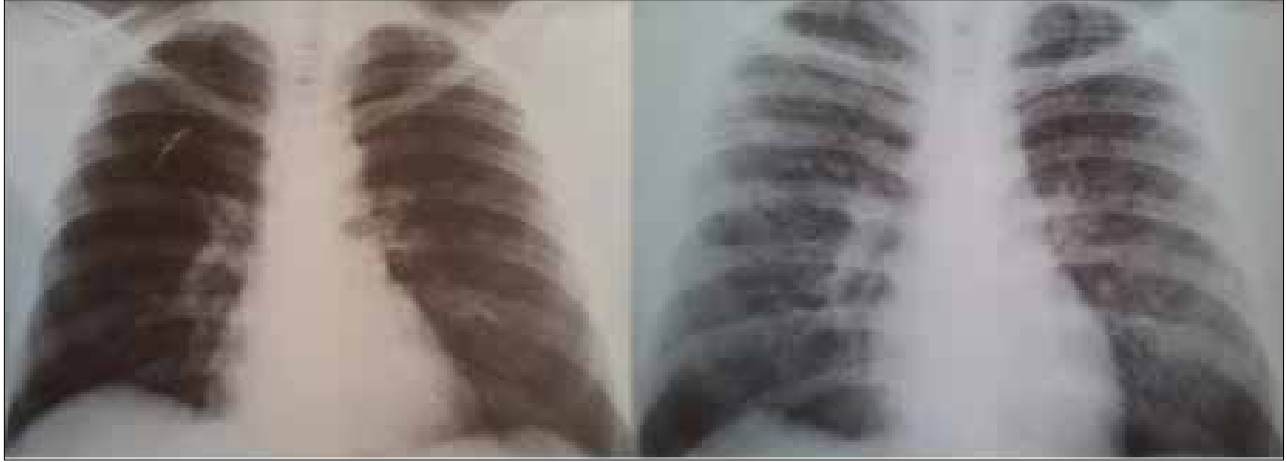

Figure 2. Pneumocystis Jiroveci infection and pulmonary pneumonia

methods have higher sensitivity than microscopic diagnostic methods. Sensitivity rates have been increased by the use of polymerase chain reaction (PCR) -DNA amplification.

Methods: In our study, clinical pictures, radiological findings, and laboratory analyses of patients who were diagnosed with pneumocystis jiroveci in the Republic of Azerbaijan Education and Research Hospital for Chest Diseases were investigated. In 3 patients who were admitted to the hospital due to the complaints of cough and fever, lung sounds and posteroanterior chest radiography findings were normal, but ground-glass appearance and cystic lesions were found in the high-resolution computed tomography (HRCT). The diagnosis of pneumocystis jiroveci was established by PCR-DNA amplification in the patients. They were immediately begun trimethoprim-sulfamethoxazole (TMP-SMZ) therapy. In the evaluation of underlying risk factors, the result of HIV test was positive in all patients. The suppression of the immune system was recorded as CD4 cell count $200 < \text{cell/mm}^3$ and treatment was initiated. One patient refused to be treated and was discharged from the hospital. After 24 days, this patient was admitted to the intensive care unit due to bilateral diffuse interstitial pneumonia and severe cyanosis and tachypnea and begun TMP-SMZ and high-dose corticosteroid. Despite the treatment, the patient died.

Results: In spite of developments in examination and treatment opportunities at present, pneumocystis jiroveci is a disease resulting in high mortality. It is important to evaluate clinical pictures carefully and to perform laboratory and radiology procedures. A multidisciplinary approach and contact with laboratory facilitate the establishment of early diagnosis. This study was conducted with the financial support of the Science Development Foundation under the President of the Republic of Azerbaijan- Grant N EIF / GAM -3-2014-6 (21) -24/19/3.

Keywords: Pulmonary pneumonia, pneumocystis jiroveci, high-resolution computed tomography

[Abstract:0164] EPS-167 [Accepted: E-Poster] [Respiratory Infections]

Unexplained Pleural infection in an Immunosuppressive Patient: Nocardiosis

Ebru Gamze Göker¹, Ahmet Emin Erbaycu¹, Mine Gayaf¹, Dursun Alizoroğlu¹, Soner Gürsoy², Mete Demirel³

¹Department of Pulmonary, Dr. Suat Seren Chest Diseases and Thoracic Surgery Training and Research Hospital, İzmir, Turkey

²Department of Thoracic Surgery, Dr. Suat Seren Chest Diseases and Thoracic Surgery Training and Research Hospital, İzmir, Turkey

³Department of Microbiology, Dr. Suat Seren Chest Diseases and Thoracic Surgery Training and Research Hospital, İzmir, Turkey

Pleural Nocardiosis a rare pleural involvement and usually is together with pulmonary paranchimal involvement. The case presented had been treated with systemic corticosteroid for a long time because of temporal arteritis. He was continuing to use the treatment when he was referred to our clinic in order to have the diagnosis of the pleural disease. Pleural culture was positive for Nocardia and then, trimethoprim-sulfamethoxazole treatment was initiated. There was a clinical and radiological improvement with treatment.

Pleural Nocardiosis should be kept in mind in the differential diagnosis of pleural effusions those with unknown origin in immunosuppressive patients.

Keywords: Pleural nocardiosis, pleural effusion, corticosteroid, immunosuppression

[Abstract:0165] PS-235 [Accepted:Poster Presentation] [Tobacco Control]

Assessment of Relationship between Smoking Tendency and Depression in Pregnant Women

Şerif Kurtuluş¹, Remziye Can², Zafer Hasan Ali Sak³¹Department of Chest Diseases, Ceylanpınar Government Hospital, Şanlıurfa, Turkey²Pınar Vocational and Technical Anatolian High School, Public Health Nursing, Şanlıurfa, Turkey³Department of Chest Diseases, Harran University School of Medicine, Şanlıurfa, Turkey**Table 1.** Distribution of Smokers and Non-Smokers Per Some Obstetric Characteristics in the Study Group

Some sociodemographic Characteristics	Smoking Status			Test value X ² ; p
	Smoker n (%) [*]	Non-smoker n (%) [*]	Total n (%) ^{**}	
Nationality				
Syria	68 (34.0)	132 (66.0)	200 (48.3)	2.529; 0.112
Turkey	89 (41.6)	125 (58.4)	214 (51.7)	
Age group				
≤24	43(28.5)	108(71.5)	151(36.5)	10.471; 0.005
25-34	79(41.1)	113(58.9)	192(46.4)	
≥35	35(49.3)	36(50.7)	71(17.1)	
Educational status				
Illiterate	82(48.5)	87(51.5)	169(40.8)	19.867;0.001
Elementary-Secondary school	45(25.7)	130(74.3)	175(42.3)	
High School and over	30(42.9)	40(57.1)	70(16.9)	
Family Structure				
Elementary Family	112(38.4)	180(61.6)	292(70.5)	0.079; 0.779
Extended Family	45(28.7)	77(30.0)	122(29.5)	
Residence				
Tent city	56 (33.1)	113(66.9)	169 (40.8)	2.779;0.095
County Town	101 (41.2)	144 (58.8)	245(59.2)	

Table 2. Distribution of Smokers and Non-Smokers in the Study Group Per Their Smoking Characteristics

Some familial characteristics	Smoking Status			Test value X ² ; p
	Smoker n (%) [*]	Non-smoker n (%) [*]	Total n (%) ^{**}	
Smoking Status of Family Members				
Yes	149(44.9)	183(55.1)	332(80.2)	34.460; 0.001
None	8(9.8)	74(90.2)	82(19.8)	
Smoking Status of Spous				
Yes	128(42.5)	173(57.5)	301(72.7)	9.922; 0.002
None	29(25.7)	84(74.3)	113(27.3)	
In-house smoking exposure status				
Yes	144(43.4)	188(56.6)	332(80.2)	Fisher; 0.000
No	13(15.9)	69 (84.1)	82(19.8)	

Table 3. Depression Distribution Per Smoking Status in Pregnancy

Smoking Status in Pregnancy	Depression Presence			Test value X ² ; p
	Yes n (%)*	None n (%)*	Total n (%)**	
Yes	108 (68.8)	49 (31.2)	157 (37.9)	36.642; 0.001
No	98 (38.1)	159 (61.9)	257 (62.1)	

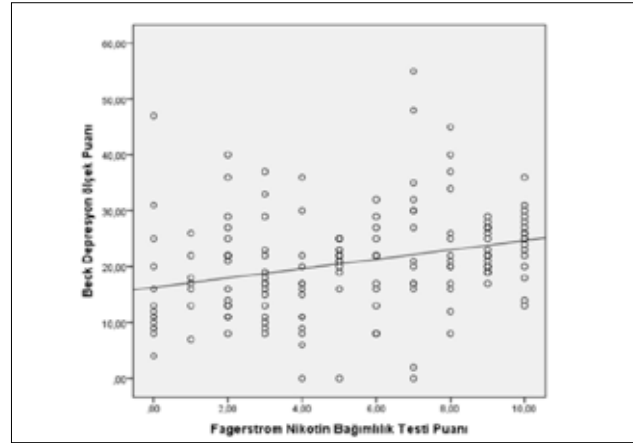


Figure 1. Scores From the Fagerstrom Test for Nicotine Dependence and From The Beck Depression Scale of the People in Study Group

Table 4. Scores From the Fagerstrom Test for Nicotine Dependence and From The Beck Depression Scale of the People in Study Group

Some Opinions about Smoking Applications	Citizenship Status			Test value X ² ; p
	Refugee n (%)*	Turkish Citizen n (%)*	Total n (%)**	
Opinion 1: Do you know the smoking prohibition in closed areas that the Ministry of Health applies?				9.226; 0,001
Yes	147(44.5)	183(55.5)	330(79.7)	
No	53(63.1)	31(36.9)	84(20.3)	
Opinion 2: Do you approve the smoking prohibition in closed areas that the Ministry of Health applies?				3.342;0.068
Yes	165(46.5)	190(53.5)	335(85.7)	
No	35(59.3)	24(40.7)	59(14.3)	
Opinion 3: Do you think that smoking prohibition in closed areas that the Ministry of Health applies decreased smoking number?				20.030;0.000
Yes	28(28.6)	70(71.4)	98(23.7)	
No	172(54.4)	144(45.6)	316(76.3)	
Opinion 4: Did you get any fine due to the smoking prohibition in closed areas that the Ministry of Health applies?				Fisher; 0.752
Yes	4(40.0)	6(60.0)	10(2.4)	
No	196(48.5)	208(51.5)	404(97.6)	
Opinion 5: Do you know anyone who get any fine due to the smoking prohibition in closed areas that the Ministry of Health applies?				5.856;0.016
Yes	8(25.8)	23(74.2)	31(7.5)	
No	192(50.1)	191(49.9)	383(92.5)	
Opinion 6: Do you know any health problems caused by smoking?				1.359;0.244
Yes	172(47.1)	193(52.9)	365(88.2)	
No	28(57.1)	21(42.9)	49(11.8)	
Opinion 7: Have you experienced any discomfort due to smoking?				1.874;0.392
Non-smoker	70(44.6)	87(55.4)	157(37.9)	
Yes	68(52.7)	61(47.3)	129(31.2)	
No	62(48.4)	66(51.6)	128(30.9)	
Opinion 8: Do you know that people who are surrounded by cigarette smoke in enclosed spaces are harmed as passive smokers?				0.920;0.337
Yes	157(47.1)	176(52.9)	333(80.4)	
No	43(53.1)	38(46.9)	81(19.6)	
Opinion 9: Can you reach cigarettes easily?				9,250; 0,010
Non-smoker	90(57.3)	67(42.7)	157(37.9)	
Yes	97(44.1)	123(55.9)	220(53.1)	
No	13(35.1)	24(64.9)	37(8.9)	

Objectives: Smoking in pregnancy has negative effects on maternal and fetus health. One of these adverse effects is depression. High prevalence cigarette consumption in pregnancy is important public health issue, not only pregnant woman, but also affecting newborn and child health. This study, it was aimed to investigate relationship between smoking behavior influencing factors, depression prevalence situation Syrian refugees and TC (Turkish Citizens) pregnant.

Methods: Total 414 pregnant TC and Syrian refugees living in the tentvillage and district center, and registered in the Public Health Institution between 15.04.2017-15.10.2017 in Ceylanpınar, the border city of Şanlıurfa to Syria were included in the survey. To collect data cross-sectional design, the pregnant were asked to fill, socio-demographic and obstetric characteristics of the population, views of the Ministry of Health's fight against tobacco products, The Fageström Nicotine Dependence Scale (FNDS) and the Beck Depression Inventory (BDI) were applied to them.

Results: The prevalence of smoking all pregnancies was determined 49.3% before pregnancy and 37.9% during pregnancy. There was statistically significant difference between age groups, education status and smoking status. Statistical difference between smoking status of pregnant women and smoking status of spouses and family members was significant ($p=0.001$, $p=0.002$). 80.2% of the pregnant were passive smokers. There was significant difference between passive smoking and smoking status (Fisher; 0.000). Depression was detected 49.8% of all pregnancies. While rate of depression was 49.5% the refugees and 50.5% TC pregnant, there was significant difference between smoking status and depression in pregnancy ($p=0.001$). 32.5% of pregnancies were found to be very nicotine dependent. Positive correlation was detected between FNDS and BDI scores of pregnant women ($r=0.346$, $p=0.001$). Pregnant women's opinions on the Ministry of Health's fight against tobacco products; there was significant difference for Opinion 1, Opinion 3 ($p < 0.001$), Opinion 5 and Opinion 9 ($p < 0.05$).

Conclusion: It was found that one third of the pregnant women smoked, one of two pregnant women showed a depressive affect, and significant difference was found between the smoking status and the presence of depression, while levels of smoking, addiction and depression were high both refugee and T.C pregnancies but there was no significant difference between them. It has been determined that the Ministry of Health's efforts to fight against tobacco products are known to TC and refugees, but that the effectiveness of the audits and inspections aren't adequate. There is a need to develop new preventive strategies for pregnant women's cigarette consumption.

Keywords: Health Policy, Depression, Pregnancy, Second Hand Smoke, Smoking

[Abstract:0166] EPS-001 [Accepted: E-Poster] [Asthma and Allergy]

Spontaneous Pneumomediastinum Associated with an Asthma Exacerbation

İbrahim Güven Çoşğun

Department of Chest Diseases, Afyonkarahisar State Hospital, Afyonkarahisar, Turkey

Introduction: Spontaneous pneumomediastinum (SPM) is a spontaneous, mediastinal air-leak not caused by chest trauma or mechanical ventilation. The etiology of SPM is infection, asthma, esophageal or tracheal rupture, foreign body aspiration, or idiopathic. We present that case of SPM with Asthma.

Case Presentation: A 28-year-old female with a past medical history of Asthma presented to the emergency department complaining of chest pain, dyspnea. A chest radiograph was performed and revealed no pneumothoraces, but gave evidence of cervical and mediastinal emphysema (Figure 1). Thorax CT was then performed which showed extensive cervical and mediastinal emphysema (Figures 2-3) She was managed conservatively with resolution of her pneumomediastinum.

Discussion: Spontaneous pneumomediastinum (SPM) was first described in 1939 by Louise Hamman. Pneumomediastinum (PM) is presence of free air in the mediastinum. In our patient, PM was developed due to an asthma attack. The pathophysiology of SPM was first described by

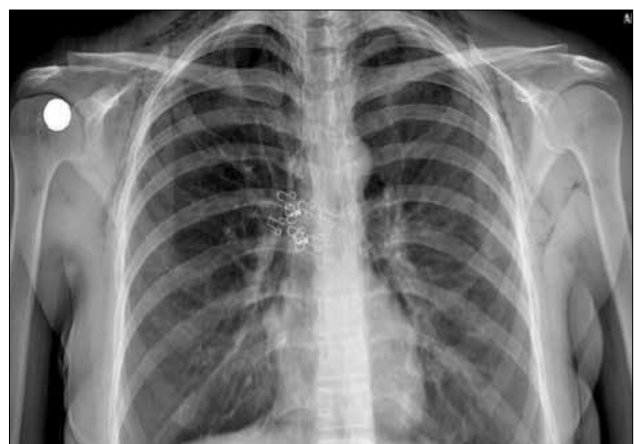

Figure 1.

Macklin. Distal air ways pressure increase due to the obstruction in the minor air ways in Asthma attack. Pressure gradient leads to alveolar rupture and air dissection along the vascular sheaths toward the hilum. Subcutaneous emphysema causes crepitus on palpation of the affected body region. SPM characteristically gives a positive Hamman sign on auscultation and best heard in the left lateral decubitus position. Hamman sign is crunching noise heard synchronously with the heartbeat. It is clinically significant when heard. In our patient did not have hamman's sign or pneumothorax but she did have neck and facial crepitus. One study reviewed the clinical literature, the most common symptoms to be retrosternal chest pain, dyspnea. In our patient have chest pain and dyspnea. Diagnostic evaluation of SPM includes chest X-ray and tomography of thorax. Initial evaluation should include anterior-posterior and lateral chest X-ray. Chest X-ray show free air tracking along the mediastinum and subcutaneous air in neck. Thorax CT is more sensitive and can show small air in the mediastinum or subcutaneous tissues. Small air may not be revealed on chest radiograph. Chest X-ray alone show approximately 30% of SPM. Thus, chest CT was needed to diagnosis of SPM. Uncomplicated SPM managed conservatively with rest, oxygen administration and analgesia. Underlying triggers such as asthma should be treated. Incidence of SPM is quite low. But SPM should be consider especially young adult with such chest pain and dyspnea. Suspicion is key to early diagnosis.

Keywords: Spontaneous pneumomediastinum, asthma, mediastinal emphysema

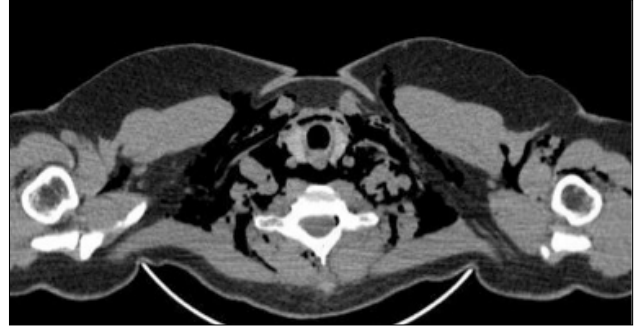

Figure 2.

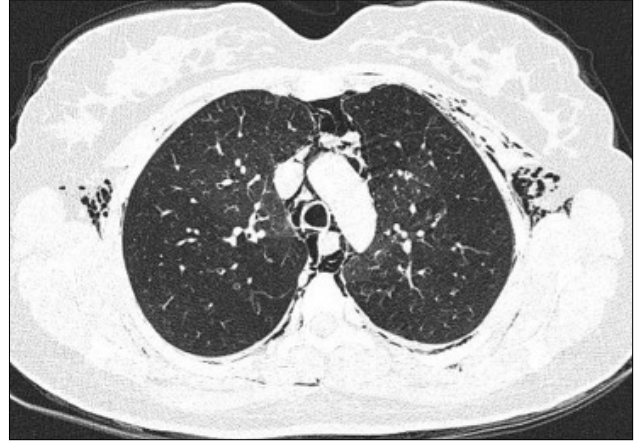


Figure 3.

[Abstract:0168] SS-051 [Accepted:Oral Presentation] [Thoracic Surgery]

Are the Results of Pulmonary Resections Performed for Lung Cancer Worse in Mid-Eighties?

Ali Cevat Kutluk¹, Celalettin İbrahim Kocatürk, Hasan Akın, Sertan Erdoğan, Altan Ceritoğlu, Salih Bilen, Yaşar Sönmezoğlu, Kemal Karapınar

Department of Thoracic Surgery, Health Science University, Yedikule Chest Diseases and Thoracic Surgery Training and Research Hospital, İstanbul, Turkey

Objectives: Aging population is an important problem in Turkey. Lung cancer is a significant cause of mortality in the elderly people. Pulmonary resection still remains to be the best method for providing survival. This study was conducted to evaluate early and late results of patients at the age of 70 years and above by comparing patients in group 1 (between the ages of 70 and 79 years) and group 2 (at the ages of 80 years and above) who underwent surgical resection.

Methods: Patients who were older than 70 years and who were applied resection for the treatment of non-small cell lung cancer between January 2006 and December 2015 were analyzed retrospectively. Data were collected about patients' ages, sexes, comorbidities, spirometry values, blood gas analysis results, surgical side, tumor size, surgical procedure (lobectomy, sublobar resection, and pneumonectomy), tumor histology, pathological TNM stage, postoperative complications, Charlson comorbidity values (CCS), and survival lengths. Patients at the age group of 70-79 years and patients older than 80 years were compared in terms of basic features and results.

Results: During study period, a total of 23105 patients were diagnosed with non-small cell lung cancer. Of them, 324 (7,6%) of 4232 patients undergoing a surgical procedure were at the age of 70 years and over and they were included in the study group. While the mean age of Group 1 (n=282) was 73.01 years, the mean age of Group 2 (n=45) was 81,6 years. While non-squamous cell histology was dominant in both groups, FEV₁ values were higher in Group 1 than in Group 2 (1,94 L vs 1,72 L). The rate of arrhythmia was found to be significantly higher in Group 2 (13% vs 24%). Multivariate analysis demon-

strated that CCS was the only important factor with regard to complications and mortality. The median length and rate of survival were 55 months and 42,5%, respectively. Although survival lengths of Group 2, which was older, were higher than in Group 1, this difference was not found to be statistically significant (49 months vs 56 months). Only lymph node metastases (N2) affected survival significantly.

Conclusion: Surgical results differ between two age groups in terms of morbidity and mortality. In the evaluation of pulmonary resection safety in the elderly patients by considering comorbidities, it is at a level that can be comparable to patients younger than 70 years. In addition, surgical procedures provide satisfying survival rates in both age groups.

Keywords: Elderly patient, surgery, pulmonary resection

[Abstract:0172] PS-301 [Accepted:Poster Presentation] [Pulmonary Pathology]

Association of Congenital Cystic Adenomatoid Malformation with Idiopathic Pulmonary Hemosiderosis

Ekrem Şentürk¹, Ragıp Ortaç²

¹Department of Thoracic Surgery, Near East University School of Medicine, Cyprus

²Medical Park Hospital, Izmir, Turkey

Congenital cystic adenomatoid malformation (CCAM) a rare form of congenital pulmonary airway malformations. CCAM rare developmental abnormality with incidence rate of 1 in 11000 to 1 in 35000 live birth It is characterized by broncho-pulmonary foregut malformations. Idiopathic pulmonary haemosiderosis (IPH) is a rare disease characterized by alveolar capillary hemorrhage resulting in deposition and accumulation of haemosiderin in the lungs. However, the association of CCAM with IPH is very rare. Here, we report a very rare case of a CCAM accompanied by IPH. A literature search was carried out; which an association between CCAM and IPH was not reported.

A 69-year-old female patient was admitted with dyspnea. SpO₂; % 88 and X-ray was normally and Routine laboratory tests were in normal limits and yielded no differential diagnosis. New and old CT scans no shown any diagnostic signs. There are no features, which are pathognomonic for any pulmonary disease. However she had a medical history of a lot of serious dyspnea attacks and their symptomatic treatments among the 7 years. We have not any diagnostic signs in research. Her systemic examination was unremarkable. Laboratory data were: Hb 9.8 g/dL, RBC 3,420.000/mm³, MCV 83, Hct 38.5%. Sedimentation rate was 25 mm/hour, C-reactive protein 0.53 mg/dL. Serum iron 6 µg/dL, total iron-binding capacity (TIBC) 743 µg/ dL, ferritin 12.57 ng/mL. No evidence of bleeding diathesis was found, kidney and liver function tests were unremarkable. Increased density was observed in chest X-rays in base of both lungs on the new attack. In thoracic CT scan there were densities with ground glass appearance in both lungs which were more distinct in posterobasal levels right lung.

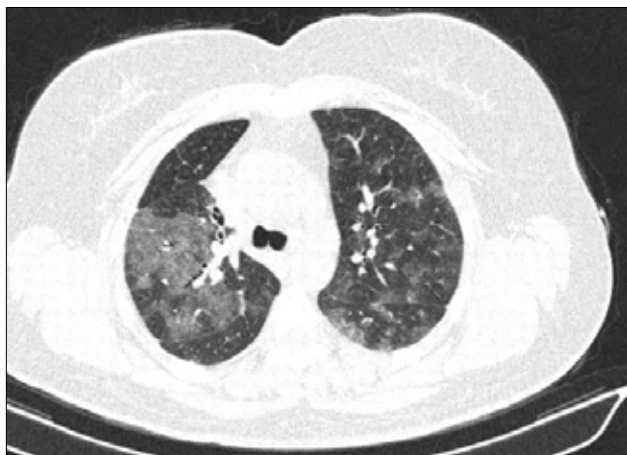


Figure 1. Thorax CT image

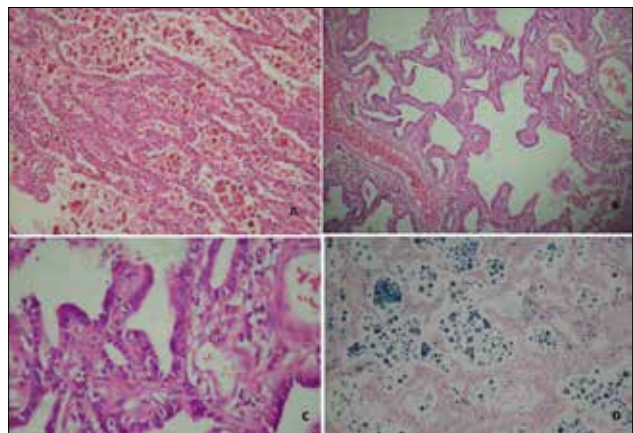


Figure 2. a; Dense iron-stored alveolar macrophages (x100; Pearl stain) Fig 2/b; Cystic spaces filled with cubic epithelium (x100; HE) Fig 2/c; Gaps in small cystic structure with cubic epithelium (400xHE) Fig 2/d; Dense Hemosiderine-loaded macrophages (x100; HE)

We got a biopsy decision. A Video Thoracoscopic Surgery (VATS) was performed, and any macroscopic problem wasn't detected to intraoperative observation. Before pleural and lung biopsy was performed on middle and lower lobes. Histological examination was performed as described elsewhere and confirmed the preoperative diagnosis of hybrid lesion (CCAM and IPH) (Figure 2).

Keywords: Congenital cystic adenomatoid malformation, idiopathic pulmonary hemosiderosis, videothoracoscopic surgery

[Abstract:0173] EPS-100 [Accepted: E-Poster] [Lung and Pleura Malignancies]

Bronchioloalveolar Carcinoma in Peutz-Jeghers Syndrome: Case Report

Burcu Yormaz, Baykal Tülek, Mecit Süerdem

Department of Chest Diseases, Selçuk University School of Medicine, Konya, Turkey

Peutz-Jeghers syndrome (PJS) is an autosomal dominantly inherited disease characterized by intestinal hamartomatous polyps and mucocutaneous pigmentation in association with serine-threonine kinase number 11 (STK11) mutation. The incidence of the syndrome is estimated to be a person between 50 and 200 thousand people. A 48-year-old male patient was admitted to our clinic with the complaints of a cough and white foamy phlegm. His history included 28 pack/year smoking. He had suffered from abdominal pain started in childhood. He had undergone colon polypectomy operations four times in total. His mother also had pigmented lesions on the perioral area. His daughter and his son underwent polypectomy operations with the diagnosis of PJS. In the thorax tomography, consolidated areas containing air bronchograms were observed in the right upper lobe posterior and middle lobe lateral segment, and patchy frosted glass areas in both lungs, which was more obvious on the right, nodular lesion of 17x14 mm in the left upper lobe, and common micronodules were observed (Figure 1, 2). Positron Emission Tomography (PET) examination revealed a hyper-metabolic mass lesion in the right upper lobe posterior segment. The patient underwent fiberoptic bronchoscopy for diagnostic purposes. Bronchoscopy revealed a tumorous lesion in the mucosa in the right upper lobe anterior segment separation carina, and biopsy was conducted on this lesion. In addition, transbronchial lung biopsy was taken from the middle lobe lateral segment. According to the pathology results, bronchoalveolar carcinoma was reported. This case was also reported to be the first reported case of Peutz-Jeghers Syndrome, which is the first bronchoalveolar cancer in our country.

Keywords: Peutz-Jeghers syndrome, bronchoalveolar carcinoma, lung

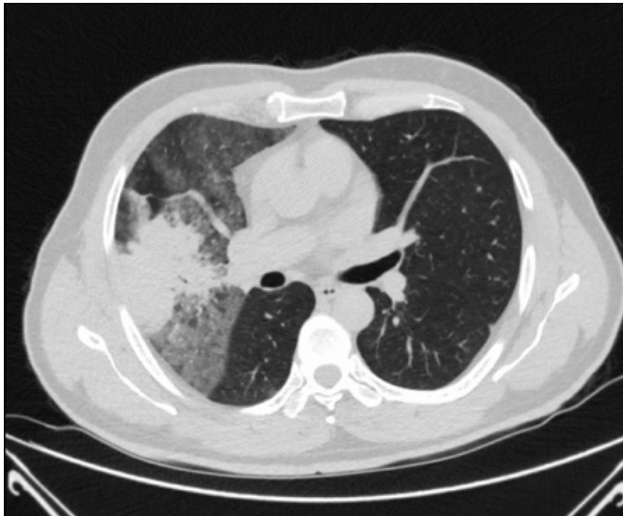

Figure 1. Computerize lung tomography

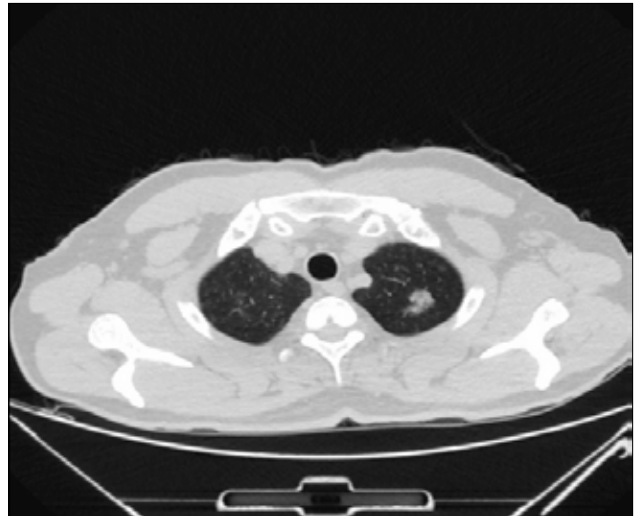


Figure 2. Computerize lung tomography

[Abstract:0177] PS-125 [Accepted:Poster Presentation] [Clinical Problems - Pulmonary Vascular Diseases]

A Case of Behçet's Disease That Presented with Atypical Findings and Underwent Surgical Treatment for Pulmonary Arterial Aneurysm and Massive Hemoptysis

Merve Atılğan Ala¹, Mehmet Sezai Taşbakan¹, Dursun Alizoroğlu², Hüsnü Pullukçu³, Figen Yargucu Zihni⁴, Şeyda Örs Kaya⁵

¹Department of Chest Diseases, Ege University, School of Medicine, İzmir, Turkey

²Clinic of Chest Diseases, Health Sciences University, Dr. Suat Seren Chest Diseases and Chest Surgery Training and Research Hospital, İzmir, Turkey

³Department of Infectious Diseases and Clinical Microbiology, Ege University, School of Medicine, İzmir, Turkey

⁴Department of Rheumatology, Ege University, School of Medicine, İzmir, Turkey

⁵Clinic of Chest Surgery, Health Sciences University, Dr. Suat Seren Chest Diseases and Chest Surgery Training and Research Hospital, İzmir, Turkey

Behçet's disease is a vasculitis that presents with recurrent oral and genital aphthae, ocular lesions such as uveitis, erythema nodosum, skin lesions such as papulopustular lesions, and positive pathergy phenomenon. The most common pulmonary involvement in Behçet's disease is arterial aneurysm. Pulmonary arterial aneurysm can lead to serious life-threatening hemoptysis as well as non-specific signs such as fever and perspiration. A 31-year-old female patient was admitted to our hospital due to the complaints of fatigue, fever, chills-shivering, and widespread muscle pain on February 2017. Because high-resolution computed tomography of the patient revealed consolidation area consistent with pneumonia, she was hospitalized in the clinic of infectious diseases and begun antibiotherapy. The factor causing infection, which would explain the reason for high fever, could not be found in the patient whose fever did not decrease despite antibiotherapy. No hematological or rheumatic pathology that could explain the cause of fever was detected in the examinations. Therefore, the patient was performed the whole-body CT with the prediagnosis of possible accompanying malignancy. In CT, the coexistence of bilateral chronic and acute thromboembolism, associated mosaic attenuation in the lung, and atelectatic changes were found. The patient was initiated anticoagulant therapy and she was examined in terms of predisposing causes of thrombosis. Prothrombin heterozygote, beta-fibrinogen heterozygote, and MTHFR homozygote mutation were detected. The patient was begun rivaroxaban therapy based on these findings and she was discharged with rivaroxaban therapy. Because her chest pain recurred in the follow-up, she was admitted again. Thoracic CT revealed findings that were consistent with newly occurring embolism and infarction area. In the cardiac MRI that was ordered for pulmonary thromboembolism, thrombus was found in the right ventricle. Irregularities consistent with chronic thromboembolism in the bilateral pulmonary arterial branches and parenchymal changes were also detected. The patient was consulted to the department of hematology and her anticoagulant therapy was switched to warfarin. She was discharged with warfarin therapy. The patient consulted to an external education and research hospital (ERH) due to massive hemoptysis on May 2017. In the thoracic CT performed there, pulmonary arterial aneurysm was found and the patient was referred to our department with the prediagnosis of Behçet's disease. In our clinic, she was consulted to the department of rheumatology again. She was begun immunosuppressive agents of methylprednisolone and cyclophosphamide due to the diagnosis of Behçet's disease. Then, the patient was discharged with the follow-up by the outpatient clinic of rheumatology. The patient was admitted to an external ERH due to massive hemoptysis on December 2017 and she was intubated and followed in the intensive care unit. Because her hemoptysis could not be taken under control, she was performed right lower lobectomy and pulmonary arterial aneurysm resection. Her pathology result was reported as thromboangiitis + aneurysm + intraparenchymal hemorrhage + congestion and lung involvement of Behçet's disease. Her hemoptysis was taken under control and she was discharged with full recovery. In our case, clinical findings of Behçet's disease were not observed at the time of first admission to the hospital. The diagnosis was established with the development of massive hemoptysis and pulmonary arterial aneurysm in the follow-up. It is suggested that Behçet's disease should be kept in mind in patients with fever of unknown origin and recurrent pulmonary thromboembolism although they do not have clinical findings at admission.

Keywords: Behçet's disease, pulmonary arterial aneurysm, pulmonary thromboembolism

[Abstract:0178] PS-066 [Accepted:Poster Presentation] [Thoracic Surgery]

Two Cases of Tracheal Hamartoma

Hakan Keskin, Levent Dertsiz, Sermin Tayfun, Makbule Ergin

Department of Chest Surgery, Akdeniz University, School of Medicine, Antalya, Turkey

Introduction: Although pulmonary hamartomas are the most common benign tumors of the lung, endobronchial hamartomas constitute only 1,4% of all hamartomas. They histologically consist of cartilage, fat, bone, and connective tissues and smooth muscle cells. We presented two cases because of their rarity.

Case 1: A 77-year-old male patient had a complaint of cough lasting for 3 months. Thoracic computed tomography revealed a lesion just in the proximal region of the right main bronchus in the trachea. The patient was firstly performed flexible bronchoscopy, but sample could not be taken due to the risk of bleeding. Rigid bronchoscopy under mask anesthesia was carried out. The lesion detected in the trachea was mechanically resected with the help of forceps.

Case 2: A 61-year-old male patient consulted to the hospital due to the complaint of fatigue. Because a vegetative mass was found in 3 cm above the carina in the thoracic tomography, flexible bronchoscopy was performed, but biopsy could not be taken due to the risk of bleeding. The patient was performed rigid bronchoscopy under general anesthesia and the mass was totally excised.

Results: Endobronchial hamartomas are slowly progressing neoplasias without malignancy potential. Besides that, they can even cause death due to airway obstruction depending on their localizations.

The most frequent symptoms include cough, dyspnea, and wheezing. Moreover, the incidence of these tumors is low and it is difficult to diagnose them through imaging techniques because of their being rare. These patients are generally followed up with some diagnoses such as chronic bronchitis, asthma, and other obstructive lung diseases. Due to the inflamed surface of hamartoma, bronchoscopic appearance cannot be differentiated from bronchogenic carcinoma. However, these tumors demonstrate high contrast enhancement in thoracic tomography because there is a little fat tissue in the lesion. The diagnosis will be easier if hamartoma is kept in mind in the presence of endobronchial lesions. The treatment method of benign tracheal tumors varies depending on the size and localization of tumor. More conservative treatments such as laser or endoscopic resection are recommended for benign tracheal lesions.

Conclusion: Although hamartoma is a benign tumor, it can lead to death by causing airway obstruction depending on its localization. Despite its being rare and difficulty in diagnosis, it can be easily diagnosed and treated if it is kept in mind.

Keywords: Benign, hamartoma, trachea, tumor

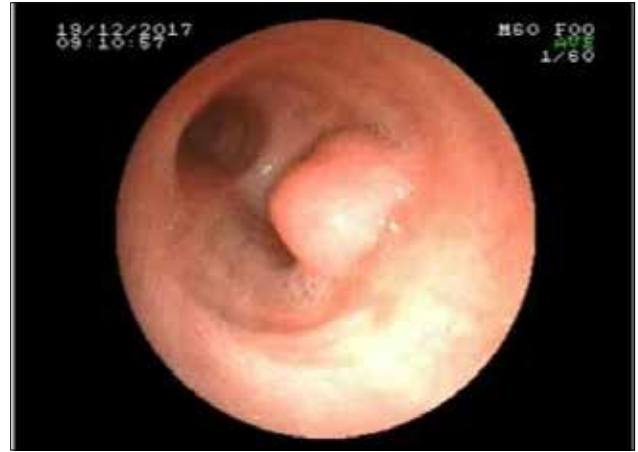

Figure 1. View of hamartoma through fiberoptic bronchoscopy

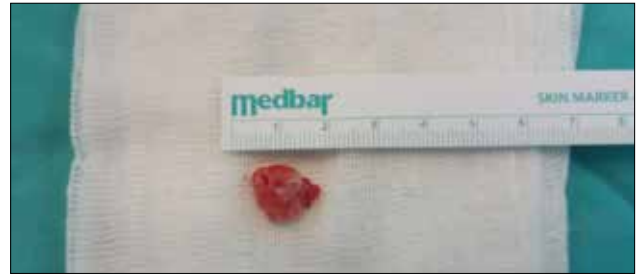

Figure 2. Macroscopic view of hamartoma removed with rigid bronchoscopy

[Abstract:0179] EPS-159 [Accepted: E-Poster] [Respiratory Infections]

Inhaler Antibiotic Treatment for Pseudomonas Aeruginosa Eradication in Adult Noncystic Fibrosis Bronchiectasis

Serir Özkan, Merve Ayık Türk, Derlen Özgeç, Türkan Dizdar, İhsan Topaloğlu, Mehmet Gülpek

Dr. Suat Seren Chest Diseases and Surgery Training and Research Hospital, İzmir, Turkey

In adult noncystic fibrosis bronchiectasis (NCFB) patients with chronic bronchial infection with Pseudomonas aeruginosa, exacerbations and hospitalization rates increase, lung function decreases rapidly and quality of life deteriorates. Therefore, early treatment of these patients with inhaled antibiotics and Pseudomonas aeruginosa eradication therapy is recommended. Recommended inhaler antibiotics are tobramycin, colistin and gentamicin.

Pseudomonas aeruginosa eradication therapy was done in 77 years old male patient with NCFB and chronic bronchial infection. The patient was admitted to our emergency department with complaints of cough, hemoptysis, yellow sputum, high fever, fatigue and loss of appetite on 12 August 2017 and has been diagnosed with bronchiectasis and rhinosinusitis since 2002. Seftazidim and ciprofloxacin treatment, which detected susceptible *Pseudomonas aeruginosa* in, were applied to sputum cultured *Pseudomonas aeruginosa*. On the eighth day, the patient was discharged with improved clinical signs of infection and ciprofloxacin treatment was completed in 14 days. Later, the number of leukocytes was increased to 14,000 and CRP: 12.34 mg/dL in patients who had 2 more hospital admissions due to fever, cough, green sputum, weakness, impatience. *Pseudomonas aeruginosa* was isolated 4 times in sputum in spite of the antibiotic use at appropriate dose and duration at every 3 hospitalizations. *Pseudomonas aeruginosa* isolation was detected once in sputum culture in 2015 when the patient's previous laboratory investigations were evaluated.

The patient received initial antibiotic p.o followed by 3 months of nebulization tobramycin as 2x300mg/5mL. After the initiation of this procedure, there was no further hospital admission, and significant improvement was achieved in the pulmonary and systemic clinical findings of the patient. Inhalation antibiotics are well tolerated. Nephrotoxicity, ototoxicity, or other adverse events were not detected. At the end of the second month of treatment, *Pseudomonas aeruginosa* was not produced in sputum for the first time. CRP 1.42 and leukocyte levels are within normal limits and clinical, laboratory and radiological follow-up of the patient is ongoing.

Keywords: Inhaler antibiotic treatment, noncystic bronchiectasis, *Pseudomonas aeruginosa*

[Abstract:0185] PS-139 [Accepted:Poster Presentation] [Clinical Problems - Pulmonary Vascular Diseases]

Ulcerative Colitis Case Complicated with Pulmonary Thromboembolism

Hasan Hasanzade¹, Murat Törüner², Demet Karnak¹

¹Department of Pulmonology, Ankara University School of Medicine, Ankara, Turkey

²Department of Gastroenterology, Ankara University School of Medicine, Ankara, Turkey

Introduction: Venous thromboembolism in patients with inflammatory bowel disease is an important cause effecting the morbidity and mortality of the disease. Thromboembolic event risk is 3-4 times higher than the general population in these cases. Thromboembolism incidence is 1-6% in ulcerative colitis patients and cerebral, portal vein, retinal vein and arterial thrombosis may be observed whereas deep vein thrombosis (DVT) and pulmonary thromboembolism are more common. Coagulation anomalies and hypercoagulopathy are considered to be responsible in etiopathogenesis. In fact, we present this case so that it may be helpful for the difficult therapy consideration along with a chest physician keep in mind this entity in daily practice which full of sign consultation safe of Gastroenterology clinics.

Case Presentation: A 40-year-old male patient referred with coughing and pleuritic chest pain complaints. He was diagnosed as ulcerative colitis two months ago and taking mesalazine 2000 mg and azathioprine 100 mg for treatment. It was learned that he referred to the emergency service with right backpain complaint a week ago which was relieved with analgesics. There were scattered backpain pneumonic and lineas opacities in the chest radiography (Figure 1). Acute thromboembolism in medium lobar and segmentary, upper

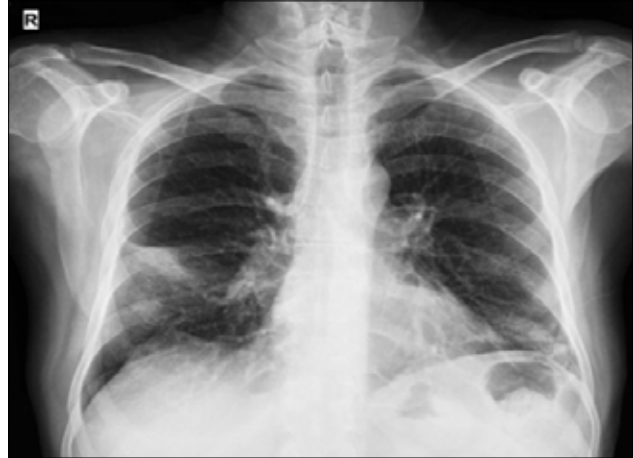

Figure 1. Lineas opacities in the chest radiography

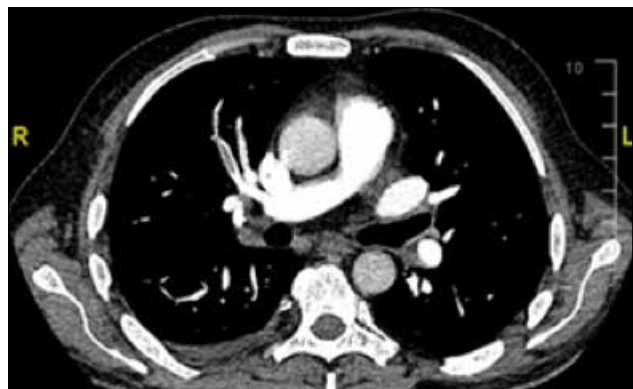


Figure 2. Medium lobar and segmentary, upper lobe anterior and lower lobe segmental pulmonary artery branches related changes.

lobe anterior and lower lobe segmental pulmonary artery branches and pulmonary infarct-related changes with pleura-leaning base in medium lobe were observed in this computed pulmonary angiography (Figure 2, 3). Thrombosis finding was not detected in both lower extremities. Low molecule weight heparin (LMWH), (enoxaparine) treatment was initiated at the dose of 2*0.4 mL subcutaneously. Immunological markers and antiphospholipid antibodies were negative. Factor V Leiden and Prothrombin gene mutation was negative and MTHFR gene mutation result was detected as heterozygote. The patient was discharged with an anticoagulant treatment planning to last three months.

Discussion: Consideration of pulmonary thromboembolism treatment in this type of cases is related to the expected gastrointestinal bleeding risk. Inferior vena cava filter can be advocated especially in a period with high bleeding risk and deep vein thrombosis in active ulcerative colitis patients. In this case, it not necessary in this case since DVT was not detected. Anticoagulant treatment is delayed until the bleeding is under control. No bleeding or activation with LMWH was observed in this case. So although bleeding risk can be seen in such patients, in case of thromboembolism, LMWH can be of threatment in case follow up.

Keywords: Ulcerative colitis, thromboembolism, anticoagulant

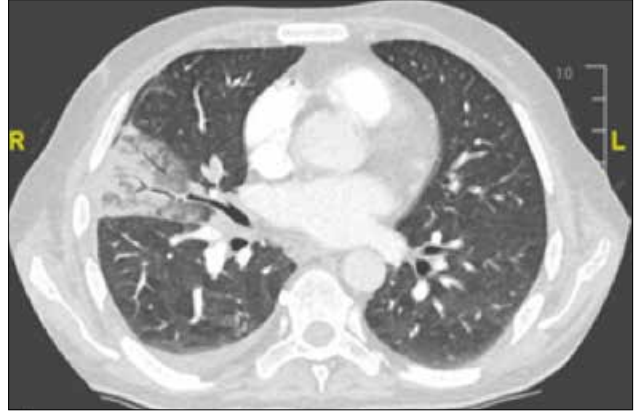

Figure 3. Pulmonary infarct related changes in medium lob

[Abstract:0188] EPS-300 [Accepted: E-Poster] [Tuberculosis]

Two Parenchymal Pulmonary Tuberculosis Cases Diagnosed With Bronchoalveolar Lavage

Bünyamin Sertoğullarından¹, Niyazi Can Ertürk²

¹Department of Chest Diseases, İzmir Katip Çelebi University, İzmir, Turkey

²Clinic of Chest Diseases, İzmir Atatürk Training and Research Hospital, İzmir, Turkey

Introduction: The establishment of diagnosis in cases with suspicious tuberculosis is very important for patient and public health and it is our, the physicians, responsibility. Low bacillary load causes diagnostic difficulty in patients with small parenchymal pulmonary lesion. In this case presentation, we wanted to share two patients who were suspected to have tuberculosis and whose sputum culture could not be taken but diagnosis was established with bronchoalveolar lavage sample and liquid medium.

Case 1: A 27-year-old female patient without any known comorbidity was admitted due to the complaints of cough and accompanying hemoptysis lasting for 3 days. It was learned from her anamnesis that she had excessive sweating causing her to change her undershirt for 2-3 times in a night for the last 1-2 months and apparent weight loss in the last one year. Her father had a history of drug use for tuberculosis. In her thoracic computed tomography (CT), tree-in-bud pattern was detected in the upper lobe of the left lung (Picture). She was performed fiberoptic bronchoscopy (FOB) -guided bronchoalveolar lavage (BAL). ARB was not detected in direct smear. The level of PCR TBC DNA was very lowly positive. While no growth was observed in solid medium in the analysis of culture, growth was found in fluid culture. The patient whose treatment was begun displayed clinical and radiological regression.

Case 2: A 46-year-old female patient without any known comorbidity consulted to our outpatient clinic due to the complaints of cough and vomiting blood approximately at an amount of one tea glass in a day, which were going on for 2

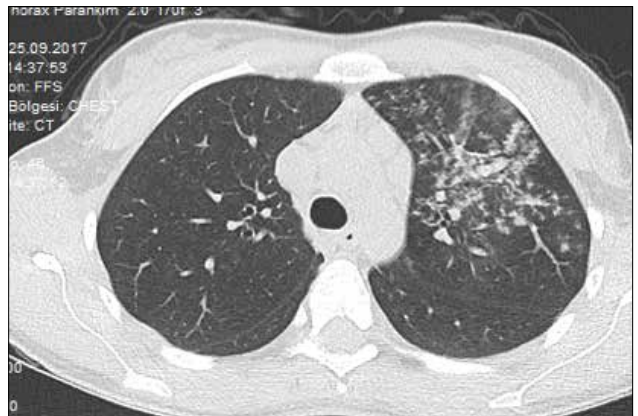

Figure 1. View of tree-in-bud on the left upper section of CT

weeks. Upon the normal findings of endoscopy performed in an external center, she consulted to us. The results of sputum smear and culture, which were taken due to the detection of a cavitory lesion in the right apex in her thoracic computed tomography previously performed in the other center, were found to be negative. In the bronchoalveolar lavage (BAL) fluid sampling that was performed in our clinic, no ARB was detected in direct smear. In BAL sampling, TBC DNA was lowly positive. In her mycobacteria culture, the analysis of which was completed 4 weeks later, 'mycobacterium tuberculosis' growth was observed. The patient, whose treatment was arranged, was referred to the tuberculosis control dispensary.

Conclusion: In cases with the suspicion of tuberculosis and in patients having small parenchymal lesion, who have been found to have negative result of sputum smear and culture or whose sputum sample cannot be taken, taking BAL fluid sample and cultivating them in solid and fluid mediums should not be forgotten in order to avoid false negative results.

Keywords: Tuberculosis, parenchymal lesion, BAL

[Abstract:0189] PS-205 [Accepted:Poster Presentation] [Asthma and Allergy]

The Frequency of Asthma-COPD Overlap (ACO) among Asthma Patients

Nurgül Sevimli¹, Dilek Yapar², Haluk Şaban Türkteş¹

¹Department of Pulmonary Disease, Gazi University School of Medicine, Ankara, Turkey

²Department of Public Health, Gazi University School of Medicine, Ankara, Turkey

Objectives: Asthma and chronic obstructive pulmonary disease (COPD) are obstructive pulmonary diseases characterized by airflow limitation. Both diseases have their own clinical and laboratory findings. Besides, there is a subgroup defined as the Asthma-COPD Overlap (ACO) which has clinical and functional features of both diseases, and there are challenges in the diagnosis of ACO. However, in our country, there is limited data about ACO. Therefore, the aims of this study were to determine the frequency of ACO among asthma patients, to compare general clinical characteristics of ACO patients with asthma patients and to determine threshold values for the diagnosis of ACO.

Methods: A total of 2742 asthma patients who were followed in the outpatient clinic of Gazi University Medical School, Department of Chest Diseases were screened. The study group comprised 338 patients who admitted between 2010 and 2017 years, and had at least 3 pulmonary function tests within the last two years. Having diagnosed the patients with ACO and asthma according to the Global Initiative for Asthma guidelines (over 40 years of age, smoking history of more than 10 pack/year or biomass exposure, with at least three features of both asthma and COPD, with reversible and persian airflow limitation) were included.

Results: The frequency of ACOS among 338 asthma patients was found to be 11.8% (N=40). ACO patients were older, had higher body mass index, higher Charlson comorbidity index, fewer allergic comorbidities, worse spirometric parameters, and required higher doses of inhaler corticosteroids compared to the asthma patients (all for $p < 0.05$). No significance differences were observed between the groups regarding the survey, number of hospitalization and attacks, symptoms at diagnosis, physical examination findings, skin prick test positivity, posterior-anterior chest radiograph findings, Immunoglobulin E level, eosinophil count and percentage (all for $p > 0.05$). Being older than 57.5 years of age, smoking more than 14 pack/year, and over the age of 40.5 years for the disease onset were determined as the threshold values. Having the three criterias made the probability of ACOS diagnosis was 12.54 (5.88-26.73) times more (OR=12.54, 95% CI, $p = 0.001$).

Conclusion: In the light of our results, it was observed that the frequency of ACO is very high in asthmatic patients. When the patient is older than 57.5 years of age, has smoking history more than 14.5 packs/year, and the diagnosis of asthma established over 40.5 years of age, the probability of ACO diagnosis increases.

Keywords: Asthma, asthma-COPD overlap, diagnosis, risk factors

[Abstract:0190] EPS-137 [Accepted: E-Poster] [Pulmonary Pathology]

Nüx Breast Cancer with Chylothorax

Emine Özsarı, Suat Konuk, Elif Açar, Tuncer Tuğ

Department of Chest Diseases, Abant İzzet Baysal University School of Medicine, Bolu, Turkey

The accumulation of lymphatic fluid in the pleural space is a result of the deterioration of integrity of the lymphatic channel. Traumatic or non-traumatic causes can cause it. Lymphomas is almost the first reason about non-traumatic etiologic factors in neoplasms. Other reasons like chronic diseases such as sarcoidosis, tuberculosis and histoplasmosis may cause chylothorax. Malignant pleural effusions, are the second ones among causes of exudative pleural effusion after infections. Lung cancer (30%), breast cancer (25%) and lymphomas (20%) constitute approximately 75% of malignant pleural effusions. Recurrent breast cancer with both malignant effusion and chylothorax is prepared in the context of literature information.

Keywords: Breast Cancer, chylothorax, metastasis, malignant pleural effusions

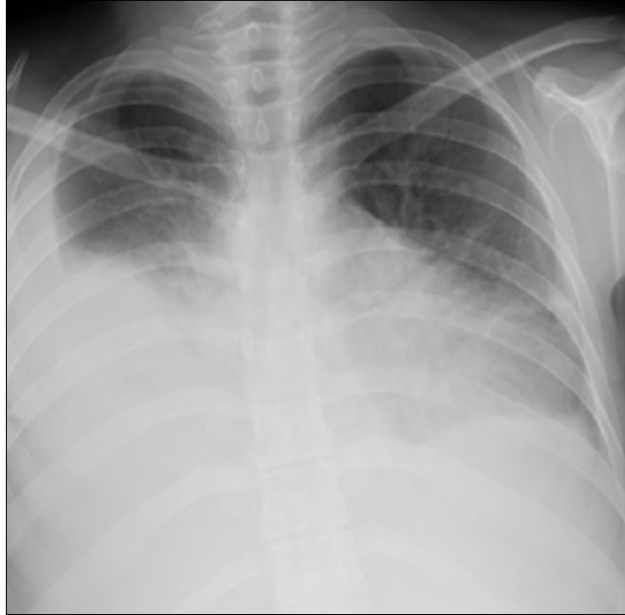


Figure 1. Posteroanterior chest X-ray at diagnosis

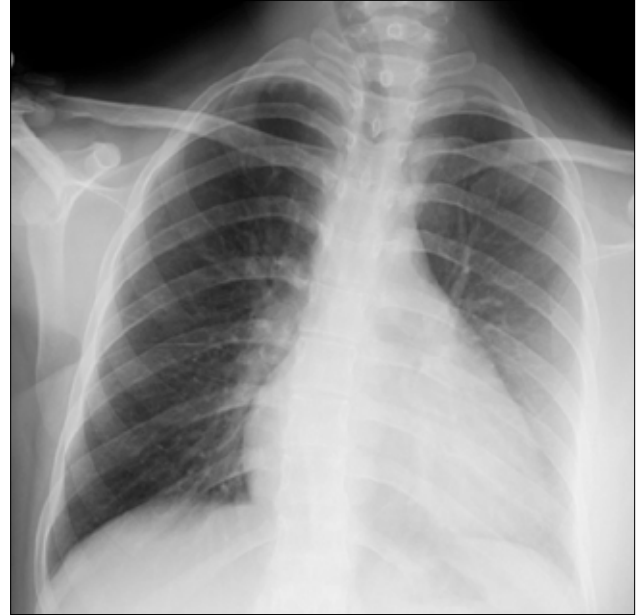


Figure 2. Posteroanterior chest X-ray after torasentesis

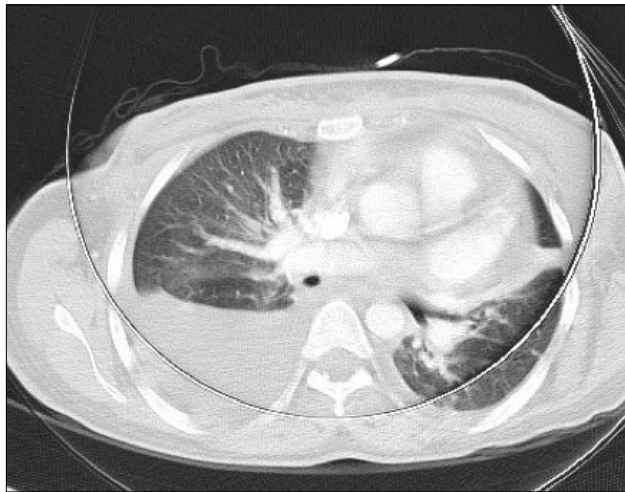


Figure 3. Torax CT in the diagnosis

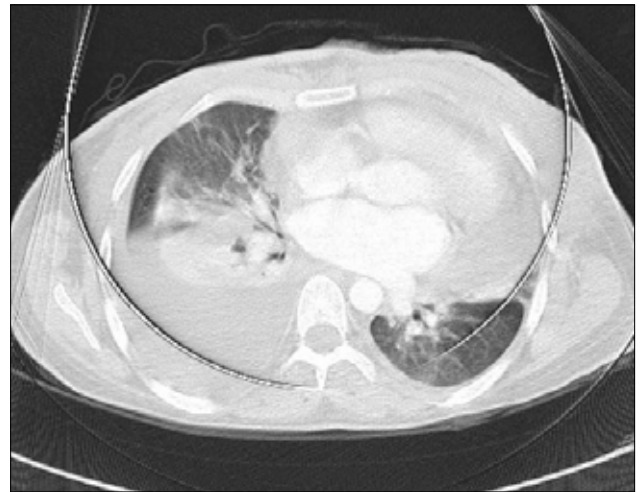


Figure 4. Thorax CT in diagnosis

[Abstract:0191] EPS-039 [Accepted: E-Poster] [Clinical Problems - Pulmonary Vascular Diseases]

Association Syndrome of Vena Cava Superior and Nontrombotic Pulmonary Embolism

Deniz Doğan, Cantürk Taşçı

Clinic of Pulmonary Diseases, Health Sciences University, Gülhane Training and Research Hospital, Ankara, Turkey

Introduction: Syndrome of vena cava superior (SVCS) is a perspective that due to the obstruction of blood flow in the superior vena cava. Frequent malignancies, especially lung cancers, appear to be a complication resulting in compression and/or invasion of the underlying malignancy. Especially in recent years there has been an increase in the number of non-malignant SVCS cases due to the increased use of central port catheters and pace-makers. Pulmonary tumor embolism is considered to be a subtype of NTPE and is rarely occurred. This condition, which is usually difficult to diagnose, develops as a result of tumor tissue infiltrating the venous structures and becoming free and reaching pulmonary circulation.

Case Presentation: A 59-year-old male patient with stage IV non-small cell lung cancer was referred to the Medical Oncology clinic for treatment and follow-up. He was admitted to our polyclinic with the complaint of shortness of breath that started suddenly in the second month of chemotherapy treatment. Vital findings of the patient; Temperature: 36.4°C, Pulse: 124 / min, BP: 107/85 mmHg, SpO2: 92% (in room air) and respiration rate was 24/min. On physical examination,

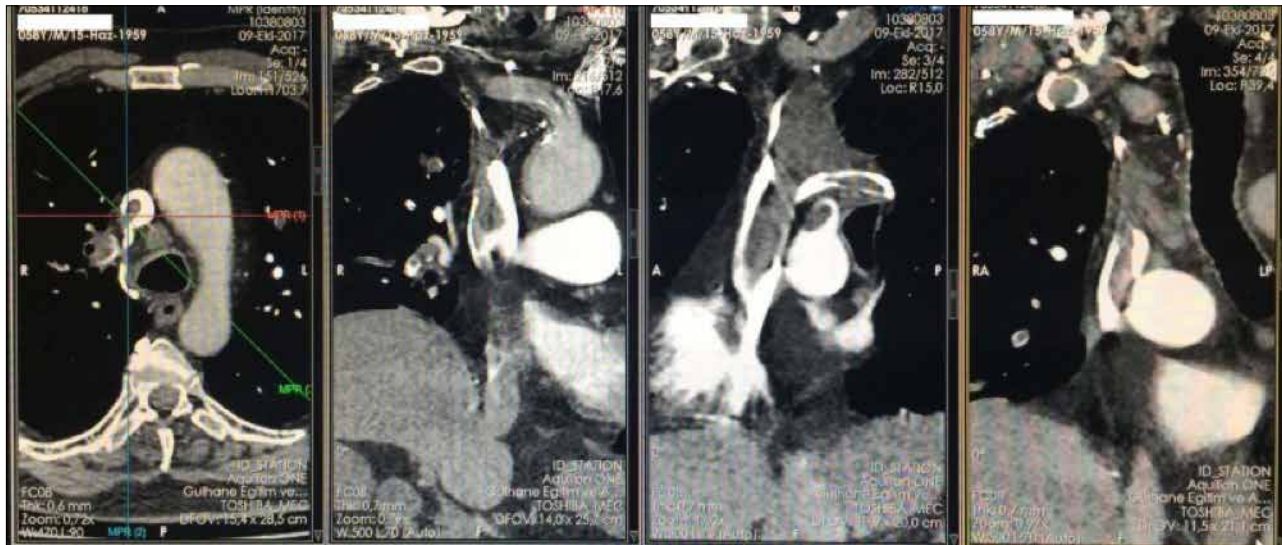


Figure 1. CT-Anjiography/MPR figures. SVC is infiltrated with tumor and visualized tumor tissue progresses to the right atrium level.

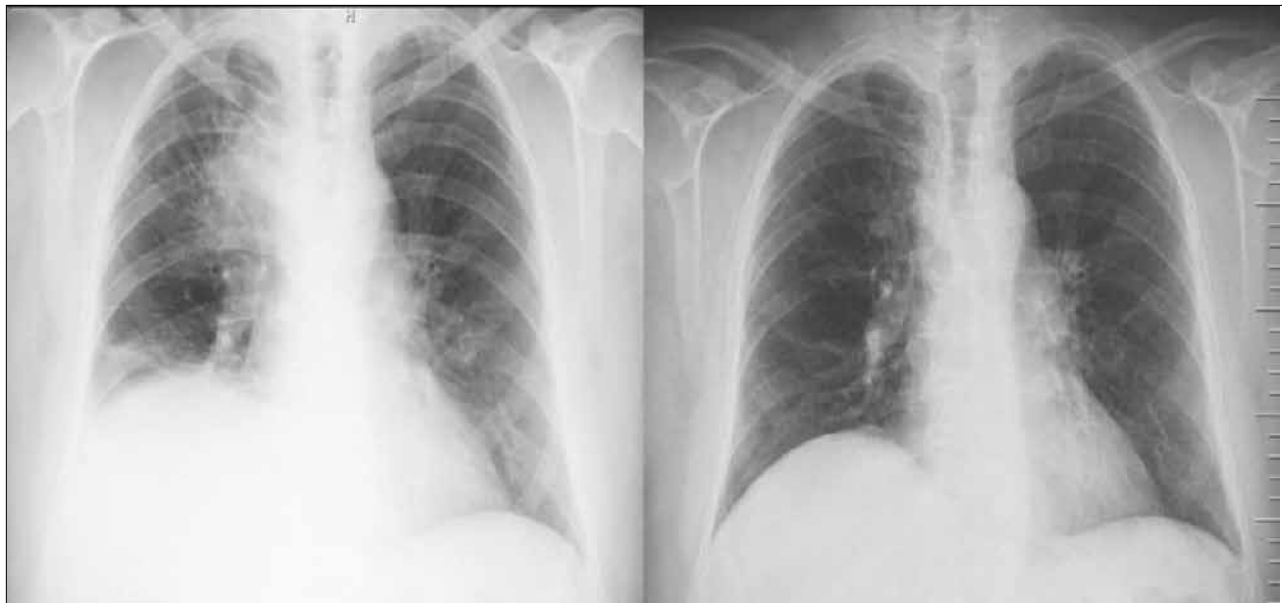

Figure 2. Before and after treatment pa lung graphy.

Significant radiological regression was observed at 2 months of treatment with chemotherapy

the right side of the neck and the upper hemithorax skin subcutaneous venous structures became more prominent and thicker on the fingers. Significant regression was observed on PA chest X-ray compared to before treatment (Figure 1). Clinically, the D-Dimer level of the patient with moderate probability of PE was 17-fold higher. In CT angiography examination, embolism-compatible filling defect areas were observed in both pulmonary arteries. At the same time, it was observed that the vena cava superior was infiltrated by the tumor and the tumor tissue progressed to the right atrium (Figure 2). Patients with normal hemodynamics were hospitalized and low molecular weight heparin at enoxaparin 1 mg/kg/12 hour dose was started.

Conclusion: The incidence of pulmonary tumor embolism in solid tumors has been reported to be between 0.19% and 0.27%. The association of SVCS and NTPE due to lung cancer is a rare clinical condition. In this case, a tumor complication was detected which could lead to sudden death, although radiologically the treatment response was very good. We aimed to present this case as an interesting case that can be rarely encountered in clinical practice, which is an association of SVCS and NTPE due to lung cancer. We also discussed our case as a review in the literature.

Keywords: Pulmonary tumor embolism, lung cancer, syndrome of vena cava superior

[Abstract:0195] EPS-027 [Accepted: E-Poster] [Clinical Problems - Diffuse Parenchymal Lung Disease]

Case of Massive Pulmonary Embolism Mimicking Diffuse Alveolar Hemorrhage

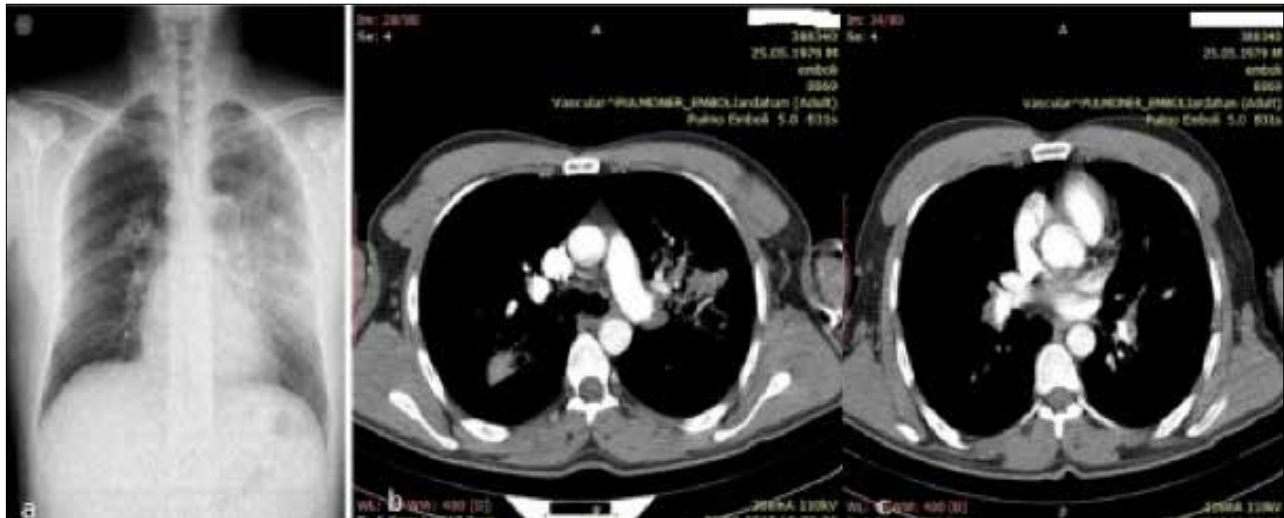

Figure 1. Views of chest radiography and computed tomography mediastinal window

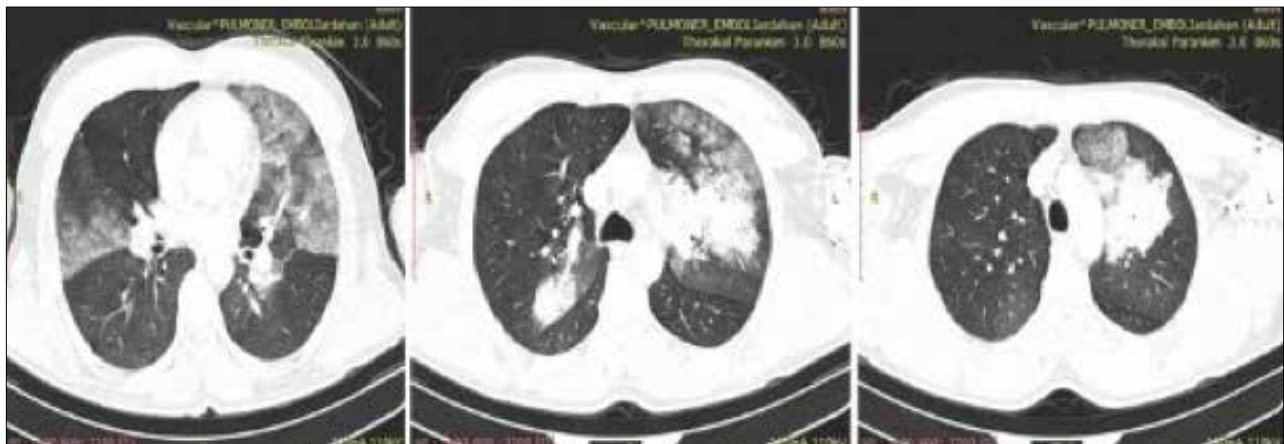

Figure 2. Computed tomography parenchymal window of the case

Selvi Aşker, İbrahim Halil Üney, Ayşegül Demirbaş, Nevzat Esen, Maşuk Çelikel

Department of Chest Diseases, Van Yüzüncü Yıl University, School of Medicine, Van, Turkey

Introduction: Alveolar hemorrhage syndromes (AHS) include a group of heterogeneous diseases that cause dyspnea, hemoptysis, anemia, and bilateral alveolar consolidations in the chest radiography as a result of diffuse hemorrhage in the alveolar spaces due to destruction in the alveolar septa. While the most common cause of AH is of autoimmune origin in patients with normal immunity, it is underlying infection or pulmonary damage in patients with normal immunity. In the cases of diffuse lung lesions accompanied by anemia, alveolar hemorrhage should be remembered firstly, particularly if the patient is young. Sometimes, hemoptysis is not observed in these diseases. The rate of hemoptysis in pulmonary embolisms was reported to be 13% in the PIOPED study. In this study, it was aimed to present a patient who was diagnosed with pulmonary embolism, but whose radiology result was similar to diffuse alveolar hemorrhage and who had anemia.

Case: A 38-year-old male patient consulted to the emergency unit due to the complaints of chest pain and blood from the mouth. The patient had no known disease and his HB value was measured as 10 g/dl. His O₂ saturation was 86% and the chest radiography revealed expanded hili and diffuse infiltration in both lungs (Figure 1a). Computed tomography angiography was performed and thrombus was detected in both main pulmonary arteries (Figure 1b, c). Diffuse ground-glass densities suggesting DAH and displaying geographic distribution in both lungs were found in the parenchymal window (Figure 2 a-c). The patient, who had right heart failure in the echocardiography, was accepted to have submassive embolism and he was followed up with standard heparin treatment. Because hypotension developed on the 3rd day of his hospitalization, half-dose thrombolytic was administered. No pathology was detected in the patient, who was examined in terms of all rheumatoid diseases, infections, cardiac pathologies, interstitial lung diseases, and malignancy. The patient, whose hemoglobin value was not decreased and oxygenation was improved, was discharged on the 10th day of the treatment to be followed up with low-molecular-weight heparin.

In pulmonary embolism patients with hemoptysis, decreased hemoglobin is not an expected condition. In our patient, parenchymal infiltration and decreased Hb suggested comorbid diseases causing DAH. The patient benefited from thrombolytic therapy without any complication. Non-development of complication might be associated with the absence of a comorbid disease. In such patients, profit-loss rate should be calculated and the most effective treatment for patient should be selected.

Keywords: Pulmonary embolism, hemoptysis, lung damage

[Abstract:0201] PS-162 [Accepted:Poster Presentation] [Tuberculosis]

Evaluation of Pregnant Women with Multi-Drug Resistant Tuberculosis

Begüm Oğur¹, Aylin Babalık¹, Fatma Kutluhan¹, Merve Karaman¹, Ayşe Rümeyza Hazine¹, Kaya Köksalan²

¹Health Sciences University, İstanbul Süeryyapaşa Chest Diseases And Thoracic Surgery Training And Research Hospital, İstanbul, Turkey

²İstanbul University Aziz Sançar Experimental Research Institute, İstanbul, Turkey

Objectives: There is a delay in the diagnosis of tuberculosis in pregnancies. Delays and difficulties are experienced at the beginning of effective and appropriate treatment of tuberculosis disease in pregnancies.

Methods: We detected a smear-positive pulmonary tuberculosis and we had a 6-month pregnancy; pregnancy and all risks were assessed and treated because of the presence of resistant TB.

Results: 31-year-old, 6 months pregnant Georgian patient had complaints of cough and sputum production. 1 year ago she used first and second line medications and TB therapy irregularly, for the last 6 months, the patient who did not receive any TB treatment was interned to continue the examination and treatment. Sputum ARB sample was positive of the patient and RIF resistance was detected in the resistance test of the DATAE laboratory. A consultation on the gynecology was requested and the patient was informed about the side effects that could be related to the baby and itself. Informed consent form was taken from her and baby's father. According to TULSA results, isoniazid, rifampicin, ethionamide resistance was detected. EMB, PZA, Etionamide, Kanamycin, Moxifloxacin, Cycloserine and PAS were detected as susceptible. After informed consent form resistant tuberculosis treatment started as Moxifloxacin 400 mg, Cycloserine 750 mg, Protionamid 750 mg, Ethambutol 1500 mg, Linezolid 600 mg, Clofazamine 200 mg. B6 vitamins and folic acid were also added to the treatment. Parenteral drugs (amikacin, capreomycin) in the direction of the WHO 2016 guideline were not given due to the taking of the Group

D drugs category. Gynecologic and obstetric consultations were also held regularly every week. Patient was transferred to the gynecologic clinic for the caesarean section and she was taken to the tuberculosis clinic after C-section. The examination of the baby was done by pediatricians and it was evaluated as healthy. Patient's sputum smear was negative at 5th month of treatment, culture was negative at 6th month. The duration of treatment was planned to be 18 months after culture negative.

Result: In pregnancy, active disease should be treated effectively with appropriate medications as soon as possible.

Keywords: Pregnancy, tuberculosis, multi-drug resistance

[Abstract:0204] PS-016 [Accepted:Poster Presentation] [Clinical Problems-Diffuse Parenchymal Lung Disease]

High-Flow Nasal Canule Oxygen Treatment Related Pneumothorax Case

Aydın Çiledağ, Dursun Baygül, Fatma Çiftçi, Serhat Erol, Banu Gülbay, Akin Kaya

Department of Pulmonary Diseases, Ankara University School of Medicine, Ankara, Turkey

High-flow nasal canule oxygen treatment is a supportive treatment which can be applied up to very high flows after oxygen heating and humidification operations and contributes to mortality in hypoxemic respiratory failure.

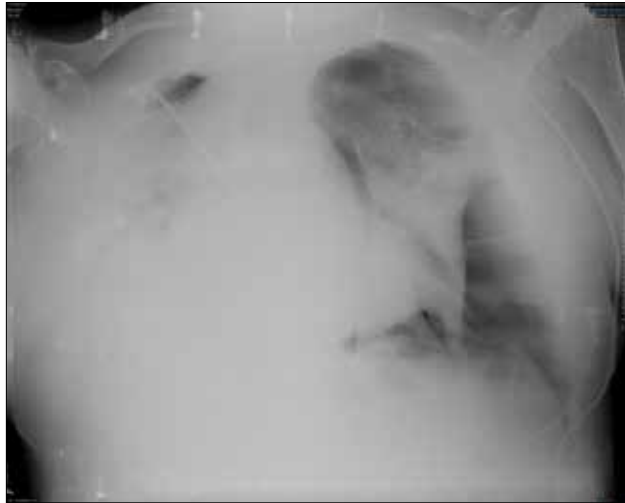


Figure 1. Chest X-ray: left sided pneumothorax

57 year-old-male patient who had a smoking story of 70 packages-year referred to the hospital with dyspnea and coughing complaints. Pirfenidone treatment was started after IPF diagnosis two years ago and he was registered in lung transplantation risk. He was taken to the intensive care unit due to severe hypoxemia during his follow-ups. In thorax computed tomography, honeycomb cysts were detected in all lobes in both lungs, especially in lower lobes and severe traction bronchiectasis secondary to fibrosis was also detected. The patient had pneumothorax story after non-invasive mechanical ventilation treatment during his previous hospitalization. Since satisfactory oxygenization couldn't be provided despite medical treatment and reservoir mask-aided oxygen support, high-flow nasal canule oxygen treatment was started at 34°C, 40-60 L/min. Pneumothorax was detected on the left in the lung graphy taken due to the sudden chest pain on the third day of treatment. Tube thoracostomy

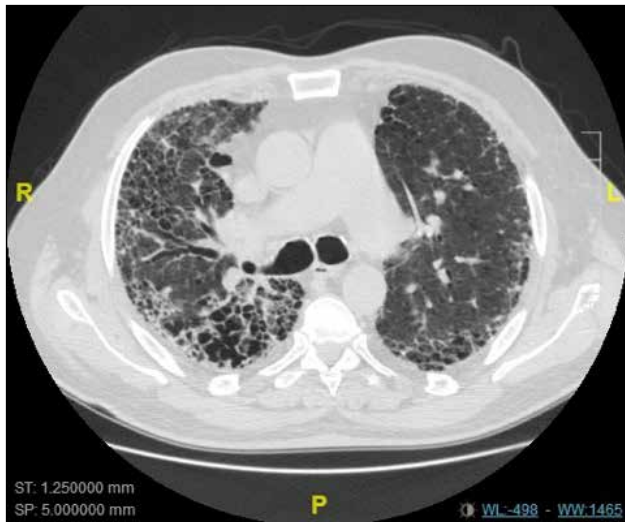


Figure 2. IPF

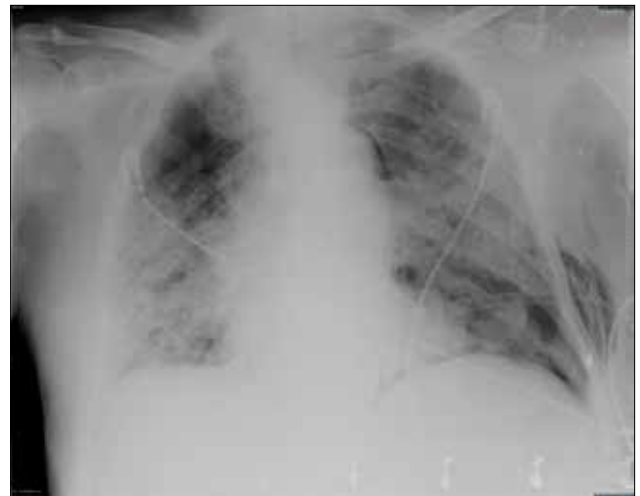

Figure 3. Left hemitorax expansion

was applied by pulmonary surgery department. Expansion was observed in control graphy. The patient who was intubated due to severe respiratory failure and followed up with invasive mechanical ventilation support died on the second day following intubation.

Expiratory positive pressure is formed in high-flow nasal canule oxygen treatment, even in low pressures. In recent years, this treatment is applied with an increasing rate in severe hypoxemic respiratory failure. In literature, a quite low number of pneumothorax cases due to high-flow nasal canule oxygen treatment were reported, generally in pediatric cases. So high-flow nasal canule oxygen treatment should be applied carefully and under control in patients with pneumothorax risk and the cases should be followed for pneumothorax.

Keywords: Flow, high, nasal, oxygen, pneumothorax

[Abstract:0205] EPS-125 [Accepted: E-Poster] [Pediatric Pulmonary Diseases]

One of Diagnoses that Should Be Considered in Patients with Cystic Fibrosis: Allergic Bronchopulmonary Aspergillosis

Gökçen Kartal Öztürk¹, Aykut Eşki¹, Sanem Eren Akarcan², Figen Gülen¹, Esen Demir¹

¹Department of Pediatrics, Division of Pediatric Chest Diseases, Ege University, School of Medicine, İzmir, Turkey

²Department of Pediatrics, Division of Pediatric Allergy, Ege University, School of Medicine, İzmir, Turkey

Introduction: Allergic bronchopulmonary aspergillosis (ABPA) is a hypersensitivity reaction associated with *Aspergillus fumigatus*, which can be encountered in cystic fibrosis (CF) patients at the rates of 2-15%. Despite the presence of some clinical, laboratory, and radiological criteria that would suggest the diagnosis, there are no specific markers for definite diagnosis and follow-up. In this study, we presented 3 ABPA cases whose diagnoses and follow-ups were different.

Case 1: A 14-year-old girl patient was admitted due to the complaints of cough and increased amount of sputum. In her examination, her weight was 3-10p, length was <3p, and SO_2 was 91%. Anterior-posterior diameter of the chest was increased and there were fine rales. White blood cell count was 15960 $10^3/\mu\text{l}$ and eosinophil level was 0.9%. Air trapping, bronchiectasis, and bilateral patchy infiltrations were observed in her graphs. In the respiratory function test (RFT), FVC was 34%, FEV_1 was 29%, FEV_1/FVC was 86%, PEF was 35%, and MEF 25-75 was 18%. The result of reversibility was positive. *Aspergillus* spp. growth was observed in the sputum culture. T.IgE was 1267 IU/mL and *Aspergillus*-splgE was 90.5 (+) kUA/l. *Aspergillus* sensitivity was detected in the skin prick test (SPT). Corticosteroid and itraconazole were initiated due to the diagnosis of ABPA. When an improvement occurred in her clinical and radiological condition and RFT (FEV_1 59%), steroid was decreased gradually and then stopped. Itraconazole therapy was continued for one more month.

Case 2: An 11-year-old girl patient was admitted due to the complaint of respiratory distress. It was learned from her anamnesis that she was begun steroid and itraconazole therapy in another center due to the diagnoses of CF and ABPA, but she did not use her drugs regularly and go for control examinations for 1.5 years. In the examination, her weight was 3-10p, length was <3p, respiratory rate was 25/min, and SO_2 was 93%, and there were fine rales. White blood cell count was 15630, eosinophil rate was 0.22%, CRP was 5.6 mg/dl, and sedimentation was 45 mm/hour. Air trapping, bronchiectasis, and patchy infiltrations were observed in her graphs. In RFT, FVC was found as 67%, FEV_1 as 58%, FEV_1/FVC as 86%, PEF as 57%, and MEF 25-75 as 70%. No reversibility was observed. *Staph. aureus* and *H.influenzae* non- type B was detected in sputum. Antibiotics therapy was begun. T.IgE was 353 IU/mL and *Aspergillus*-splgE was 17.5 4 (+) kUA/l. *Aspergillus* sensitivity was positive in SPT. Corticosteroid and itraconazole therapy was initiated with the diagnosis of ABPA. The dose of steroid was decreased with clinical improvement. In the control examination in the 2nd month, the dose of steroid was doubled because of fever, new infiltration in the graph, and increased T.IgE and *Aspergillus*-splgE.

Case 3: A 12-year-old boy patient consulted to our clinic because of his persistent fever despite antibiotics therapy that had been begun for the complaints of respiratory distress and fever. In his examination, his weight-length was <3p, anterior-posterior diameter of the chest was increased, and there were finger clubbing, fine rales, and rhonchus. White blood cell count was 13800, eosinophil rate was 2.83%, CRP was 7.68 mg/dl, and sedimentation was 84 mm/hour. Air trapping, bronchiectasis, and patchy infiltrations were observed in his graphs. In RFT, FVC was 35%, FEV_1 was 38%, FEV_1/FVC was 107%, PEF was 30%, and MEF 25-75 was 22%. No reversibility was observed. *C.glabrata* was detected in sputum and antibiotic therapy was begun. T.IgE was 1028 IU/mL and *Aspergillus*-splgE was 52.5 5 (+) kUA/l, and no *Aspergillus* sensitivity was observed in SPT. Corticosteroid and itraconazole were begun due to the diagnosis of ABPA. High-flow oxygen support was provided because of increased respiratory distress and carbon dioxide retention. His blood glucose and HbA1c levels were high; therefore, insulin was initiated. The patient, who was recovered with blood glucose regulation and ABPA therapy, was

weaned from ventilation support. Steroid was decreased and then discontinued because of clinical and radiological improvement and decreased T.IgE in his control. However, itraconazole was continued for one more month.

Keywords: Cystic fibrosis, allergic bronchopulmonary aspergillosis, aspergillus fumigatus

[Abstract:0208] EPS-056 [Accepted: E-Poster] [COPD]

Chronic Obstructive Pulmonary Disease due to Pulmonar Tuberculosis in a Military Personnel

İbrahim Koç

Viranşehir State Hospital, Şanlıurfa, Turkey

Chronic obstructive pulmonary disease (COPD) is an important public health problem which is associated with systemic inflammation. The main cause of COPD is tobacco smoking yet biomass exposure and many infections may be reasons. Tuberculosis is an infection caused by mycobacterium tuberculosis which mostly effects the lungs. A twenty years old military personnel was referred to our hospital with complaints of chest tightness and dyspnea during exercising. The patient was hospitalized for the further evaluation. His physical examination revealed normal body temperature (36 C°), heart rate of 80 beats per minute, respiratory rate of 17 breaths per minute, blood pressure of 110/80 mm Hg, and SpO₂ of 93% in room air which decreased to 85% after exercise. Physical examination of the chest revealed diminished respiratory sound on both hemithorax. When questioned his medical history revealed that he had suffered from pulmonary tuberculosis ten years ago. The patient was hospitalised. Post bronchodilatory forced expiratory volume on the first second (FEV₁) was 65 %.Computed tomography of the chest revealed left sided sequel lesion and bilateral emphysematous changes. There are many well known reasons for COPD but in a twenty years old military personnel its very rare case.

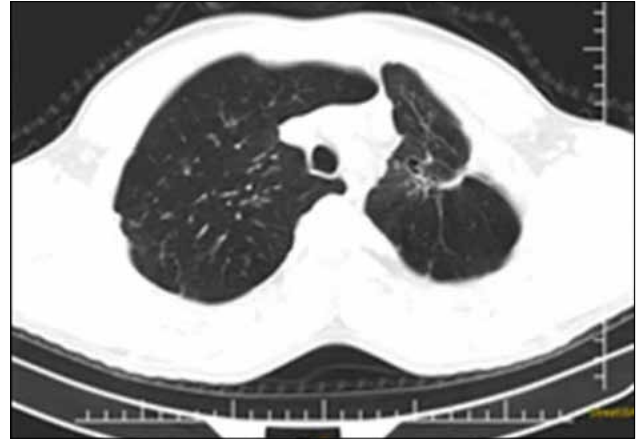


Figure 1. Computed tomography of the chest revealed left sided sequel lesion and bilateral emphysematous changes

Keywords: COPD, Pulmonary Tuberculosis, Military Personnel

[Abstract:0209] PS-170 [Accepted:Poster Presentation] [Tuberculosis]

Evaluation of HIV TB Cases

Merve Karaman Kocabıyık, Aylin Babalık, Soner Umut Küver, Lale Sertçelik, Fatma Kutluhan, Gül Erdal Sönmez, Olga Çelenk, Tülin Kuyucu

Health Sciences University, İstanbul Süreyyapaşa Chest Diseases and Chest Surgery Training and Research Hospital, İstanbul, Turkey

Objectives: Frequency of Tuberculosis (TB) in HIV-positive people all over the world is higher than HIV-negative population. According to World Health Organization 10% of new TB cases estimated in 2016 were associated with HIV.HIV-TB deaths have been reported as 374,000. Aim of our study is sharing the increasing number of HIV-TB coexistence cases in recent years.

Methods: 24 HIV-positive TB patients were diagnosed and treated in Süreyyapaşa Hospital between 2016-2017 years. Patient files were evaluated for microbiological, radiological, and treatment retrospectively.

Results: The mean age of the patients was 41±10.4. Twenty two of them were male, 2 of them were female. 6 cases were foreign nationals. 20 cases had bacteriological, 2 had histopathological, 2 had a clinical radiological diagnosis. 19 patients who were tested for resistance, MDR-TB treatment was initiated in 4 patients. 20 cases were treated as new cases, 4 cases

were treated as recurrent cases. 12 of 14 cases with thoracic CT were evaluated for cavitory lesions, Mediastinal lymphadenopathy in 4, miliary appearance in 3, pleural effusion was detected in 3 cases. 15 patients were diagnosed with HIV and TB simultaneously. Pneumocystis jiroveci pneumonia was detected in 1 MDR-TB patient during the examinations because grand glass opacity were observed in CT sections. Patients with MDR-TB were treated with PAS, protonamide, cycloserine, moxifloxacin, amikacin as second line drugs. Two patients were also treated with linezolid.

Conclusion: Treatment for HIV-TB cases with atypical radiological findings, different clinical course and drug interactions should be started rapidly. Assessing anti-HIV antibodies in TB patients increases the likelihood of early diagnosis of HIV-TB patients

Keywords: HIV, TB, MDR TB

[Abstract:0217] EPS-068 [Accepted: E-Poster] [Diagnostic Methods]

Use of EBUS in the Diagnosis of Necrotic Endobronchial Lesions: Presentation of 2 Cases

Berat Celil Doğan, Aykut Çilli

Department of Chest Diseases, Akdeniz University, School of Medicine, Antalya, Turkey

Introduction: Endobronchial ultrasonography (EBUS) is generally used for indications such as nodal staging in lung cancer, diagnosis of mediastinal lymph node, and diagnosis of mediastinal mass lesions. In this study, 2 patients whose bronchoscopy revealed endobronchial lesion and who could not be diagnosed with conventional bronchoscopy, but diagnosed with EBUS biopsy were presented.

Case 1: A 41-year-old female patient consulted to the outpatient clinic due to the complaints of cough, dyspnea, and sputum, which were continuing for one month. Restrictive pattern was observed in her respiratory function test. The results of routine blood analyses were normal. In her PET-CT, a 3,8 cm mass filling the anterior region of the left lung upper lobe and being in the neighborhood of left hilar region and increased FDG involvement (SUV max: 15,4) in the atelectasis complex were observed. No pathological FDG involvement was found in the mediastinal structures. Firstly, the patient was performed normal bronchoscopy and necrotic endobronchial lesion was detected in the entry of the left upper lobe. Forceps biopsy performed from here was not diagnostic. In the second bronchoscopy of the patient, trans-

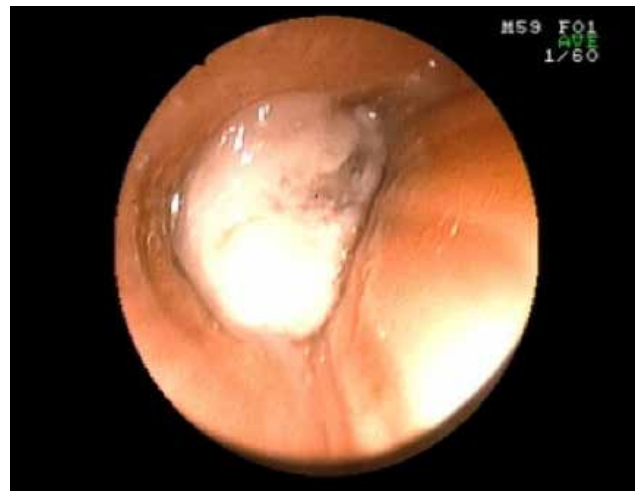

Figure 2. In the second case, view of necrotic endobronchial lesion on the entry of the right lower lobe

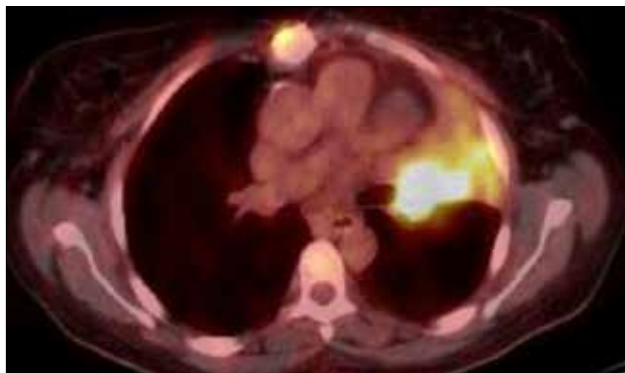


Figure 1. In the first case, a 3,8 cm mass filling the anterior region of the left lung upper lobe and being in the neighborhood of left hilar region and increased FDG involvement (SUV max: 15,4) in the atelectasis and fluid complex

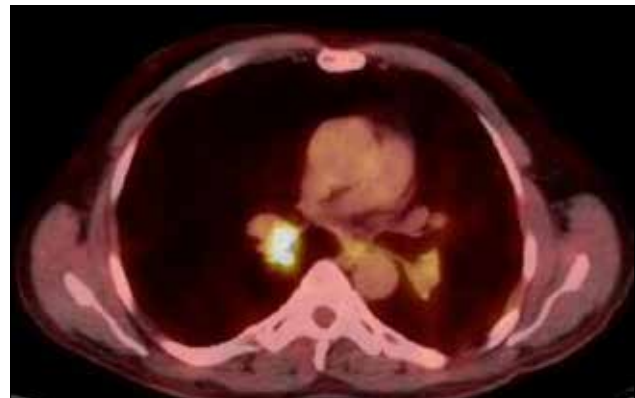


Figure 3. In PET-CT of the second case, view of a 2,3x1,6 cm hypermetabolic (SUV max:12,5) lesion in the neighborhood of right lower lobe superior segment and right hilus posterior

bronchial needle biopsy with EBUS was performed from non-necrotic area. The patient was pathologically diagnosed with squamous cell carcinoma and planned to be begun chemotherapy.

Case 2: A 50-year-old male patient was admitted to the outpatient clinic due to the complaints of cough, sputum, hemoptysis, fever, and weight loss, which lasted for about 2 months. His hemogram, biochemistry, and RFT results were found to be normal in the examinations. His PET-CT examination revealed multiple mediastinal hypermetabolic lymph nodes (SUV max: 16,9) and a 2,3x1,6 cm hypermetabolic (SUV max:12,5) lesion in the neighborhood of right lower lobe superior segment and right hilus posterior. In the bronchoscopic examination, a necrotic endobronchial lesion was detected in the right lower lobe entry. Because the patient had hyperventilation, mediastinal lymph node sampling could not be performed. In the evaluation with EBUS, transbronchial biopsy was carried out from non-necrotic region. The pathological diagnosis was reported as small-cell lung carcinoma. The patient, who was considered as non-operable, was initiated chemotherapy.

In conclusion, in two cases presented here, we have demonstrated that EBUS bronchoscopy can have a diagnostic value in the diagnosis of necrotic endobronchial lesions which can be difficult to diagnose through classical bronchoscopy.

Keywords: Endobronchial ultrasonography, necrotic, biopsy

[Abstract:0227] EPS-142 [Accepted: E-Poster] [Pulmonary Rehabilitation and Chronic Care]

Pulmonary Rehabilitation in a Young Patient with Interstitial Lung Disease

Seçil Sarı, Tuğba Göktalay, Yavuz Havlucu, Ayşın Şakar Coşkun, Pınar Çelik, Arzu Yorgancıoğlu

Department of Pulmonary Diseases, Celal Bayar University, Manisa, Turkey

A 20-year-old woman diagnosed with interstitial lung disease (ILD) was referred for pulmonary rehabilitation (PR) with the cause of effort dyspnea and fatigue. The patient was diagnosed a year ago and never smoked. She has not received any treatment for ILD yet. Physical examination revealed scoliosis. In the aquaculture, bilateral respiratory voices were reduced and bilateral lower zones had velcro ralles. The patient had a cachectic appearance, BMI: 15,26 kg/m², SpO₂: 99%, Nb: 112/min. Before pulmonary rehabilitation, FEV₁ was 0.84lt (28%), FVC was 1.35lt (39%) and FEV₁/FVC was 62%. mMRC,

Table 1. Evaluation parameters before and after pulmonary rehabilitation of the case

BEFORE PULMONARY REHABILITATION	AFTER PULMONARY REHABILITATION
HEART RATE:112	HEART RATE:99
SPO2 (REST) : 98	SPO2 (REST) : 98
SPO2 (EXERCISE) :81	SPO2 (EXERCISE) :92
BORG (REST) : 2	BORG (REST) : 1
BORG (EXERCISE) :4	BORG (EXERCISE) :3
MRC: 2	MRC: 1
EXERCISE CAPACITY: INSUFFICIENT	EXERCISE CAPACITY: A BRIEF LESS
6MWT: 460M	6MWT:585M
SHUTTLE: 580M	SHUTTLE: 610M
HAD	HAD
ANXIETY: 13	ANXIETY: 11
DEPRESSION: 6	DEPRESSION: 5
St.George's:	St.George's:
SYMPTOM: 59	SYMPTOM: 53
ACTIVITY: 55	ACTIVITY: 53
EFFECT: 20	EFFECT: 29
TOTAL: 37	TOTAL: 40
BMI:15,26	BMI:16,46

Significant improvement was observed in patient data recorded after pulmonary rehabilitation compared with before.

Borg dyspnea scales, ST.George's quality of life questionnaire and HAD scale were filled. The capacity was determined by the 6-min walk test (6MWT) and the shuttle test (Table 1). Before pulmonary rehabilitation programme, the patient was consulted by cardiology, ejection fraction (EF) of the patient was evaluated as 65%, maximal heart rate: 130/min. The patient was assigned to a structured pulmonary rehabilitation program for 8 weeks, 3 days a week, supervised at the hospital, 1 hour/day over the day. Endurans were calculated as 15 minutes. 85% of VO₂max was taken for the walking band. Disease training was given and bronchial hygiene techniques were taught. Exercise program consisted of exercises of joint motion, openness exercise, aerobic exercise, strengthening exercise, respiration exercise and relaxation and stretching exercises. Since the patient was desaturated in the lower extremity pedaling exercise, O₂ inhalation was given to the patient during the pulmonary rehabilitation program at 4 lt/min. At the end of the program there was a decrease in the dyspnea perception, an increase of 125 meters at 6MWT and a 30-meter increase at AHMT. Improvement in the quality of life parameters was observed. Weight gain was also detected (Table 1). Improvement in the quality of life parameters was observed. As a result, the improvement we have recorded in our case has supported the effectiveness of pulmonary rehabilitation programs in obstructive diseases as well as restrictive pulmonary diseases. Encouraging these patients to participate in structured pulmonary rehabilitation programs will have positive effects on functional capacities and quality of life.

Keywords: Interstitial lung disease, pulmonary rehabilitation, scoliosis

[Abstract:0229] EPS-112 [Accepted: E-Poster] [Lung and Pleura Malignancies]

Contribution of Transbronchial Needle Aspiration Biopsy to Lung Cancer Diagnosis

Bünyamin Sertoğullarından¹, Celal Doğan²

¹Department of Pulmonary Medicine, İzmir Katip Çelebi University, İzmir, Turkey

²Katip Çelebi University, Atatürk Research and Teaching Hospital, İzmir, Turkey

Objectives: Bronchoscopic endobronchial forceps biopsy (CTT) is a routine diagnostic method of lung cancer in the cases have suspect of lung cancer and Thoracic computed tomography report in this respect. In these cases, Occasionally, there are not endobronchial lesions, or the locality of lesios leads to difficulties in obtaining the diagnosis. Transbronchial needle aspiration (TBNA) is a cheap and minimally invasive diagnostic method that can be used to diagnose lung cancer cases. Especially when the endobronchial mass is not detected or when the doctor thought sample can be negative, it may contribute to the diagnosis by applying it to the localization of the mass or to the large and easiestly-exemplified lymph nodes.

Methods: We evaluated endobronchial forceps biopsy and TBNA results of cases with suspected lung cancer in our clinic in last one year.

Results: We detected 19 cases had simultaneous forceps biopsy and transbronchial needle aspiration. One colan carcinoma case had mediastinal LAP on both TCT and PET CT. In 10 cases, the diagnosis was confirmed by forceps biopsy and concurrent TBTNA was negative. In 5 cases, TBNA was positive and forceps biopsy was negative. In 5 cases, simultaneous diagnostic result was reached. Cellular types were squamous cell carcinoma in 5 cases, small cell carcinoma in 5 cases, adenocarcinoma in 2 cases, large cell carcinoma in 1 case, undifferentiated carcinoma in 1 case, colon metastasis in 1 case, neuroendocrine tumor in 1 case, lymphoma in 1 case. 3 cases were detected as non-small cell cancer. One patient underwent surgical treatment for lung cancer, which received diagnosis by TBNA with non-small cell lung cancer.

Conclusions: TBNA is a minimally invasive, inexpensive, easy learn method that can contribute to the diagnosis of lung cancer. It should be routinely performed in cases where it can be performed to reduce the need for additional procedure.

Keywords: Lung Cancer, Transbronchial needle aspiration, diagnosis

[Abstract:0231] PS-140 [Accepted:Poster Presentation] [Clinical Problems - Pulmonary Vascular Diseases]

A Patient Not Wanting to Give Inferior Vena Cava Filter: A CTEPH Case

Selvi Aşker¹, Müntecep Aşker², Mesut Özgökçe³, İbrahim Halil Üney², Ayşegül Demirbaş²

¹Department of Chest Diseases, Van Yüzüncü Yıl University, School of Medicine, Van, Turkey

²Department of Cardiology, Van Yüzüncü Yıl University, School of Medicine, Van, Turkey

³Department of Radiology, Van Yüzüncü Yıl University, School of Medicine, Van, Turkey

Introduction: Anticoagulant therapy is primarily preferred in the treatment and prevention of venous thromboembolism (VTE). However, in some cases, inferior vena cava (IVC) filters, which is a mechanical prophylaxis method, are considered. The indications for inferior vena cava filters are the presence of contraindication to anticoagulant therapy, occurrence of bleeding complication under treatment, and development of recurrence under treatment. For the filter to be removed safely, the period should not exceed 90-120 days. After placement, the most common complications encountered in permanent filters include the development of DVT, IVC thrombus, chronic venous insufficiency in the lower extremities, recurrent pulmonary thromboembolism associated with thrombus formation in filter, and thrombotic obstruction of filter. In this study, we aimed to present a CTEPH (chronic thromboembolic pulmonary hypertension) patient who had inferior vena cava filter for three years and who did not want to give the filter because of thinking that it protected her.

Case Presentation: A 47-year-old female patient was admitted to the outpatient clinic of chest diseases because of dyspnea. It was learned from the hospital records of the patient, whose two legs were amputated, that she carried MTHFR homozygote gene mutation. Her legs were amputated due to arterial thrombus 5 years ago. One year after that, she had pulmonary embo-

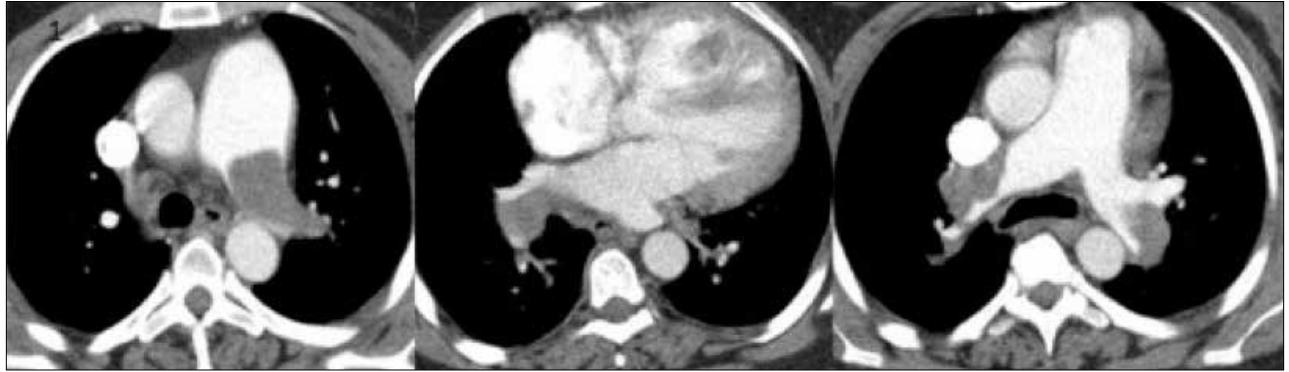

Figure 1. Computed tomography images of the case (2014)

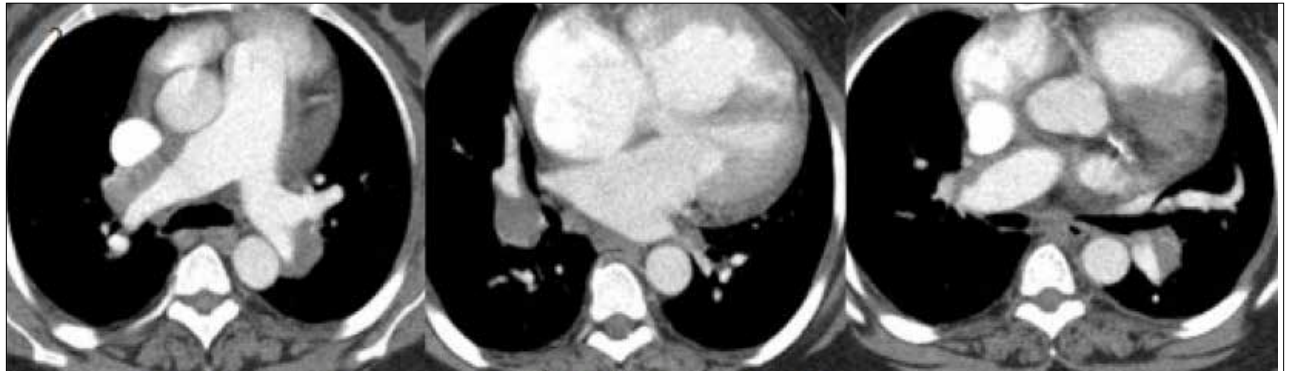

Figure 2. Computed tomography images of the case (2016)

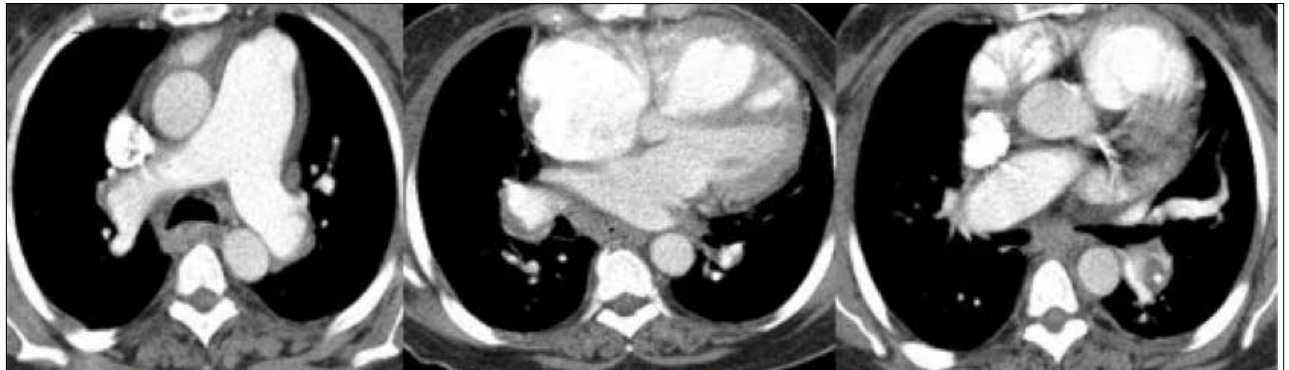


Figure 3. Computed tomography images of the case (2018)

lism and had thrombus in the pelvic veins. It was also learned that pulmonary embolisms re-occurred despite antithrombotic treatment and therefore, inferior vena cava filter was inserted (Figure 1). In the lung computed tomography of the patient, who had IVC filter for three years and received warfarin therapy, chronic thrombus was detected in both main pulmonary arteries (Figure 2). In the abdominal Doppler ultrasonography, stasis and collaterals were found in the pelvic veins. In the abdominal MR examination, the lumen of inferior vena cava filter was observed to be narrowed and there were passages from sides. Systolic pulmonary arterial pressure value was measured as 90 mmhg in the echocardiography. The patient, who had perfusion defects in V-P scintigraphy, was begun riociguat, which is a guanylate cyclase stimulator. She did not want IVC filter to be removed and she was followed up by considering possible complications that could develop during procedure. The patient, who did not accept pulmonary endarterectomy, was performed control tomography because of impaired clinical parameters of pulmonary hypertension in the first year of the treatment. A new occurrence of acute embolism was not encountered (Figure 3). It was switched to combination therapy in the patient. She is still followed up with IVC filter. Although inferior vena cava filter is protective, it can cause the development of DVT, IVC thrombus, vessel wall erosion, chronic venous insufficiency, and recurrent pulmonary thromboembolisms in a long-term period. Although the cause of chronic embolism in the case is associated with hereditary condition, recurrent embolisms might have resulted from IVC filter. However, the removal of a filter staying so much can lead to the development of new complications in such an immobile patient with venous insufficiency. An appropriate approach on time would have been better for this patient.

Keywords: Vena kava filters, embolism, pulmonary hypertension

[Abstract:0232] SS-150 [Accepted:Oral Presentation] [Tuberculosis]

Evaluation of 123 Cases with MDR TB (Multidrug Resistant Tuberculosis) Treatment

Aylin Babalık¹, Ayşe Rümeysa Hazine¹, Fatma Kutluhan¹, Olga Akkan¹, Gül Erdal Dönmez¹, Ahmet Balıkçı¹, Gülay Çatmabacak¹, Kaya Köksalan², Tülin Kuyucu¹

¹Health Sciences University, İstanbul Süreyyapaşa Chest Diseases and Chest Surgery Training and Research Hospital, İstanbul, Turkey

²Istanbul University Aziz Sançar Institute of Experimental Medicine, İstanbul, Turkey

Objectives: Drug-resistant TB is threatening global TB control, one of the basic public health problems for most countries. There were a half of MDR TB patients in İstanbul. In our study, we aimed to evaluate our patients who received MDR TB treatment in our hospital, which is one of the two important reference hospitals of İstanbul.

Methods: Between 2015-2017 years, patients who received MDR TB treatment were evaluated retrospectively in SB University Süreyyapaşa Chest Diseases. Microbiologic diagnosis, resistance tests (laboratory-related laboratory, Süreyyapaşa EAH, DEATE, TULSA laboratory records), age, gender, nationality, treatments regime were evaluated.

Results: Between 2015-2017, 123 patients with a mean age of 39±14 were diagnosed and treated as MDR TB. 84 (69%) patients were male and 25 (20.3%) were foreign nationals (Azerbaijan (4), Turkmenistan (3), Somalia (3), Syria (3), Georgia (3), Uzbekistan (2), Bulgaria (1), Dagestan (1), Afghan (1), Armenian (1), Kazakhstan (1), Kyrgyzstan (1), Mongolia (1), Tajikistan (1), Ukraine (1)). 87 (70.2%) were classified as previously treated patients. 88 (70.9%) patients had smear positively. 115 (93.4%) were hospitalized in the tuberculosis clinic. The mean hospital stay was 56±53 days. 8 (6.5%) of 123 patients had rifampicin resistance without isoniyasid resistance, 115 (93.5%) patients had HR resistance and 51 (41.5%) patients had HRES resistance. PZA drug susceptibility test was in 60 (48.8%) patients (PZA resistance detected in 7 patients). 102 (82.9%) had second-line drug susceptibility test (2 patients had amikacin resistance, 10 had quinolone resistance, 88 had ethionamide resistance, and 11 had PAS resistance). Linezolid resistance was studied in 85 (69.11%) of 123 patients (Linezolid resistance was detected in 1). When 123 treatment regimens were evaluated, 4 (0.25%) Isoniasid, 81 (65.8%) PZA, 20 (16.7%) EMB, 121 (98.4%) amikacin, 121 quinolone (moxifloxacin 120, levofloxacin 1) was used. 106 (86.2%) patients were treated with ethionamide, 106 (86.2%) with PAS, 24 (19.5%) with linezolid, 22 (17.8%) with clofazimine and 2 (1.6%) with amoxicillin+clavulanate. In the treatment regimen, the duration of PE drug was planned to be 4 to 6 months, and the total duration of treatment was 18 months after culture negative. The results of treatment of patients are followed.

Conclusions: MDR TB treatment is a treatment regimen with long duration, high side effects and high treatment default rates. Early diagnosis of MDR TB patients, the initiation of an effective and correct treatment regimen, and the maintenance and completion of effective treatment are important for the TB control program.

Keywords: MDR, TB, treatment

[Abstract:0233] EPS-042 [Accepted: E-Poster] [Clinical Problems - Pulmonary Vascular Diseases]

A Patient Unable to Escape From Pulmonary Hypertension: A Case Report

Selvi Aşker¹, Müntecep Aşker², İbrahim Halil Üney¹, Ayşegül Demirbaş¹

¹Department of Chest Diseases, Van Yüzüncü Yıl University, School of Medicine, Van, Turkey

²Department of Cardiology, Van Yüzüncü Yıl University, School of Medicine, Van, Turkey

Introduction: Pulmonary hypertension is a chronic and progressive disease that can occur due to various reasons. For diagnosis, the etiological group of pulmonary hypertension must be known. It is classified in 5 main groups as: Group I: Pulmonary arterial hypertension (PAH), Group II: PH associated with left heart diseases, Group III: PH associated with lung diseases and/or hypoxia, Group IV: Chronic thromboembolic PH (CTEPH), and Group V: PH with unknown mechanisms or caused by many factors. In some patients, simultaneous coexistence of these groups can be seen. In this study, we aimed to present a patient who was group 1 pulmonary hypertension patient but recovered with operation, but developed group 4 pulmonary hypertension after a long time.

Case Presentation: A 70-year-old female patient consulted to the outpatient clinic of chest diseases due to the complaints of chest pain and dyspnea. In the chest radiography of the patient, whose oxygen saturation was 88%, pulmonary conus was apparently observed (Figure 1a). Computed tomography of the patient revealed thrombus in the right pulmonary arterial distal region and hypodensities consistent with chronic thrombus in the branches extending from the left pulmonary arterial distal towards the lower lobe (Figure 1b). Thrombus narrowing the lumen to a great extent was found in the lingular branch (Figure 1c). Computed tomography images that had been performed 3 months ago were reached and thrombus was detected in the same region. In her echocardiography, systolic pulmonary arterial pressure value was measured as 80 mmHg. Moderate-high risk perfusion defect was detected in the ventilation/perfusion scintigraphy. It was learned that the patient had undergone open surgery due to ASD (atrial septal defect) 12 years ago. It was found in the hospital records that preoperative PAP value of the patient was 55 mmhg and then pulmonary insufficiency disappeared. The patient was performed right heart catheterization. Systolic/diastolic/mean PAP value was measured as 64/25/42 mmhg. Pulmonary vascular resistance was 8 Wood/U and pulmonary capillary end pressure was 12 mmhg. All factors that could lead to pulmonary embolism were investigated. The patient, for whom no reason was found, was considered to have CTEPH developing in association with idiopathic pulmonary embolism. She was initiated treatment with rivaroxaban, which is a novel oral anticoagulant, and riociguat, which is guanylate cyclase stimulator, and followed up.

In pulmonary hypertension patients, the risk of pulmonary thrombus associated with statis always exists because of chronic changes in the vascular structure. Although class of recommendation is low, antithrombotic therapy is recommended for these patients. In our case, the development of embolism despite the disappearance of pulmonary insufficiency after ASD closure enabled us to think about whether the cause of embolism was idiopathic or associated with past vascular changes. Such patients should be followed closely.

Keywords: Pulmonary hypertension, pulmonary embolism, atrial septal defect

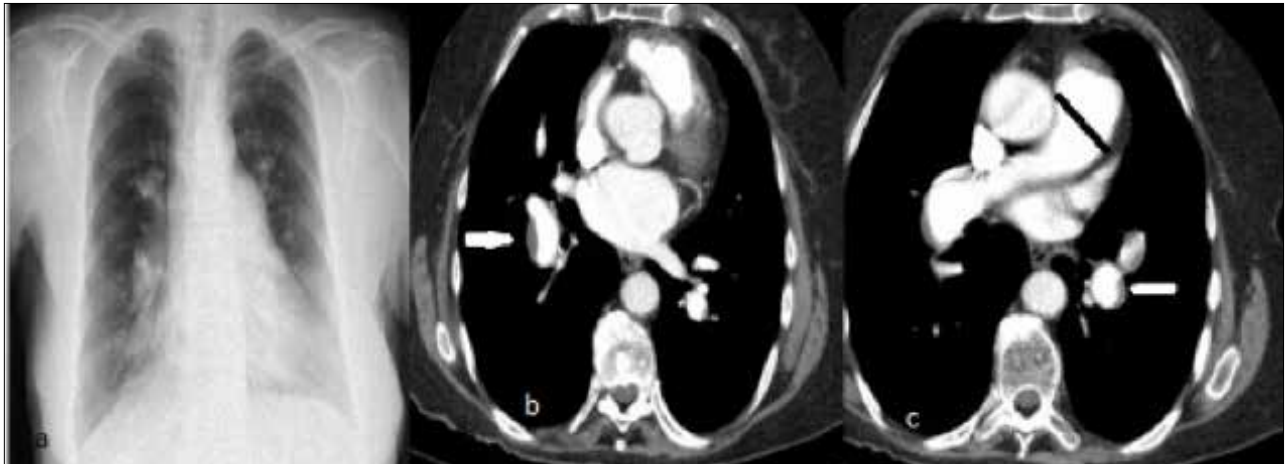


Figure 1. Chest radiography and computed tomography images of the case

[Abstract:0234] EPS-037 [Accepted: E-Poster] [Clinical Problems - Pulmonary Vascular Diseases]

Three Causes of Pulmonary Hypertension in a Patient: Collagen Tissue Disease, Congenital Disease, and Chronic Thromboembolism

Selvi Aşker¹, Müntecep Aşker², Ayşegül Demirbaş¹, İbrahim Halil Üney¹

¹Department of Chest Diseases, Van Yüzüncü Yıl University, School of Medicine, Van, Turkey

²Department of Cardiology, Van Yüzüncü Yıl University, School of Medicine, Van, Turkey

Introduction: Pulmonary hypertension (PH) is a chronic and progressive disease that can occur due to various reasons. Its cause cannot always be definable. It can result from one or more underlying conditions. In the diagnosis of pulmonary hypertension, the etiological group and the related disease included in that group should be determined. It is classified in 5 main groups as: Group I: Pulmonary arterial hypertension (PAH), Group II: PH associated with left heart diseases, Group III: PH associated with lung diseases and/or hypoxia, Group IV: Chronic thromboembolic PH (CTEPH), and Group V: PH with unknown mechanisms or caused by many factors.

In some patients, simultaneous coexistence of these groups can be seen. In this study, we aimed to present a patient who was diagnosed with ASD after pulmonary embolism and found to have mixed connective tissue disease in the follow-ups.

Case Presentation: A 36-year-old female patient was admitted to the outpatient clinic of chest diseases due to the complaints of swelling in the leg and dyspnea three years ago. In the computed lung tomography of the patient, who had deep venous thrombosis, unilateral minimal effusion and segmental thrombus in the same side were detected. Her blood pressure was normal and her chest radiography revealed increased CTR. Echocardiography was performed due to expanded hilus (Figure 1a). Her PAP value found as 70 mmhg. Additionally, fenestrated ASD was detected. Because her general condition was good, ASD closure was planned and warfarin was initiated. After performing closure in an external center, the patient was begun endothelin receptor antagonist. In the control examination in the 6th month, PAP value was measured as 45 mmhg. No DVT was detected. V-P scintigraphy was evaluated to be normal and warfarin therapy was stopped. In the 18th month, the patient consulted us for the complaints of fever, chest pain, and dyspnea. In the chest radiography, bilateral effusion was seen, CTR was high, both hili were expanded, and parenchymal infiltration was observed (Figure 1b). PAP value was measured as 80 mmhg. Thrombus in both main pulmonary arteries and diffuse infiltration in the parenchyma were detected (Figure 2a, b). No DVT was observed in Doppler USG. The patient was examined with regard to rheumatoid diseases. The antibodies of ANA 1/1320, SSA, SSB, Anti Sm, Ro52, and RNP were determined to be positive. The patient, who was diagnosed with mixed connective tissue disease, was begun immunosuppressive treatment. In her 3rd month controls, lung lesions were regressed (Figure 3). Because perfusion defect continued and right heart insufficiency findings were detected in V-P scintigraphy, it was switched to combination therapy for pulmonary hypertension. She was begun to be given riociguat, which is guanylate cyclase stimulator, therapy. The patient is still followed up as clinically stable.

Although the cause of pulmonary hypertension is known, all other factors should also be investigated. If we think that there is no problem related to the disease course in the case of clinical deterioration during follow-ups, it is necessary to examine other causes of pulmonary hypertension. The cases of pulmonary hypertension the causes of which can be cured should not be overlooked and we should evaluate them.

Keywords: Pulmonary hypertension, mixed connective tissue disease, pulmonary embolism, congenital heart defects

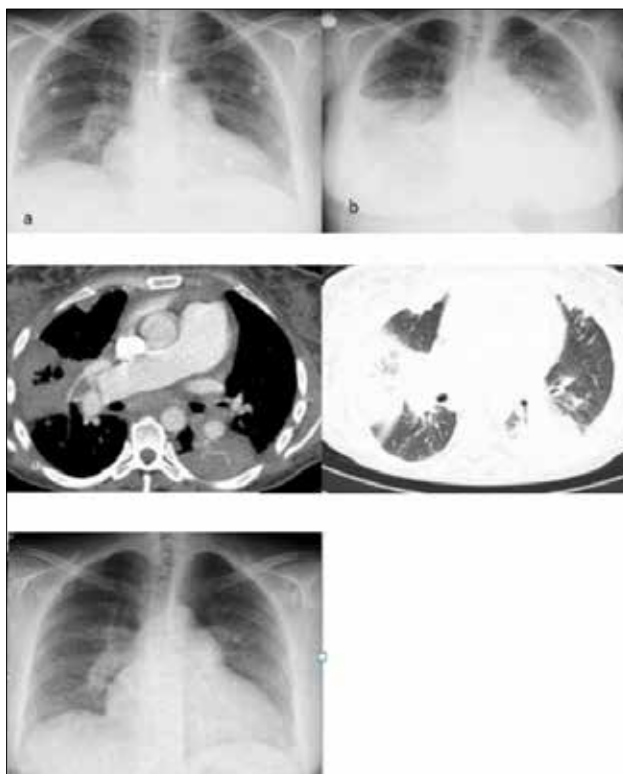


Figure 1-3. Radiological images of the case

[Abstract:0235] PS-308 [Accepted:Poster Presentation] [Respiratory Infections]

Acute Eosinophilic Pneumonia due to Heroin Inhalation

Canan Doğan¹, Hacı Ahmet Bircan², Zekiye Kula²

¹Clinic of Chest Diseases, Isparta City Hospital, Isparta, Turkey

²Department of Chest Diseases, Süleyman Demirel University School of Medicine, Isparta, Turkey

Introduction: The use of illegal drugs is a common and important public health problem and rarely can lead to pulmonary complications. Heroin, one of these substances, is known to cause coughing, bronchospasm, pulmonary edema, eosinophilic lung disease and diffuse alveolar damage when used. Here we present a case of eosinophilic pneumonia referring to the acute hypoxemic respiratory failure as a result of heroin inhalation.

Case Presentation: A 26-year-old male patient was admitted to the emergency service for three days with complaints of increasing dyspnea, fever, cough and sputum. The patient also has 8 pocket/year cigarette smoking, intermittent alcohol and heroin use. In vital symptoms; heart rate was 92, blood pressure was 110/70 mmHg, respiration rate was 35, and fever was 38.2°C. On physical examination, the general condition was moderate, dyspneic, conscious and cooperative. Bilateral common expiratory rhoncus were present, heart sounds were rhythmic and tachycardic. Other system examination findings were ordinary. SpO₂ was 74% in the room air. In arterial blood gas pH was 7.45, pCO₂ was 35, mmHg pO₂ was 41.2, and mmHg sO₂ was 74.3%. The routine biochemical examination were 16.200 mm³ leucocytes, 20.5% eosinophil (3.32), 9.61 mg/dL CRP, and total IGE>1210. Chest x-ray showed bilateral, diffuse and heterogeneous density and the thorax computed tomography showed bilateral, diffuse, patchy ground-glass opacities. Restrictive pattern was observed in respiratory function test. Flexible fiberoptic bronchoscopic (FOB) examination was performed, transbronchial biopsy was reported as atelectatic lung tissue and bronchoalveolar lavage was not diagnostic. No parasites, fungal or bacterial factors were detected that could explain eosinophilia in the blood, sputum, FOB and stool microbiological examination of the patient. In the presence of these findings the patient was diagnosed with AEP due to heroin inhalation. Radiological and clinical regression was observed after methylprednisolone was started and he quit using heroin.

Conclusion: Illegal drug and any substance use should be carefully examined in cases of interstitial lung disease in young ages and eosinophilic pneumonia should be considered in differential diagnosis in patients with acute respiratory failure as in our case.

Keywords: Acute eosinophilic pneumonia, heroin inhalation, respiratory failure, eosinophilia

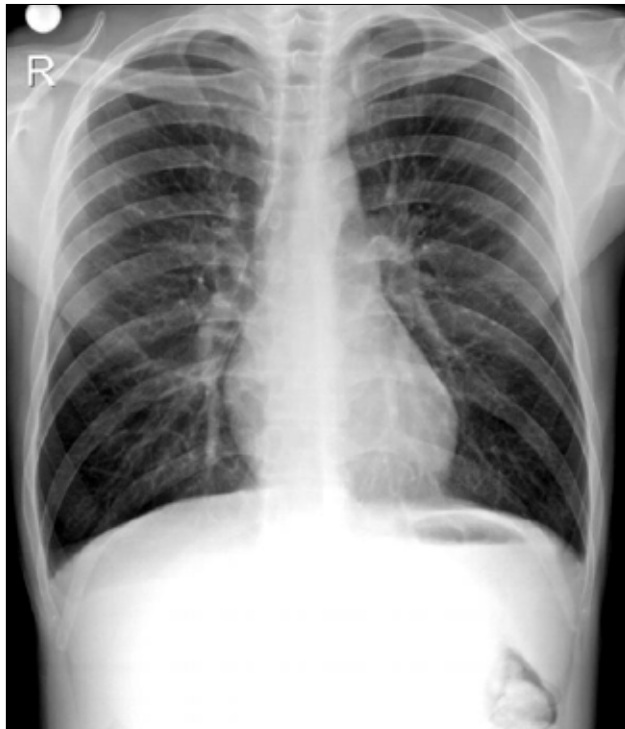


Figure 1. Chest X-ray diagnosis

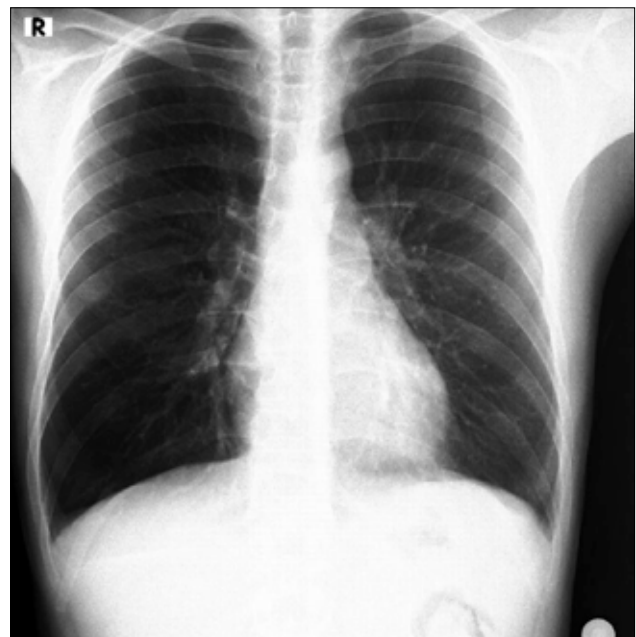


Figure 2. Chest X-ray after treatment

[Abstract:0238] EPS-139 [Accepted: E-Poster] [Pulmonary Pathology]

Nüx Stomach Cancer with Endobronchial Metastases

Emine Özsarı, Suat Konuk, Elif Açar, Tuncer Tuğ, Songül Taştan Çelik, Manolya Mahlıçlı

Department of Chest Diseases, Abant İzzet Baysal University School of Medicine, Bolu, Turkey

One of the most frequently observed organs of extrapulmonary solid tumor metastases is the lungs. Pulmonary metastatic lesions are mostly observed in parenchyma, endobronchial metastases are very rare and the incidence is reported as 2%. Tumors that are most commonly metastatic to the lungs from extrathoracic malignancies are breast, kidney and colorectal cancers. Endobronchial involvement of stomach cancer as the first metastasis site is a very rare condition. A case was presented to emphasize the necessity of considering metastatic cancer in differential diagnosis in endobronchial lesions.

Keywords: Endobronchial lesion, metastasis, stomach cancer

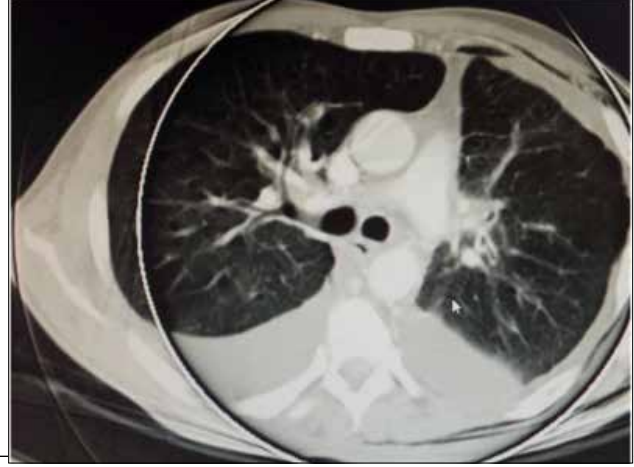


Figure 2. Thorax CT at the diagnosis

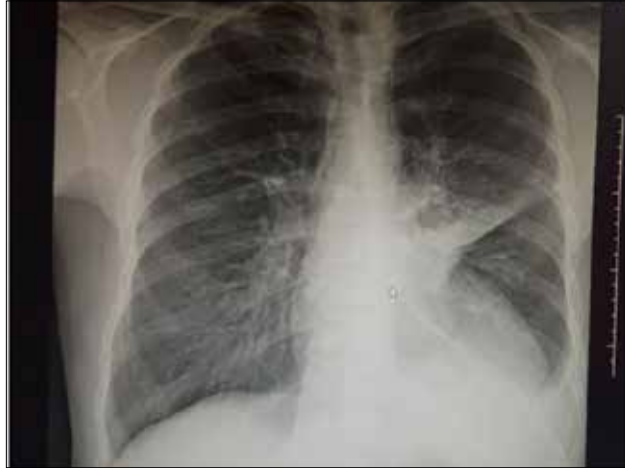

Figure 1. Posteroanterior chest X-ray at the time of diagnosis

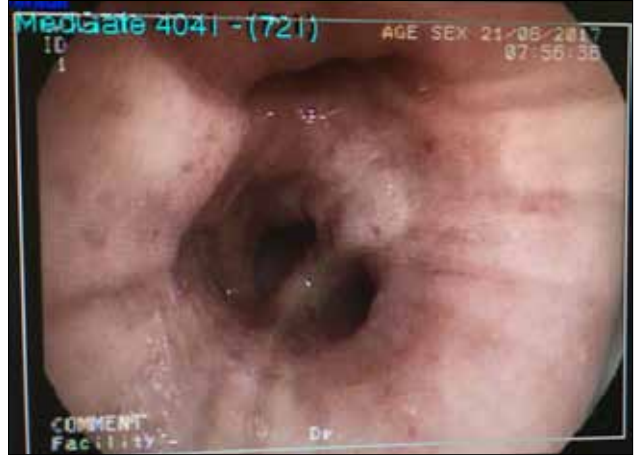

Figure 3. Fiberoptic bronchoscope image

[Abstract:0240] SS-004 [Accepted: Oral Presentation] [Asthma and Allergy]

Can Neutrophil to Lymphocyte Ratio (NLR) or Eosinophil to Lymphocyte Ratio (ELR) Be Used to Predict The Outcome of Omalizumab Treatment in Eosinophilic and Non-Eosinophilic Severe Allergic Asthma?

Hasan Özgen¹, İsmet Bulut², Fatma Merve Tepetam², Cihan Örçen²

¹Department of Chest Diseases, Süreyyapaşa Chest Diseases and Thoracic Surgery Training and Research Hospital, University of Health Sciences, İstanbul, Turkey

²Department of Allergy and Immunology, Süreyyapaşa Chest Diseases and Thoracic Surgery Training and Research Hospital, University of Health Sciences, İstanbul, Turkey

Objectives: Th2/Th1 mix pathological pathway may be seen as a common set of low eosinophilic phenotype in severe aller-

gic asthma. This may affect omalizumab (OMB) treatment response. The results of OMB therapy have been reported in previous studies in which exhaled nitric oxide (FENO) measurement, serum periostin levels, and bronchial eosinophilia levels could be used. These methods are expensive and invasive. In this study, we aimed to investigate whether eosinophil level and eosinophil lymphocyte ratio predict OMB therapy.

Methods: Patients who received OMB therapy in our allergy clinic were screened retrospectively. Baseline hemogram parameters, pre- and post-treatment emergency admission, annual steroid use, annual admission of inpatient care unit, medication and doses used by patients and asthma control tests (ACT) were recorded. According to the global efficacy assessment (physician's GETE) scale patients were recorded as responder if assessed as complete improvement (excellent) and significant improvement (good); and recorded as unresponder if assessed as limited change, no change or worsening.

Results: The mean age of 83 patients was 50.03 ± 10.78 ; 64 (77%) patients were female and 18 (23%) were male. While ACT scores and FEV₁ as a pulmonary function parameter were significantly increased, the number of urgent admission, annual hospitalizations and systemic steroid needs decreased significantly ($p < 0.05$). Sixty-three of the patients (76%) were in the responder group and twenty of the patients were in the unresponder group (24%). When the groups were compared as eosinophil and eosinophil lymphocyte ratio, the ratio of eosinophil and eosinophil lymphocyte was significantly higher in the responder group (the mean eosinophil count was 290 cells/mm³ (3.71%) and the eosinophil lymphocyte ratio was 0.14 was in the responder group; the mean eosinophil count was 180 cells/mm³ (2.09%) and the eosinophil lymphocyte ratio was 0.06 in the unresponder group; p value was < 0.017 and 0.04 respectively).

Conclusion: Instead of expensive and invasive methods for predicting the response of OMB therapy in severe allergic asthma, the eosinophil lymphocyte ratio in hemogram parameters is correlated with treatment response and giving hope to be cheaper and easier way to reach. There is a need for larger patient numbers and randomized controlled studies.

Keywords: Asthma, eosinophil, neutrophil, lymphocyte, ratio, omalizumab

[Abstract:0241] EPS-015 [Accepted: E-Poster] [Clinic Problems - Others]

Pulmonary Arteriovenous Malformation Mimicking Solitary Pulmonary Nodule

Fatmanur Çelik Başaran¹, Mine Gayaf², Canan Doğan³, Ahmet Emin Erbaycu²

¹Clinic of Lung Transplantation, Bursa High Specialization Training and Research Hospital, Bursa, Turkey

²Department of Pulmonary Medicine, Dr Suat Seren Pulmonary Medicine and Surgery Training and Research Hospital, İzmir, Turkey

³Department of Pulmonary Medicine, Isparta State Hospital, Isparta, Turkey

Pulmonary arteriovenous malformation are rare vascular

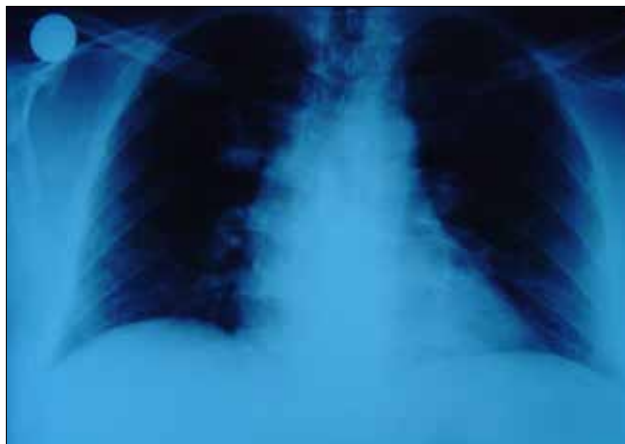

Figure 1. Chest X-Ray

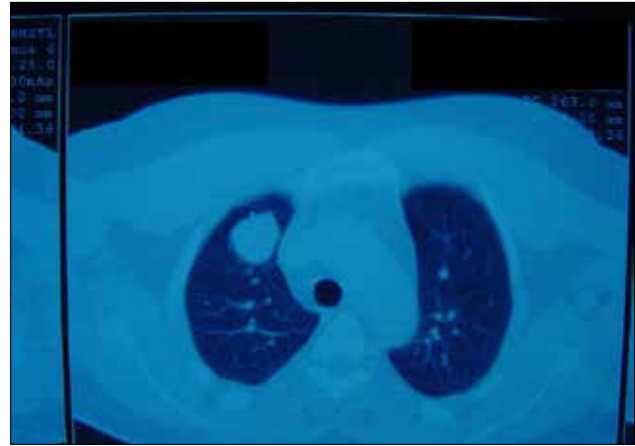

Figure 2. Thorax Angio BT

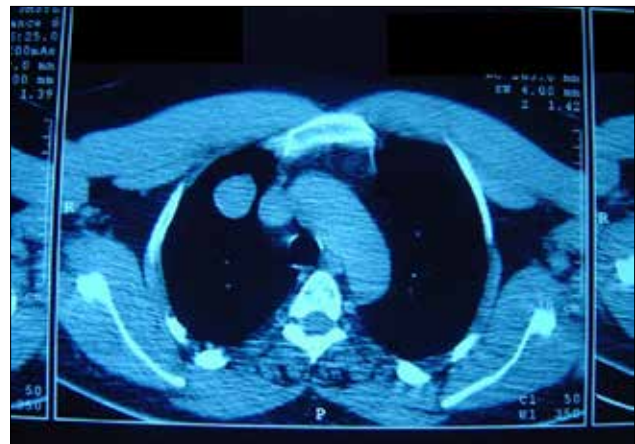


Figure 3. Thorax Angio BT

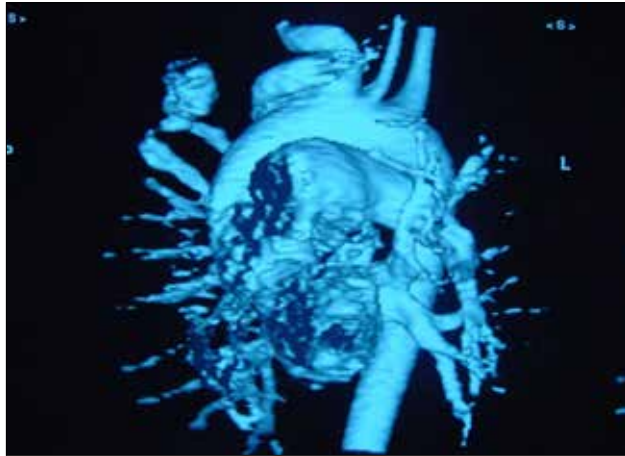


Figure 4. MR Angiography

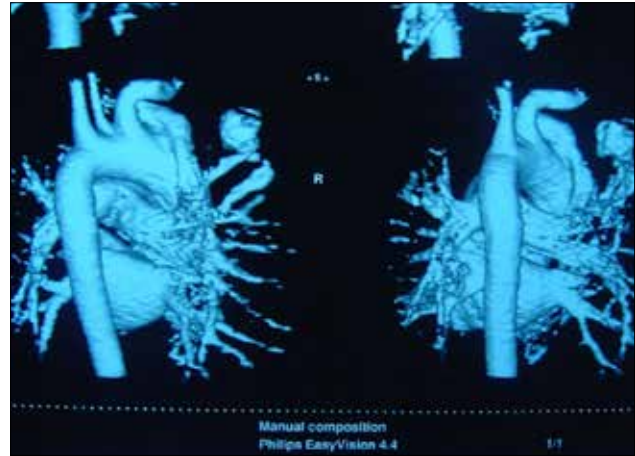


Figure 5. MR Angiography

abnormalities of the lung. The vast majority of pulmonary AVM cases are isolated but can be related to Rendu-Osler-Weber Syndrome. Although most patients are asymptomatic, AVM can cause hemoptysis or hypoxemia. It is presented because it is rarely seen and takes place in the differential diagnosis of lung tumors and solitary pulmonary nodules.

Keywords: Pulmonary arteriovenous malformation, solitary pulmonary nodule, Rendu-Osler-Weber Syndrome

[Abstract:0242] EPS-189 [Accepted: E-Poster] [Thoracic Surgery]

Role of Reformate Images in Evaluating Preoperative CT of Lung Cancer: Are Axial Images Enough in Preoperative Evaluation?

Mustafa Çalık¹, Murat Serhat Aygün²,
Saniye Göknil Çalık³, Zümrüt Ela Arslan Kasdoğan⁴,
Nuri Düzgün¹, Ferdane Melike Duran¹,
Hıdır Esme¹

¹Department of Thoracic Surgery, Health Sciences University, Konya Training and Research Hospital, Konya, Turkey

²Department of Radiology, Health Sciences University, Konya Training and Research Hospital, Konya, Turkey

³Emergency and First Aid Program, Vocational School of Health Services KTO Karatay University, Konya, Turkey

⁴Department of Anesthesiology and Reanimation, Health Sciences University, Konya Training and Research Hospital, Konya, Turkey

Objectives: There can be some unexpected situations during the surgery in the case of evaluating only axial plane CT images in lung cancer.

Methods: Total 98 patients, who had lung cancer in our clinic, were included in our study. Sagittal and coronal plane CT images were reconstructed and uploaded to PACS system. CT images of the 56 patients were re-evaluated by a radiologist who doesn't know the pathologic and surgery results. Sagittal, coronal and axial planes are evaluated separately. All results are compared with surgery and pathologic results.

Results: In 4 cases axial plane evaluation caused mis-diagno-

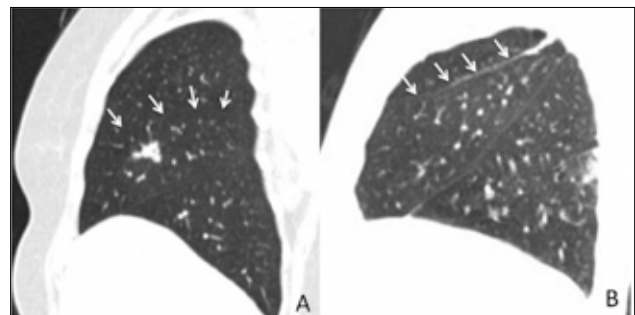


Figure 1. Sagittal plane reconstructed images of different patients. A: Variations of minor fissure (arrows) that causes mistakes in evaluation. Transverse minor fissure is not easy to detect on axial plane. B: Too high position of minor fissure also leads to mistakes

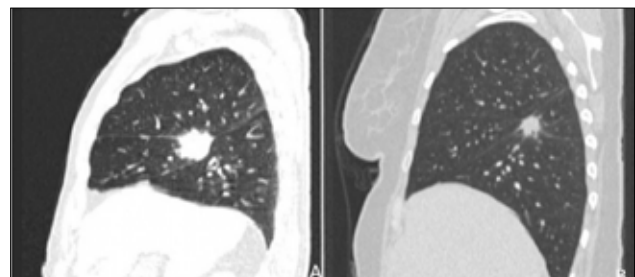


Figure 2. Two different patients with same appearance on axial plane, but lesion is in middle lobe with invasion of superior lobe (a) and in the other image lesion is lower lobe

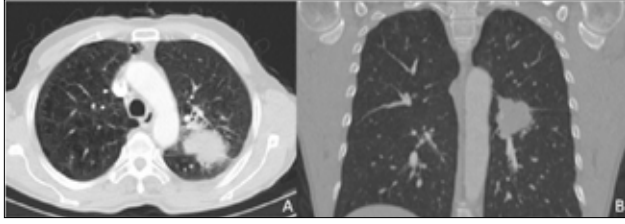


Figure 3. Axial and coronal plane showed invasion of fissure in two different cases. A: Upper lob lesion extended lower lob B: Lower lob lesion invaded upper lob

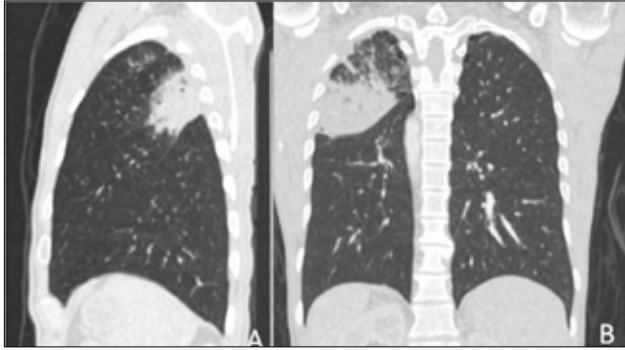


Figure 4. Only sagittal plane showed that upper lob lesion invaded middle lob

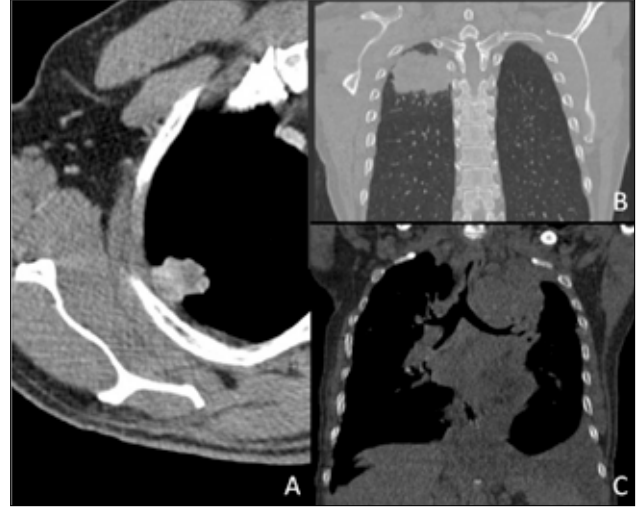


Figure 5. Chest X-Ray showed upper zone lesion (a) . Pleural invasion was only diagnosed by coronal plane (b) . Also on coronal plane maximum dimation is bigger than the axial dimation because of oblique orientation of the lesion.

sis about the localization of the lesions. In 2 cases right upper lobe anterior segment lesion was mis-diagnosed as middle lob lesion and in other 2 cases confusion was between left lung inferior lobe superior segment and inferior parts of upper lobe apicoposterior lobe. Sagittal and coronal planes were founded best planes for evaluating the localization of the lesion. In four patients pleural invasion could not detected with axial plane images.

Largest dimensions of the lesions were increased approximately %8 with reformate imaging. But in only two patients that increase changed the stage of the lesion.

Conclusion: Evaluating only axial plane images could cause faulty in staging lung cancers. But in measuring the biggest size rarely changes the stage. In evaluation and diagnosis of Pancoast tumor, MRI is superior to other modalities. But coronal plane reformate CT images of thin slices have same accuracy of MRI.

Keywords: Reformate images, lung cancer, staging

[Abstract:0243] SS-089 [Accepted:Oral Presentation] [Pediatric Pulmonary Diseases]

Diverse Clinical Characteristics of Aspergillus Growth in Patients with Cystic Fibrosis

Nagehan Emiralioğlu¹, Deniz Doğru¹, Özlem Doğan², Dolunay Gülmez², Sevtap Arıkan Akdağlı², Sanem Eryılmaz¹, Gökçen Tuğcu¹, Mina Gharibzadeh Hızal¹, Ebru Yalçın¹, Uğur Özçelik¹, Burçin Şener², Nural Kiper¹

¹Department of Pediatric Chest Diseases, Hacettepe University School of Medicine, Ankara, Turkey

²Department of Clinical Microbiology, Hacettepe University School of Medicine, Ankara, Turkey

Objectives: Patients CF have an extending spectrum of clinically significant Aspergillus disease in addition to allergic bronchopulmonary aspergillosis (ABPA). Here we aimed to review the different clinical phenotypes related with Aspergillus growth on the airway culture of patients with CF and we also aimed to evaluate the effect of Aspergillus growth on lung function of these patients. Our second aim was to review the risk factors affecting the growth of Aspergillus in sputum of patients with CF.

2001 and June 2016 were retrospectively analyzed. Age, gender, symptoms, physical examination findings, pulmonary function tests, the diagnosis of ABPA, and sputum culture results were recorded for every visit. Patients with Aspergillus growth on airway cultures were classified into different groups as ABPA, Aspergillus sensitization, Aspergillus colonization and Aspergillus bronchitis.

Results: There were 100 patients with Aspergillus growth in sputum culture during the study period. Of these, medical records of 83 patients and 147 sputum cultures were attainable. The mean age of the patients was 17.6 ± 7.6 years and the mean age of the first Aspergillus growth in sputum culture was 12.5 ± 6.7 years. Fifty-three patients had Aspergillus growth more than once. At first Aspergillus isolation, 43.4, 37.3 and 21.7 % of the patients had symptoms, physical examination findings, and radiological findings, respectively. At first isolation, *A. fumigatus* was the most common SC of Aspergillus in sputum (76.3%) and 14.5% of these patients required hospitalization. Aspergillus sensitization was diagnosed in 3.6% (n=3) of the patients. Aspergillus colonization was detected in 18.1% (n=15) of all patients and lead to decline in FEV1%, FVC% and FEF25-75% which was not statistically significant in these patients, furthermore. ABPA was detected in 9.6% (n=8) of all patients and lead to statistically significant decline in FEV1% ($p=0.02$); nonsignificant decline in FVC% and FEF25-75%. Aspergillus bronchitis was detected in 43.4% (n=36) of all patients and lead to decline in FEV1%, FVC% and FEF25-75% which was not statistically significant in these patients.

Conclusion: Pulmonary disease due to Aspergillus growth on the airway culture has a diverse spectrum of clinical syndromes in patients with CF. Although ABPA is recognized as the most common Aspergillus associated disorder in CF patients, the clinical significance of Aspergillus colonization and bronchitis may be associated with worse lung functions. However, our study did not show significant deterioration on lung function tests of these groups.

Keywords: Aspergillus, cystic fibrosis, airway culture

[Abstract:0246] PS-180 [Accepted:Poster Presentation] [Tuberculosis]

COPD and Tuberculosis Comorbidity: Diagnosis Problems

Halina Baradzina

Belarusian State Medical University, Minsk, Belarus

Objectives: Chronic obstructive pulmonary disease (COPD) and tuberculosis (TB) are diseases with a high level of disability and mortality. It is known that COPD and TB contribute to the progression of each other. To study the prevalence and effectiveness of COPD diagnosis in patients with tuberculosis.

Methods: A complete retrospective survey of 622 patients (mean age 47.3 ± 2.2 years) with multidrug-resistant tuberculosis (MDR-TB) was conducted. Stage 2- a prospective examination of 46 patients with MDR-TB. Inclusion criteria: over 40 years, no bacterial excretion, no history of COPD. Patients with COPD and TB combination were additionally questioned using the mMRC, CAT.

Results: In a retrospective study, it was found that COPD was only diagnosed in 2.9% of patients with TB (89%-over 40 years). All patients had severe COPD and respiratory failure. Patients with MDR-TB had numerous social and medical risk factors for COPD, which are common to both diseases. In a prospective study diagnosis of COPD was detected in 63% patients with TB ($p=0.000$), and a mild bronchial obstruction was diagnosed in 51.7% of cases ($p=0.000$). The questionnaire showed that clinical examination data did not correlate with the subjective assessment of their condition by patients. According to the mMRC results, 48.3% of patients did not notice problems, 51.7% of patients have only mild degree of dyspnea. According to the CAT questionnaire, the average score was 9.0 ± 1.4 , which indicates a slight impact of dyspnea. Patients with TB and COPD comorbidity could not also objectively assess the frequency and severity of COPD exacerbations, and therefore, using of ABCD classification is not appropriate for this category of patients.

Conclusion: Comorbidity of COPD and TB in patients over 40 years is a common pathology, which unfortunately often remains unrecognized. COPD in patients with MDR-TB is detected only in advanced stages, when serious complications develop and therapeutic possibilities in which extremely limited. The untimely diagnosis of COPD in patients with TB is due to the difficulties of examining patients with bacterial excretion, frequent antisocial life style, a significant underestimation of the severity of their condition by patients. Early diagnosis of COPD among this category of patients is only possible with regular lung function testing.

The results of the questionnaire demonstrated inadequate assessment of their condition by patients who explained poor health, shortness of breath and cough with the presence of TB and a long-term experience of smoking.

Keywords: Tuberculosis, COPD, diagnosis

[Abstract:0248] PS-322 [Accepted:Poster Presentation] [Lung Transplantation]

Examination of Quality of Life in Patients Who are Candidate for Lung Transplantation

İpek Bayraktar¹, Hakan Kitapçı², Hafize Kaya Namazcı¹

¹Koşuyolu High Specialization Training and Research Hospital, İstanbul, Turkey

²Gebze Technical University, Kocaeli, Turkey

Objectives: The aim of this study is to evaluate quality of life in patients who are candidates for lung transplantation.

Methods: The study was conducted on 52 patients that were candidates for lung transplantation. The patients were asked questions on quality of life that were recommended by American National Medicine Center and Beckman Research Institute. The questionnaire consisted of items on the sub-dimensions of physical health, psychological health, social concerns, and mental well-being and on socio-demographic features. The data were collected through interviews performed by nurses.

Results: The obtained data were analyzed by SPSS software and they were evaluated in terms of differences in the sub-dimensions of life quality according to the demographic features of the patients. Considering the findings obtained in the preliminary analysis, there was a significant difference in mental well-being and quality of life for non-smoking participants and a significant difference in mental well-being for participants not drinking alcohol. The mean, standard deviation, and median values of the sub-dimensions of physical health, psychological health, social concerns, and mental well-being were calculated as $3,08\pm,75$, 3,10; $3,08\pm,45$, 3,00; $3,84\pm,42$, 3,88, and $3,39\pm,49$, 3,40, respectively.

Conclusion: According to the findings obtained in the preliminary analysis, social concern is felt more and physical health is felt less for patients.

Keywords: Lung transplantation, quality of life, patient who is candidate for transplantation

[Abstract:0249] EPS-222 [Accepted: E-Poster] [Thoracic Surgery]

Treatment of Secondary Spontaneous Pneumothorax

İbrahim Ethem Özsoy, Mehmet Akif Tezcan, Fatih Gürler

Department of Thoracic Surgery, University of Health Sciences, Kayseri Training and Research Hospital, Kayseri, Turkey

Objectives: A pneumothorax is a collection of air outside the lung but within the pleural cavity. There are two types of pneumothorax: traumatic and atraumatic. The two subtypes of atraumatic pneumothorax are primary and secondary. Secondary spontaneous pneumothorax (SSP) occurs subsequent to an underlying pulmonary disease. Prolonged air leak in secondary spontaneous pneumothorax patients remains one of the biggest challenges for thoracic surgeons.

Methods: Between January 2015 and December 2017, 41 patients who were diagnosed and treated with SSP in our clinic were compiled retrospectively. Age, gender, underlying lung disease, symptoms, diagnosis, treatment type, surgical indication, morbidity, recurrence, mortality and hospital stay of the patients were reviewed.

Results: Of the patients, 35 (85.4%) were males and 6 (14.6%) were female. The mean age was 62.1 ± 11.4 years (43-84 years). The most common pre-existing lung diseases responsible for pneumothorax was COPD (48,7%) and fol-

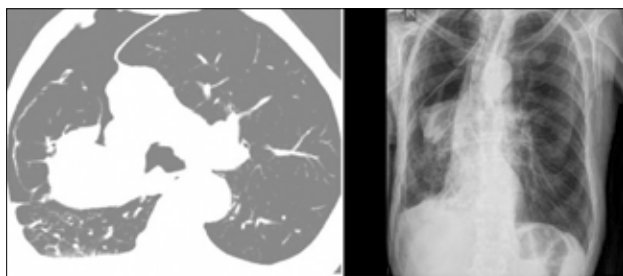


Figure 1. CT Scan of right secondary spontaneous pneumothorax

lowed by bullous emphysema (36.5%). Whereas 28 patients (68.2%) were managed by tube thoracostomy, 8 patients (19.5%) were managed by tube thoracostomy+pleurodesis. Five patients underwent surgery. Operative indications were prolonged air leak (n=4) and recurrence (n=1). The mean hospitalization day was 7.78 ± 4.99 (2-24 days). Hospital mortality was %2.4.

Conclusion: SSP is a condition that requires early diagnosis and treatment. The first treatment option should be tube thoracostomy. In most of patients the appropriate treatment could be achieved with tube thoracostomy. Persistent air leakage was a major surgical indication for SSP. Early surgical treatment reduced postoperative complications for SSP.

Keywords: Secondary spontaneous pneumothorax, COPD, tube thoracostomy

[Abstract:0252] SS-117 [Accepted:Oral Presentation] [Experimental Investigations]

Imiquimod Ameliorates Radiation-Induced Pulmonary Fibrosis

Mustafa Çalık¹, Güler Yavaş², Esin Çelik³, Çağdaş Yavaş², Saniye Göknil Çalık⁴, Zümürüt Ela Arslan Kasdoğan⁵, Mustafa Fevzi Sargon⁶, Yusuf Tolga Şanlı⁷, Hıdır Esme¹

¹Department of Thoracic Surgery, Health Sciences University, Konya Training and Research Hospital, Konya, Turkey.

²Department of Radiation Oncology, Selçuk University School of Medicine, Konya, Turkey

³Department of Pathology, Selçuk University School of Medicine, Konya, Turkey

⁴Emergency and First Aid Program, Vocational School of Health Services KTO Karatay University, Konya, Turkey

⁵Department of Anesthesiology and Reanimation, Health Sciences University, Konya Training and Research Hospital, Konya, Turkey.

⁶Department of Anatomy, Hacettepe University School of Medicine, Ankara, Turkey

⁷Department of Radiation Oncology, Onko Mersin Oncology Center, Mersin, Turkey

Objectives: Radiation-induced lung injury (RILI) is a major dose limiting factor during thoracic irradiation. Clinically RILI is typically divided into two phases: pneumonitis and fibrosis. Imiquimod (I) is an immune response modifier and approved for the treatment of external genital and perianal warts. I stimulates the innate and adaptive immune pathways and induces cytokine production.

The aim of the current study was to evaluate the impact of I-RILI.

Methods: Sixty rats were divided into 6 groups: Group (G) 1 control, G2 radiotherapy (RT) only, G3 and G4 5 and 10 mg/kg I; G5 and G6 RT plus 5 and 10 mg/kg I groups respectively. A single dose of 15 Gy RT was given to both lungs. I was applied intraperitoneally with daily doses, until animals were sacrificed 6 and 16 weeks after RT. Lung tissues were dissected for light and electron microscopy.

Results: The inflammation, fibrosis and transforming growth factor (TGF) - α scores of all study groups were significantly different at 6th and 16th week of RT ($p < 0.001$ for all). We analyzed the RT groups and non-RT groups separately, since the main deterioration in tissue samples were observed in the RT groups. At 6th week of RT, pair-wise comparisons revealed that the inflammation, fibrosis and TGF- α scores of did not significantly different in both RT groups and non-RT groups. Ultrastructural findings of the electron microscopical examination also supported the light microscopical findings. By 16th week of RT inflammation, fibrosis and TGF- α scores we significantly different between G2 and G5 (p values were 0.033, 0.041, and < 0.001 for inflammation, fibrosis, and TGF- α scores respectively), and G2 and G6 (p values were 0.043, 0.002, and < 0.001 for inflammation, fibrosis, and TGF- α scores respectively). Electron microscopy revealed that at 16th week of RT, there weren't any ultrastructural changes in non-RT groups. On the other hand in all RT groups there were vacuoles in the alveolar epithelial cells and capillary endothelial cells. Additionally intercellular and pericellular edema were observed. However the vacuoles were larger and the intercellular edema was more prominent in G2 when compared to the both G5 and G6. When G5 and G6 compared, there weren't any differences with respect to the ultrastructural findings at both 6th and 16th weeks of RT.

Conclusion: Although I did not improve pneumonitis phase of the RILI, I ameliorates radiation-induced lung fibrosis. This finding should be clarified with further clinical studies.

Keywords: Imiquimod, fibrosis, radiotherapy, rat

[Abstract:0255] PS-099 [Accepted:Poster Presentation] [Pulmonary Rehabilitation and Chronic Care]

The Relationship between Health Status, Quality of Life and Physical Activity in Geriatric Individuals with Chronic Obstructive Pulmonary Disease

İsmail Özsoy¹, Buse Özcan Kahraman¹, Gülşah Özsoy², Nursen İlçin¹, Nil Tekin³, Sema Savcı¹

¹Dokuz Eylül University, School of Physical Therapy and Rehabilitation, İzmir, Turkey

²Department of Physical Medicine and Rehabilitation, İzmir Bozyaka Research and Training Hospital, İzmir, Turkey

³İzmir Narlıdere Nursing Home Elderly Care and Rehabilitation Center, İzmir, Turkey

Objectives: Chronic obstructive pulmonary disease (COPD) is a chronic lung disease that is common in geriatric individuals and causes mortality and morbidity. The COPD Assessment Test (CAT) is a valid and reliable test that has been used frequently in recent years to assess health status in this disease. Demonstrating the relationship between health status, quality of life and physical activity in geriatric COPD patients is important in terms of knowing the disease-related effects. The aim of the study was therefore to investigate the relationship between health status, quality of life and physical activity in geriatric individuals with COPD.

Methods: A total of 22 geriatric individuals with stage II-III stable COPD, over 65 years of age, were included in the study. The demographic and spirometric values of the participants were recorded. The health status (CAT), the level of physical activity (Physical Activity Scale for the Elderly (PASE)) and the quality of life (World Health Organization Quality of Life Instrument-Older Adults Module (WHOQOL-OLD)) were assessed.

Results: Participants' the median age was 76 years in the study. The CAT, PASE and WHOQOL-OLD median scores of the participants were 14.00, 61.10 and 53.64 respectively. There was a strong correlation between CAT and PASE ($r=-0.642$, $p<0.001$) and WHOQOL-OLD score ($r=-0.665$, $p<0.001$) in the study.

Conclusion: The relationship between health status, physical activity level and quality of life was found in geriatric individuals with COPD. The health status assessed by CAT is adversely affected by a decrease in physical activity and deterioration in the quality of life in geriatric individuals with COPD.

Keywords: Physical activity, chronic obstructive pulmonary disease, health status, quality of life

[Abstract:0258] SS-036 [Accepted:Oral Presentation] [Respiratory Failure and Intensive Care]

Association of Caregiver Burden and Depression in Caregivers Of Patients with Chronic Respiratory Failure Secondary to Advanced and End Stage Lung Disease

Şehnaz Olgun Yıldızeli, Hüseyin Arıkan, Umut Sabri Kasapoğlu, Derya Kocakaya, Emel Eryüksel, Berrin Ceyhan, Sait Karakurt

Department of Pulmonary and Critical Care Medicine, Marmara University School of Medicine, İstanbul, Turkey

Objectives: Some of the chronic lung diseases are progressive and can lead to end-stage lung disease and respiratory failure. In this patient group, functional capacity is considerably reduced, and assistance is needed to continue daily activities and palliative medical care. Due to the limited number of palliative care centers in our country, most of the patients are receiving this support by their caregivers in their own homes and usually from a family member.

The purpose of this study is to explore the relationship between caregiving burden and depression in care givers of patients with advanced and end stage pulmonary disease.

Methods: Between January 2016 and November 2017 patients admitted to our outpatient clinic were screened. Care givers of patients with hypoxemia and forced expiratory volume in first second (FEV1) <50% or forced vital capacity (FVC) <40%

were included in the study. The burden of care and the Beck depression questionnaires were applied to the primary caregivers of these patients.

Results: A total of 54 patients (19 women) were included in the study. The median age of the patients was 51 years (min 19-max 71). Twenty-four patients (44.4%) were receiving supplemental non-invasive ventilation (NIV) support, while forty-five patients (83.3%) received more than 12 hours of oxygen therapy per day. The mean FEV1 of the patients was 1.5+/-0.5 l, and the 6 minute walking test (6MWT) was 168+/-43 m.

The average age of caregivers was 43.4+/-10.6 years and 48 (88.8%) were female. While the number of caregivers participating care of patient for more than five years was 40 (74.1%), 49 (90.7%) had no prior care experience. When Zarit and Beck scores were explored there was a significant positive correlation with duration of long term oxygen therapy ($r=0.624$, $p<0.001$; $r=0.582$, $p<0.001$) and there was a significant negative correlation with 6MWT ($r=-0.076$ $p<0.001$; $r=-0.692$, $p<0.001$).

Conclusion: In patients with chronic respiratory failure, increased time spent with daily oxygen support poor functional capacity are associated with increasing caregiver burden and depressive symptoms in caregivers. Especially in these patient groups care givers need to be supported socially in order to be able to maintain the quality of the care.

Keywords: Caregiver burden, depression, respiratory failure

[Abstract:0259] PS-286 [Accepted:Poster Presentation] [Respiratory Failure and Intensive Care]

Palliative Care Needs after Chronic Critical Disease: Clinical Experiences

Şehnaz Olgun Yıldızeli, Hüseyin Arıkan, Umut Sabri Kasapoğlu, Emel Eryüksel, Sait Karakurt

Department of Pulmonary and Critical Care Medicine, Marmara University School of Medicine, İstanbul, Turkey

Objectives: Palliative care is the type of care that is customized medical content for cases of serious illness. The concept of chronic critical illness is a newly introduced definition and is defined as a condition that is not a consensus but typically occurs on the ground of chronic illness and requires intensive care admission for more than five days.

The aim of this study is to share our clinical experience on palliative care after chronic critical illness in our intensive care unit.

Methods: Between January October 2017, files of patients hospitalized in our medical intensive care unit (MICU) were retrospectively screened. Patients who stayed more than 5 days in MICU and during admission required tracheostomy and percutaneous endoscopic gastrostomy (PEG) included. Patients' demographic information, source of admission, length of hospitalization (MICU and wards), Charlson comorbidity index (CCI), APACHE II scores, status of caregiver training, complications during intensive care unit admission, discharge sites, rehospitalization, and mortality rates of 30 and 90 days were recorded.

Results: 17 (63%) male and 10 (37%) female patients were included in the study and the mean age was 67.6±14.3 years. Of the 16 cases (59.3%), the first admission was directly to intensive care unit and 11 (40.7%) were to wards. Nine patients (33.3%) had sepsis, 9 patients (33.3%) had aspiration pneumonia, 3 patients (11.1%) had cardiac arrest, 4 patients (14.8%) had cerebrovascular disease and 2 (7,4%) prolonged post-operative admission. Average APACHE II was 28.8±4.8 CCI was 8±0.7. Mean duration of hospitalization in MICU was 26.8±22.8 days and the in the wards was 27.2±13.3 days. Mean duration of caregiver training was 7.1±2.7 days. During the hospitalization 7 (25.9%) of patients developed pressure sores; 9 (33.3%) developed reinfection and 7 (25.9%) had secondary MICU admission. Fifteen patients (55.6%) were discharged home after the follow-up, and 8 patients (29.6%) were discharged to the palliative care center. Seven patients (25.9%) were hospitalized again after discharge and 3 patients (11.1%) died at the end of hospital stay. Thirty-day overall mortality was 18.5%; 90-day overall mortality was found as 25.9%.

Conclusion: The need for palliative care following a chronic critical illness is complicated and mortality is high. In these patients complications and ICU readmissions can be seen. Especially in this group of patients, hospital staff and home care providers should be informed about the complications that may develop after intensive care.

Keywords: Palliative care, chronic critical illness, intensive care

[Abstract:0260] SS-148 [Accepted:Oral Presentation] [Tuberculosis]

Characteristics of Pulmonary Tuberculosis Cases Which are Diagnosed by Histopathologic Method

Gül Erdal Dönmez, Olga Akkan, Merve Hörmet, Aylin Babalık, Fatma Kutluhan, Tülin Kuyucu

Department of Pulmonary Diseases and Thoracic Surgery, MH Health Sciences University Süreyyapaşa Training and Research Hospital, İstanbul, Turkey

Objectives: Tuberculosis (TB) can be confused with many diseases with different radiological and clinical appearances. The aim of this study is to retrospectively evaluate the patients who were not diagnosed by non-invasive or minimally invasive methods and who had undergone surgical treatment.

Methods: 30 pulmonary TB patients who were diagnosed by wedge resection or anatomic resection in our clinics between 2015 and 2017 were retrospectively evaluated.

Results: 7 (%23.3) of our cases were women and 23 (%76.7) were men. The mean age was calculated as 48, 26. 11 (%36.6) of the cases were asymptomatic at the time of first admission and the most common symptom was cough (20%). On radiological examination, 50% of the lesions were in the form of a solitary nodule and the most common location was the upper lobe of the right lung (%28. 6). 25 (%83.3) cases were undergone positron emission tomography (PET-CT). Mean maximum Standard uptake value (SUVmax) of lesions was calculated as 5.48. %70 of the patients were undergone preoperative bronchoscopy and only 4 of them had endobronchial lesions. In the pathologic examination, three of this four cases were reported as nonspecific inflammatory changes. At the time of admission, acid-fast bacilli (AFB) examination in sputum or bronchial lavage couldn't done in the 9 (%30) of the cases. In other cases, sputum and/or bronchial lavage AFB was negative, where as pleural fluid AFB was positive for only 1 case. None of the patients who were directed to the tuberculosis polyclinic after surgery were positive for sputum AFB. However in two patients' sputum and/or bronchial lavage AFB culture which were given at the time of first admission were positive. Wedge resection was performed in 22 patients (%73.3), mediastinoscopy with wedge resection in 6 patients (%20), and lobectomy in 2 patients. In 27 cases, the pathology report was necrotizing granulomatous inflammation. However in 2 cases granulomas with necrosis and coarse calcification were detected. In 1 case, large cell carcinoma and necrotizing granulomatous inflammation were found in different lobes.

Conclusion: Radiologically detected lesions may suggest TB, but none of these radiologic findings are specific to TB. It is often necessary to apply diagnostic surgical methods in undiagnosed thoracic TB lesions. However, when considering cost, mortality and morbidity, detailed clinical evaluation before these procedures is important. In conclusion surgery has an important role at the diagnose of tuberculoma form of TB.

Keywords: Histopathology, diagnosis, tuberculosis

[Abstract:0261] SS-029 [Accepted:Oral Presentation] [Pulmonary Rehabilitation and Chronic Care]

Effectiveness of Multidisciplinary Pulmonary Rehabilitation after Lung Transplantation: Our Central Results

İpek Candemir, Pınar Ergün, Dicle Kaymaz, Seher Satar, Harun Karamanlı, Neşe Demir, Fatma Şengül, Nurcan Egesel

Atatürk Traning and Research Hospital for Chest Diseases and Chest Surgery, Ezurum, Turkey

Objectives: Lung transplantation (L TX) is an important treatment choice for selected patients having end-stage lung disease. With increasing survival rates, the attentions have been directed to treatment targets requiring a multidisciplinary approach such as providing an increase in quality of life, exercising capacity, and daily life activities. The aim of this study is to evaluate the effectiveness of Pulmonary Rehabilitation (PR) program with, ambulatory, multidisciplinary, comprehensive, and directly observed approach in after lung transplantation.

Methods: The data of outpatients who were included in the PR program after L TX between 2012 and 2017 were evaluated

retrospectively. Diagnoses, ages, sexes, and smoking histories of all cases were recorded. The methods used for evaluation were MIP and MEP for respiratory muscle strengths before and after PR; Medical Research Council (MRC) dyspnea scale for dyspnea perception; incremental shuttle walk test (ISWT) and endurance shuttle walk test (ESWT) for exercising capacity; St. George Respiratory Questionnaire (SGRQ) chronic respiratory diseases questionnaire (CRDQ) for health-related quality of life; bioelectrical impedance analysis for body composition; and Hospital Anxiety and Depression Scale (HADS) for psychosocial state.

Results: It was found that 17 of 23 patients completed the PR program and the mean time for beginning the program was 75 ± 15 days after transplantation. The mean age was 47 ± 10 years and 15 patients were male and 2 were female. Bilateral lung transplantation was performed in 5 (29%) patients with COPD, in 6 (35%) patients with IPF, in 2 (11%) patients with histiocytosis-X, in 2 (11%) patients with silicosis, and in 2 patients (11%) with bronchiectasis. While the distances at ISWT was at 23% of the expected rate before PR after L TX, it increased to 36% after PR ($p < 0.001$). Moreover, statistically significant increases were observed at ISWT ($p < 0.001$) and ESWT ($p = 0.005$) values. While there were significant improvements in MIP ($p = 0.001$), MEP ($p = 0.008$), SGRQ ($p = 0.001$), CRDQ ($p < 0.001$), BMI ($p < 0.001$), FFMI ($p = 0.011$), and HADS ($p = 0.001$, $p = 0.002$) values, no significant changes were observed in FEV₁, FVC expected percentage values and MRC scores (Table 1).

Conclusion: This study has demonstrated that restriction in exercising capacity continued after lung transplantation and personal PR program with an hospital-centered, ambulatory, multidisciplinary, comprehensive, and directly observed approach provides improvement in respiratory muscle strength, quality of life, body composition, and psychosocial state in addition to exercising capacity in patients performed lung transplantation. It was concluded that the patients who were evaluated to be late for attending the PR program after L TX according to literature should be directed early after discharge from hospital.

Keywords: Lung transplantation, pulmonary rehabilitation, exercising capacity

Table 1. Parameters recorded before and after PR

	Before PR	After PR	p
FEV1 %	64±22	68±25	
	65 (18:104)	67 (18:122)	0.241
FVC %	58±20	62±21	
	58 (24:102)	64 (24:110)	0.374
MIP cm H ₂ O	74±26	100±26	
	63 (50:132)	90 (50:137)	0.001
MEP cm H ₂ O	100±29	116±27	
	100 (55:171)	113 (81:167)	0.008
MRC	2±1	1.8±1	
	2 (0:4)	2 (0:4)	0.102
BMI kg/m ²	22±3	24±3	
	23 (15:27)	25 (18:28)	<0.001
FFMI	18.3±1.8	18.6±1.9	
	19 (14:20)	18.2 (16:22)	0.011
ISWT meter	274±130	377±107	
	210 (100:520)	360 (160:560)	<0.001
ESWT minute	8±6	16±6	
	7 (2:20)	20 (4:20)	0.005
CRDQ	51±22	26±14	
	51 (18:100)	24 (10:63)	0.001
KSHA	83±20	108±12	
	80 (45:113)	111 (78:122)	<0.001
ANXIETY	10±1	7±1	
	10 (7:12)	7 (7:11)	0.001
DEPRESSION	9±1	7±1	
	9 (7:13)	7 (7:11)	0.002

[Abstract:0262] EPS-207 [Accepted: E-Poster] [Thoracic Surgery]

The Reasons for Cancellations on the day of Operation in an Education Hospital

Serkan Bayram, Onur Derdiyok, Serda Kanbur, Volkan Baysungur, Çağatay Tezel

Clinic of Chest Surgery, Süreyyapaşa Chest Diseases and Chest Surgery Training and Research Hospital, İstanbul, Turkey

Objectives: The cancellations of planned operations on the day of operation cause the times of operating rooms not to be used effectively and also waste of resources. Moreover, with prolonged hospitalization and repeated pre-operative preparations, they create logistic and financial burden related to lost-time and missed opportunity costs. These cancellations also lead to disturbance in patients and their families. This study was planned for evaluating the reasons for the cancellations of elective surgeries on the day of operation in a 40-bed state hospital.

Methods: The list of operations was prospectively evaluated in a 10-month period (August 1, 2016-August 1, 2017). All

patients planned to undergo an elective surgery as of August 2016 were included in the study. The numbers of cancelled operations and the reasons for cancellations were documented.

Results: In the study period, 1439 elective surgeries, including 87 operations cancelled on the day of operation (6.04%), were planned. It was detected that 55 of 87 cancelled cases were potentially preventable. The most common causes of cancellations were hospital-related (39 cases, 44.8%), patient-related (31 cases, 35.6%), and physician-related (17 cases, 19.5%), respectively.

Conclusion: It is suggested in this study that most of cancellations are evitable and related to hospital. It was found that cancellation rate lower than 2.2% could be obtainable on the day of operation. It has been revealed that the rate of cancellation can be reduced by doing necessary preparations for the day of operation and giving necessary information to patients.

Keywords: Chest surgery, reasons for cancellations, surgery

[Abstract:0267] PS-215 [Accepted:Poster Presentation] [COPD]

Is Peripheral Eosinophilia a Predictor of Mortality in Patients with COPD Exacerbations? What Are the other Predictors of Mortality?

Meltem Ağca¹, Reyhan Yıldız¹, Cüneyt Saltürk², Fatma Tokgöz Akyıl³, Tülin Sevim¹

¹Department of Pulmonology, Health Sciences University, Süreyyapaşa Chest Diseases and Thoracic Surgery Training and Research Hospital, İstanbul, Turkey

²Respiratory Intensive Care Unit, Süreyyapaşa Chest Diseases and Thoracic Surgery Training and Research Hospital, İstanbul, Turkey

³Clinic of Pulmonology, Çanakkale State Hospital, Çanakkale, Turkey

Objectives: Eosinophilic and non-eosinophilic inflammation of COPD exacerbations have different reported prognoses. There are few studies of the relationship between eosinophil count and long-term survival after COPD exacerbations.

The primary objective of this study is to analyze whether peripheral eosinophilia is a determinant of long-term survival after COPD exacerbations along with other demographics and laboratory values. The secondary objective is to compare the characteristics of eosinophilic and non-eosinophilic COPD exacerbations.

Table 1. Baseline characteristics of severe copd patients with acute exacerbations in non-survivors and survivors

	All patients (n=410)	Nonsurvivor (n=79)	Survivor (n=331)	p
Sex, n (%)				
Male	283 (69)	62 (78)	221 (67)	
Female	127 (31)	17 (22)	110 (33)	0,043
Smoking history, n (%)				
Non smoker	69 (18)	11 (15)	58 (18)	
Ex-smoker	211 (56)	44 (61)	167 (55)	0,66
Smoker	53 (14)	8 (11)	45 (15)	
Biomass fuel exposure	45 (12)	9 (13)	36 (12)	0.51
Charlson comorbidity Index, (mean±SD)	5,20±1,68	5.72±1.8	5.08±1.6	0.002
LTOT, n (%)	183 (44.6)	36 (45,6)	147 (44,4)	0.47
Home NIV, n (%)	86 (21)	16 (20.2)	70 (21.1)	0.86
Number of AECOPD within 1 year of prior hospitalization (mean±SD)	3,48±4.5	4.42±5.9	3.26±4.1	0.040
Number of AECOPD within 6 month of discharge, (mean±SD)	Number of AECOPD within 6 month of discharge, (mean±SD)	1.25±2.1	1.74±3.3	0.22
	1.64±3.1			

Abbreviations: SD, standard deviation; LTOT, long-term oxygen therapy; NIV, noninvasive ventilation; AECOPD, acut exacerbation

Methods: The current study is a retrospective, observational single-center study. Between January 2015 and October 2016, 410 hospitalized patients with a diagnosis of COPD exacerbation were included in the study. Patients' demographic data, baseline complete blood count, albumin, C-reactive protein, arterial blood gas values. The Charlson comorbidity index (CCI) was calculated for all patients. All admissions to the hospital, to either the pulmonary clinic or emergency department with respiratory symptoms, one year prior to hospitalization and during the first six months of discharge were investigated. Survival status in 6 months after discharge was investigated.

COPD exacerbations were grouped as eosinophilic ($\geq 2\%$) and non-eosinophilic ($< 2\%$) and the recorded parameters were compared. Mortality analysis was performed for all patients.

Results: Of all the 410 patients included in the study, 69% were male and the mean age was 69 (37-92). The mean CCI was 5.2 ± 1.7 and mean length of hospital stay was 6 (1-26) days.

Eighty-six (21%) patients were grouped as eosinophilic. Age, gender, corticosteroid treatment during hospitalization, length of hospital stay, and hospital admissions before and after the baseline admission were similar between the groups ($p > 0.05$). The six-month mortality was 19% ($n=79$) of this group.

Advanced age, male gender, and higher CCI were found to increase mortality ($p=0.01$, $p=0.04$ and $p=0.02$, respectively). Patients who did not survive 6-month had significantly lower hemoglobin and albumin values ($p=0.001$, $p=0.001$; respectively). Admissions with COPD exacerbations in one year prior to the baseline hospitalisation were significantly less frequent in patients who survived 6 months ($p=0.04$). Eosinophilic patients' mortality was significantly lower compared to non-eosinophilic patients ($p=0.004$).

In multivariate analysis, independent risk factors for mortality were advanced age (hazard ratio [HR]: 1.030; CI: 1.008-1.054, $p=0.009$), peripheral eosinophilia (HR: 0.415; CI: 0.199-0.863, $p=0.018$) and male gender (HR: 1.765; CI: 1.023-3.045, $p=0.041$).

Conclusion: Peripheral eosinophilia was not found to correlate with hospital admissions and exacerbation rates in COPD exacerbations requiring hospitalization. However, eosinophilia strongly correlated with lower mortality in these patients. Advanced age and male gender were found other independent predictors of higher mortality. Closer monitoring may be required in these patients.

Keywords: Chronic obstructive pulmonary diseases, exacerbation, mortality, peripheral eosinophilia

Abbreviations: SD, standard deviation; LTOT, long-term oxygen therapy; NIV, noninvasive ventilation; AECOPD, acute exacerbation

Table 2. Multivariate analysis of 6 month mortality

Factor	Hazard ratio	95%CI	p
Age	1.030	1.008-1.054	0.009
Sex	1.765	1.023-3.045	0.041
Co-morbidity	1.004	0.998-1.010	0.16
Eosinophilia	0.415	0.199-0.863	0.018
LTOT	0.955	0.581-1.670	0.95
Domiciliary NIV	0.848	0.549-2.075	0.84

Abbreviations: Eosinophilia, peripheral eosinophilia $\geq 2\%$; LTOT, long-term oxygen therapy; NIV, noninvasive ventilation

[Abstract:0270] PS-171 [Accepted:Poster Presentation] [Tuberculosis]

Influence of Sources of Infection from Epidemic Focus on Morbidity of Tuberculosis in Children and Adolescents

Irada Akhundova, Agigat Kadirova, Aygun Hajjaliyeva, Ilham Gasimov

Research Institute of Lung Diseases, Baku, Azerbaijan

Objectives: The high incidence of tuberculosis among children from the outbreaks of tuberculosis infection continues to be an acute problem. Children from contact with tuberculosis patients are often infected with tuberculosis pathogens, which the spectrum of drug resistance to antituberculosis drugs fully or partially coincides with the resistance spectrum at the source of infection. To assess the impact of sources of infection from epidemic focus on the development of tuberculosis in children and adolescents.

Methods: 161 cases history of the patient for 2016 from the children's department of the Scientific Research Institute of Lung Diseases were analyzed. The average age of children is between 3 and 18 years. 125 (75%) of the patients were from the focus of tuberculosis infection, 2 (1.6%) patients from 125 had resistance for antituberculosis drugs. The survey included the collection of the results of anamneses, clinical-laboratory (GeneXpert), instrumental research methods. The sensitivity spectrum of mycobacteria isolated by patients with Drug Resistance (DR) tuberculosis was fully coincides with the resistance spectrum at the source of infection.

Results: All children with DR tuberculosis (1.6%) were from prolonged contact with patients with chronic and relapsing forms of drug-resistant tuberculosis. Tuberculosis in these children was characterized by the prevalence of the process (with the defeat of two or more segments of the lungs, with bilateral processes with multiple cavities.) The coincidence of the spectrum of DR of micobacteria Tubrculosis to antituberculosis drugs with the source was noted in the all of children. Also for tuberculosis caused by drug-resistant strains of mycobacterium tuberculosis, are characterized by: acute onset of the disease, severe intoxication and continuously progressive course of the disease.

Conclusion: For tuberculosis caused by drug-resistant strains of mycobacterium tuberculosis characteristically acute onset of the disease, intoxication and continuously progressive course of the disease.

This work was supported by the Science Development Foundation under the President of the Republic of Azerbaijan- Grant ² EIF-KEPTL-2-2015-1 (25) -56/40/3

Keywords: Tuberculosis, source contact, children, adolescents

[Abstract:0271] PS-242 [Accepted:Poster Presentation] [Environmental and Occupational Lung Diseases]

Occupational Asthma of Carpenter: Case Report

Seher Kurtul, Nejdije Mazican, Zeynep Doğrul, Meral Türk

Department of Public Health, Division of Work Health and Occupational Disease, Ege University School of Medicine, İzmir, Turkey

Occupational asthma is a disease characterized by variable airflow limitation and/or airway hyperresponsiveness depending on the causes and circumstances specific to a particular occupational environment (a non-business warning is not responsible). For carpenters; there are mainly wood dust, mold fungi, insecticide, fungicide, adhesive, paint and solvent exposure. Respiratory diseases such as occupational asthma, chronic bronchitis, hypersensitivity pneumonia, sinonasal cancer, lung cancer can be seen in carpenters depending on these exposures. For carpenters; the various wood dusts, formaldehyde and paints containing diisocyanate are agents that cause asthma.

A 35-year-old male patient had complaints of shortness of breath, cough, sputum production for 3 years. The patient, who worked as a packing worker in furniture manufacturing for 8 years and had no smoking history, was taking bronchodilator

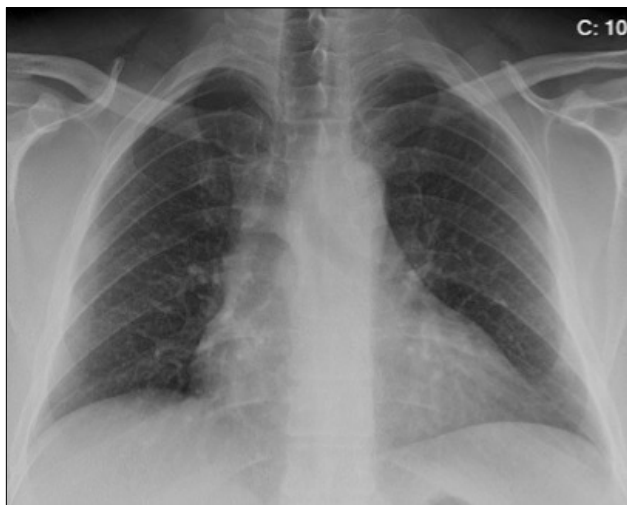


Figure 1. PA Chest X-ray

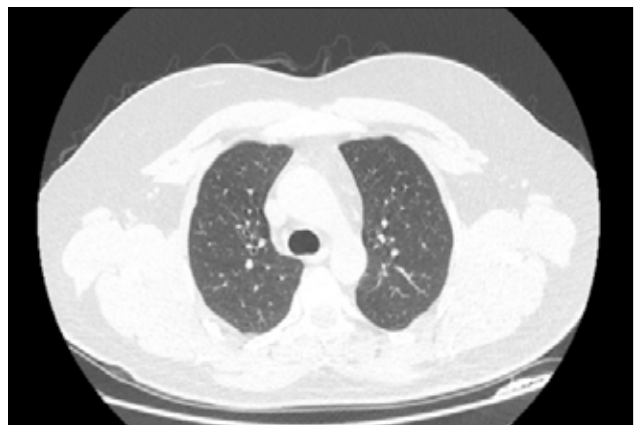

Figure 2. HRCT

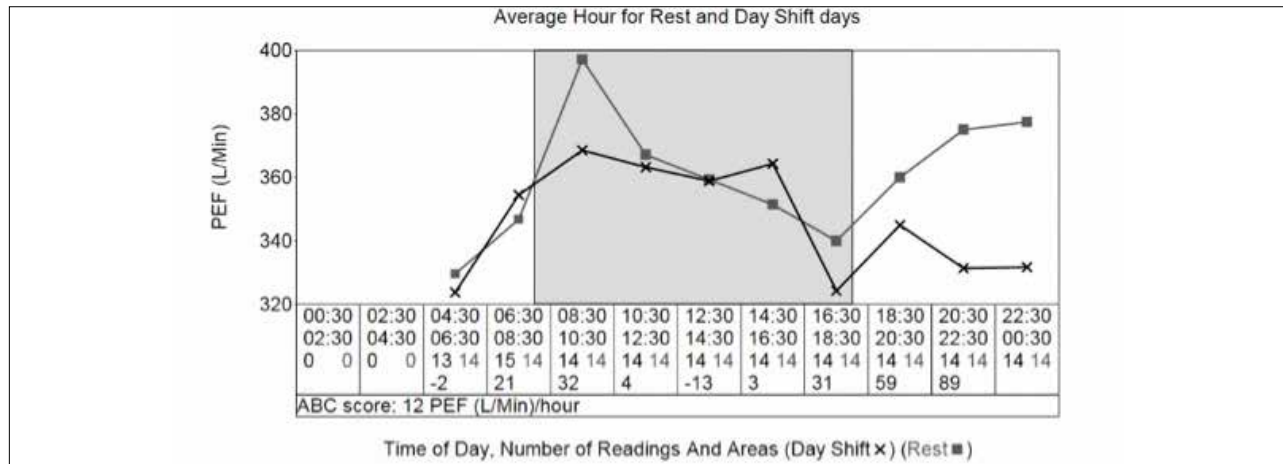


Figure 3. PEF Records

treatment with asthma bronchiale diagnosis for 3 years. Bilateral expiration was determined to be prolonged in the respiratory system examination. Routine hemogram and biochemistry tests were within normal limits. In the functional evaluation of respiration; FEV1: 2.44L (64%), FVC: 3.40L (75%), FEV1/FVC: 72%, PEF: 7.77L/sec (86%) and post bronchodilator test was positive. There was an increase in bilateral bronchovascular appearance in PA chest X-ray. High-resolution computed tomography (HRCT) showed nonspecific millimetric nodules in the anterior segment of the right upper lobe of the lung, and fibro atelectatic parenchyma in the middle lung of the right lung. In skin prick test; weed and grass antigens, alder, birch tree, hazelnut, hornbeam, ash tree, olive tree was determined a positive reaction against antigens. Total IgE, specific IgE mix multiple allergen and specific IgE grass panel was detected at high levels. After long-acting bronchodilators were discontinued, the patient was followed up for 4 weeks which was made of PEF records for every 2 hours. PEF results entered the OASYS system and were reported as highly probable occupational asthma. The patient was assessed as wood-dust-related occupational asthma. It has been suggested to use his asthma treatment regularly and keep away from his work environment.

Employees in the furniture sector are a high-risk occupational group in terms of asthma. The termination of exposure after diagnosis is important for lung health. For this reason, it is necessary to make proper environment ventilation of the carpenter's workplace, to use personal protective equipment suitable for their job, to make regular measurements of workplace and periodic examinations.

Keywords: Occupational asthma, wood dust, carpenter

[Abstract:0275] EPS-030 [Accepted: E-Poster] [Clinical Problems - Diffuse Parenchymal Lung Disease]

Cryptogenic Organizing Pneumonia: Our Clinical Experience with 9 Patients

Songül Özyurt¹, Neslihan Özçelik²

¹Department of Chest Diseases, Recep Tayyip Erdoğan University School of Medicine, Rize, Turkey

²Department of Chest Diseases, Kaçkar State Hospital, Rize, Turkey

Objectives: Cryptogenic organizing pneumonia (COP) is a rare but highly characteristic clinicopathological condition in lung diseases. Histopathologically diagnosed with fibroblasts in alveolar ducts and alveoli, granulation tissue buds formed by collagen and fibrinous exudates

Methods: In this study, we retrospectively analyzed 9 patients who were diagnosed as COP histopathologically. Clinical, radiological findings, respiratory function tests, diagnostic method, treatment and follow-up results were evaluated.

Results: Of the 9 patients; three (33.3%) were female, 6 (66.7%) were male. The mean age was 65.44±15.26 (min36-max 869). 44% (4) of the patients never smoked, 33.3% (3) left, 22.2% (2) were still smoking. The major symptoms were; 7 patients with shortness of breath, 3 patients had fever, all patients had cough, 8 patients had malaise, and 4 patients had sputum. For diagnosis 11.1% (1) bronchoscopic biopsy, 55.6% (5) CT-guided fine needle aspiration biopsy and 33.3% (3)

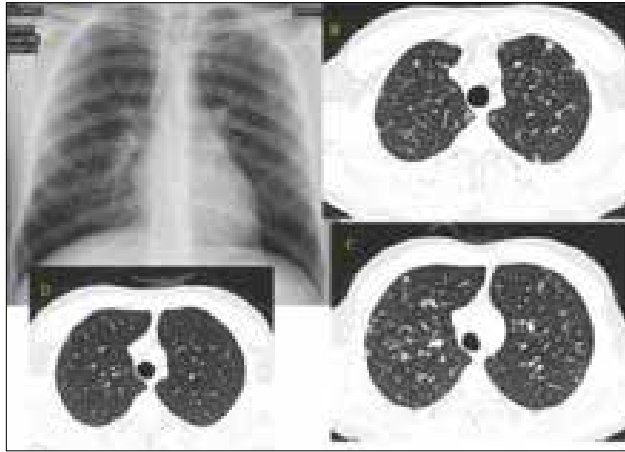


Figure 1. Radiological Findings

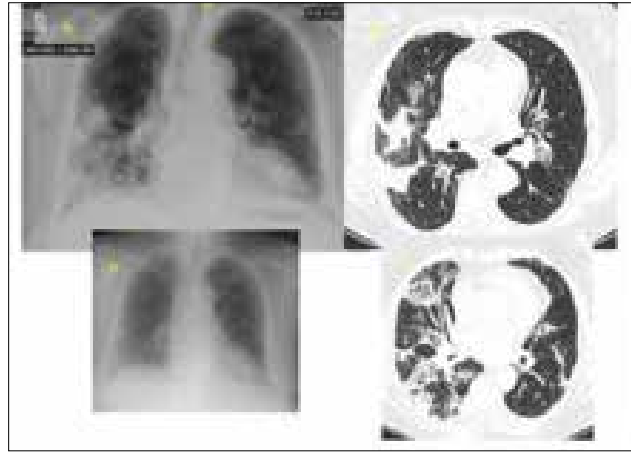

Figure 2. Radiological Findings

open lung biopsies were performed. When additional diseases were examined, there were no comorbidities in 4 patients (44.4%), two patients had hypertension, one patient had HT+DM, and one patient had COPD + DM. In laboratory values of patients; sedimentation average 69.22 mm/h \pm 32.75 (min 26- max 115), CRP; 2.83 (\pm 1.63, min 1.32- max 5.65), the other laboratory values were normal. PFT; 3 patients were normal, 1 patient was obstructive, and 5 patients were restrictive. DLCO could not be done. DLCO test could not be performed by reason of technical failure. Saturation values were normal. Radiological examination was performed in all patients with HRCT. There was consolidation in 5 patients, consolidation+ ground glass opacity in 2 patients, mass in 1 patient, reticulonodular infiltration in 1 patient. Macrolide and follow-up were used in 1 patient for 1 month, and corticosteroid was used in 8 patients. The average follow-up period was 5.67 \pm 1 month. One patient (11.1%) resulted in fibrosis and the other 7 patients were treated (77.8%). There was no problem with their follow-up. One patient (11.1%) developed a recurrence. Steroid therapy started again.

Conclusion: COP is a rare clinicopathologic condition that can be typical clinical and radiological findings, but there are many diseases on differential diagnosis list. Histopathologic diagnosis is almost always needed. A good history and systemic examination is necessary to determine whether it is idiopathic or secondary COP. Corticosteroids are often used in therapy for a long time and often respond very well.

Keywords: Cryptogenic Organizing Pneumonia, diagnosis, radiological findings

[Abstract:0277] PS-210 [Accepted:Poster Presentation] [Asthma and Allergy]

In Adult Patients with Mite and/or Pollen Induced Allergic Rhinitis, Eosinophil Levels and Bronchial Hyperreactivity Can Be Reduced By Subcutaneous Immunotherapy (SCIT) Treatment?

Fatma Merve Tepetam¹, Cihan Örcen¹, Halime Pençe², İsmet Bulut¹

¹Department of Sleep Laboratory, Health Sciences University, Süreyyapaşa Chest Diseases and Thoracic Surgery Training and Research Hospital İstanbul, Turkey.

²Department of Medical Biochemistry, Health Sciences University School of Medicine, İstanbul, Turkey.

Objectives: Allergic rhinitis can be associated with bronchial hyperreactivity (BHR), and creates an increased risk for asthma development. It was demonstrated that not only the development of asthma, but also reactivity to methacholine bronchoprovocation test (BPT) can be reduced with immunotherapy especially in children. For adults there were no enough study about preventive or reductive effect of subcutan immunotherapy (SCIT) comparing with traditional medical treatment. We aimed in the study to investigate the effect of SCIT on BHR and eosinophil level as well as clinical effect after at least 1 year of treatment.

Methods: Retrospective case control study was conducted in our immunology and allergy department. Recorded data consisted with the patients who are tested for evaluating BHR with symptoms of allergic rhinitis with or without asthma before

Table 1. Symptom, eosinophil and PD20 changes of groups after treatment

	Baseline SCIT group (n=40)	After SCIT (mean duration: 34,6 5 mounth)		Baseline Control Group (n=28)	After Medical treatment (mean duration: 30,10 mounth)	
			p value			p value
^Symptom score	15.26±3.82	6.81±4.58	<0.001	10,65±5,57	8.96±5.31	0.061
*Eosinophil Level ¹ (cell/mL)	275±200 (260)	256±211 (200)	0.023	200±130 (110)	170±110 (100)	0.59
^Eosinophil ¹ (%)	4.15±2.55	3.45±2.35	0.057	2.79±1.23	2.58±1.43	0.72
*PD20 (mg/mL)	3.06±3.17 (1.85)	5.34±4.22 (3.76)	0.078	5.98±3,54 (5.53)	5.89±4.96 (5.71)	0.85

Abbreviations: SCIT: Subcutaneous Immunotherapy, PD20: Metacholine challenge proved to be 20% lower in FEV1. ¹: only those with hemogram data were included. ^: Mean±SD values were given for normal distribution and paired t test was used for posttreatment change. *: Median values were given besides the mean±SD due to abnormal distribution, Wilcoxon signed rank test was used for posttreatment change analysis. p <0.05 was considered statistically significant.

planned subcutan immunotherapy who have mite and/or pollen allergy. While SCIT group was selected from the data receiving SCIT for at least 1 year besides drugs, control group was selected from the data to whom thought to begin SCIT but waived because of does not have enough time, moved out, scare of adverse reaction or economic status; so only taking drugs. Patients with severe asthma or forced expiratory volume in 1 second less than 70% of predicted, malignancies, autoimmune, rheumatological diseases, causes of other BHR and patients who previously received SCIT were excluded. Groups were compared in terms of changes in symptom score, eosinophil level, drug consumption, BHR, and new aeroallergen sensitization after 1-4 year (mean: 32.77 mounth) of treatment.

Results: In our study, SCIT group include 40, control group include 28 patients. There were no statistical signficiance in terms of mean age, sex, smoking history, duration of follow-up, frequency of asthma, mite and/or pollen sensitization rate between the groups. In only SCIT group, while symptom score, eosinophil level were significantly decreased, PD20 level was increased (Table1). But there were no statistical significance between the groups as number of drug consumption per mounth and new sensitization- desensitization rate. While the percentage of patients with positive BHR (PD20<8 mg/mL) decreased in SCIT group, increased in the control group (Figure 1). The percentage of patients with progressive disease (decreased PD20 levels or recently formed PD20<16 mg/mL) was significantly higher in controls (70% to 38.1% p=0.046).

Conclusion: Although randomized prospective controlled studies with more patients are needed, we showed that in adult patients, SCIT reduced BHR while raising PD20 value, also decreased eosinophil levels.

Keywords: Bronchial hyperreactivity, eosinophil, subcutan immunotherapy

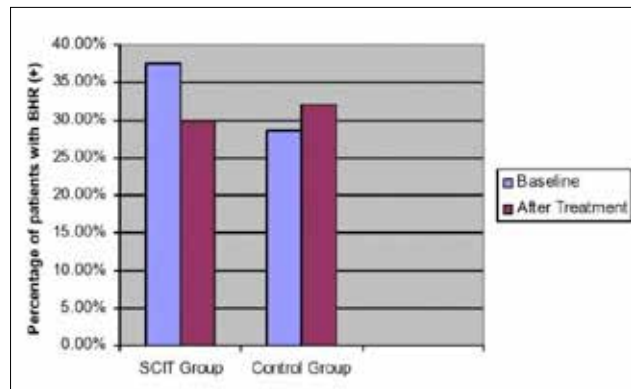


Figure 1. Changes in BHR (+) patient ratio after treatment in the SCIT and control group

SCIT: Subcutaneous Immunotherapy BHR: Bronchial Hyperreactivity McNemar test; p>0.05

[Abstract:0278] PS-199 [Accepted:Poster Presentation] [Pediatric Pulmonary Diseases]

Evaluation of Microorganisms and Their Resistance in The Respiratory Tract Specimens of Patients with Cystic Fibrosis and the Correlation of Antibiotic Resistance with Clinical Findings and Pulmonary Function Tests

Mukaddes Kılıç Sağlam¹, Canan Baydemir², Zeynep Seda Uyan³

¹Department of Pediatrics, Kocaeli University School of Medicine, Kocaeli, Turkey

²Department of Biostatistics and Medical Informatics, Kocaeli University School of Medicine, Kocaeli, Turkey

³Division of Pediatric Pulmonology, Kocaeli University School of Medicine, Kocaeli, Turkey

Objectives: Antibiotics have an important role in the treatment of cystic fibrosis (CF) lung disease. Antibiotic resistance increases in patients with CF. The aim of this study was to determine whether there is a change in antibiotic resistance and antibiotic susceptibility of respiratory tract specimens of CF patients and to evaluate the relationship between the antibiotic resistance and patients' clinical status and pulmonary function tests.

Methods: CF patients followed at our pediatric pulmonology clinic who had significant microorganisms in cultures taken from the respiratory system from August 2010 through December 2016 were included in the study. The clinical and laboratory findings of the patients were analyzed retrospectively. The culture results and the antibiotic susceptibility data were collected from the hospital's automation system.

Results: In this study, 333 respiratory cultures taken from 39 CF patients were analyzed. MSSA was isolated from 122 cultures (31%), *P. aeruginosa* from 97 cultures (24.7%) and MRSA from 22 cultures (5.6%). While MSSA and MRSA incidence increased from 2010 to 2016, *Pseudomonas aeruginosa* and other microorganisms' incidence didn't increase in years. Multidrug-resistant (MDR) -MSSA and MDR-*P. Aeruginosa* incidence didn't change, but MRSA incidence increased in years. There was a significant relationship between antibiotic resistance development and acute pulmonary exacerbations, pulmonary examination findings, loss in weight and height percentile. As the antibiotic resistance increased, FEV1, FVC, FEV1 / FVC, PEF, FEF25-75 were significantly decreased. The use of azithromycin or inhaled antibiotics (in the last 6 months, last year, at any time) and the use of oral antibiotics in the last three months were not associated with the development of antibiotic resistance.

Conclusion: Antibiotic resistance, especially multi-drug resistance, is a major problem in CF. Since pulmonary disease remains the leading cause of morbidity and mortality in patients with CF, it is important to take respiratory tract cultures with 3-months intervals and at the time of acute pulmonary exacerbation in CF patients and to give rational antibiotic treatment (correct antibiotic, correct pathway, correct and effective dose, correct duration) according to the culture results.

Keywords: Antibiotic resistance, cystic fibrosis, microorganism

[Abstract:0279] PS-107 [Accepted:Poster Presentation] [Pulmonary Rehabilitation and Chronic Care]

The Effects of Core Stabilization Exercises on Respiratory Functions in Adolescent with Substance Use Disorder: Randomized Controlled Study

Rüstem Mustafaoğlu¹, Rengin Demir², Arzu Çiftçi³, Zerrin Yiğit²

¹Department of Neurological Physiotherapy and Rehabilitation, Division of Physiotherapy and Rehabilitation, İstanbul University, Faculty of Health Sciences, İstanbul, Turkey

²Department of Cardiology, İstanbul University Institute of Cardiology, İstanbul, Turkey

³Department of Neurology and Neurosurgery, Child and Adolescent Drug and Alcohol Dependence Treatment Center (CEMATEM), Bakırköy Prof. Dr. Mazhar Osman Mental Health and Neurological Diseases Training and Research Hospital for Psychiatry, İstanbul, Turkey

Objectives: The use of substance in the world and in our country has been increasing in recent years. This increase is particularly rapid in adolescence. Studies have reported that prolonged use of the substance may lead to airway inflammation and infection leading to chronic bronchitis, a decrease in FVC and FEV1 values. Core stabilization exercises activate the trunk muscles and stabilize the spine and abdominal wall. Contraction of the diaphragm and transverse abdominal muscles helps to increase breathing by increasing abdominal pressure. The aim of our study to investigate the effects of core stabilization exercises on respiratory functions in adolescents with substance use disorder.

Methods: The study sample comprised of 15-18 year-old male. Participants were required to be in-residence at the treatment center and meet DSM-V criteria for substance use disorder in Bakırköy Prof. Dr. Mazhar Osman Mental Health and Neurological Diseases Training and Research Hospital for Psychiatry, Neurology and Neurosurgery; Child and Adolescent Drug and Alcohol Dependence Treatment Center in İstanbul. Participants were randomly assigned to exercise (n=25) and control (n=24) groups. In addition to the routine rehabilitation program applied at service, the exercise group performed core stabilization exercises combined with deep breathing for 6 weeks, 2 days a week, 45-60 minutes a day. The control group participated in aerobic exercises under supervision for 6 weeks, 2 days a week, for 45-60 minutes per day in addition to the routine rehabilitation program. Participants' respiratory functions were assessed by portable MIR Spirobank II before and after training.

Table 1. Comparison of pulmonary function parameters of the participants

	Baseline Mean±SD	After Training Mean±SD	p*	Effect Size	p#
Exercise Group	3.92±0.57	4.29±0.61	0.001	0.64	0.001
Control Group	4.10±0.80	4.15±0.82	0.205	0.05	
FEV1 (L)					
Exercise Group	3.64±0.59	4.04±0.67	0.001	0.66	0.044
Control Group	3.77±0.67	3.94±0.54	0.061	0.23	
FEV1/FEVC (%)					
Exercise Group	93.11±7.42	94.41±7.51	0.409	0.17	0.301
Control Group	94.45±5.45	93.94±4.95	0.455	0.09	
PEF (L/sec)					
Exercise Group	6.19±1.66	8.03±1.59	0.001	1.10	0.001
Control Group	6.76±1.56	7.01±1.70	0.003	0.15	
FEF%25-75 (L/sec)					
Exercise Group	4.33±0.94	4.98±0.96	0.001	0.69	0.080
Control Group	4.63±0.60	4.93±0.84	0.088	0.48	

FVC: Forced Vital Capacity; FEV1: Forced Expiratory Volume in 1 second; FEV1/FVC: Tiffeneau index; FEF 25-75%: Forced Expiratory Flow at 25-75% of the pulmonary volume; PEF: Peak Expiratory Flow; SD: Standard Deviation; CI: Confidence Interval; L: liter; sec: second * Paired Sample T-test; p < 0.05 # Independent Sample T-test, p < 0.05

Results: The mean age of the exercise and control groups was 16.7 and 16.8 years, respectively. The duration of substance use was found to be 44.8 months in the exercise group and 46.6 months in the control group. The participants' last time to use substance was 10.4 days in the exercise group and 9.5 days in the control group. There was no statistically significant difference between groups in spirometric parameters at baseline. There was statistically significant improvement in FVC, FEV1, FEF25-75% and PEF parameters according to baseline values after 6 week core stabilization exercise program ($p < 0.001$). In the control group, only PEF value was found to be statistically significant ($p = 0.003$) after six weeks training. Compared to the control group, FVC, FEV1 and PEF values were statistically significant in the exercise group after 6 week ($p < 0.05$).

Conclusion: Core stabilization exercises have been shown to be an effective and feasible exercise method for improving respiratory function in adolescents who are receiving substance abuse treatment. We believe that the addition of exercise to substance use disorder individuals treatment program will provide additional benefits.

Keywords: Substance use disorder, core stabilization exercises, respiratory functions, rehabilitation

[Abstract:0280] EPS-195 [Accepted: E-Poster] [Thoracic Surgery]

Elastofibroma Dorsi: Analysis of 21 Cases

Hakan Keskin, Makbule Ergin, Sermin Tayfun, Levent Dertsiz

Department of Chest Surgery, Akdeniz University School of Medicine, Antalya, Turkey

Objectives: Elastofibroma dorsi (ED) is a rarely seen benign soft tissue tumor. It was defined as a benign fibroblastic/myofibroblastic tumor in the classification of soft tissue tumors by the World Health Organization in 2002. In this study, 21 patients with the diagnosis of ED, who were operated between 2014 and 2017, were retrospectively examined with literature.

Methods: The mean age of the patients was 59,3±4,9 years and the female/male ratio was 19/2. It was found that 2 male patients diagnosed with ED had no active complaint and the mass was removed while performing cancer surgery. The mass was bilateral in 8 patients, right-sided in 11 patients, and left-sided in 2 patients. Considering their dominant extremities, the side of mass and the side of dominant extremity were different only in 2 patients. With regard to their familial histories, only 2 patients mentioned the presence of a similar disorder in their families. It was detected that, in 4 asymptomatic patients, mass was incidentally found during thoracotomy that was performed for another reason and it was removed (Figure 1-3).

Results: Because ED is a rare pathology, there are no clear data about its pathogenesis, but several theories have been proposed. 1. Familial transmission. Only 2 of our patients stated that their families had a similar disease. However, it should be kept in

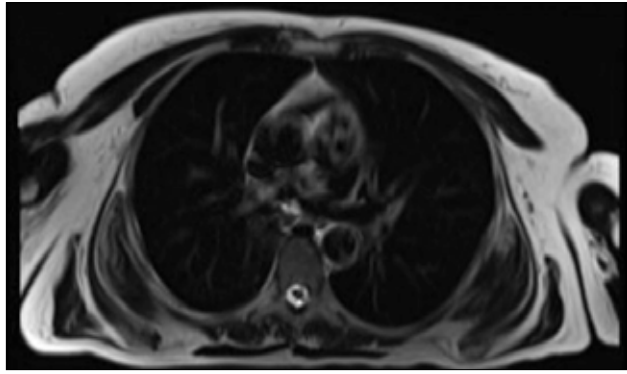


Figure 1. Magnetic resonance image of patient diagnosed with bilateral elastofibroma

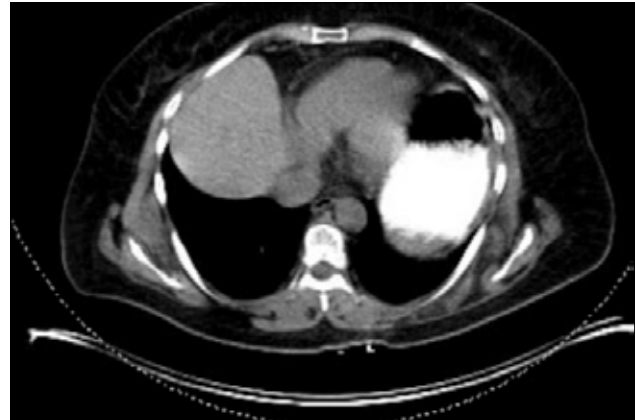

Figure 2. Elastofibroma found in the patient through positron emission tomography performed due to bronchial cancer

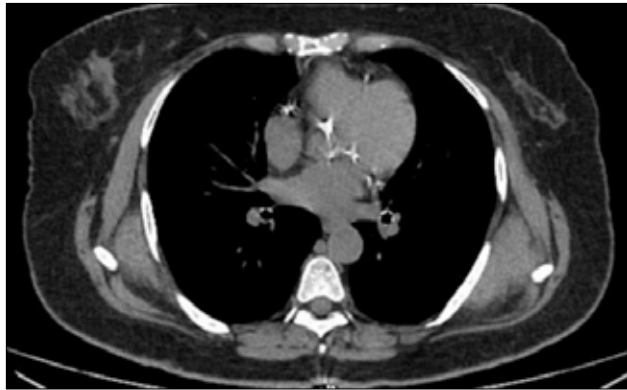


Figure 3. Thoracic tomography image of the patient operated for bilateral elastofibroma

mind that ED patients are generally not diagnosed because most of them are asymptomatic.

2. Reactive hyperproliferation of fibroelastic tissue due to microtraumas. The presence of patients with bilateral ED and particularly those whose disease is not located in the side of their dominant extremities weakens this hypothesis. Age-related vascular insufficiency and secondary degeneration of elastic fibers. The mean age in the study supports this thesis; however, a finding related to vascular insufficiency was not found in any patient. ED primarily occurs after the 5th decade and the female/male ratio is 7/1.

ED is generally asymptomatic. Patients generally consult to hospital due to the complaints of pain occurring with shoulder movements and swelling felt under the scapula.

In physical examination, ED is typically found as masses that are not adherent to the skin over them but attach to the chest wall under them. Mass is noticed in shoulder abduction more easily. Lipomas, vascular malformations, sarcoma, neurofibroma, and metastatic tumors should be considered in the differential diagnosis. Taking biopsy for confirming the diagnosis is not necessary for most of cases. Radiological imaging techniques will be sufficient. The gold standard imaging technique for diagnosis is magnetic resonance imaging. In T1 and T2 sequences, a hyperintense appearance representing fats in the mass is observed. The treatment includes the total excision of mass. The possibility of recurrence is highly low in patients without no tumor at surgical resection margins. In literature, no malignant transformation has been reported up to now.

Conclusion: While ED is mainly asymptomatic, it can totally be removed after confirming its diagnosis with magnetic resonance imaging, which is the gold standard diagnostic method, in symptomatic cases. The risk of recurrence is quite low in patients with clear surgical margins.

Keywords: Benign, surgery, elastofibroma dorsi, extrathoracic

Table 1. Demographic distribution of patients

Age	Sex	Symptom	Localization	Dominant Side	Familial Predisposition
62	F	Swelling	Bilateral	Right	None
63	F	Pain	Right	Right	None
57	F	Pain	Bilateral	Right	None
55	F	Pain	Bilateral	Right	None
62	M	None	Right	Right	None
60	F	Pain	Left	Right	None
65	F	Swelling	Right	Left	Yes
67	F	Pain	Bilateral	Right	None
57	F	Pain	Bilateral	Right	None
56	F	Pain	Right	Right	None
64	F	Swelling	Right	Right	None
59	F	Pain	Bilateral	Right	None
52	F	Pain	Right	Right	None
62	F	Swelling	Right	Right	Yes
60	F	Pain	Bilateral	Right	None
45	F	Swelling	Right	Right	None
63	F	None	Right	Right	None
57	F	None	Left	Right	None
63	F	Pain	Right	Right	None
61	F	Swelling	Bilateral	Right	None
56	M	None	Sağ	Right	None

[Abstract:0284] EPS-075 [Accepted: E-Poster] [Health Policies]

The Deaths of Respiratory System in Our Cities According to Age Groups in 2016

Sedat Altın, Cengiz Özdemir, Lütfiye Erkan, Handan Altın

Health Sciences University, Yedikule Chest Diseases and Surgery Training and Research Hospital, İstanbul, Turkey

Objectives: It was aimed to investigate indirectly the respiratory illness burden by studying the facts that all deaths according to genus according to age and age groups and respiratory system diseases were related to the average of deaths.

Methods: Demographic data were obtained from TUIK death statistics by comparing general mortality, respiratory diseases, sex, age and permanent residence in 2016. Correlation between the cities of above the average and respiratory patient numbers was examined.

Results: In 2016, a total of 422,135 people were died, including 231.200 (54,8%) men and 190,935 women. These deaths were due to respiratory diseases (J00-J99) of 48.532 (11.5%). 28,025 (12.1%) were male and 20,507 (10.7%) female, and male/female ratio in respiratory system deaths was calculated as 1.37. However, the ratio of male to female in total deaths was 1.21 ($p < 0.05$).

Bartın (17.9%), Kayseri (17.5%), Ardahan (17.1%), Niğde (16%), Bayburt (14%), the first 10 provinces where respiratory system related deaths were highest in 2016, Nevşehir (14.8%), Kastamonu (14.6%), Giresun (14.5%), Çankırı (14.4%) and Kars (14.2%) while in male deaths Ardahan, Bartın, Kayseri, Bayburt, Kastamonu, Zonguldak, Niğde, Giresun, Kars and Uşak are listed in top 10. In female death Bartın, Kayseri, Niğde, Ardahan, Çankırı, Nevşehir, Giresun, Bayburt, Yalova and Kastamonu was placed.

According to age groups, Kayseri was the highest with 20.5% in the group with the highest respiratory patient age 65 and over, Bartın with 20.3%, Ardahan with 19.6%, Niğde with 18.1% It is followed by Kars with 17.9. Kayseri with 22.2%, Ardahan with 22.1%, Bartın with 21.8%, Kars with 21.1% and Zonguldak with 20.2% with respiratory system deaths with the highest rate of 15.3% we have been cities.

Tunceli (25%), Bilecik (10.7%), Amasya (8,3%), Kilis (7.7%) and Batman (7%) were cities where the most common respiratory system deaths in the 0-14 age group. The top 5 provinces in the 15-44 age group were Samsun with 9.8%, Rize with 9.6%, Giresun with 8.4%, Artvin and Bartın with 8.2%. In the 45-64 age group, Niğde with 14.5%, Kayseri with 12.2%, Kilis with 11.7%, Ardahan with 11.2% and Çankırı cities with the 11.1% shared the first 5.

Conclusion: It is interesting that respiratory deaths in our Central Anatolian cities such as Kayseri, Nevşehir and Niğde are at a high level as well as our West and Central Black Sea cities in which respiratory disease burden is the highest in the respiratory system in 2016, as well as Ardahan, Kars and Bayburt. It is noteworthy that these are found in geographical regions where cold weather conditions prevail. Although it may be attributed to air pollution and biomass exposure, more comprehensive epidemiological studies are needed in order to prevent community health and deaths.

Keywords: Respiratory system, mortality rates, cities

[Abstract:0285] EPS-035 [Accepted: E-Poster] [Clinical Problems - Diffuse Parenchymal Lung Disease]

Unusual Presentation of Bronchiolitis Obliterans Organizing Pneumonia with Multiple Pulmonary Nodules, A Case Report

Demet Polat¹, Eylem Sercan Özgür¹, Sibel Naycı¹, Tuba Kara², Feramuz Demir Apaydın³, Pınar Pelin Özcan Kara⁴, Erhan Ayan⁵

¹Department of Chest Disease, Mersin University School of Medicine, Mersin, Turkey

²Department of Pathology, Mersin University School of Medicine, Mersin, Turkey

³Department of Radiology, Mersin University School of Medicine, Mersin, Turkey

⁴Department of Nuclear Medicine, Mersin University School of Medicine, Mersin, Turkey

⁵Department of Thoracic Surgery, Mersin University School of Medicine, Mersin, Turkey

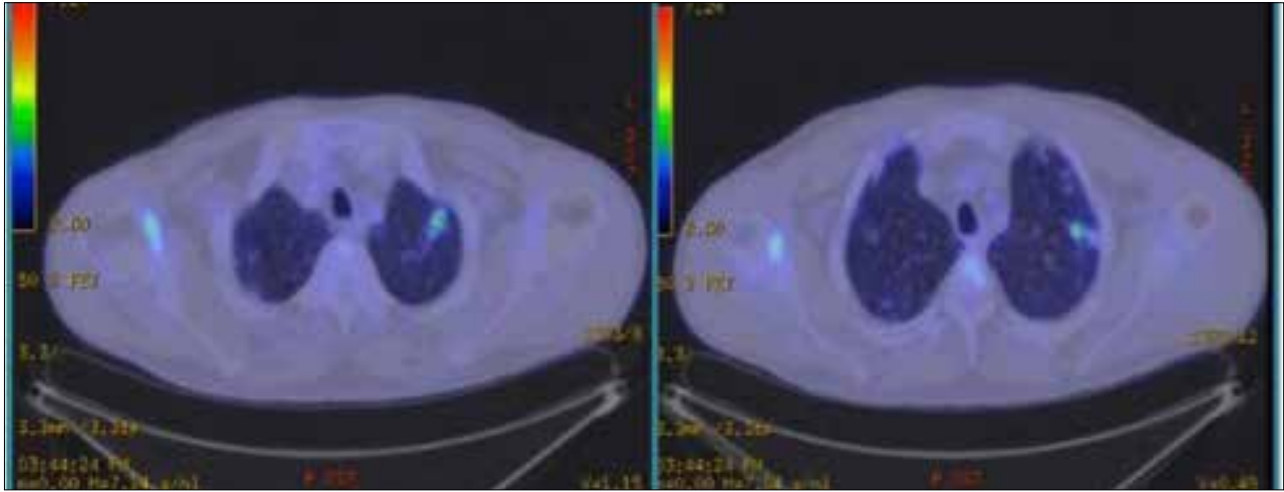


Figure 1. Pet-CT

Pet-CT: A large number of nodules were observed in both lung parenchyma, some of which were calcified, with mildly elevated FDG uptake (Early SUV max: 2.18, Late SUV Max: 3.14) .

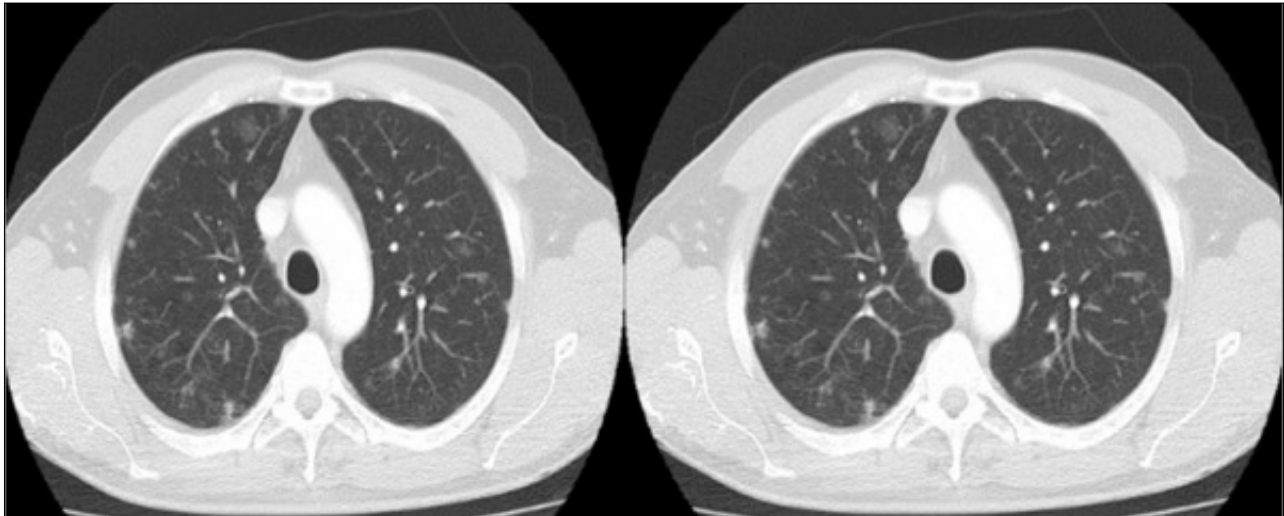


Figure 2. Thorax Computed Tomography

Thorax computed tomography; Predominantly in the upper lobe, bilateral, multiple pulmonary nodules (the largest 20 mm) with variable border features were detected, some of which were frosted glass densities.

Introduction: Bronchiolitis obliterans organizing pneumonia (BOOP) is an interstitial lung disease that is characterized by multiple air space consolidations with a subpleural distribution or areas of ground glass lung infiltration. Many other unusual presentations have also been reported.

Case Presentation: 47-year-old man presented with cough. Thorax computed tomography (CT) : Predominantly in the upper lobe, bilateral, multiple pulmonary nodules (the largest 20 mm) with variable border features were detected, some of which were frosted glass densities. Positron emission tomography/computed tomography (Pet-CT) : A large number of nodules were observed in both lung parenchyma, some of which were calcified, with mildly elevated FDG uptake (Early SUV max: 2.18, Late SUV max: 3.14). Histopathological analysis consisted with BOOP. The patient underwent steroid therapy at a dose of 48 mg/day with the diagnosis of BOOP. At 3 months of treatment, control thorax computed tomography revealed that the areas in the multifocal pulmonary nodules were completely removed.

Conclusion: Our patient had an unusual radiological pattern of bilateral pulmonary nodules associated with BOOP that mimicked pulmonary metastases. Its radiological and nuclear properties can lead to misdiagnosis like malignancy.

Keywords: Bronchiolitis obliterans organizing pneumonia, computed tomography, pet CT, pulmonary nodules

[Abstract:0286] SS-149 [Accepted:Oral Presentation] [Tuberculosis]

The Effect Of Latent Tuberculosis Infection Treatment (LTET) on the Development of Tuberculosis (TB) among Household Contacts Who Are 35 Years-Old or Younger

Filiz Öztürk¹, Elif Altundaş Hatman², Mesut Köskü³, Şule Kızıldaş³, Nesrin Sarımurat³, Zeynep Eren³, Bektaş Kısa³, Tansu Tuskan³, Halil Akyüz³, Nuray Erdal³, Deniz Dönmezoğlu³, Zeki Kılıçaslan⁴

¹Ümraniye TB Dispensary, İstanbul, Turkey

²İstanbul University School of Medicine, Occupational Training Programme, İstanbul, Turkey

³Dispensaries of İstanbul TB Association, İstanbul, Turkey

⁴Department of Chest Diseases, İstanbul University School of Medicine Hospital, İstanbul, Turkey

Objectives: Before 2011, the approach of Treatment of Latent Tuberculosis Infection (LTBI) had covered the close contacts who are 15 years-old and younger. Treatment of LTBI began to implemented under the age of 35 in the year of 2011. The aim of this study is to determine the effect of treatment of LTBI on the development of TB among contacts with different age groups.

Methods: A cross sectional study is designed. Individuals (n=7823), who are household contacts with smear positive patients who were diagnosed between 2009 and 2014 in 10 (ten) TB Association Dispensary in İstanbul. We excluded individuals who has history of TB treatment or who diagnosed with TB at the first control or who is migrant or who couldn't complete the TB treatment at the dispensaries or who is contacts with Multi Drug Resistance TB. We performed descriptive statistics for the distribution of each variable and chi-square analysis in univariate analysis of nominal variables and t-test in independent groups for continuous variables.

Results: Total of 2409 smear positive patients have 7823 household contacts and 87.5% (n=6846) of the individuals were checked at least once. The mean follow-up time of the disease-free contacts (n=7668) was 6.04±1.8 years; the contacts' who developed TB was 1.74±1.67 (min: 0.14 max: 8.09) years.

Among contacts 54.9% (n=4294) were female On the other hand, 2% (n=72) of male and 1.9% of females developed TB (p=0.735).

While the mean age of the contacts who developed TB was 26.86±15.35, the mean age of the disease-free contacts was 30.38±19.21 (p=0.005).

While the mean number of family members of TB patients was 5.04±2.69, disease-free household contacts number was 4.58±2.69 (p=0.038).

It was found that 2.0 % (n=155) of the individuals developed TB. 59.4% (n=92) of the patients were in the age group of 16-35. 2.5% (n=18) of the age group of 0-15 did not receive the LTBI treatment and 3.8% (n=88) of the age group of 16-35 did not receive LTBI treatment. In both age groups there were statistical differences, between receiving LTBI treatment and developed TB. (p=0.001).

Table. The effect of the receiving treatment of LTBI on the development of TB among household contacts with different age groups

Age groups of contacts		Disease Free	Developed TB	Total	P
Age of 0-15	No treatment	2.5 % (18)	97.5 % (715)	100 % (733)	0.001
	LTBI Treatment	0.7 % (9)	99.3 % (1280)	100 % (1289)	
	Total	1.3 % (27)	98.7 % (1995)	100 % (2022)	
Age of 16-35	No treatment	3.8 % (88)	96.2 % (2233)	100 % (2321)	0.001
	LTBI Treatment	0.7 % (4)	99.3 % (557)	100 % (561)	
	Total	3.2 % (92)	96.8 % (2790)	100 % (2882)	
Age ≥36	No treatment	1.2 % (36)	98.8 % (2844)	100 % (2919)	0.001
	LTBI Treatment	0 % (0)	100 % (39)	100 % (39)	
	Total	1.2% (36)	98.8 % (2883)	100 % (2919)	
Total	No treatment	2.4 % (142)	97.6 % (5792)	100 % (5934)	0.001
	LTBI Treatment	0.7 % (13)	99.3 % (1876)	100 % (1889)	
	Total	2.0 % (155)	98.0 % (7668)	100 % (7823)	

Conclusion: LTBI treatment significantly reduces the risk of illness in both age groups. TB developed contacts were younger and lived in crowded families.

Keywords: Tuberculosis, contact, latent tuberculosis infection, treatment

[Abstract:0291] PS-067 [Accepted:Poster Presentation] [Thoracic Surgery]

Traumatic Lung Hernia: Report of Two Cases and Review of the Literature

Salih Kür, Ekin Zorlu, Nesimi Günal, Koray Dural, Berkant Özpolat

Department of Thoracic Surgery, Kırıkkale University Faculty of Medicine, Kırıkkale, Turkey

Introduction: Lung hernia is the protrusion of lung tissue from a defect forming the rigid structures of the chest wall. In the literature, Roland was the first author who defined this condition in 1499. Here we present and discuss two cases of lung hernia diagnosed and managed in our clinic with the light of relevant literature.

Case 1: A 79-year-old man was evaluated in the emergency department due to a tractor accident. In his background, there was no lung disease or surgical intervention to the thoracic cavity. In his physical examination, there was severe pain at left thoracic wall and the breath sounds were decreased at basal region of the lungs bilaterally. Thorax computed tomography revealed a lung herniation from the 6th intercostal space laterally, bilateral hemothorax and hematoma within latissimus dorsi muscle 22 mm in diameter (Figure 1). Control tomography showed that hernia was regressed.

Case 2: 60-year-old man was presented with a swelling on his chest wall during coughing. In his background a lung reducing surgery via VATS had been performed in our clinic due to emphysema. In his physical examination, protrusion of the lung was detected at left fourth intercostal space over the 5cm incision line on Valsalva maneuvers and during coughing. Thorax computed tomography revealed a lung hernia from the fourth intercostal space anterolaterally (Figure 2). Due to the asymptomatic nature of the case follow-up and avoiding the maneuvers causing protrusion advised.

Discussion: After its definition by Roland in 1499, Morel Lavalley classified the lung hernia as congenital and acquired in 1845. The later accounts 70% of all cases and sub-classified as traumatic, spontaneous and pathologic. Traumatic cases are usually underdiagnosed because of accompanying hemothorax/pneumothorax. Symptoms were pain and swelling/mass during cough but some patients were asymptomatic. Diagnosis can be achieved by palpation of the mass and inspection

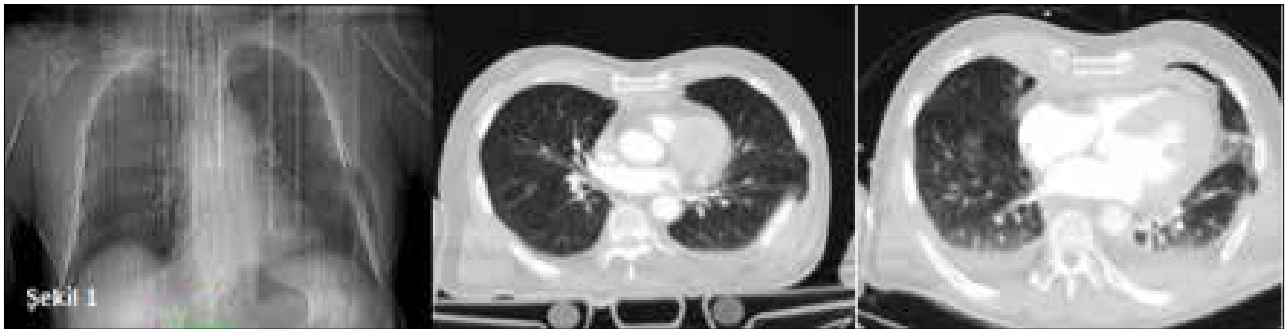


Figure 1. Under presentation of case 1

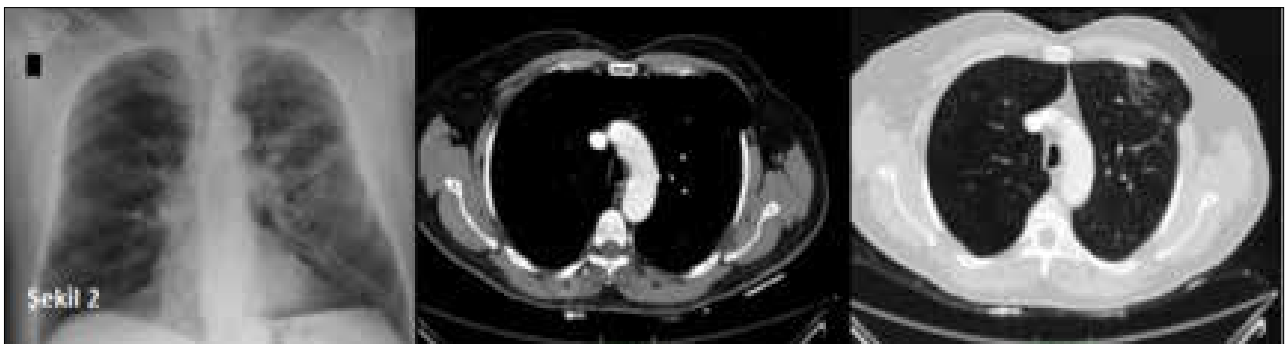

Figure 2. Under presentation of case 2

during Valsalva maneuvers. Radiologic examination shows a well circumscribed, radioluscent mass herniated from chest wall on PA x-ray. Thorax computed tomography is the gold-standard for diagnosis. Treatment consist of avoiding movements causing the herniation, cessation of cough and follow-up in asymptomatic cases. However, primary surgical repair, closure of the defect with otogenous or artificial grafts were treatment of choice in symptomatic cases. In our cases, conservative management was preferred. In the case that an increase in size of herniation, incarceration observed or if patient complaints of pain, surgical intervention will be planned as mentioned in the literature.

Keywords: Thoracic trauma, lung hernia, VATS, lung volume reducing surgery, computed tomography

[Abstract:0292] EPS-263 [Accepted: E-Poster] [Thoracic Surgery]

Our 5-Year Results of Mediastinoscopy

Fatih Meteroğlu, Menduh Oruç, Ali Birak, Funda Öz Bektaş, Serdar Onat, Refik Ülkü

Department of Chest Diseases, Dicle University School of Medicine, Diyarbakır, Turkey

Objectives: Tuberculosis (TB) can lead to some difficulties in diagnosis by radiologically giving findings that are similar to those in some tumoral, inflammatory, and systemic diseases. In this presentation, we wanted to draw attention to that TB had an important place with 72 cases among the mediastinoscopy results of 332 cases that were investigated due to mass lesion. TB and lung carcinoma are the diseases that are sometimes confused with each other and thus cause delayed diagnosis and treatment. Tuberculosis can present with different clinical and radiological appearance. Pulmonary TB can cause difficult diagnosis by demonstrating findings similar to those in some tumoral, inflammatory, and systemic diseases. The underlying factors for these radiological differences in findings include the diseases and conditions such as diabetes, silicosis, sarcoidosis, AIDS, and malignancy, which impair the immune system. In this study, it was aimed to present 72 patients who were hospitalized in our clinic due to mass lesion and considered to have lung cancer at the beginning, but diagnosed with pulmonary TB according to the examinations that were performed.

Methods: Between 2012 and 2016, 141 male and 191 female patients were admitted to our clinic for mass in the lungs and/or mediastinal lymph node. The age range of these 332 patients was 20-78 years (mean age: 49,3 years). The files of them were retrospectively evaluated.

Results: Thoracic computed tomography of all hospitalized patients were performed. No pathology was found in their laboratory parameters. Moreover, ARB was not examined in the patients because tuberculosis was not considered. All patients were performed PET-CT due to the pre-diagnosis of tumor and involvement was found at malignancy level. Mediastinoscopy was performed in 332 patients who could not be diagnosed despite evaluations of the department of chest diseases. The results of mediastinoscopy are given in Table 1. In this table, it is seen that the rates of tuberculosis and non-granulomatous diseases are remarkably high (Figure 1).

Conclusion: In regions where tuberculosis is endemic, particularly tuberculosis presenting with a mass appearance can be confused with lung cancer. PET/CT, which is used in the differential diagnosis of lung cancers and in the determination of their prevalence, can be used in TB patients restrictedly because increased involvement can also be found in tuberculosis. Therefore, PET/CT cannot help in the differential diagnosis of tuberculosis and lung cancer by itself.

Keywords: Lung cancer, mediastinoscopy, tuberculosis

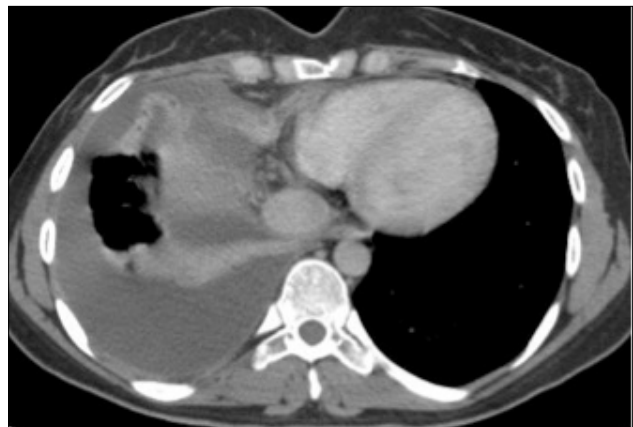


Figure 1.

[Abstract:0295] PS-291 [Accepted:Poster Presentation] [Respiratory Failure and Intensive Care]

Evaluation of Intensive Care Infections and Demographic Characteristics of Patients with Neurological Problems Followed by Mechanical Ventilator

Yusuf İnanç

Department of Neurology, Gaziantep University School of Medicine, Gaziantep, Turkey

Objectives: Intensive care units are the areas where both hospital-acquired infections and mortality rates are significantly higher. Serious infections, especially sepsis, are responsible for 60% of mortality and 40% of cost in intensive care units. In this study, it was planned to investigate the patients characteristics those have been followed up at neurological intensive care unit under mechanical ventilation, in respect to demographic data and endotracheal aspirate cultures.

Methods: 108 participants under mechanical ventilation and had tracheal aspirate culture were included among 238 participants who were followed up in neurological intensive care unit during 2017 year. The study was designed as retrospective and cross-sectional. Demographic data and tracheal aspirate culture results were recorded.

Results: 57% of the participants were female and 43% were male. Mean age was 64 ± 15.9 . 66% of participants had diagnosis with ischemic stroke, 8% had subarachnoid hemorrhage, 8% had encephalitis, 6% had hemorrhagic stroke and the rest had other diagnosis. Prevalences of diagnosis were not different between genders ($p > 0.05$). WBC, CRP, Sedimentation rates at the time of the first admission, tended to be higher in females but it was not statistically significant ($p > 0.05$). The mean time period between the first admission and getting the first tracheal aspirate culture was higher in male participants as follows: 5 ± 2.4 days and 6.9 ± 4.1 days in females and males respectively ($p = 0.03$). The first blood culture positivity rate was 57% (55.2% and 59.1% in females and males, respectively. $P > 0.05$). Microorganisms identified from the first blood cultures were as follows: 48.3% were *Acinetobacter baumannii*, 10.3% were *Pseudomonas aeruginosa*, 10.3% were ESBL (+) *Klebsiella pneumoniae* and 6.9% *Corynebacterium striatum*. There was no statistically significant difference between genders in respect to prevalence of identified microorganisms. Mean ages of those with and without positive culture results were 68.3 ± 13.2 and 58.2 ± 17.5 , respectively ($p = 0.038$). 55% of participants had the second tracheal aspirate culture. The second culture positivity rate was 90%. The most common microorganisms were *Acinetobacter baumannii*, *Pseudomonas aeruginosa*, respectively. Mortality rate was 64%.

Conclusion: *Acinetobacter baumannii*, *Pseudomonas aeruginosa* are the most common microorganisms identified in tracheal aspirate cultures in our study. The mean time period between the first admission and getting the first tracheal aspirate culture was longer in male than female participants. Positive tracheal aspirate culture result are higher in younger participants. Mortality rate is high.

Keywords: Mechanical ventilator, intensive care, aspirate culture

[Abstract:0299] EPS-242 [Accepted: E-Poster] [Thoracic Surgery]

Unexpected Etiology In A Patient With Left Arm and Shoulder Pain: Giant Pulmonary Hydatid Cyst

Tuba Şahinoğlu¹, Hüseyin Yıldırım², Bekir Tezcan¹

¹Department of Thoracic Surgery, Konya Numune State Hospital, Konya, Türkiye

²Department of Thoracic Surgery, Kars Harakani State Hospital, Kars, Türkiye

Cyst hydatid disease is a parasitic and endemic infection that is often caused by *Echinococcus Granulosus*. Cyst hydatid remains an important clinical problem in endemic countries. It is characterized by cystic lesions, especially in the liver and lung. Rarely shows settlement in other organs. The cysts larger than 10 cm in lung tissue are defined as giant hydatid cysts. We present this case as a case of hydatid cyst which is located in the upper lobe of the left lung and which develops with complaints of numbness with pain in the left shoulder and arm. The difference of this case is its different clinical presentation and giant size.

An 18-year-old female patient was admitted to the emergency room with complaints of numbness with pain on her left

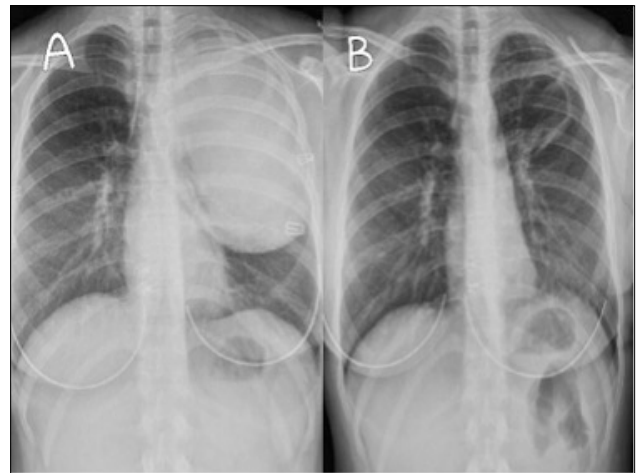


Figure 1. A. Preoperative chest X-ray of the patient, B. Postoperative chest X-ray of the patient

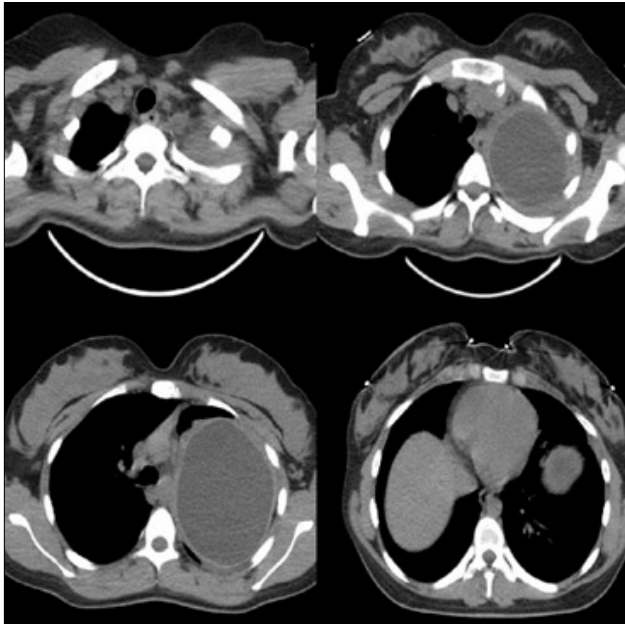


Figure 2. Thorax BT sections of the patient

shoulder and arm for 1 week. When the symptoms were elaborated, a giant lesion covering the left lung was seen on a chest X-ray. The patient then suffered thorax computed tomography (CT). CT is reported as 'cystic mass with a size of approximately 150x90 mm extending into the left lung upper lobe, middle lobe and part of the lower lobe segments filling the left lung in great measure, cystic hydatid? The cystic mass showed a close proximity to the left ventricle with aortic arch, left pulmonary artery, left main bronchus and branches. Living in the village was remarkable in the history of the patient who was directed to the thoracic surgeon polyclinic. She had no additional systemic disease. Physical examination was normal. In the auscultation respiratory voices were slightly deep in the left lung. No pathology was detected in the laboratory evaluations. Cyst hydatid indirect hemagglutination test was negative. There was no cyst hydatid in the liver in abdominal ultrasonography. The patient was interviewed and the operation was decided. After operation preparations had completed, cystotomy and capitonnage were performed with thoracotomy. The exudated cyst was approximately 15x10cm in size. On the 5th post-operative day, tube drain was terminated. The patient was discharged on the 6th postoperative day. On polyclinic follow-up the lung was full-expansive in chest X-ray. Complaints of the patient retreated after surgery.

To be able to diagnose cyst hydatid in a patient, it needs to be suspicious. It is important to have an accurate and comprehensive patient history. As a result, it should not be forgotten that like in this case, the pulmonary cyst hydatid may occur with nonspecific symptoms of the chest wall and respiratory system and should always be considered in differential diagnosis.

Keywords: Giant, hydatid cyst, pulmonary

[Abstract:0300] PS-070 [Accepted:Poster Presentation] [Thoracic Surgery]

Two Adult Brothers with Cystic Fibrosis Bronchiectasis

Hatice Eryiğit Ünalı¹, Mehmet Ünalı²

¹Department of Thoracic Surgery, İzmit Seka Government Hospital, Kocaeli, Turkey

²Department of Emergency Medicine, Derince Training and Research Hospital, Kocaeli, Turkey

Introduction: Cystic fibrosis is an autosomal recessive disorder and usually diagnosed in childhood. It causes bronchiectasis and progressive lung injury with chronic pulmonary infection. We diagnosed cystic fibrosis in two adult brothers who were followed up for bronchiectasis. Because these patients are rare, we want to present their clinical features.

Case Presentation: The first of brothers was 29 years old. The patient had a history of progressive cough and colorful sputum for years. Computed tomography reviewed cystic bronchiectatic changes in the right lower middle lobe and lower lobes bilaterally. The significant obstructive change was in the pulmonary function tests. No evidence of tuberculosis was found.

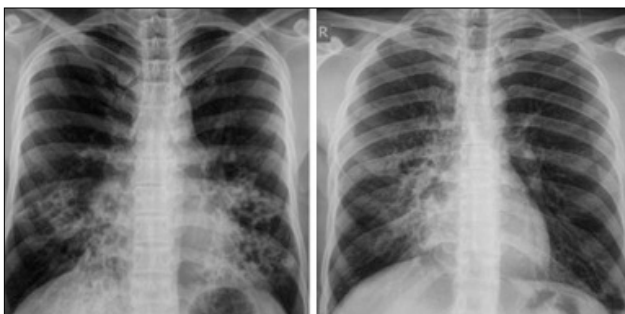

Figure 1. Preoperative chest X-ray images of patients

The middle lobectomy and lower lobe wedge resection have been performed to the patient. The left lower lobectomy was done ten months later. The patient was discharged uneventful after either both operation. He is in the third year after the second operation.

The other male in 25 years old was underwent three times excision of nasal polyps. He had mild respiratory symptoms. There was cystic bronchiectatic changes in the middle lobe and upper lobe. Pulmonary function tests had no obstruction. The middle lobectomy and wedge resection of upper lobe anterior segment were performed. The patient was discharged without problem on postoperative third day. The

pneumothorax was detected in the patient with chest pain 15 days after discharged. Tube thoracostomy was performed after failed recurrent thoracentesis. The patient in the postoperative fourth year is asymptomatic.

Two brothers have cystic fibrosis transmembrane conductance regulator (CFTR) gene with E217G mutation, homozygote in big brother, heterozygous in the other patient.

Conclusion: The etiology of bronchiectasis should be search to all patient. Cystic fibrosis should be remembered in even adult patients because of follow up for both respiratory and other systems.

Keywords: cystic bronchiectasis, nasal polip, surgical resection

[Abstract:0301] EPS-089 [Accepted: E-Poster] [Lung and Pleura Malignancies]

Outcomes of Surgical Resection with Pathological N2 Patients

Hatice Eryiğit Ünal¹, Kadir Burak Özer², Ekin Ezgi Cesur², Recep Demirhan²

¹Department of Thoracic Surgery, İzmit Seka Government Hospital, Kocaeli, Turkey

²Department of Thoracic Surgery, Kartal Dr Lutfi Kırdar Training and Research Hospital, İstanbul, Turkey

Objectives: Although the management clinical and pathological N2 disease is enigma, lymph node metastasis is the most important to determine the survival time. We reviewed the surgical outcomes of patients with pathological N2 positive.

Methods: The surgical treatment was performed to 251 patients with primary lung cancer in between 2010 and 2017. Twenty-two patients had N2 disease. We analyzed clinico-pathological features of pN2 (+) patients, number, nodal zone of metastatic lymph nodes retrospectively.

Results: The mean age was 60 years (37-81) and 18 patients were male. The ratio of pneumonectomy was 22.7 %and all of them was on left side. The complication occurred to only 3 patients. The mean hospital stay was 8,5 days. Locations of lung cancer were 13 central, 9 peripherally. Lymph node positive was 8 patients on positron emission tomography and, 13 patients were performed invasive staging procedure preoperatively. The frequent positive lymph stations were #7, 5 and 4R. 8 patients with N2 disease had also N1 positive. The mean of pathological lymph node number was 3 (1- 10). Three patients had multiple N2 positive lymph stations. Tumor subtypes were 12 squamosus cell carcinoma, 9 adenocarcinoma, one adeno-squamosus carcinoma. Mean tumor dimension was 42.2 cm. "T" staging were T1- six patients, T2- ten, T3- three, T4- three patients according to 8th staging. Three cases had brain metastasis. The survival was in between 6 and 72 (mean- 28) months.

Conclusion: The N2 disease has many subgroups as microscopic metastasis, bulky N2, one or multiple lymph node positive, with/without N1 positively. Although the number of patients was low, outcomes was similar as literature and we know a little knowledge about N2 disease.

Keywords: Lymph node, N1 disease, surgery

[Abstract:0302] PS-188 [Accepted:Poster Presentation] [Pediatric Pulmonary Diseases]

Laryngeal Tuberculosis as Rare Cause of Dysphonia in Children

Lina Muhammed Al Shadfan, Hakan Yazan, Erkan Çakır

Department of Pediatric Pulmonology, Bezmialem Vakif University School of Medicine, İstanbul, Turkey

A 15-year-old girl patient was presented with progressive dysphonia, dysphagia and difficulty in breathing for the last 6 months. She was referred to ENT and flexible laryngoscopy was done and it showed a vocal cord nodule. She was referred to our clinic for perioperative nodule excision assesment. The patient didn't have any extra symptoms or physical signs. An chest x-ray was requested in order to rule out any respiratory cause for her difficulty of breathing. Chest x-ray showed bilateral diffuse nodular opacities and infiltration (Figure 1). After that we order a tuberculin skin test and thorax CT scan. Tuberculin skin test result was 12 mm. the patient was unable to produce sputum so a bronchoscopy was done. Bronchoscopy showed true vocal cord nodule otherwise it was normal (Figure 1). Thorax CT scane showed bilateral diffuse nodular opac-

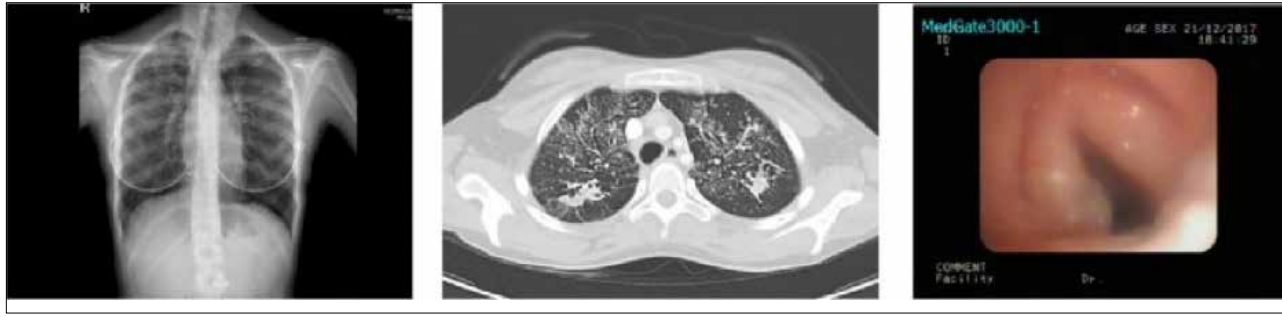

Figure 1. Chest X ray and tomography showing diffuse paranchymal infiltrates and edema and nodule on vocal cords

ities, tree in bud sign, multiple calcified lymphadenopathy with largest one about 13 mm in diameter, multiple calcified nodules and traction bronchiectasis (Figure 1). Depending on these findings the patient was diagnosed to have tuberculosis and started on 4 regimen anti tuberculosis medication. The BAL culture showed mycobacterium tuberculosis complex. The diagnosis of laryngeal and pulmonary tuberculosis was confirmed depending on the radiological and microbiological results. This case presented because of the rarity of laryngeal tuberculosis as the cause of dysphonia in children.

Keywords: Tuberculosis, child, dysphonia, laryngeal tuberculosis

[Abstract:0304] EPS-088 [Accepted: E-Poster] [Lung and Pleura Malignancies]

Metastatic Squamous Cell Carcinoma from Cancer of Unknown Primary in the Mediastinal Lymph Node

Meltem Ağca¹, Aysun Kosif², Fatma Tokgöz Akyıl³, Tülin Sevim¹

¹Department of Pulmonology, University of Health Sciences İstanbul Süreyyapaşa Chest Diseases and Thoracic Surgery Research, and Training Hospital, İstanbul, Turkey

²Department of Thoracic Surgery, Health Sciences University, İstanbul Süreyyapaşa Chest Diseases and Thoracic Surgery Research and Training Hospital, İstanbul, Turkey

³Department of Pulmonology, Çanakkale State Hospital, Çanakkale, Turkey

Introduction: Cancer of unknown primary (CUP) are a group of heterogeneous tumors whose primary origin could not be determined despite detailed examinations, blood tests and radiological tests. The tendency to spread early, unpredictable metastases and aggressive progression are their common properties. They amount to 2-5% of all cancer cases and are the fourth largest cause of cancer-related deaths. The majority (90%) are histological-type adenocarcinomas while only 5% feature squamous cell carcinoma. Multiple metastases found in half of the patients are towards the liver, lungs and bones. On the other hand, mediastinal lymph node metastases are exceedingly rare with poor prognosis with a survival less than a year.

The present case, diagnosed as squamous cell carcinoma from CUP in the mediastinal lymph node is reported due to its rarity.

Case Presentation: A 63-year-old male was admitted with complaints of chronic coughs and hick-ups. His medical history included hypertension, diabetes mellitus and he had smoked 50 packs of cigarettes. Physical examination was normal. Except slightly elevated creatinine levels, laboratory analysis were within normal limits. In thorax computed tomography, right upper paratracheal, right lower paratracheal lymph nodes were enlarged with 26 millimeter dimension.

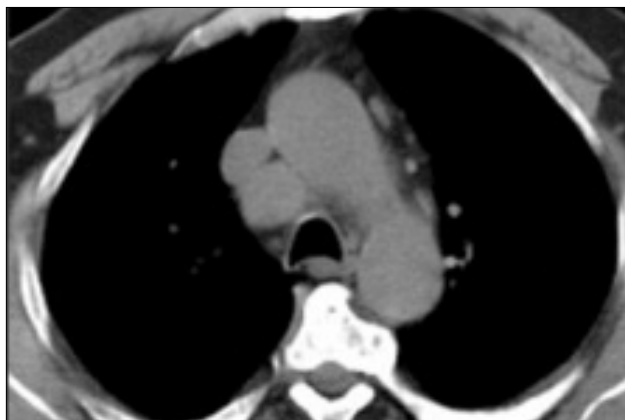

Figure 1. Chest computed tomography: 4R mediastinal lymph node station

No endobronchial lesions were observed in the fiberoptic bronchoscopy. Transbronchial needle aspiration biopsy was performed from enlarged lymph nodes and histopathological examination did not reveal a specific diagnosis. Mediastinal lymph nodes FDG uptake was 29.7 at positron emission tomography. There were no hypermetabolic centre for primary malignancy except lytic lesion on L3 vertebra (SUVmax; 16.2). Systematic evaluation did not point a primary malignancy in the gastrointestinal system or else. Mediastinoscopy was performed through 4R due to the case being a heavy smoker

and his respiratory complaints. Malign tumor metastasis was detected. In the immunohistochemical examination, the tumor cells were painted positive with CK7 and negative with CD20,HMB45, S-100,P63 ve TTF1, PSA. It was reported that the current immunoprofile contained no indications for a distinct sign of a primary. The patient was admitted by the oncology unit with a diagnosis of tumor with unidentified primary. The patient died in one year after the diagnosis.

Discussion: In the presence of metastatic cancer in the mediastinal lymph node without any primaries detected in the lungs or the other organs, cancer of unknown primary should be considered, which is known to have aggressive progression with a non-negligible occurrence.

Keywords: Mediastinal lymph node, squamous cell carcinoma, unknown primary

[Abstract:0308] PS-183 [Accepted:Poster Presentation] [Pediatric Pulmonary Diseases]

Diffuse Panbronchiolitis: A Rare Cause of Bronchiectasis in Children

Gökçen Dilşa Tuğcu¹, Beste Özsezen¹, Güzin Cinel², Doğuş Güney³, Emrah Şenel³, Esra Karakuş⁴, Diclehan Orhan⁵

¹Department of Pediatric Chest Diseases, Hacettepe University, İhsan Doğramacı Children's Hospital, Ankara, Turkey

²Department of Pediatric Chest Diseases, Ankara Child Health, Hematology-Oncology Training and Research Hospital, Ankara, Turkey

³Department of Pediatric Surgery, Ankara Child Health, Hematology-Oncology Training and Research Hospital, Ankara, Turkey

⁴Department of Pathology, Ankara Child Health, Hematology-Oncology Training and Research Hospital, Ankara, Turkey

⁵Department of Pediatric Pathology, Hacettepe University, İhsan Doğramacı Children's Hospital, Ankara, Turkey

Introduction: Diffuse panbronchiolitis (DPB) is a chronic, progressive disease of the lower respiratory tract, which is rarely encountered in our country. Clinically, persistent cough, sputum, and exercise-induced dyspnea are apparent. If DPB is not early diagnosed and treated, it can lead to bronchiectasis, progressive suppurative and obstructive airway disease, chronic respiratory failure, and mortality. Its diagnosis can be established by the demonstration of peribronchial inflammation characterized by bronchial infiltration of plasma cells, lymphocyte, and thickening on the respiratory bronchial wall and peribronchial tissue. Although infection and genetic factors are considered to be effective, the pathophysiology of the disease is still unclear, but it has been reported that the disease can be recovered to a great extent through long-term use of macrolides at low doses. Characteristic imaging and histological findings of a 12-year-old male patient who consulted to our clinic with the diagnosis of DPB were defined.

Case Presentation: A Sudanese 12-year-old male patient was admitted to our clinic due to cough with purulent sputum and recurrent lung infection that lasted since the age of 4 years. It was learned that the patient was followed due to the diagnosis of asthma but he did not benefit from inhaled bronchodilator and steroids, he was hospitalized because of recurrent lung infection for many times, and thoracic computed tomography (CT) revealed diffuse bronchiectases. In his physical examination, apparent clubbing, diffuse rough crepitant rales in the lungs, and partial sibilant rhonchus were found. Transcutaneous oxygen saturation was 98%, white cell count was 12000/mm³, hemoglobin was 13,4, and platelet count was 55000/mm³. Severe restriction and obstruction that did not give response to bronchodilator were found in the respiratory function test. In bilateral chest radiography, bronchiectasis, which was more apparent in the lower zones of both lungs, and collapse in the upper and middle lobes of the right lung were observed. The result of sweat test was 15 mmol/l. His detailed immunological examinations and alpha-1 antitrypsin levels were normal. The result of tuberculin skin test was reported as anergic. No m.tuberculosis was found in sputum and bronchoalveolar lavage (BAL). In Water's sinus graph, bilateral maxillary sinusitis was detected. High-resolution thoracic CT revealed small centrilobular nodular opacities, thickened bronchial wall structures, collapse in the upper and middle lobes of the right lung, and diffuse bronchiectasis. In flexible bronchoscopy (FB), mucopurulent secretion from all lobes and yellow polypoid and nodular lesions in the bronchial wall of the right upper lobe were observed. Biopsy was taken from the defined lesions by passing endoscopy forceps through FB. In the pathology of endobronchial lesions, an increase was found in subendothelial monocytes. No recovery was observed in cystic bronchiectases and right lung upper-middle lobe collapse of the patient, who had Paeruginosa growth in BAL aerobic culture, after 2-week appropriate antibiotherapy and chest physiotherapy. The patient was performed right upper and middle lobectomy. Because the pathological results were reported as apparently increased subendothelial lymphocytes in respiratory bronchioles, he was diagnosed with DBP and begun 250 mg/day erythromycin.

Discussion: Although DBP is rarely seen in children and in our country, the diagnosis should be established through high-resolution CT after the initial examinations in children with chronic cough with sputum, respiratory distress, restriction, and nasosinusitis and the complications of the disease should be prevented with early macrolide therapy. Because the pathology

develops in the respiratory bronchioles in DPB, the diagnostic sufficiency and sensitivity of samples taken with transbronchial biopsy are low; however, FB-guided BAL and transbronchial biopsy is guiding for diagnosis. In the diagnosis of DPB, lung biopsy performed with open or laparoscopic interventions helps to diagnose.

Keywords: Diffuse panbronchiolitis, bronchiectasis, flexible bronchoscopy, biopsy

[Abstract:0310] EPS-131 [Accepted: E-Poster] [Pulmonary Pathology]

Mature Mediastinal Teratoma

Elvin Çetiner, Gülşah Ethemoglu

Department of Chest Diseases, Mehmet Akif İnan Training and Research Hospital, Şanlıurfa, Turkey

The tumor arose from the left lobe of the thymus and extended into the left pleural cavity, completely compressing the left lung and extensively shifting the mediastinum to the right. It was successfully treated by surgical resection, with a final pathological diagnosis of a grades 1-2 mature teratoma.

Mediastinal mature teratoma (MMT) is an uncommon neoplasm, accounting for only 4.3% of all germ cell tumors.

It may cause stridor and dyspnea by direct tracheal compression in children <2 years old but is rarely symptomatic in later.

Occasionally, MMT may rupture into the pleural cavity, pericardium, lung, and tracheobronchial tree, leading to protean clinical presentations.

We report a case of a mediastinal teratoma in an 30-year-old woman who presented with a short history of chest pain cough and fever persisted. She visited a community hospital where the chest radiograph revealed left lower lung minimal consolidation and CT suggested pneumonia with a solid soft tissue lesion with cystic components in it. She was treated for lobar pneumonia. Despite antibiotic treatment, cough and fever persisted. He was then referred to our hospital. Physical examination revealed an acutely ill-looking patient with fever (39°C) and decreased but coarse breathing sounds over the left lower chest. Abnormal laboratory data included a white blood cell count of 12,300/mm³ with 77% polymorphonuclear leukocytes and elevated C-reactive protein (129 mg/L). Chest radiograph showed left hiler opacity with left hiler fullness.

Total tumor resection, thymectomy, Pathologic examination confirmed MMT After surgery, the patient recovered uneventfully and remained well at 6 month follow-up.

Mediastinal mature teratoma is a benign, slow-growing tumor within or near the thymus gland typically affecting 20 to 40 year-old adults.

Mediastinal mature teratoma is generally asymptomatic. Occasionally, it may rupture into the mediastinum, pleura, lung, bronchus, and pericardium, with various clinical presentations including chest and/or back pain, fever, cough with hairy and/or sebaceous expectorant.

In our patient, with a short history of chest pain cough and fever she was first treated such as lobar pneumonia but despite antibiotic treatment, cough and fever persisted. CT is the modality of choice for evaluating MMT, which typically manifests as a heterogeneous mass containing soft tissue, fat, fluid, and/or calcium. However, as seen in our case, Scrutiny of any intralesional fat component can help

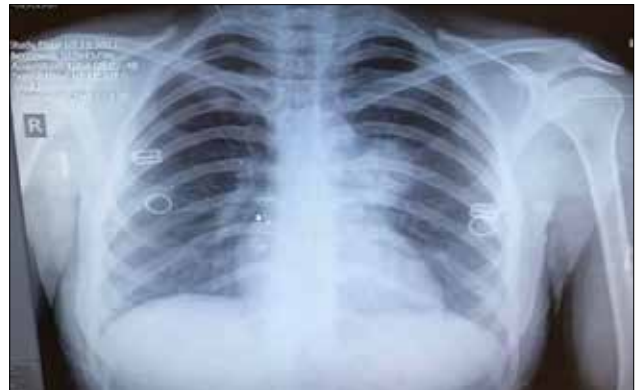

Figure 1. Left hiler enlargement on the left lung

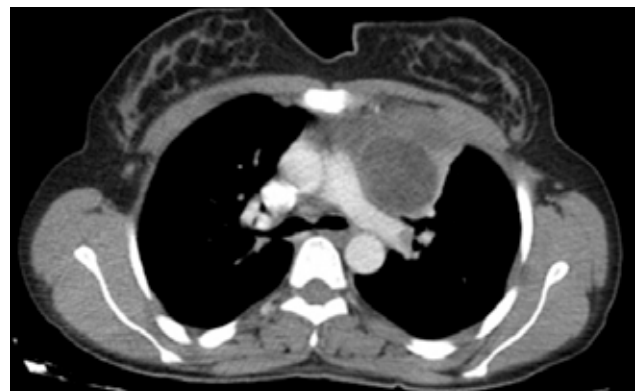


Figure 2. Lung ventilation not observed on the left lung upper anterior lobe in which solid soft tissue lesion with cystic components diameters of 42mm and 25mm. in the adjacent lung parenchyma subsegmental mild atelectasis area is seen.

establish diagnosis, but 15% of MMT may be purely cystic without fat or calcium. Once diagnosed, early surgery of MMT is recommended. Fortunately, successful surgical treatment was achieved in our patient.

Keywords: Mature Mediastinal Teratoma (MMT), thymus, CT, surgical

[Abstract:0311] SS-021 [Accepted:Oral Presentation] [Diagnostic Methods]

New Diagnostic Parameters about Pulmonary Embolism: Initial Study

Yeliz Aktürk, Serra Özbal Güneş

Health Sciences University, Dışkapı Yıldırım Beyazıt Training and Research Hospital, Ankara, Turkey

Objectives: Acute pulmonary embolism (PE) is a serious cardiopulmonary medical condition which may go fatal. Diagnosis may be problematic when the case is not presented with typical symptoms. The most common diagnostic radiological tool is Computed Tomography Angiogram (CTA). Diagnosis may be achieved by detecting filling defects in pulmonary arterial system, sometimes because of the hemodynamic condition of the patients and technical reasons the desired images cannot be obtained. Secondary findings gain importance in such conditions. We aim to analyze the efficiency of elapsed time (ET) and reflux of contrast media to Vena Cava Inferior (VCI) in diagnosis and evaluation of the severity of PE.

Methods: The pulmonary CTAs taken between June 2017 and December 2017 were retrospectively analyzed. The angiograms of 30 patients with PE diagnosis were scored according to Qanadli index. The 30 patients with PE and 26 cases who had normal angiograms were evaluated. The ET between the injection of the contrast media and the formation of adequate density in the pulmonary truncus were calculated. It was noted whether there was a reflux of contrast media to VCI. It was also analyzed whether ET increased and reflux of contrast media to VCI as the Qanadli index score of the patients increased. Patients with PE were compared with non-PE cases to investigate the diagnostic efficiency of these finding with Pearson correlation and regression analyzes.

Results: There was a positive and significant correlation between Qanadli score and ET and reflux of contrast media to VCI, ($p < 0.05$). The ET and the reflux of the media to VCI increased with the increase in the severity score. When patients with and without PE were compared, the ET elongated significantly in patients with PE ($p < 0.001$).

Conclusion: ET is the time needed to get the adequate density of the contrast medium in the pulmonary truncus, after the media was given via intravenous route to reach and accumulate in the pulmonary truncus. The filling defects are seen after homogenous high brightness and contrasting are reached. ET varies between patients according to hemodynamic properties. In animal studies, ETs are found to be related with cardiac output and vasculatory system. ET may be elongated because of pulmonary hypertension and right ventricle dilatation. Therefore it may be useful to reflect prognosis in patients with PE. The longer ET in patients with PE and the higher incidence of reflux to VCI may be of diagnostic importance in patients when the diagnosis is ambiguous.

Keywords: Embolism, tomography, angiogram

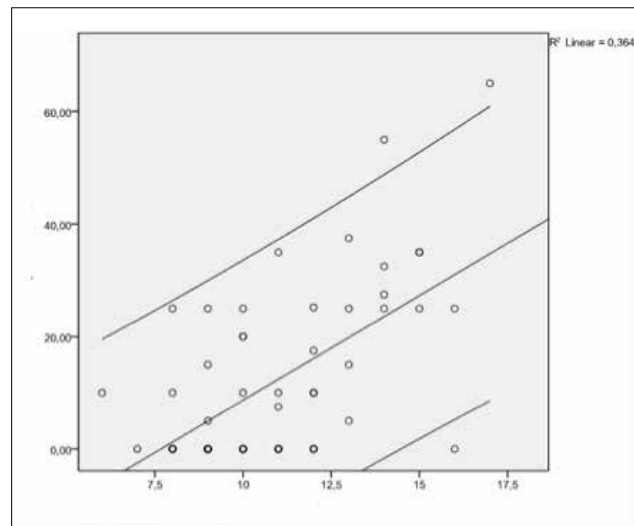


Figure 1. The relation of elapsed time with Qanadli severity index score in patients with pulmonary embolism (oblique lines: standart deviation, o:cases)

Table 1. Findings in patients with and without pulmonary embolism

	Patients with pulmonary embolism (n=30)	Non-pulmonary embolism cases (n=26)
Age (mean)	67.6	71.4
Female/male ratio	15/15	18/8
Mean elapsed time	11.8±2.6	9.85±1.8
The rate of reflux in the vena cava inferior	16/30 (53.3%)	4/26 (15.4%)

[Abstract:0312] PS-177 [Accepted:Poster Presentation] [Tuberculosis]

Miliary Tuberculosis with Involvement of Cerebellar

Neslihan Köse¹, Olga Akkan¹, Özgür Bilgin Topçuoğlu², Tülin Kuyucu¹¹Department of Chest Diseases, Health Sciences University, Süreyyapaşa Chest Diseases and Thoracic Surgery Training and Research Hospital, İstanbul, Turkey²Department of Neurology Diseases, Health Sciences University, Süreyyapaşa Chest Diseases and Thoracic Surgery Training and Research Hospital, İstanbul, Turkey

Introduction: Central nervous system (CNS) involvement is approximately 5-10% in tuberculosis (TB). Intracranial tuberculomas are in 10-20% of cases with CNS involvement. %2-8 of all intracranial tuberculomas are located in the brain stem. Localization of Tuberculomas may cause neurological symptom due to local pressure, epileptic seizures and neurological deficits due to increased intracranial pressure. It should be kept in mind that intracranial and brainstem tuberculomas may occur in patients with tuberculosis-diagnosed neurological symptoms. A 77-year-old man with cerebellar involvement with miliary pulmonary tuberculosis was discussed in the light of the literature.

Case Presentation: A 77-year-old male patient applied with complaints what was started suddenly headache, consciousness, speech and swallowing difficulties, weakness in extremity, unbalanced walking and urinary incontinence. Bronchoscopy was made because of miliary appearance on chest X-ray. Bronchial lavage was stained positive for acid-resistant bacteria (ARB). The first neurological examination of the patient referred to our clinic with pre-diagnosis of tuberculous meningitis had partly cooperative, apathetic, minimum dizartric speaking. He was understanding only simple orders. Palatal arc reflexes were decreased. IR+/, gag+/. Each of the four extremities was moving spontaneous but he didn't cooperate to the cerebellar examination. Trunkal ataxia was observed towards the left while sitting. Complete blood count, biochemistry and ELISA parameters were normal. He didn't throw the sputum, Trekeal aspiration sampling was made, mycobacteria tuberculosis was demonstrated by GENE-EXPERT PCR and Rifampicin was found to be sensitive. When oral intake was insufficient, nasogastric feeding was supported. With cranial MR imaging, the lesions dispersed bilaterally what were ring-like contrast that lesion involvements were hypointense in T1A sections, hyperintense in T2A sections, so that tuberculomas were considered. Tumoral lesions was consulted with the neurosurgery department for definitive diagnosis. And then it was decided to follow up. Quater TB and dexamethasone treatment were begun. Oral intake increased at 3 weeks of treatment. And then he started to set up simple sentences and become mobilized with support. The lesions was observed regression in the control MR imaging one month later. Due to the patient's current examination, clinical findings, radiological imaging follow-up, and antituberculous treatment response, it was decided that mass-like lesions in cerebellum and cerebrum were tuberculomas.

Conclusion: As in our country, patients who live in areas endemic for tuberculosis and who have loculated lesions in the brain stem were kept in mind for definitive diagnosis that tuberculomas should be considered. Early diagnosis and treatment shouldn't be forgotten that it is life saving.

Keywords: Tuberculomas, miliary tuberculosis, involvement of neurology

[Abstract:0313] PS-017 [Accepted:Poster Presentation] [Clinical Problems - Diffuse Parenchymal Lung Disease]

Antisynthetase Syndrome as a Cause of Interstitial Lung Disease

Fadime Sultan Albez¹, Meltem Alkan Melikoğlu², Elif Yılmazel Uçar¹¹Department of Chest Diseases, Atatürk University School of Medicine, Erzurum, Turkey²Department of Physical Therapy and Rehabilitation, Division of Rheumatology, Atatürk University School of Medicine, Erzurum, Turkey

Antisynthetase syndrome is an autoimmune disease in which autoantibodies against aminoacyl-tRNA synthetase enzyme are produced and it mostly presents with intersti-

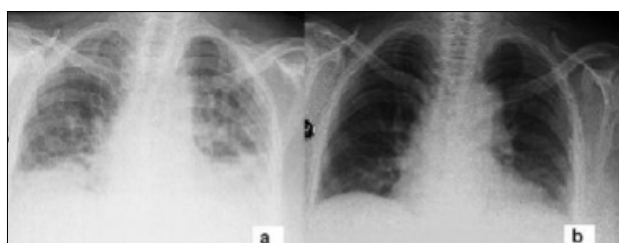

Figure 1. PA lung graphs, 1a: Before treatment, 1b: After treatment

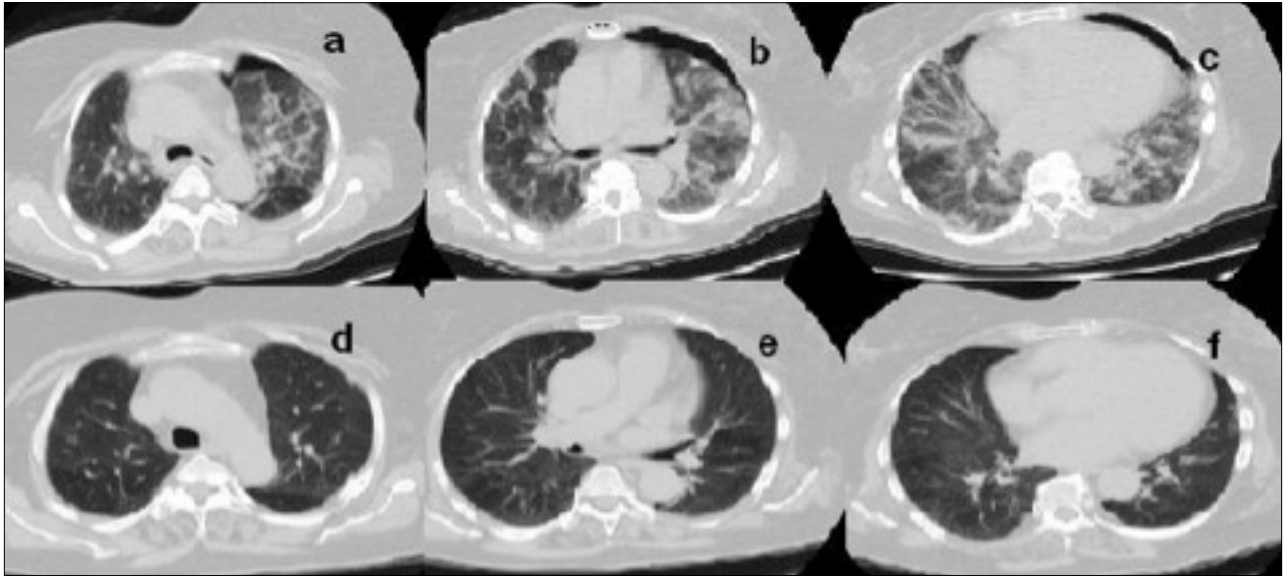


Figure 2. HRCT sections, (a-c) Before treatment, 2 (d-f) After treatment

tial lung disease (ILD) and its mortality is determined with ILD, and also it displays clinical features including myositis, Raynaud's phenomenon, and arthritis. The most common one of aminoacyl t-RNA autoantibodies is anti-Jo 1 autoantibody and in antisynthetase syndrome presenting with positive anti-Jo 1 antibody and coexisting with ILD, the prevalence of muscle symptoms (fatigue and myalgia) is significantly high. In the presence of anti-PL7 and anti-PL12 positivity, myositis is less observed, but the prognosis is poorer with severe ILD. In its treatment, other immunosuppressive agents can be used in patients not giving response to prednisolone. In this case presentation, it was aimed to draw attention to the antisynthetase syndrome requiring a multidisciplinary approach in its diagnosis, follow-up, and treatment.

Our patient was a 62-year-old female patient who defined dry cough and dyspnea lasting for one month. In her medical history, hypertension, Hashimoto's thyroiditis, and intermittent use of inhaler therapy for the diagnosis of asthma were included. Two months before the beginning of her complaints, her husband had died and she had no history of any inhaler exposure, any drug use except amlodipine and levothyroxine, and smoking. The physical examination of the patient, who had no feature in her familial history, was normal except tachypnea-dyspnea-hypoxia, and bibasilar rales in the inspirium. In the respiratory function test (RFT), restrictive pattern and DLCO loss was observed. The thoracic CT revealed diffuse ground glass appearance and consolidation areas in the parenchymas of both lungs. Interlobular septal thickenings, which were more apparent in the lower lobes, and partial sequela changes were observed. There were several lymph nodes, the largest of which was 12x6 mm, in the mediastinum. Her ejection fraction was 55% and pulmonary edema was not considered. In her biochemical examinations, there were no abnormalities except CRP value of 55, sedimentation value of 31, CK value of 63, and white blood cell count of 14.000 (neu:80%).

The prediagnosis of interstitial lung disease was made with bronchoalveolar lavage and transbronchial biopsy. The pathological examination revealed minimal increase in fibrotic tissue and focuses of inflammatory cell infiltration in the interstitial region. No granuloma or infiltrative pathology was reported to be observed. With this condition, the patient was accepted as non-specific interstitial pneumonia and etiological analysis was performed. In the examination of autoantibodies, only anti SS-A and anti-Jo1 positivity was found apart from microsomal Ab explaining Hashimoto's thyroiditis. While continuing her examinations, progressive muscle pain and fatigue preventing her to do daily activities occurred. She was begun 1 mg/kg/day dose of prednisolone. An increase in anti Jo-1 levels, which were simultaneously evaluated, was observed and CK levels were also elevated. The patient, whose EMG results were normal and other autoantibodies were negative, was diagnosed with antisynthetase syndrome. A response to prednisolone therapy was obtained in time. In the first year of 8 mg/day maintenance prednisolone therapy, total regression was observed in her clinical and radiological findings. No restriction was found in RFT and diffusion capacity. The levels of anti-Jo1 antibody were negative. By considering positive response to prednisolone therapy, the patient was begun to be followed up without any treatment. Although there are similar treatments with differential diagnoses, the definition of antisynthetase syndrome as a result of multidisciplinary approach will provide benefits to the clinician and patient for making correct detections on clinical variations and complications that can be encountered during follow-up and disease course and severity and for taking precautions for them.

[Abstract:0314] SS-109 [Accepted:Oral Presentation] [COPD]

Can Serum Eosinophil/Neutrophil Ratio Be A Marker for the Selection of Inhaler Treatment in Cases with Stable COPD?

Halil İbrahim Yakar, Erkan Ceylan, Asiye Kanbay

IMU Göztepe Education and Research Hospital, İstanbul, Turkey

Objectives: Neutrophil, macrophage and CD+8 T lymphocytes are the main cells that have a role in the pathophysiology of COPD. At present, some studies have demonstrated that eosinophils and T helper 2 cell-mediated inflammation also play an important role in the pathology of COPD. In this study, it was aimed to investigate eosinophil rate, eosinophil/neutrophil ratio (ENR), and the effect of ENR on the prediction of annual attack and hospitalizations rates in stable COPD cases.

Method: The examination results of stable COPD cases during their controls in the outpatient clinic were recorded. The eosinophil percentage above 2% in whole blood analysis was accepted as eosinophilia. The cases were put into two groups as those with and without eosinophilia. Patients with a known allergic disease, using allergy and immunosuppressive drugs, being bronchiectasis, having structural lung disease such as CF, and having active infection, hematological disease, and collagen tissue disease were excluded from the study. Demographic and laboratory findings of all patients were recorded.

Results: The study included 206 patients with stable COPD. A total of 127 patients were in the eosinophilic group (115 male, mean age 63.1 ± 10.1 years) and 79 were in the non-eosinophilic group (68 male, mean age 62.8 ± 10.0 years). In the comparison of demographic features of both groups, they were statistically found to be similar in terms of gender, comorbidities, and

Table 1. Comparison of clinical characteristics between stable COPD patients with eosinophilic and non eosinophilic patients

	Eosinophilic group	Non eosinophilic group	P value
Subjects, n	127	79	
Male, n (%)	115 (90)	68 (86)	0.98
Age (years) , mean \pm SD	61.3 \pm 10.1	62.8 \pm 10.0	p<0,001
BMI (kg/m ²) , mean \pm SD	27.6 \pm 5.4	27.4 \pm 4.8	p<0,001
Comorbidities, n %			
HT	16 (12.6)	11 (13.9)	p = 0.78
DM	12 (9.5)	6 (7.6)	p = 0.20
İCD	20 (15.8)	6 (7.6)	p = 0.86
CHF	2 (1.6)	5 (6.3)	p = 0.06
CVD	2 (1.6)	2 (2.5)	p = 0.62
Asthma History, n (%)	24 (18.8)	10 (12.6)	p = 0.24
Smoking History, n (%)			
Never	56 (44.1)	41 (51.9)	p = 0.27
Exsmoker	49 (38.5)	22 (27.8)	p = 0.11
Current smoker	22 (17.3)	16 (20.3)	p = 0.59
Smoking (PY) , mean \pm SD	31.2 \pm 13.5	25.5 \pm 14.8	p<0,001
Exacerbations/last year	0.76 \pm 0.11	0.50 \pm 0.10	p<0,001
mMrc score	1.43 \pm 0.63	1.33 \pm 0.65	p<0,001
COPD medication, n (%) *			
None	46 (36.2)	23 (29.1)	p = 0.29
IKS+LABA	52 (40.9)	45 (56.9)	p = 0.025
LAMA	30 (23.6)	22 (27.8)	p = 0.49
LABA	15 (11.8)	11 (13.9)	p = 0.65
SAMA	22 (17.3)	21 (26.5)	p = 0.11
SABA	16 (12.6)	6 (7.6)	p = 0.25
Theophylline	4 (3.1)	5 (6.3)	p = 0.15

Table 2. Baseline PFT, blood parameters and GOLD classification

	Eosinophilic group mean±SD	Non eosinophilic group mean±SD	P value
FEV1/FVC (%)	77.0±11.1	75.1±11.1	p<0,001
FEV1 (L/min)	2.03±0.77	1.92±0.80	p<0,001
FEV1 (%)	70.1±24.0	67.8±23.0	p<0,001
FVC (L/min)	2.93±3.81	2.52±0.93	p<0,001
FVC (%)	71.5±20.4	70.8±20.3	p<0,001
Leukocyte (mm ³)	7906±1883	8015±2600	p<0,001
Hemoglobin (g/dL)	13.80±1.48	13.31±1.30	p<0,001
Eosinophil count (cell/μL)	299±190	91±60	p<0,001
Eosinophil %	3.74±2.12	1.04±0.61	p<0,001
Neutrophil count (cell/mm ³)	4570±1550	5200±1875	p<0,001
Neutrophil %	56.6±8.2	64.1±9.5	p<0,001
Eosinophil/Neutrophil Ratio	0.07±0.04	0.02±0.01	p<0,001
CRP (mg/L)	0.90±0.21	1.76±0.42	p<0,001
GOLD classification, n (%)			
A	62 (48.8)	47 (59.5)	p = 0.13
B	37 (29.1)	26 (33.3)	p = 0.56
C	8 (6.3)	2 (2.4)	p = 0.22
D	19 (14.9)	4 (4.8)	p = 0.028

smoking history. However, in the eosinophilic group, the mean age was significantly lower but the mean mMrc dyspnea score, BMI, and smoking pack/year were significantly higher (Table 1). comorbidities were similar in both groups. In the eosinophilic COPD patients, leucocyte level and C-reactive protein (CRP) were found to be significantly lower ($p<0.001$, $p<0.001$, respectively) (Table 2). Eosinophilic COPD patients had more bronchial hyperreactivity history, but the difference was not statistically significant ($p=0.24$) (Table 1). Despite better RFT findings, the number of exacerbations in the last one year was higher in the eosinophilic group ($p<0.001$) (Table 1). In eosinophilic COPD patients, ENR value was found to be significantly higher than in the non-eosinophilic group ($p<0.001$). However, there was no significant relationship between ENR and GOLD stage groups ($f=0.84$, $p=0.47$) (Figure 1). When two groups were compared separately with regard to treatment choices, the use of ICS+LABA was detected to be lower in the eosinophilic group ($p=0.025$). The rates of the uses of other bronchodilator drugs were statistically similar.

Conclusion: ENR was found to be higher in the eosinophilic COPD patients ($p<0,001$). However, there was no significant relationship between GOLD stage and ENR in the eosinophilic COPD cases. Although RFT results were better in the eosinophilic COPD group in which ENR was high, the use of ICS was significantly lower and the number of exacerbations was significantly higher. In D group, the number of eosinophilic COPD patients was significantly higher compared to the non-eosinophilic group. Although RFT results were better in the eosinophilic COPD group in which ENR was high, the use of inhaler CS was observed to be significantly lower and the number of exacerbations was significantly higher. Therefore, we suggest that the use of ICS should be given priority in patients whose ENR value is high.

Keywords: COPD, Eosinophil/Neutrophil Ratio, inhaler corticosteroid, GOLD stage

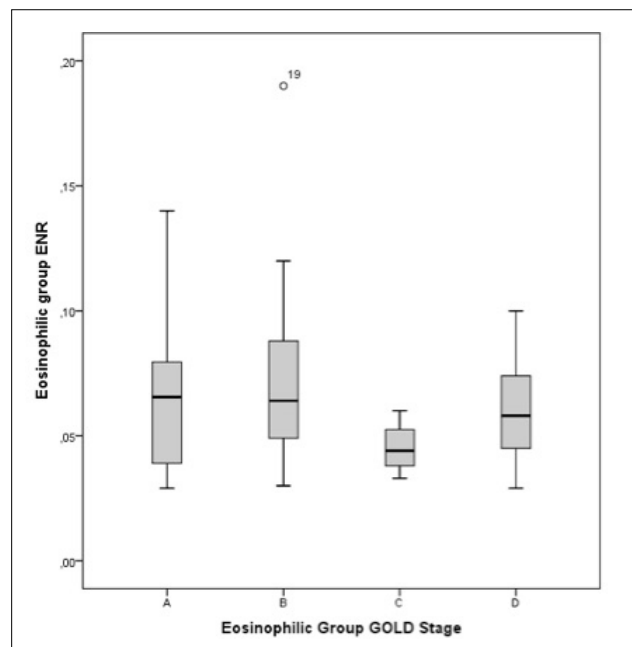


Figure 1. Association between Eosinophilic group ENR and GOLD stages. Notes: GOLD stage 1 (n=62), GOLD stage 2 (n=37), GOLD stage 3 (n=8), GOLD stage 4 (n=19). Data analyzed with one-way analysis of variance with Tukey post hoc test ($F=0,84$, $p=0,47$). Error bars represent 95% CIs.

[Abstract:0315] SS-031 [Accepted: Oral Presentation] [Respiratory Failure and Intensive Care]

Current Interventions for the Prevention of Ventilator Associated Pneumonia in Turkish Intensive Care Units: Turkish Thoracic Society Critical Care Assembly Point Prevalence Trial

Özlem Yazıcıoğlu Moçin¹, Özlem Edipoğlu², Ezgi Özyılmaz³, Cüneyt Saltürk¹, Tuğba Önalın⁴, Gülşah Seydaoğlu⁵, Zerrin Özçelik⁶, Sema Kultufan⁷, İskender Kara⁸, Atilla Kara⁹, Emine Dağlı¹⁰, Selma Duru Bülbül¹⁰, Kadriye Kahveci¹¹, Metin Dinçer¹¹, Nimet Şenoğlu¹², Hüseyin Özkarakaş¹², İlhan Bahar¹³, Melike Cengiz¹⁴, Atilla Ramazanoğlu¹⁴, Burcu Çelik¹⁴, Ümmügülsün Gaygısız¹⁵, Gülay Kır¹⁶, Ahmet Bindal¹⁷, Belgin Akan¹⁷, Işıl Özkoçak Tuan¹⁷, Fatma Yıldırım¹⁸, Burcu Başarık¹⁹, Zeliha Arslan Ulukan²⁰, Serdar Efe²¹, Murat Sungur²², Şahin Temel²², Seval İzdeş²³, Derya Hoşgün²³, Nurhan Karadeniz²⁴, Eylem Tunçay², Nezihe Çiftarslan Gökşenoğlu², İlim Irmak², Utku Datlı²⁵, Avşar Zerman²⁶, Devrim Akdağ²⁷, Levent Özdemir²⁸, Gülseren Elay²⁹, Yücel Karaçayır³⁰, Arzu Topeli³¹, Pervin Hancı³¹, Esat Kıvanç Kaya³¹, Pınar Güven³², Hilal Sazak³³, Semih Aydemir³³, Gülbın Aygencel³⁴, Yusuf Aydemir³⁵, Zahide Doğanay³⁶, Özgür Kömürçü³⁶, Volkan Hancı³⁷, Emre Karakoş³⁸, Didem Sözütek³⁸, Güven Coşkun³⁹, Güngör Ateş⁴⁰, Civan Tiryakı⁴⁰, Ayşe Nur Soytürk⁴¹, Nermin Kelebek Girgin⁴¹, Gülbahar Çalıřkan⁴¹, Oben Bıyıklı⁴², Necati Gökmen⁴³, Uğur Koca⁴³, Aydın Çiledağ⁴⁴, Kezban Özmen Süner⁴⁵, İsmail Cinel⁴⁶, Mustafa Kemal Arslantaş⁴⁶, Fethi Gül⁴⁶, Sena Ataman¹, Cenk Kıraklı¹, Fevziye Tuksavul¹, Recai Ergün⁴⁷, Nafiye Yılmaz⁴⁸, Defne Altıntaş⁴⁹, Leyla Talan⁴⁹, Murat Yalçınsoy⁵⁰, Mehmet Nezir Güllü⁵¹, Perihan Ergin Özcan⁵², Günseli Orhun⁵², Yusuf Savran⁵³, Murat Emre okur⁵³, Serdar Akpınar⁵⁴, Pelin Şen⁵⁵, Gül Gürsel⁵⁶, İrem Şerifoğlu⁵⁷, Ender Gedik⁵⁷, Öner Abidin Balbay⁵⁸, Türkay Akbaş⁵⁸, Sinem Cesur⁵⁸, Hülya Yolaçan⁵⁹, Seda Beyhan Sagmen⁶⁰, Pervin Korkmaz Ekren⁶¹, Feza Bacakoğlu⁶¹, Begüm Ergen⁶², Ersin Günay⁶³, Muzaffer Sarıaydın⁶³, Dursun Ali Sağlam⁶⁴, Sait Karakurt⁶⁵, Emel Eryüksel⁶⁵, Turgay Çelikel⁶⁵, Hüseyin Arıkan⁶⁵, Funda Öztuna⁶⁶, Emine Sevil Ayaydın Mürtezaoğlu⁶⁶, Hakan Cinemre⁶⁷, Ahmet Nalbant⁶⁷, Öznur Yağmurkaya⁶⁷, Tuğba Mandal⁶⁸, Belgin İkidağ⁶⁹

¹Department of Chest Diseases and Thoracic Surgery, Süreyyapaşa Training and Research Hospital, İstanbul, Turkey

²İzmir Dr Suat Seren Chest Diseases and Surgery Training and Research Hospital, İzmir, Turkey

³Çukurova University School of Medicine Balcalı Hospital, Adana, Turkey

⁴İzmir Çiğli District Hospital, İzmir, Turkey

⁵Department of Biostatistics, Çukurova University School of Medicine, Adana, Turkey

⁶Balıkesir State Hospital, Balıkesir, Turkey

⁷Ankara Yüksek İhtisas Training and Research Hospital, Ankara, Turkey

⁸Konya Numune Hospital, Konya, Turkey

⁹Sivas Numune Hospital, Sivas, Turkey

¹⁰Tarsus State Hospital, Mersin, Turkey

¹¹Ankara Ulus State Hospital, Ankara, Turkey

¹²University of Health Sciences İzmir Tepecik Training and Research Hospital, İzmir, Turkey

¹³Van Training and Research Hospital, Van, Turkey

¹⁴Akdeniz University Hospital, Antalya, Turkey

¹⁵Erzurum District Training and Research Hospital, Erzurum, Turkey

¹⁶Gazi Osmanpaşa Taksim Training and Research Hospital, İstanbul, Turkey

¹⁷Ankara Numune Training and Research Hospital, Ankara, Turkey

¹⁸Ankara Dışkapı Yıldırım Beyazıt Training and Research Hospital, Ankara, Turkey

¹⁹Denizli State Hospital, Denizli, Turkey

²⁰Medicana International İstanbul Hospital, İstanbul, Turkey

²¹Trakya University Health Research and Application Hospital, Edirne, Turkey

²²Erciyes University School of Medicine Hospital, Kayseri, Turkey

²³Ankara Atatürk Training and Research Hospital, Ankara, Turkey

²⁴Manisa State Hospital, Manisa, Turkey

²⁵Kütahya Evliya Çelebi Training and Research Hospital, Kütahya, Turkey

²⁶Adana Numune Training and Research Hospital, Adana, Turkey

²⁷Çukurova University School of Medicine Balcalı Hospital, Adana, Turkey

²⁸Dörtöl State Hospital, Hatay, Turkey

²⁹Gaziantep Dr Ersin Arslan Training and Research Hospital, Gaziantep, Turkey

³⁰Muğla Sıtkı Koçman University Training and Research Hospital, Muğla, Turkey

³¹Hacettepe University School of Medicine Hospital, Ankara, Turkey

³²Bolu İzzet Baysal State Hospital, Bolu, Turkey

³³Ankara Atatürk Chest Diseases and Surgery Training and Research Hospital, Ankara, Turkey

³⁴Gazi University School of Medicine Hospital, Ankara, Turkey

³⁵Sakarya University Training and Research Hospital, Sakarya, Turkey

- ³⁶Samsun Training and Research Hospital, Samsun, Turkey
³⁷Dokuz Eylül University School of Medicine Hospital, İzmir, Turkey
³⁸Çukurova University School of Medicine Balcalı Hospital, Adana, Turkey
³⁹Afyonkarahisar State Hospital, Afyon, Turkey
⁴⁰Memorial Diyarbakir Hospital, Diyarbakir, Turkey
⁴¹Uludağ University School of Medicine Hospital, Bursa, Turkey
⁴²İzmir Central Hospital, İzmir, Turkey
⁴³Dokuz Eylül University School of Medicine Hospital, İzmir, Turkey
⁴⁴Ankara University School of Medicine Hospital, Ankara, Turkey
⁴⁵Konya Training and Research Hospital, Konya, Turkey
⁴⁶Marmara University Pendik Training and Research Hospital, İstanbul, Turkey
⁴⁷Ankara Dışkapı Yıldırım Beyazıt Training and Research Hospital, Ankara, Turkey
⁴⁸Atatürk University Health Research and Application Hospital, Erzurum, Turkey
⁴⁹Ankara University School of Medicine Hospital, Ankara, Turkey
⁵⁰İnönü University School of Medicine Hospital, Malatya, Turkey
⁵¹University of Health Sciences Diyarbakir Gazi Yasargil Training and Research Hospital, Diyarbakir, Turkey
⁵²İstanbul University İstanbul School of Medicine Hospital, İstanbul, Turkey
⁵³Dokuz Eylül University School of Medicine Hospital, İzmir, Turkey
⁵⁴Ankara Dışkapı Yıldırım Beyazıt Training and Research Hospital, Ankara, Turkey
⁵⁵İstanbul Başkent University Hospital, İstanbul, Turkey
⁵⁶Gazi University School of Medicine Hospital, Ankara, Turkey
⁵⁷Ankara Başkent University Hospital, Ankara, Turkey
⁵⁸Düzce University Health Research and Application Hospital, Düzce, Turkey
⁵⁹Eskişehir Yunus Emre State Hospital, Eskişehir, Turkey
⁶⁰University of Health Sciences Dr Lütfi Kırdar Kartal Training and Research Hospital, İstanbul, Turkey
⁶¹Ege University School of Medicine Hospital, İzmir, Turkey
⁶²Dokuz Eylül University School of Medicine Hospital, İzmir, Turkey
⁶³Afyon Kocatepe University Ahmed Necdet Sezer Research and Application Hospital
⁶⁴Ankara Atatürk Training and Research Hospital, Ankara, Turkey
⁶⁵Marmara University Pendik Training and Research Hospital, İstanbul, Turkey
⁶⁶Karadeniz Technical University School of Medicine, Trabzon, Turkey
⁶⁷Sakarya University Training and Research Hospital, Sakarya, Turkey
⁶⁸Adıyaman University Training and Research Hospital, Adıyaman, Turkey
⁶⁹SEV American Hospital, Gaziantep, Turkey

Objectives: Ventilator associated pneumonia (VAP) is a common cause of nosocomial infection which is associated with a significant utilization of health care resources and also mortality. Thus, VAP prevention measures are increasingly being adopted as a quality of care indicator in intensive care units (ICU) around the world. Endotracheal tube biofilm formation and microaspiration of oropharyngeal secretions, contaminated by endogenous flora, remain as key mechanisms for the development of VAP and are the target of several intervention strategies. The aim of this study is to evaluate the VAP prevention strategies currently used in Turkish ICUs.

Methods: A cross sectional point prevalence study was performed to answer the study question. Data from 67 ICUs were collected between October 26th 08:00 AM-October 27th 2017 08:00 AM. Questionnaires including data about prevention of VAP were completed. Ethical approval was obtained from Ethics Committee for Non Invasive Researches of Faculty of Medicine, Cukurova University.

Results: Nine hundred and twenty-one patients (58.6% male) were included for the study. Mean APACHE II, q SOFA and GCS results of the patients were 18.5 ± 8.8 , 1.4 ± 1.4 and 10.2 ± 4.3 , respectively. The mean hospitalization day was 20 ± 70 days. From several VAP prevention strategies, the most commonly used was elevation of the head of bed (81.8 %), venous thromboembolism prophylaxis (80.6%), peptic ulcer prophylaxis (80.4%) and enteral feeding (50.2%). In addition, mobilization of the patient (21.6%), oral care (4.1%), sedation interruption and weaning attempt on the study day (8.3 and 16.2%) were performed. Other methods including subglottic aspiration and isolation of the patient were used as 1 % of the study group. When the VAP prevention methods compared among different types of ICUs, elevation of the head of bed and peptic ulcer prophylaxis were more commonly used in medical ICUs (92.9 % and 88.6%, respectively) then general (81.4% and 77.2%) and respiratory ICUs (75.1 and 75.8%) ($p=0.02$ and $p=0.01$).

Conclusion: Medical VAP prevention strategies are widely used in Turkish ICUs however more attention should be given to behavioural barriers especially hand hygiene in order to decrease VAP rates in our country.

Keywords: Ventilator associated pneumonia, point prevalence, intensive care unit

[Abstract:0317] SS-070 [Accepted:Oral Presentation] [Tobacco Control]

How Does Reimbursement Status Affect The Smoking Cessation Interventions?

Hüseyin Koşak¹, Dilek Karadoğan¹, Özgür Önal²,

¹Department of Chest Diseases, Recep Tayyip Erdoğan University School of Medicine, Rize, Turkey

²Department of Public Health, Local Health Authority, Burdur, Turkey

Objectives: In our country in the last decade smoking cessation outpatient clinics (SCC) were extended to provide counseling to smokers for their quit attempts. At first only counseling was under coverage of health insurances. Afterwards, in year 2011 and 2015 free varenicline and bupropion preparats were distributed to SCC by Turkish Ministry of Health and each period longed for 1.5 years. There is no study in the literature that directly compares the outcomes of free medication periods with the other periods in our country. Therefore in that study we aimed to compare both periods' outcomes and our study will be important to guide SC interventions.

Methods: Patients applied to SCC in a secondary health care unit between June 2014- June 2017, evaluated available for SC interventions and had the record of phone visits at their third months were included to the study. Patients were grouped and evaluated according to reimbursement status; free counselling period-1 (First period) (July 2014- March 2015) , free counselling+free medication period (Second period) (April 2015- December 2016) , free counselling period-2 (Third period) (January 2017-June 2017) . For the logistic regression analysis they were grouped under only two categories according to coverage of the medications; free period (FP) group, not-free period (NFP) group.

Results: Totally 733 patients applied to SCC and 77.7% of them had applied at the second period. Mean monthly admission numbers were 15, 38 and 6 respectively for the first, second and third periods. Among the total number 417 patients' data were available for the analysis according to the inclusion criterias, 346 of them were in FP group. Mean age of the patients was 44.0±13.7, 65% of them was male. Demographic characteristics of patients in both groups were similar, while rate of patients who had comorbid diseases were lower in FP (p<0.05) . Treatment choices were different, rate of patients that used adviced treatment at least 30 days (treatment adherent) and rate of quitters at third month were higher in FP (p<0.05) . Bupropion prescribed group's rate was similar, however varenicline was mostly prescribed in FP while ninotine replacement therapy was mostly prescribed in NFP (p<0.05) .

Conclusion: Our study showed that free medication period increased not only the quit attempts but also the treatment adherence and quit success of the smokers. Additionally, irregular coverages became confusing both for clinicians and patients. Therefore coverage of smoking cessation medications should be consistently and include all used forms of the medications.

Keywords: Smoking cessation, coverage, reimbursement, varenicline, bupropion

[Abstract:0318] SS-096 [Accepted:Oral Presentation] [Tobacco Control]

Commercial Presentation of Waterpipe Tobacco Must Be Banned: Web-Based Search Results, 2017 İstanbul

Efza Evrengil

Turkish National Committee on Tobacco and Health

Objectives: International tobacco control literature raises concern over increasing prevalence of commercial presentation of waterpipe tobacco (WPT) and its café culture. Studies conducted in Turkey also indicate that the number of venues commercially presenting WPT, along with a variety of hospitality and entertainment functions geared toward the youth, is rapidly rising, there are political/social dynamics stimulating this process, commercially presented WPT is almost entirely illicit, and legislation aiming at putting this industry under control is failing.

Methods: As of 12 June 2017, on zomato.com.tr, a web-based restaurant search service, 1.272 venues commercially presenting WPT were identified in İstanbul, which were examined according to types and geographic location. With regard to the

first most popular 350 venues in this list, photographs (835,379) , dated 2015 and after, published on webpages assigned to these venues in zomato.com.tr and tfoursquare.com, and if available on their own websites, were scrutinised for photographic evidence for (a) cigarette or waterpipe smoking in enclosed space, (b) compulsory health warnings on waterpipe devices, (c) little children as customers, and (d) illicit products mentioned on their WPT menus.

Results: Out of 1.272 venues, 56.4% were classified as restaurants, 30.6% cafés, 6.2% bars, 5.9% fast-food places, and 0.9% patisseries. 16.6% of establishments were located in the historic peninsula, 28.3% in other central districts, and 55.1% in suburban districts. Out of 350 venues, 90% featured indoor smoking, 1.1% compulsory health warnings on devices, 31.1% attendance of toddlers and small children, 7.4% kids menus, 5.1% children's events, 1.7% playrooms, and 4.9% playgrounds. WTP menus available on internet (75.1%) mentioned illicit brand names (63.5%) and illicit flavours/mixtures (90.1%) .

Conclusion: Study findings denote three fundamental problems related to commercial presentation of WPT:

- Given its duration, WPT smoking is practiced as an indoor activity particularly in adverse weather conditions, resulting in management policies entirely dismissive of smoke-free rules.
- In a mixed use environment, children and other non-smokers inadvertently get exposed to tobacco smoke and WPT culture.
- Practical, profitable, and commonplace, the use of illicit WPT, additional ingredients, and on-site manufactured mixtures make product presentation impossible to regulate, inspect, and standardize. In stark contradiction to tobacco control and consumer protection legislations and causing serious impasse for public health, these problems may only be solved by questioning legal and social legitimacy of commercial presentation of WPT.

Keywords: Commercial presentation, tobacco control policy, waterpipe tobacco

[Abstract:0319] SS-071 [Accepted:Oral Presentation] [Tobacco Control]

Turkish Experience at the Intersection of Neoliberal Capitalism and Tobacco Control

Efza Evrengil

Turkish National Committee on Tobacco and Health

Objectives: An influential mainstream literature purposefully steering theory and practice of tobacco control economics asserts that tobacco control as a public health policy and neoliberal policies of trade liberalization, foreign direct investment incentives, and privatization can be jointly realised as validated by alleged success of Turkey. This study, employing the same Turkish case, aims at questioning these assertions and policy recommendations, by shedding light on empirical manifestations of interplay between neoliberal policies aiming at supply-side growth and tobacco control strategies for demand reduction.

Methods: Law 4733 which crystalized neoliberal fundamentals for tobacco products market in Turkey, other relevant regulations, and their implementations during 2003-2017 were analysed with official tobacco products market data, dual character and illicit market estimates based on secondary sources and media monitoring results for 2015-2017.

Results: Despite declining consumption trend observed since 1999, during 2003-2017, licenced tobacco product volumes grew progressively. E.g., on average, each year cigarette manufacturing rose by 3 billion sticks, and each month 2 new cigarette brands were put on the market. In addition to taxation policies, boosting industry and government revenues but having minor consumption impact, incentives relentlessly enlarging tobacco manufacturing capacities were enacted. These policies eventually caused consumption to enter an upward trend in the last five years. In addition to smuggled cigarettes with a market share of 7.5% in 2017, domestic illicit tobacco consumption, estimated at 15,000 tonnes for 2016 by Tobacco Experts Association, grew drastically in recent years. Equivalent to 20.5 billion cigarette sticks, this consumption tallies with 19 billion legal empty cigarette tubes sold same year. Consequently, illicit market share in total cigarette consumption has reached an unprecedented level (27%). Illicit market volumes are also strikingly high for other tobacco products. This situation emerged from exacerbated conflict of interest between transnational tobacco companies having oligopoly status, domestic capital groups demanding legality and a piece from the lucrative tobacco market, and downtrodden farmers, resulting in regulatory squabble in 2017.

Conclusion: The facts that both legal and illicit markets have grown concomitantly and consumption trend changed direction show that in Turkey neoliberal policies have had a far larger de facto impact, and Law 4733 failed to achieve market effi-

ciency. The rectification of this picture which defies FCTC objectives, principles, and obligations calls for abandonment of neoliberal policies as a prerequisite for effective tobacco demand reduction, through instituting public control and planning over manufacturing and trade in order to extinguish tobacco supply.

Keywords: Neoliberal policies, tobacco consumption, tobacco control economics

[Abstract:0320] EPS-034 [Accepted: E-Poster] [Clinical Problems - Diffuse Parenchymal Lung Disease]

A Case from Cryptogenic Organization Pneumonia

Mihrican Yeşildağ, Zuhale Şentürk

Department of Chest Diseases, SBU Konya Training and Research Hospital, Konya, Turkey

Objectives: Cryptogenic organization pneumonia (COP) is a rare clinicopathological condition, which is characterized by an inaccurate healing of the inflammatory response existing in the alveoli as a result of an unknown damage. We aimed to present a case of COP that we diagnosed with CT- guided transthoracic lung biopsy in terms of diagnosis and treatment approaches.

Case Presentation: A 68-year-old female patient was admitted to hospital twice with severe right side pain and flu-like symptoms and pneumonia for three to four weeks. There was no trait in the history of the patient and her relatives as well. Her hemogram values, CRP, ESR, D-dimer, biochemical markers, collagen biomarkers were within normal limits. Her pulmonary function tests and blood gas analyzes were too within normal limits. On her chest X-ray, a homogeneous consolidation based on pleura area was observed in the lower right zone (Figure1) . In her Thorax CT, a consolidation area in the right lower lobe, appearance of a tree buds in right lung lower, middle, upper lobe posterior and left lung lingular segment were observed (Figure 2). The patient underwent fiberoptic bronchoscopy and lavage. Her lavage Asido rezistan bacteria (ARB) and three times sputum ARB was negative and lavage pathology didn't include this property. CT-guided transthoracic lung biopsy was performed on the patient. The biopsy was reported as organizing pneumonia. The patient underwent corticosteroid therapy and the treatment was completed in a year through decreasing the dose. In the patient's control films, all the lesions were observed to have disappeared and been clinically resolved (Figure 3) .

Conclusion: Cryptogenic Organization Pneumonia (COP) is a disease known to develop as idiopathic too with its etiology having aspiration pneumonia, toxic gas inhalation, transfusion and radiotherapy and viral infections. Patients usually have a similar picture of upper respiratory tract infections or pneumonia. In their pulmonary imaging, the displacement of consolidation areas placing in the pleura is specific to the COP. It is diagnosed through bronchoscopy, bronchoalveolar lavage (BAL), and biopsy. It can be definitively diagnosed through fine-needle biopsy along with imaging methods, but for the pathologic evaluation to be not compatible with COP doesn't exclude the recognition of the diagnosis. In its treatment, corticosteroids are the first-line treatment and generally this treatment is well tolerated. In our case, definitive diagnosis was made with

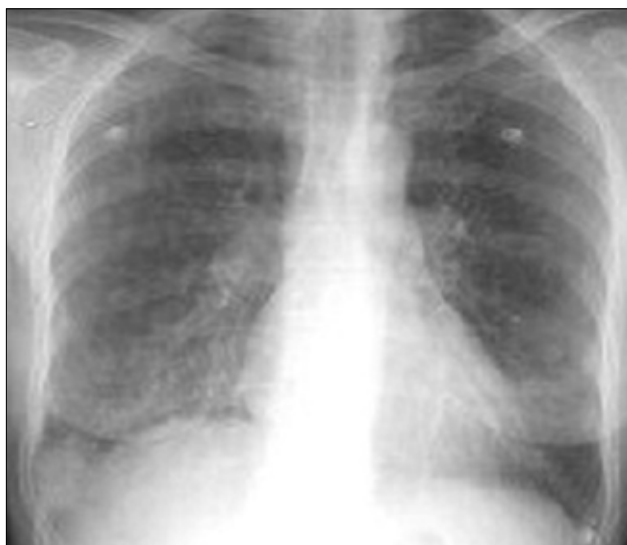

Figure 1. Chest X-ray shows a homogeneous consolidation based on pleura area in the low right zone

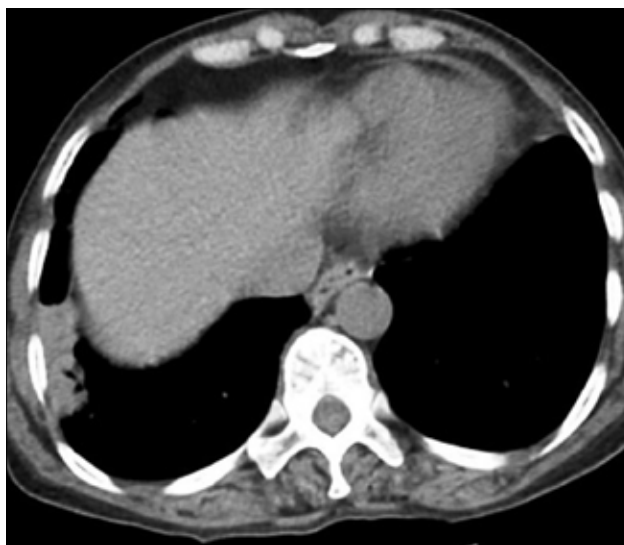


Figure 2. Thorax CT shows a consolidation area in the right lower lobe

guided transthoracic lung biopsy and the response to corticosteroid treatment was very good and the patient is still followed without any relapses.

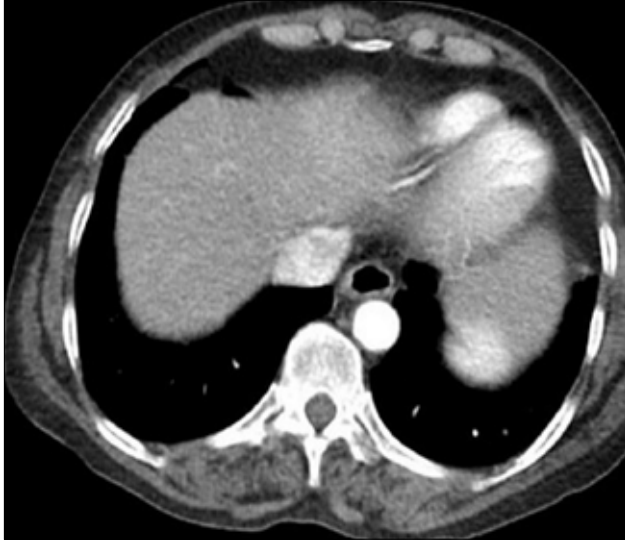


Figure 3. Control Thorax CT shows disappeared all lesions

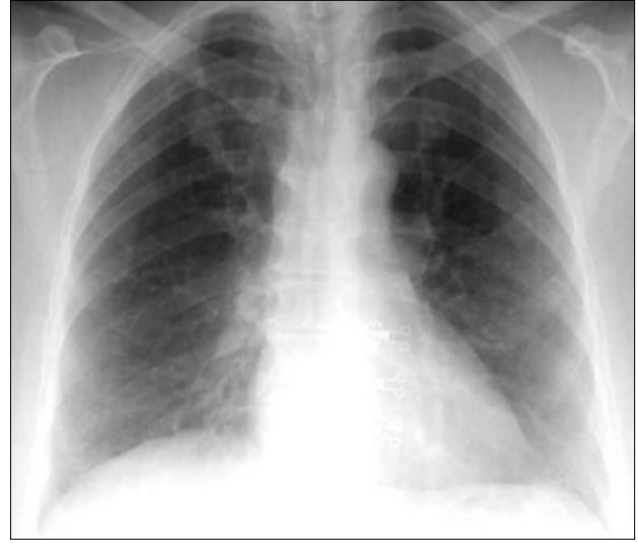


Figure 4. Control Chest X-ray shows disappeared all lesions

Keywords: Biopsy, Cryptogenic Organizing Pneumonia, corticosteroid

[Abstract:0321] SS-135 [Accepted:Oral Presentation] [Respiratory Failure and Intensive Care]

Why Does NIV Failure in Expert Hands in the ICU Even Hypercapnic Respiratory Failure in Patients with COPD?

Sinem Güngör, Emine Aksoy, Nezihe Çiftaslan Gökşenoğlu, Eylem Tunçay, Birsen Ocaklı, İlim Irmak, Cüneyt Saltürk, Nalan Adıgüzel, Özlem Yazıcıoğlu Maçın, Zuhul Karakurt

Health Sciences University Süreyyapaşa Chest Diseases and Thoracic Surgery Health Search and Application Center, İstanbul, Turkey

Objectives: Chronic obstructive lung diseases (COPD) patients with severe acidosis ($\text{pH} < 7.25$), critical state (APACHE II > 29), severe hypercapnic ($\text{PaCO}_2 > 92 \text{ mmHg}$) and low Glasgow coma scale ($\text{GCS} < 11$) have high risk for noninvasive ventilation (NIV) failure. This study was aimed to answer, if NIV performed in intensive care unit (ICU) with expert team, why NIV failure in patients with defined failure risk factors and evaluated short and long-term survival in NIV failure patients.

Methods: Retrospective cohort study was done in a level 3 ICU of a tertiary teaching university hospital. All consecutive previously COPD diagnosed patients with hypercapnic ($\text{PaCO}_2 > 45 \text{ mmHg}$ and with/without hypoxemic, $\text{PaO}_2/\text{FiO}_2 < 300$) acute respiratory failure (ARF) were enrolled in study period (November 2015-November 2016). All patients' demographics, comorbidities, arterial blood gases (ABGs) on the admission to ICU, at NIV failure and at discharge from ICU and patients' ICU data, biochemistry, reasons of ARF, reasons of NIV failure, length of ICU stay, hospital, 28th day-12 month mortality recorded. NIV failure was defined as cardiac arrest during NIV and intubation. NIV failure and NIV success group were compared according to recorded data. NIV failure risk factors in the ICU and short and long term mortality were analyzed.

Results: In study period, 407 COPD patients were admitted to study, NIV success and NIV failure patients were 265 versus 142. NIV success and NIV failure patients median APACHE II; 19 (17-21) and 26 (22-29) ($p < 0.001$). Septic shock (OR:22.4), sepsis (OR:5.5), higher APACHE-II (≥ 29) (OR:9.9), lower pH (≤ 7.25) (OR:6.5), higher Charlson index (OR:1.3) were found significantly NIV failure risk factors. COPD patients using domiciliary NIV had less risk for NIV failure (OR: 0.42). The mortality rate for NIV failure and NIV success in the ICU %41.5 vs 0, and after ICU discharge 28th day 14.5% vs 3% and one year 53% vs 30.6% respectively.

Conclusion: NIV application with NIV expert team to critically ill COPD patients due to hypercapnic ARF could be failed if they had severe infections lead to septic shock in the ICU. During follow up, there will be still higher risk of mortality for those COPD patients with NIV failure.

Keywords: Noninvasive ventilation, failure, COPD, respiratory failure

[Abstract:0323] EPS-135 [Accepted: E-Poster] [Pulmonary Pathology]

Nodular Trachea due to One Case: Tracheobronchopathia Osteochondroplastica

Mihrican Yeşildağ¹, Zuhal Şentürk¹, İlknur Küçükosmanoğlu²

¹Department of Chest Diseases, SBU Konya Training and Research Hospital, Konya, Turkey

²Department of Pathology, SBU Konya Training and Research Hospital, Konya, Turkey

Objectives: Tracheobronchopathia Osteochondroplastica (TO) is a rare benign disease entity characterized by development of nodules in the trachea. We aim to present a typical case of TO with chronic cough and repeated hospital admission with recurrent upper and lower respiratory tract infections which we diagnosed by fiberoptic bronchoscopy.

Case Presentation: A 60-year-old man was admitted to our clinic with a history of dry cough proceeding for approximately three years and frequent recurrent upper and lower respiratory tract infections. There was no history of family and background. Routine blood tests, collagenous markers, sputum ARB and pulmonary function tests were within normal limits. There was nothing significant in his chest radiograph. There were three thorax tomography taken during the patient's admission. Only in one tomography report, calcification nodules, milimetric formations causing minimal irregularity in the trachea wall were reported (Figure 1). Fiberoptic bronchoscopy was performed seeing that he had recurrent infective episodes and complaints of long-standing ongoing dry cough. Fiberoptic bronchoscopy revealed numerous white irregular nodules extending from the anterior and lateral walls of the trachea to the carina (Figure 2). In addition, it was observed that the trachea posterior wall was preserved. FOB biopsy result was reported to be associated with supmucosal cartilaginous nodules, sometimes with calcification and ossification foci (Figure 3). Nonspecific treatment was planned for cough and recurrent infections and the patient was followed up. The patient has been followed up for one year with complaints of coughing developing intermittently.

Conclusion: Tracheobronkopatia Osteochondroplastica (TO) is a rare, generally asymptomatic and benign disease that is often characterized by slowly growing multipl submucosal bone and cartilaginous nodules extending into the lumen of tracheobronchial tree. The preservation of the posterior wall of the tracheobronchial tree and the preservation of the anterolateral wall of the nodules is a typical feature that can be observed bronchoscopically. Its etiology and pathology are still unclear. Specific identification can be made by fiberoptic bronchoscopy (FOB) and histopathologic examination. TO should be considered for recurrent upper and lower respiratory tract infections and cough separator. We believe that the radiologic definitions may lead the clinician to early bronchoscopy and diagnosis. If we can recognize this TO by the case of FOB, but if we look back, we can show that it can be recognized earlier with thorax CT. In conclusion, TO is a rare disorder and should be considered in the differential diagnosis of calcified lesions of the trachea.

Keywords: Fiberoptic bronchoscopy, chronic cough, nodular trachea

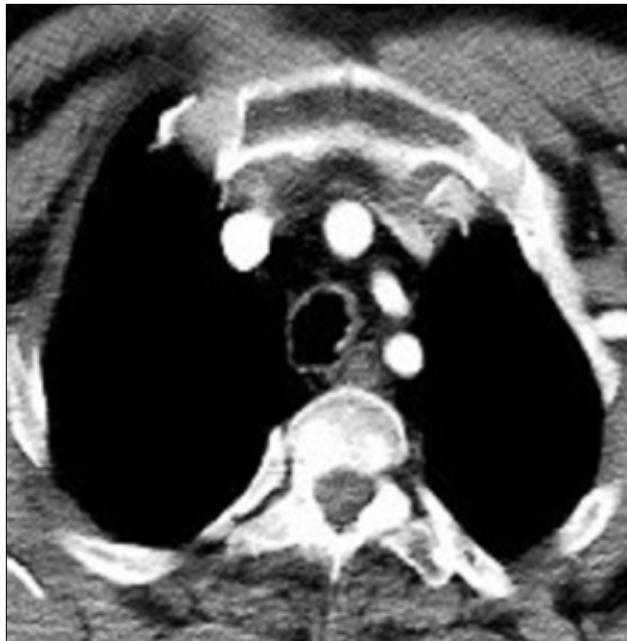

Figure 1. Thorax CT shows calcification nodules, milimetric formations causing minimal irregularity in the trachea wall

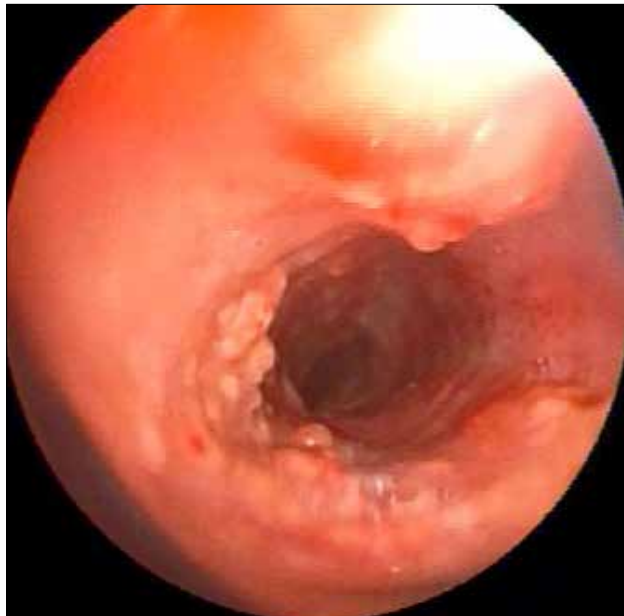

Figure 2. Fiberoptic bronchoscopy shows numerous white irregular nodules extending from the anterior and lateral walls of the trachea to the carina

[Abstract:0325] SS-082 [Accepted:Oral Presentation] [Pulmonary Rehabilitation and Chronic Care]

Pulmonary Rehabilitation after Lung Transplantation; First Experiences

İpek Özmen¹, Elif Yıldırım¹, Özgür Yılmaz², Mustafa Vayvada³, Sevkan Caner³, Meral Karakış², Rüya Aydın², Merih Balcı⁴, Murat Öztürk²

¹Department of Chest Disease, Health Science University Süreyyapasa Chest Disease and Thoracic Surgery Training and Research Hospital, İstanbul, Turkey

²Pulmonary Rehabilitation Unit, Health Sciences University Süreyyapasa Chest Disease and Thoracic Surgery Training and Research Hospital, İstanbul, Turkey

³Clinic of Lung Transplantation, Kartal Koşuyolu Yüksek İhtisas Heart Training and Research Hospital, İstanbul, Turkey

⁴Department of Chest Disease, Yeni Yüzyıl University School of Medicine, Gaziosmanpasa Hospital, İstanbul, Turkey

Objectives: The aim of the study is to investigate the effect of pulmonary rehabilitation (PR) after lung transplantation.

Methods: Patients who had lung transplantation between December 2014 -December 2017 and participated in PR were evaluated retrospectively. The quality of life (St. George's Respiratory Questionnaire=SGRQ) and exercise capacities (6-min walk test) of patients before and after PR were evaluated. An 8-week (2 days/week) outpatient PR programme.

Results: Seven male and one female patients with a mean age of 48±13 were included in the study. The diseases that lead to lung transplantation were Usual interstitial pneumonia (5) , emphysema (1) and cystic fibrosis (2) , respectively. The 6 min walk test before and after PR was median 411m (282-461) , 486m (442-544) p=0.012, the SGRQ score before and after PR was median 35.5 (20.3-74.4) p=0.012.The anxiety score before and after PR was median 4 (3-9) , 2 (1.9-8) p=0.039.

Conclusion: A comprehensive PR program as well as medical treatment and close follow-up after lung transplantation, is essential to increase exercise capacities and quality of life.

Keywords: Pulmonary rehabilitation, lung transplantation, quality of life, 6 min walk test

[Abstract:0327] EPS-025 [Accepted: E-Poster] [Clinical Problems - Diffuse Parenchymal Lung Disease]

Diffuse Alveolar Hemorrhage Developing in Ibuprofene Use: Case and Literature Review

Mihrican Yeşildağ, Zuhâl Şentürk

Department of Chest, SBU Konya Education and Research Hospital, Konya, Turkey

Objectives: Diffuse Alveolar Hemorrhage (DAH) is a disease characterized by disturbed diffuse alveoli bleeding stemming from alveolar capillary damage. It is a medical emergency with hemoptysis, cough, progressive dyspnea, which can cause acute respiratory failure. We present a case of diffuse alveolar hemorrhage due to the use of ibuprofen so as to review the literature in terms of clinical diagnosis and treatment.

Case Presentation: A 65-year-old male patient presented to our clinic with a sudden onset of breathlessness and hemoptysis. There was no trait in the patient's history. He stated to use ibuprofen intensively just for his knee pain for several weeks. There was no other special medication he used. He did not describe collagen tissue disease. Physical examination of the patient revealed tachycardia (120/min) and tachypnea (30/min) . Bilateral common rales were observed to be present in the respiratory system examination. Arterial blood had pH 7.31, PO₂ 60 mmHg, PCO₂ 47

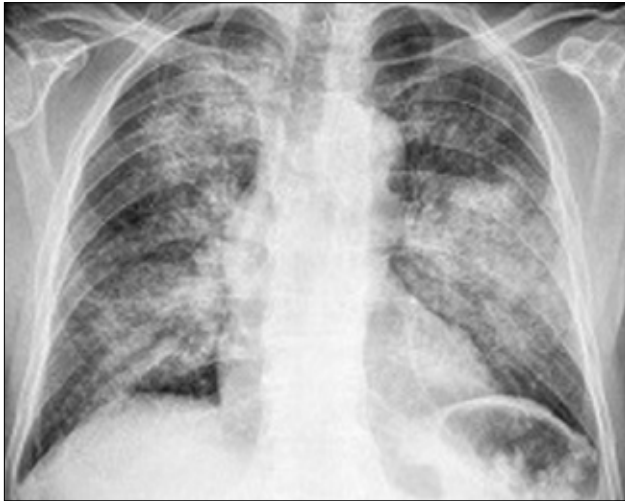


Figure 1. Chest X-Ray shows bilateral diffuse heterogeneous infiltrates

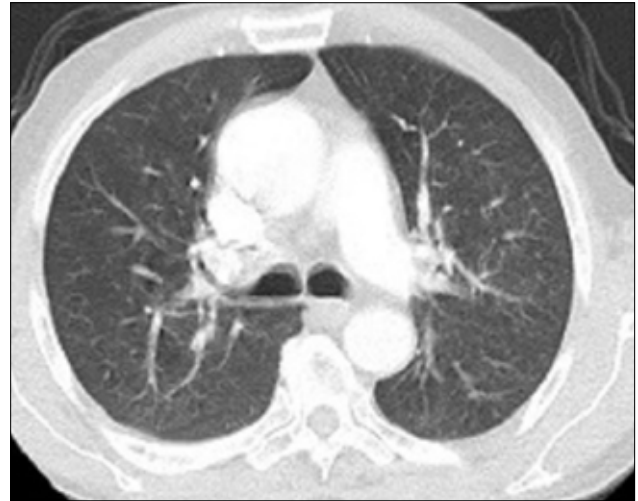

Figure 3. Control CT shows disappeared ground glass opacity in both lung

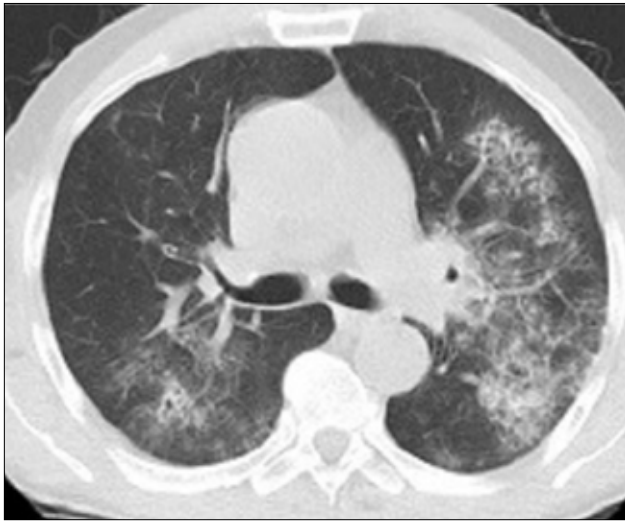


Figure 2. Toraks CT shows widespread ground-glass alveolar opacity in both lungs

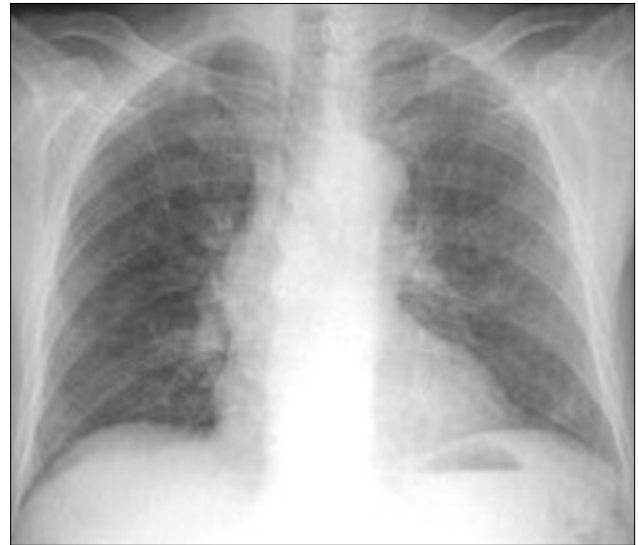

Figure 4. Control Chest-X Ray

mmHg, HCO₃ 20 mmol/L and SaO₂ 85%. The patient had bilateral diffuse heterogeneous infiltrates on his chest x-ray (Figure 1). In his Thorax CT, there were widespread ground-glass alveolar opacity in both lungs (Figure 2). The hemoglobin values of the patient were gradually decreased 10.2, 9.4, 8.6, 7.9 g/dL respectively. Active hemorrhage areas were seen in the fiberoptic bronchoscope. Bronchoalveolar lavage was performed. Bronchoalveolar lavage findings were reported to be consistent with alveolar haemorrhage. Ibuprofen pneumotox online site was investigated for drug toxicity. It was noticed that it can cause lung pathologies like eosinophilic pneumonia, pulmonary edema, ARDS, bronchospasm, asthma, pleural effusion, pulmonary arterial hypertension, DRESS and hypersensitivity reactions. No other etiologic agent was detected in the patient, and the diagnosis of diffuse alveolar hemorrhage due to ibuprofen was made clinically, radiologically and pathologically. The medication used by the patient was stopped and the patient underwent puls steroid therapy for respiratory distress. Clinical and radiological improvement was soon observed in the patient (Figure 3).

Conclusion: Drug induced lung injury is defined as diffuse parenchyma lung disease (DPAH). Diffuse Alveolar Hemorrhage (DAH) may develop due to many factors such as drugs, collagen diseases, infections, toxic agents, vasculitis and uremia. When considering drug induced pulmonary disease, detailed information is available at Pneumotox Online (<http://www.pneumotox.com>). Early diagnosis and treatment in cases of acute alveolar hemorrhage are life-saving, and may be important in determining the anamnesis etiological agent and in the diagnoses of alveolar hemorrhage resulting from drugs.

Keywords: Diffuse Alveolar Hemorrhage, dyspnea, ibuprofen

[Abstract:0328] PS-006 [Accepted:Poster Presentation] [Clinical Problems - Diffuse Parenchymal Lung Disease]

Alveolar Hemorrhage Syndrome Associated With Sodium Valproata: Due to a Case

Mihrican Yeşildağ, Emel Atayık

Department of Chest, SBU Konya Education and Research Hospital, Konya, Turkey

Objectives: Diffuse alveolar hemorrhage (DAH) is a syndrome through haemoptysis, coughing and progressive dyspnea and is characterized by the accumulation of red blood cells in the alveolar spaces. We aimed to present a case with alveolar hemorrhage syndrome due to the use of sodium valproate and to examine the diagnostic and therapeutic approaches in the light of literature.

Case Presentation: A 74-year-old male patient was admitted to our clinic with a sudden onset of breathlessness and hemoptysis. It was learned that he had epilepsy and used sodium valproate in the past. Bilateral common rales, tachycardia and tachypnea were present in his physical examination. The Hb values of the patient were decreased 11.8, 10.2, 9.6, 8.2 g/dL respectively. His arterial blood test included; ph 7.30, PO₂ 50 mmHg, PCO₂ 47 mmHg, HCO₃ 20 mmol/L and O₂ saturation 83%. There were diffuse heterogeneous bilateral infiltrations on his chest X-Ray (Figure 1) . In thorax CT, widespread ground-glass-alveolar opacity was observed in both lungs (Figure 2) . Active hemorrhage were observed in the fyberoptic bronchoscopy. A large number of erythrocytes were also been reported in Bronchoalveolar lavage (BAL) . The patient was investigated for other diseases and causes of DAH and all diseases were excluded. The patient was diagnosed alveolar haemorrhage through these findings. Thinking only sodium valproate to be the culprit, sodium valproate was investigated, and it was discovered that it may lead to many lung pathologies such as pneumonitis, ARDS, eosinophilic pneumonia, pleuropericardial effusion, DRESS and hypersensitivity. The patient's medication was stopped and another agent was started for puls steroid therapy and epilepsy. Soon, the patient became clinically and radiologically normal (Figure 3) .

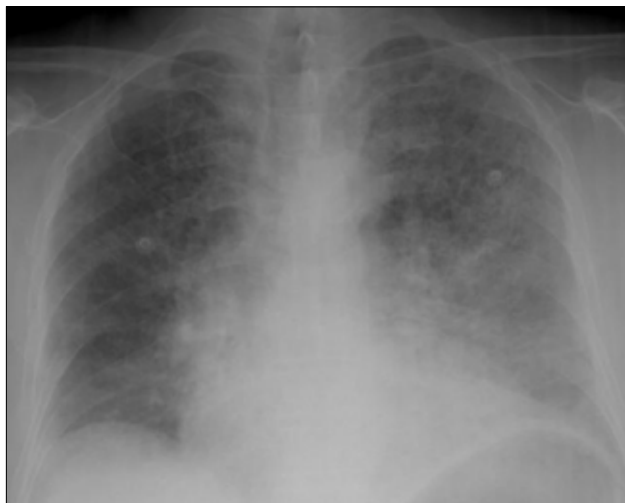

Figure 1. Chest X-Ray shows diffuse heterogeneous bilateral infiltrations

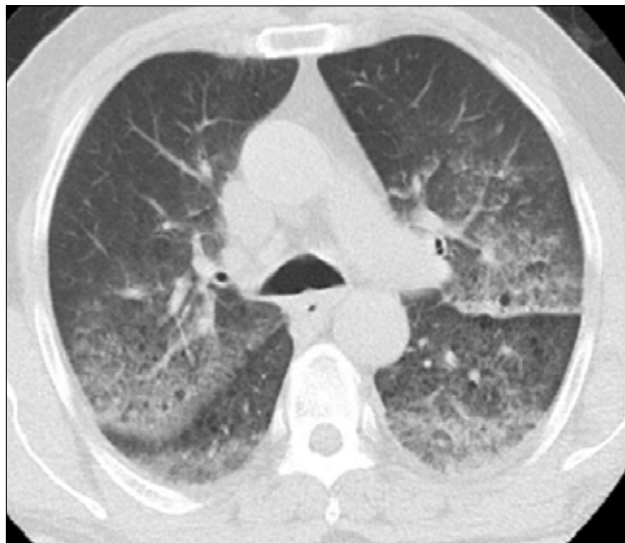

Figure 2. Thorax CT shows widespread ground-glass opacity in both lungs

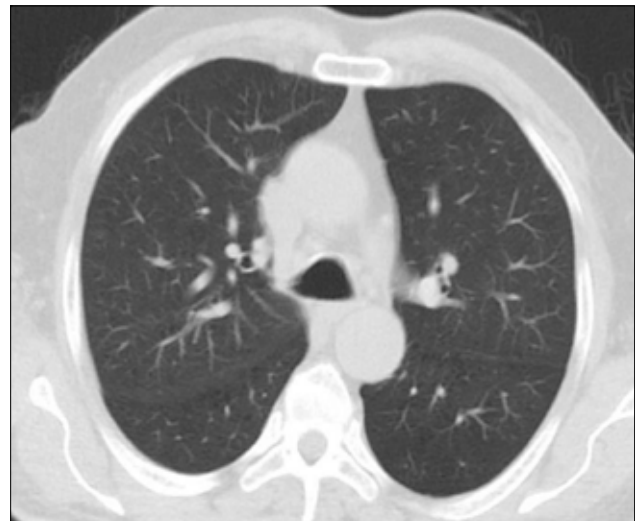

Figure 3. Control Thorax CT shows disappeared ground glass opacity in both lung

Conclusion: Diffuse and alveolar hemorrhage is a clinico-pathologic syndrome that develops due to a group of immunologically heterogeneous diseases, that has a spectrum ranging from alveolar damage to massive heamorrhage and

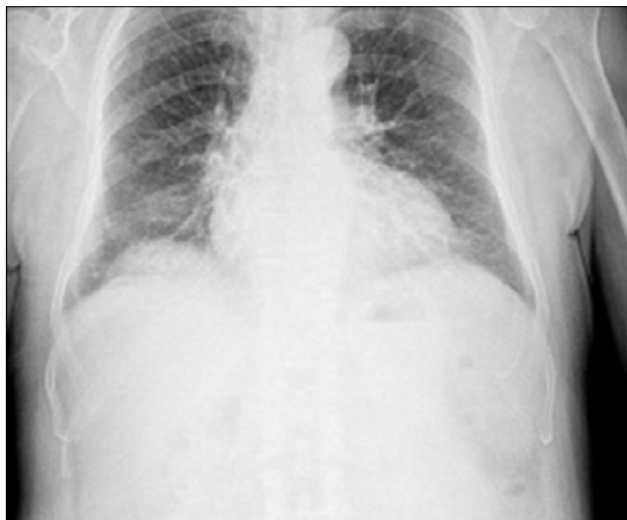

Figure 4. Control Chest X-Ray shows disappeared bilateral infiltrations

that can often lead to acute respiratory failure. Anemia, hemoptysis and bilateral alveolar infiltrates, which appear as a new entity in chest X-ray, constitute the classical diagnostic triad. BAL is usually necessary to confirm the diagnosis. We present, a case of alveolar hemorrhage stemming from sodium valproate, which was not previously reported among alveolar haemorrhage syndromes. In patients using sodium valproate, pulmonary toxicity should be considered in the presence of haemoptysis, fever, pulmonary infiltrates, cough and dyspnea. DAH should be considered in the differential diagnosis of patients with respiratory distress, especially hemoptysis.

Keywords: Alveolar hemorrhage, hemoptysis, sodium valproate

[Abstract:0329] EPS-048 [Accepted: E-Poster] [COPD]

Education Is Essential: Risk Factors for Frequent Hospitalization in Patients with COPD

Hakan Arık, Sinem Ermin, Özgür Batum, Ufuk Yılmaz

Department of Chest Diseases, Health Sciences University, Dr. Suat Seren Chest Diseases and Surgery Training and Research Hospital, İzmir, Turkey

Objectives: Chronic Obstructive Pulmonary Disease (COPD) is a common disease characterized by acute exacerbations requiring hospitalization. Some patients receive inpatient treatment more frequently than others. This increases both the morbidity and mortality and the health costs in patients. The aim of this study was to determine the characteristics of patients hospitalized with acute exacerbation of COPD and the risk factors associated with frequent hospitalization.

Methods: This study was conducted with 113 patients hospitalized with acute exacerbation of COPD between March 2015-2017. While patients with COPD with two or more exacerbations in the past year constituted the frequent hospitalization group, patients hospitalized for the first time constituted the non-frequent hospitalization group. The GOLD Strategy (2015) groups appropriate for the stabilization period were identified.

Results: There were 59 (52.2%) patients in the frequent hospitalization group and 54 (47.8%) patients in the non-frequent hospitalization group. There were 34 (64%) patients under 65 years of age, and 25 (42%) patients over 65 years of age in the frequent hospitalization group. There were 19 (36%) patients under 65 years of age and 35 (58%) patients over 65 years of age in the non-frequent hospitalization group ($p=0.017$). In the present study, 102 (90.3%) of the patients were male, and 11 (9.7%) were female. There were 46 (46.9%) literate patients, and 13 (86.7%) illiterate patients in the frequent hospitalization group. There were 52 (53.1%) literate patients, and 2 (13.3%) illiterate patients in the non-frequent hospitalization group ($p=0.010$). There were 6 (32%) patients with the GOLD Group C in the frequent hospitalization group, and 13 (68%) patients with the GOLD Group C in the non-frequent hospitalization group. There were 53 (57%) patients with the GOLD Group D in the frequent hospitalization group, and 40 (43%) patients with the GOLD Group D in the non-frequent hospitalization group ($p=0.043$). However, there was a significant difference between the two groups in terms of Long-Term Oxygen Therapy (LTOT), BIPAP therapy and nebulizer treatment before hospitalization ($p=0.001$, $p=0.001$, $p=0.000$, respectively). There was a significant difference in the duration of COPD between the two groups ($p=0.014$). Moreover, there was a significant difference between the two groups in terms of mMRC score, forced expiratory volume in one second (FEV_1) (Lt) and forced expiratory flow between 25% and 75% of vital capacity (FEF_{25-75}) (Lt) ($p=0.000$, $p=0.041$, $p=0.034$, respectively). Multivariate analysis indicated that the risk of frequent hospitalization increased in illiterate patients (OR=8.227; 95% CL: 1.595-42.438) and in patients receiving nebulizer treatment (OR=5.131; 95% CL: 2.183-12.064).

Conclusion: Patients with COPD who are illiterate or receive nebulizer treatment are at serious risk of hospitalization. This group of patients should be followed with special care to reduce hospitalizations.

Keywords: COPD, frequent hospitalization, risk

[Abstract:0330] SS-033 [Accepted:Oral Presentation] [Respiratory Failure and Intensive Care]**Approach of the Turkish Thoracic Society Member's to the End of Life**Ezgi Özyılmaz¹, Cüneyt Saltürk², Zühal Karakurt², Özlem Ediboğlu³, Özlem Yazıcıoğlu Moçin², Hüseyin Arıkan⁴, Begüm Ergan⁵, Turgay Çelikel⁴¹Department of Chest Disease, Çukurova University School of Medicine, Adana, Turkey²Sureyyapasa Chest Diseases and Chest Surgery Training and Research Hospital, İstanbul, Turkey³Dr. Suat Seren Chest Diseases and Chest Surgery Training and Research Hospital, İzmir, Turkey⁴Department of Critical Care, Marmara University School of Medicine, İstanbul, Turkey⁵Department of Chest Disease, Dokuz Eylül University School of Medicine, İzmir, Turkey

Objectives: Dying is a normal part of end of life (EOL) like birth, however it is often treated as an illness. As a consequence, many people die in intensive care units (ICUs), alone and in pain. Many modern health care agencies have developed specific policies related to EOL-care however current approaches have great variability due to medical-legal-ethical-cultural-religious and financial factors. In many developed countries, the management of these EOL-patients was split off the acute care and mainly remained on the palliative and home care systems. Unfortunately, in many developing countries like Turkey, EOL decisions are not available; so these patients are frequently hospitalized in ICUs and receiving futile treatments. The aim of this study is to investigate the approach of Turkish Thoracic Society (TTS) Member's to the EOL-care in Turkey.

Table 1: Demographical characteristics of the study group

Age (yrs)	
*20- 30	12.8 %
* 30- 40	34.1 %
*40-50	33.5 %
*50-60	15.9 %
*60 and more	3.7 %
Medical degree graduation year	
*< 1985	9.1 %
*1985- 1995	21.3 %
*1995- 2005	33.5 %
*2005- 2015	31.1 %
*2015-	5 %
Main speciality	
*Pulmonology	76.8 %
*Internal Medicine	11 %
*Other (Infectious Disease, Anesthesiology, Chest Surgery, General surgery)	12.2 %
ICU subspeciality	
*Yes	17.1%
*No	82.9 %
Currently working in an ICU	
*Yes	47.9 %
*No	52.1 %
Duration of ICU working (years)	
* < 3	25.4 %
*3- 10	43 %
* >10	31.6 %

Table 2: Approach of the Turkish Thoracic Society members to the end of life

Do you routinely follow up terminally ill patients? • Yes • No	89 % 11 %
The percent of terminal patients who have followed up during the last year • < 10 % • 10- 25 % • 25- 50 % • 50 % and more	12.7 % 32.9 % 36.7 % 17.7 %
Do you have to use futile care to the terminally ill? • Yes • No	90.9% 9.1 %
Did you had a training about EOL care during your medical school education? • Yes • No	14.6 % 85.4 %
Do you think that all terminally ill patients should die in ICUs? • Yes • No	2.5 % 97.5 %
Do you think that the current legal conditions about EOL sufficient in Turkey? • Yes • No	3.7 % 96.3 %
Which groups should be covered with this legal arrangements? • All terminally ill patients except the ones worsened due to reversible conditions • All hospitalized patients may have a right to refuse treatment (independent from the terminal status) • All patients should be hospitalized in ICUs and full support should be given including intubation and resuscitation • Noncommittal	74.8 % 20.2 % 1.8 % 3.2 %
Do you think legal arrangements will improve the quality of standards in ICUs? • Yes • No • Noncommittal	87.8 % 4.3 % 7.9 %
Why do you think like that? (Related with the previous question, more than one answer is acceptable) • Because futile care only results in a long, lonely and painful death • Because this may lead to increase the chance to find beds in ICUs for the potentially reversible patients • Because this may decrease the healthcare costs • Because this may keep the ICU team motivated with less burnout	89.5% 87.5% 68.5 % 69.4%

Methods: The study was cross-sectional and data were obtained by a survey shared with several communication channels (e-mail/social interaction platforms) with the members of the TTS. The survey included 26-questions and results were obtained between January 8-15th,2018. The descriptive analysis was used for evaluations of answers.

Results: The survey was shared with 3454-members and the response rate was 4.74%. The population demographics are summarized in Table 1. Majority questionnaires' main speciality was Pulmonology (76.8%) . Utmost of the participants don't have an ICU sub-speciality (82.9%) but approximately half were currently working in ICU (47.9%) , mostly in more than 3yrs (74.6%) . A great majority reported that they routinely follow terminally ill patients (89%) , have to use futile care (90.9%); and 87.3% of them indicated that the ratio of the terminal patients were >10% of the all patients which they have followed at the previous year. 89.9% reported that they had to refuse potentially reversible patients due to fullness of ICU beds. 97.5%

Table 3: Approach of the TTS members to the EOL- Decision process

Would you decide to not to intubate the terminally ill when legal arrangements allow? <ul style="list-style-type: none"> • Yes • No 	95 % 5%
After legal arrangements allow to do, who should involve the decision process of the EOL? <ul style="list-style-type: none"> • The patient he/herself or the legal guardian for the unconscious patient • Primary doctor who follows up the incurable disease (pulmonology, oncology, neurology specialist, etc) • The doctor who follows the patient in ICU • Hospital ethical committee member, specialist • Other 	78.5 % 79.1 % 82.8 % 42.9 % 1.2%
After legal arrangements allow to not to intubate/not to resuscitate the patient, when the opinion of the patients should be asked? <ul style="list-style-type: none"> • Personal opinion should be asked to all hospitalized patients independent of the prognosis • Potentially terminal patient (before the terminal period) • Only the terminally ill patient • Not only to ill people, it should be asked to healthy people too • It should never be asked 	32.3 % 25 % 18.9 % 13.4 % 10.4 %
Do you think that ICU sources are effectively used in our country? <ul style="list-style-type: none"> • Yes • No 	1.9 % 98.1%
What's your personal comments to improve both the use of ICU sources and the care of terminally ill? <ul style="list-style-type: none"> • Home care services should be improved • Palliative care units should be evolved • Sermons and education should be given according to religions • A legal guardian should be appointed to all hospitalized patients • All patients should receive religious support • Legal arrangements should be done 	94.5 % 98.1 % 59.7 % 37.1 % 29.2 % 93.9 %
If the terminally ill patient was you or your first degree relative (hope this would never be true), would you like to take ICU care at the terminal period? <ul style="list-style-type: none"> • Yes • No 	9.3 % 90.7 %

of the participants thought that all terminally ill patients should not die in ICU. A great majority reported that the legal arrangements of EOL are insufficient (96.3%) and should be revised (95.7%) . These legal arrangements may improve the quality of ICU standards in Turkey (87.8%) and they may decide to not to intubate the terminally ill after these arrangements (95%) . 90.7% reported that they may refuse ICU care for themselves or primary degree relatives when needed (Table 2) .

Conclusions: In real life practice terminally ill patients are frequently hospitalized in ICUs and given futile care during EOL. Meanwhile, ICU sources are both limited and expensive in Turkey like all over the world, medicolegal policies with multi-disciplinary approach are urgently required for our country.

Keywords: ICU, end of life, futile care, terminally ill

[Abstract:0331] SS-098 [Accepted:Oral Presentation] [Thoracic Surgery]

Is Right Sleeve Lower Lobectomy Necessary? Is It Safe

Celalettin İbrahim Kocatürk, Özkan Saydam, Celal Buğra Sezen, Cem Emrah Kalafat, Ali Cevat Kutluk, Levent Cansever, Hasan Akın, Muzaffer Metin

Department of Thoracic Surgery, Yedikule Chest Diseases and Thoracic Surgery Training and Research Hospital, İstanbul, Turkey

Objectives: The right sleeve lower lobectomy is the least used of the bronchial sleeve operations. There are only case-based studies in the literature. In this study, we compared this technique to those used in patients who underwent a right lower bilobectomy.

Methods: We retrospectively reviewed the data of patients who had been operated on due to non-small cell lung cancer (NSCLC) from January 2005 to December 2015 from a dataset that was formed prospectively. Of the 4.166 patients who underwent resections due to NSCLC, the files of those who had a right sleeve lower lobectomy (Group S) and those who had a right lower bilobectomy Group B) were evaluated. The remaining 25 patients in group B and the 18 patients in group S were compared in terms of demographic data, morbidity, hospitalization time, mortality, histopathology, recurrence, and total survival.

Table 1. Demographic characteristics of patients

Variables	Grup B n (%)	Grup S n (%)	p value
Gender			
Male	25 (100)	16 (88.9)	0.169
Female	0	2 (11.1)	
Comorbidity	18 (72)	12 (66.7)	0.707
Cardiac Problems (Arrhythmia/CF)	8 (32)	5 (27.8)	0.766
COPD	9 (36)	8 (44.4)	0.576
CRF	2 (8)	1(5.6)	1
Diabetes Mellitus	3 (12)	5 (27.8)	0.247
Hypertension	6 (24)	4 (22.2)	1
Previous Surgery	2 (8)	5 (27.8)	0.112
Smoking Habits			
Smoker	19 (76)	14 (77.8)	1
Non-Smoker	6 (24)	4 (22.2)	

CRF: Chronic Renal Failure; CF: Cardiac Failure; COPD: Chronic Obstructive Pulmonary Disease

Table 2. Histopathological Comparisons

Variables	Group B n (%)	Group S n (%)	p value
Tumor Histology			
Squamous cell Carcinoma	20 (80%)	15 (83.3%)	1
Adenocarcinoma	5 (20%)	3 (16.7%)	
Pathological Stage			
1A	1 (4%)	1 (5.6%)	0.443
1B	10 (40%)	9 (50%)	
2A	4 (16%)	2 (8.7%)	
2B	9 (36.0%)	4 (22.2%)	
3A	1 (4%)	3 (16%)	

Table 3. Histopathological Comparisons

Variables	Group B n (%)	Group S n (%)	p value
Tumor Histology			
Squamous cell Carcinoma	20 (80%)	15 (83.3%)	1
Adenocarcinoma	5 (20%)	3 (16.7%)	

Results: No significant differences in the demographic or clinical characteristics were observed between the two groups, except that Group S had more female patients. Postoperative complications developed in 52% of the patients in Group B and 11.1% of the patients in Group S ($p=0.006$). Mean hospitalization time was 9.6 ± 3.6 (range, 6-19) days in Group B and 6.72 ± 1.5 (range, 4-9) days in Group S ($p=0.001$). All patients received complete resections. The mean patient follow-up time was 42.9 months. No significant difference was found between local and distant recurrences ($p=1$, $p=0.432$). Mean survival time was 89.6 months (5-year rate=73%), which was 90.6 months (5-year rate=75.3%) in Group B and 63.1 months (5-year rate=69.3%) in Group S ($p=0.82$).

Conclusion: This technique allows for reduced filling of the thoracic cavity by a prolonged air leak and a reduced prevalence of complications. Additionally, the hospitalization time is shortened. It does not produce an additional mortality burden, and total survival and oncological outcomes are reliable. This technique can be used in selected patients at experienced centers.

Keywords: Lung cancer, right sleeve lower lobectomy, bilobectomy, thoracotomy

[Abstract:0333] PS-004 [Accepted:Poster Presentation] [Clinical Problems - Diffuse Parenchymal Lung Disease]

Drug-Induced Hypersensitivity Pneumonia: Due to a Case

Mihrican Yeşildağ, Emel Atayik

Department of Chest Diseases, SBU Konya Education and Research Hospital, Konya, Turkey

Objectives: Drug-induced lung diseases are common iatrogenic diseases. While clinical presentations may be either a little severe or fatal, they may manifest in various patterns such as chronic interstitial lung disease, hypersensitivity pneumonia, cryptogenic organizing pneumonia and diffuse alveolar hemorrhage. We aimed to present a case of hypersensitivity pneumonia due to trastuzumab in a patient who is receiving chemotherapy for breast cancer.

Case Presentation: A 56-year-old female patient was consulted from the oncology clinic for nearly three months of a growing number of shortness of breath and coughing complaints. We were informed that she had received chemotherapy with breast cancer invasive ductal carcinoma and that chemotherapeutic medication with causative agent of trastuzumab was started about 3-4 months ago. Hemogram, biochemistry, collagenous markers were within normal limits. In his pulmonary function test, it was observed that FVC was 59%, FEV1 was 60% and FEV1/FVC was 86%. In his chest X-ray, interstitial infiltrations and linear atelectasis areas were present in the bilateral lower zones (Figure 1). His thorax CT showed infiltration areas containing air bronchograms in both lung parenchymal areas with increased densities in the form of ground-glass opacity, evident in the right middle lobe laterally (Figure 2). Fiberoptic bronchoscopy and biopsy were not performed since the patient did not admit them.

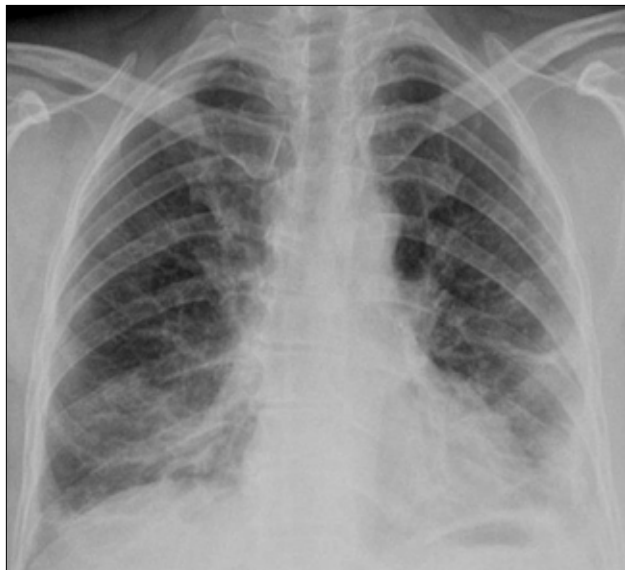


Figure 1. Chest X-Ray shows interstitial infiltrations and linear atelectasis in the bilateral lower zones

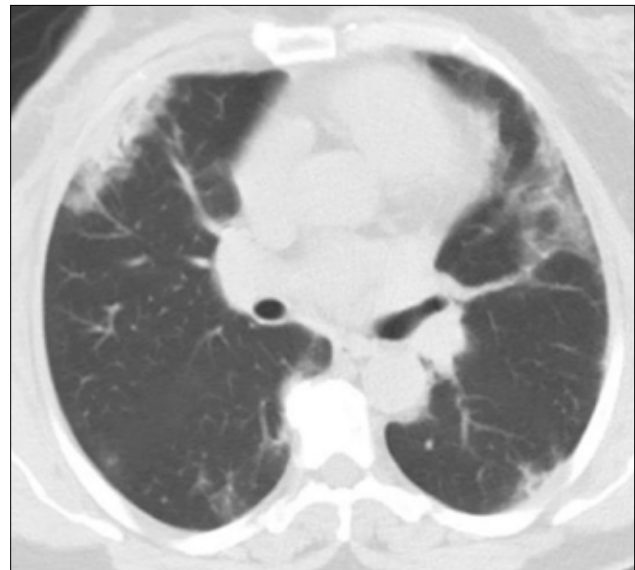

Figure 2. Thorax CT shows infiltration areas containing air bronchograms and patchy ground-glass opacity in both lung

The patient was diagnosed hypersensitivity pneumonia through the clinical, anamnesis and imaging findings. When investigated in the chemotherapeutic drug Pnomotox, It was learned that the chemotherapeutic medication named trastuzumab, used for metastatic breast cancer, might lead to hypersensitivity reactions. Our patient also developed a hypersensitivity pneumonitis due to trastuzumab (Herceptin) . Therefore, the patient's medication was stopped and corticosteroid therapy was started. Significant improvement was observed in the lung lesions and his complaints (Figure 3) .

Conclusion: Drug-induced lung diseases (DILD) are the damages and side effects of the substances used for therapeutic purposes on the respiratory system. The resulting clinic may be mild, moderate or severe, and sometimes fatal. It is reported that around 700 medicines cause this, but chemotherapeutic drugs play the biggest role. A list of these drugs is available at www.pneumotox.com. In the hypersensitivity pneumonia induced by drugs, the first symptom may be seen days or years after its use. When symptoms such as shortness of breath or cough develop in patients using chemotherapeutic drugs, hypersensitivity pneumonia should be suspected and the drug use histories of the patients should be questioned in detail.

Keywords: Drug, Dyspnea, Hypersensitivity pneumonia

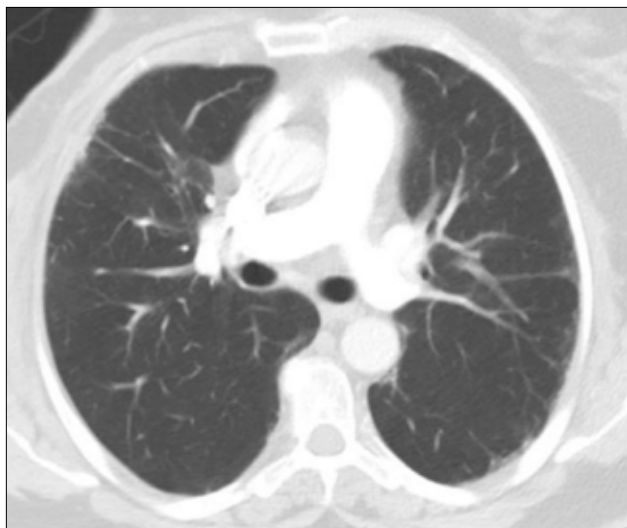

Figure 3. Control Thorax CT shows significant improvement in the lung lesions

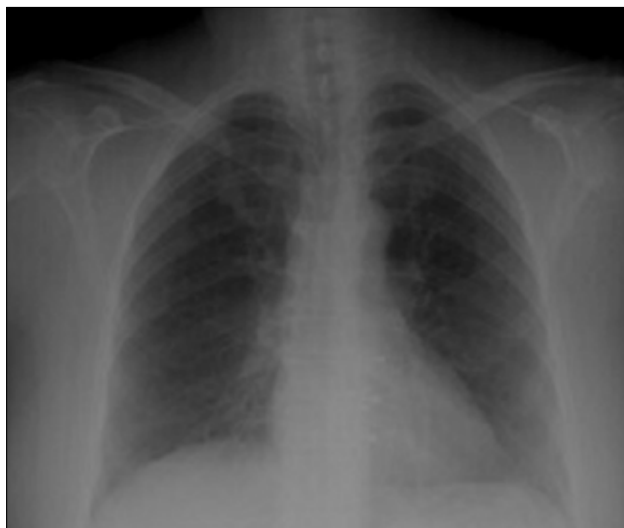

Figure 4. Control Chest Xray shows significant improvement in the lung lesions

[Abstract:0334] SS-107 [Accepted:Oral Presentation] [Clinical Problems - Diffuse Parenchymal Lung Disease]

Can we Predict Bleomycin Toxicity with PET-CT

Seda Beyhan Sağmen¹, Sevda Cömert¹, Esra Turan Erkek², Aysun Küçüköz Uzun³, Coşkun Doğan¹, Güven Yılmaz², Nesrin Kiral¹, Ali Fidan¹, Çağla Yılmaz Haksal³, Elif Torun Parmaksız¹

¹Department of Pulmonary Medicine, SBU Kartal Dr.Lutfi Kırdar Training and Research Hospital, İstanbul, Turkey

²Department of Hematology, SBU Kartal Dr Lütüf Kırdar Training and Research Hospital, İstanbul, Turkey

³Department of Nuclear Medicine, SBU Kartal Dr Lütüf Kırdar Training and Research Hospital, İstanbul, Turkey

Objectives: Bleomycin is an antitumor antibiotic used successfully to treat a variety of malignancies, predominantly germ cell tumors and Hodgkin's lymphoma (HL) . The major limitation of bleomycin therapy is the potential for life-threatening interstitial pulmonary fibrosis. It is important to recognize the patients who can develop toxicity early in the asymptomatic period. We aimed to evaluate PET findings to predict bleomycin toxicity (BT) early after doxorubicin, bleomycin, vinblastine, dacarbazine (ABVD) chemotherapy before clinical symptoms and radiological changes occur.

Methods: Hodgkin's lymphoma patients who were treated with ABVD were evaluated. SUVmax of lung parenchyma were analyzed in PET-CT at diagnosis and after 4 cycleof chemotherapy in all patients. At the end of the chemoteraphy cycles lung parenchymal SUVmax values of patients with BT and without BT were compared statsitically.

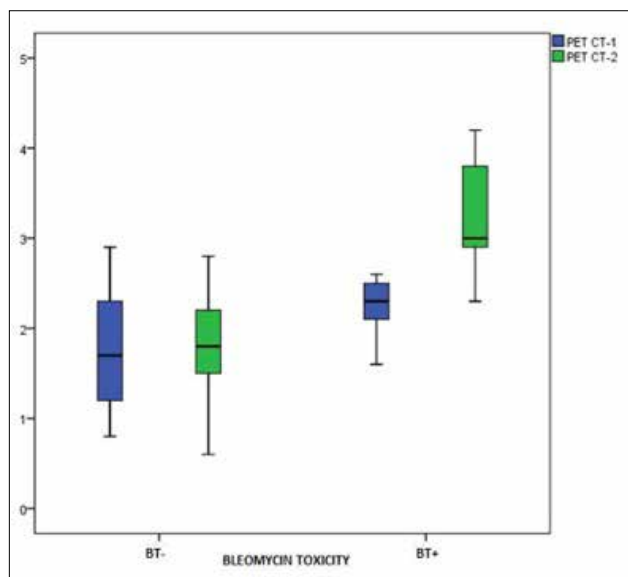


Figure 1. PET-CT findings in patients developing and not developing bleomycin-induced toxicity

Results: 20 (66.7%) male, 10 (33.3%) female patients with HL were included. 5 (16.7%) HL patients developed BT. In 3 of HL patients BT was determined after 5 cycles and in 2 of patients BT was seen after 6 cycles. In all 5 of these patients with BT, FDG uptake in PET-CT was increased after 4 cycle chemotherapy and BT was predicted before clinical and radiological findings by PET-CT. After 4 cycle chemotherapy, lung parenchymal SUVmax of patients with BT (3.24 ± 0.76) was significantly higher than patients without toxicity (1.84 ± 0.52) ($p < 0.001$). In patients with BT, a significant increase was established in lung parenchymal SUV max after 4 cycle chemotherapy when compared to at the time of diagnosis ($p = 0.043$).

Conclusion: Bleomycin toxicity can be fatal. Early detection of bleomycin toxicity is essential in clinical practice. PET CT can predict bleomycin toxicity before clinical and radiological findings occur.

Keywords: Bleomycin toxicity, SUVmax, early diagnosis

[Abstract:0337] SS-112 [Accepted: Oral Presentation] [COPD]

The Relationship Between Serum Levels of Surfactant Protein D in COPD Exacerbation Severity and Mortality

Fatma Esra Günaydın, Nurdan Kalkan, Gülşah Günlüoğlu, Esmâ Nur Aktepe, Barış Demirkol, Sedat Altın

Yedikule Hospital for Chest Disease and Thoracic Surgery Training and Research Hospital, İstanbul, Turkey

Objectives: Chronic Obstructive Pulmonary Disease (COPD) is a major cause of morbidity and mortality in all countries of the world. In COPD patients, various inflammatory markers such as cytokines, chemokines, and acute phase proteins, which show systemic inflammation in the circulation increase during exacerbations. Surfactant protein D (SP-D) increase as secondary to systemic inflammation in lung pathologies. Following SP-D is thought to be a pulmonary-specific biomarker in the regulation of the treatment schedule, in determining the frequency of exacerbations. In our study, we aimed to determine the relationship between serum SP-D levels and exacerbation severity, clinical course of disease, early mortality after discharge.

Methods: In our study, control group consisting of nonsmoker healthy 40 subjects older than 40 year and 42 subjects than 40 year having at least 10 pack-year smoking history, patient group consisting of 50 subjects that hospitalized with COPD exacerbation. Venous blood samples were taken from all patients for complete blood count, C-reactive protein (CRP) and blood SP-D levels. Patients with COPD were followed up for exacerbation frequency, hospital admission and mortality for 3 months.

Results: When the three groups of subjects compared serum SP-D levels were significantly higher in the control group of healthy smokers and there were no significant difference between healthy individuals and COPD exacerbations serum SP-D levels ($p > 0.05$). Serum SP-D levels in the stable period of the patients were lower than exacerbation ($p < 0.001$). There was a statistically significant correlation between the serum levels of SP-D and mMRC and CAT ($p < 0.05$). In our study, there was no significant relationship between blood SP-D levels and FEV1 (L,%) values ($p = 0.69$); There was a significant correlation between the increase in blood SP-D levels in the first month after discharge and the hospital admission in the first month ($p < 0.05$). There was no statistically significant relationship between serum SP-D and 3-month emergency admission and hospitalization ($p = 0.18$). There was no statistically significant correlation between serum SP-D and 3-month mortality ($p > 0.05$).

Conclusion: Our study showed that serum SP-D level was higher than that of stable phase in COPD exacerbations, but did not correlate with emergency admission, hospital admission and mortality in the 3 months post-exacerbation period but it was found to be a useful biomarker in predicting emergency admission and hospitalization at 1 month post-discharge. SP-D as a lung biomarker can be used to monitor COPD and progression.

Keywords: Surfactant protein D, COPD, inflammation

[Abstract:0340] PS-244 [Accepted: Poster Presentation] [Environmental and Occupational Lung Diseases]

Latex as a Well-Defined Cause of Occupational Asthma: An Unknown Branch of Business

Pınar Yıldız Gülhan, Ege Güleç Balbay, Fuat Aytekin

Department of Chest Diseases, Düzce University School of Medicine, Düzce, Turkey

Introduction: Occupational asthma (OA) is a disease characterized by the presence of variable airflow limitation and/or bronchial hyperactivity developing in association with some substances in working environment but not with factors found outside the workplace.

Case Presentation: A 40-year-old female patient was admitted to the hospital due to the complaint of dry cough lasting for 4 months. In an external center where she visited for cough 2 months ago, she was begun salmeterol/fluticasone and desloratadine/montelukast for the diagnosis of asthma. She had no known disease except migraine and hypertension. Although she received her drugs regularly, her complaints did not regress, and she consulted to our department. She had the complaint of dry cough for 4 months. The results of her respiratory function test were normal. It was learned that she was working as a mechanic in the manufacture of closet sets for a private business for 4 years. Here, they used latex for preventing the closet carpet backing to be slippery. The patient was performed bronchial provocation test and the result was negative. Latex-specific IgE was found to be positive. In one-month PEF follow-up, a decrease of 20% was detected in 7 working days (Figure 1). Based on these findings, the patient was diagnosed with latex-induced occupational asthma and she was recommended to change her job.

Conclusion: Latex is used in the manufacture of non-slip carpets and this can cause occupational asthma. These cases are diagnosed less than its existing rate. This is mostly because of that occupations are not well investigated and agents that are exposed due to occupations are not well known.

Keywords: Latex, occupational asthma, PEF

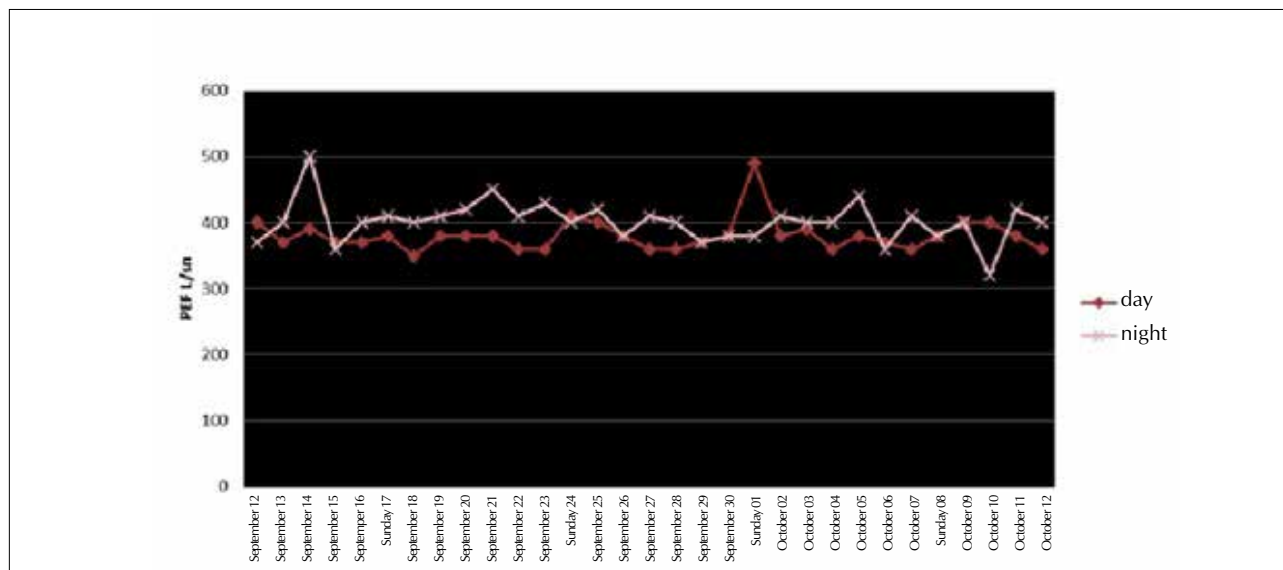


Figure 1. Monthly PEF follow-up of the patient

[Abstract:0341] PS-098 [Accepted: Poster Presentation] [Pulmonary Rehabilitation and Chronic Care]

Inspiratory Muscle Training and Aerobic Exercise in An Osas Patient with Diaphragm Dysfunction

Haluk Tekerlek¹, Ebru Calik Kutukcu¹, Deniz Inal Ince¹, Cemile Bozdemir Ozel¹, Aslihan Cakmak¹, Hazal Sonbahar Ulu¹, Melda Saglam¹, Naciye Vardar Yagli¹, Hulya Arikan¹, Lutfi Coplu²

¹Department of Physiotherapy and Rehabilitation, Faculty of Health Sciences, Hacettepe University, Ankara, Turkey

²Department of Chest Diseases, Hacettepe University School of Medicine, Ankara, Turkey

Objectives: Pulmonary rehabilitation (PR) combined with primary treatment for obstructive sleep apnea syndrome (OSAS), improves the efficacy of treatment and provides long-term benefit to the patients. In addition, diaphragm dysfunction causes symptoms to increase in patients with OSAS. We aimed to investigate the effects of inspiratory muscle training (IMT) and aerobic exercise (AE) on exercise capacity and sleep-related parameters in an OSAS patient with diaphragm dysfunction.

Methods: A 69-years-old male patient who was referred to the Cardiopulmonary Rehabilitation Unit of the Physiotherapy and Rehabilitation Department of Hacettepe University from Hacettepe University Department of Chest Diseases. Patient's demographic and clinical data were recorded. The patient undergoing BiPAP was submitted IMT at 40-60% maximum inspiratory pressure (MIP), 30 breathe in 3 cycles, three times per day, seven days/week and AE at 60-90% maximum heart rate (HRmax) 45 min/day, three days a week for eight weeks. Before and after treatment, the pulmonary function using a spirometer, respiratory muscle strength (RMS) using a mouth pressure device, and respiratory muscle endurance (RME) using constant threshold load (MIP 60%) were measured. Functional exercise capacity was determined using six-minute walk test (6MWT), sleep quality and daytime sleepiness were measured with Pittsburgh Sleep Quality Index (PSQI) and Epworth Sleepiness Scale (ESS) respectively.

Results: Demographic and clinical data are presented in Table 1. After PR, patient's pulmonary function, RMS, RME and 6MWT distance were higher than before. There was also an increase in sleep quality, a decrease in daytime sleepiness and body weight by 4 kg (Table 2).

Conclusion: Although PAP (positive airway pressure) is the primary treatment for OSAS; compliance, adherence and financial problems related to the PAP may reduce the effectiveness of treatment. Therefore, different procedures that can be applied with PAP have gained importance in recent

Table 1. Patient's demographic and clinical data

Age (years)	69
Height (cm)	180
Weight (kg)	122
Body mass index (kg/m ²)	37.65
Apnea-hypopnea index (times/h)	54
Comorbidities	Hypertension, type2 DM, heart failure
Dyspnea (MMRC)	2
Heart failure functional classification (NYHA)	Class II

Table 2. The effects of IMT and AE on factors related to exercise and sleep

Variable	Before PR	After PR
Anthropometric measurement		
Weight (kg)	122	118
Body mass index (kg/m ²)	37.65	36.41
Pulmonary function		
FEV1 (L)	1.59	1.81
FEV1 (%)	49	52
FVC (L)	1.71	1.83
FVC (%)	41	43
FEV1/FVC	86.9	84.8
PEF (L)	6.40	7.21
PEF (%)	78	85
FEF25-75% (L)	1.98	2.24
FEF25-75% (%)	59	69
Respiratory muscle strength		
MIP (cmH ₂ O)	47	60
%MIP	45.74	58.39
MEP (cmH ₂ O)	111	142
%MEP	57.74	73.86
Respiratory muscle endurance test		
Time (sn)	122	260
Functional exercise capacity		
6MWT distance (m)	480	524
%6MWT distance	97.16	104.8
minSPO ₂ during test (%)	75	82
Sleep quality		
PSQI score (0-21)	11	6
Daytime sleepiness		
ESS score (0-24)	7	5

years. In the literature, there was no study using IMT+AE in OSAS patients. It has been reported that in some studies using either IMT or AE only; there were no significant changes in pulmonary function, aerobic capacity, and sleep parameters. According to the results; IMT+AE improves exercise capacity, pulmonary function, RMS and RME in patients with OSAS. IMT+AE also decreases daytime sleepiness and body weight; while increasing sleep quality. A further large randomized controlled trial is needed.

Keywords: Aerobic exercise, Inspiratory muscle, obstructive sleep apnea

[Abstract:0342] SS-103 [Accepted: Oral Presentation] [Clinical Problems - Pulmonary Vascular Diseases]

Thrombolytic Treatment (Recombinant Tissue Plasminogen Activator) for Pulmonary Embolism also Improves Deep Venous Thrombosis in Same Patients

Mükremin Er

Department of Pulmonary Diseases, Atatürk Training and Research Hospital, Ankara, Turkey

Objectives: Anticoagulants have been suggested as the standard medical treatment for DVT to reduce further clots forming and prevent pulmonary embolism (PE). Thrombolytic treatment is another treatment option which can be done with streptokinase, urokinase and recombinant tissue plasminogen activator (r-tPA) to dissolve the thrombus in the deep veins. Thrombolytic treatments commonly have been performed locally via catheter to occluded vein. Catheter based thrombolytic treatment is difficult and costly procedure. We aimed in this study, to evaluate the effect of systemically administered r-tPA treatment to pulmonary embolism patients who have also deep venous thrombosis.

Table 1. Comparison of CUS results of the groups on the 6th month of the treatment

Residual Vein Obstruction	Group 1 n: 66	Group 2 n: 64	P
RVO (+)	54	41	0.029
RVO (-)	12	23	0.29

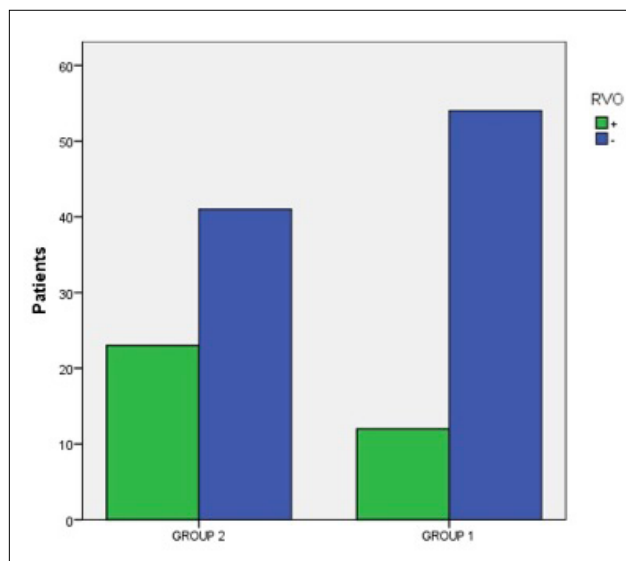


Figure 1. Residual vein obstruction rates between two groups

Methods: 130 patients who diagnosed PE and DVT at the same time were included in this study. Patients were diagnosed as PE by computed tomography (CT) pulmonary angiography. Lower extremity compression ultrasonography (CUS), and transthoracic echocardiography were applied for all patients. During a follow-up control on the 6th month of the treatment, CUS of lower extremities were repeated. Sixty six patients who were given thrombolytic therapy classified as Group 1. Sixty four patients, who weren't suitable for thrombolytic treatment because of contraindication, were given conventional anticoagulant treatment and classified as Group 2. 100 mg r-tPA was administered intravenously via peripheral veins in Group 1 patients during 2 hours. Subcutaneous enoxaparin administered for 5 days and oral warfarin was started consecutively. Group 2 patients weren't received thrombolytic treatment and they administered subcutaneous enoxaparin for 5 days since the beginning and oral warfarin was started consecutively. When INR values reached 2.0-3.0 range, enoxaparin was stopped in both groups. Warfarin treatment was continued keeping the range of INR between 2.0-3.0. up to 6 months.

Results: In sixth month control CUS of the Group 1 and Group 2 patients, 54 patients were completely resolved in the venous thrombus, and 12 of them had chronic thrombosis. Sixty-four patients who received standard conventional therapy were found to have complete resolution in 41 of them while 23 patients maintained thrombosis. This difference was statistically significant ($p=0.029$). Hazard ratio (HR) was calculated to be 2.52. In other words, the risk of residual venous occlusion (RVO) increased by 2.52 times without thrombolytic therapy.

Conclusion: Thrombolytic treatment is essential for avoid complications of DVT which originated from peripheral deep veins. Although, thrombolytic treatment via catheter have been common thrombolytic treatment procedure, systemic thrombolytic treatment should be more often considered as a reliable and cost effective treatment option. Also CUS control is strongly recommended after six months before stopping anticoagulants.

Keywords: Deep vein thrombosis, pulmonary embolism, thrombus resolution, thrombolytic treatment, warfarin treatment

[Abstract:0349] EPS-181 [Accepted: E-Poster] [Thoracic Surgery]

Bronchogenic Cyst Case Coexisting with Right-Sided Arcus Aorta

Gülşen Yılmaz¹, Pınar Bıçakcıoğlu¹, Seray Hazer¹, Erkmen Gülhan¹, Hakan Ertürk²

¹Department of Chest Surgery, Health Sciences University, Ankara Atatürk Chest Diseases and Chest Surgery Training and Research Hospital, Ankara, Turkey

²Department of Radiology, Health Sciences University, Ankara Atatürk Chest Diseases and Chest Surgery Training and Research Hospital, Ankara, Turkey

Bronchogenic cyst and arcus aorta anomalies occur due to abnormal development of one or more components of embryonic arch. The anomalies of the aortic arch and its main branches are very rare and its incidence varies between 1% and 3% in autopsy series. The right arcus aorta is a rarer anomaly and its feature is the presence of a single aortic arch that passes to the right side of the trachea by crossing the right main bronchus. The findings in symptomatic cases are generally the symptoms of vascular rings. Bronchogenic cysts localized in the mediastinum are rarely seen and they can be asymptomatic at the time of diagnosis. For the confirmation of diagnosis and prevention of present or possible complications, surgery is indicated for all bronchogenic cysts with or without clinical symptoms. In this study, we have presented a case of right-sided arcus aorta anomaly that rarely coexists with bronchogenic cyst causing chest pain. Because this rare coexistence can lead to confusions and complications during radiological examinations and surgical operations, they should be known by anatomists, radiologists, and surgeons.

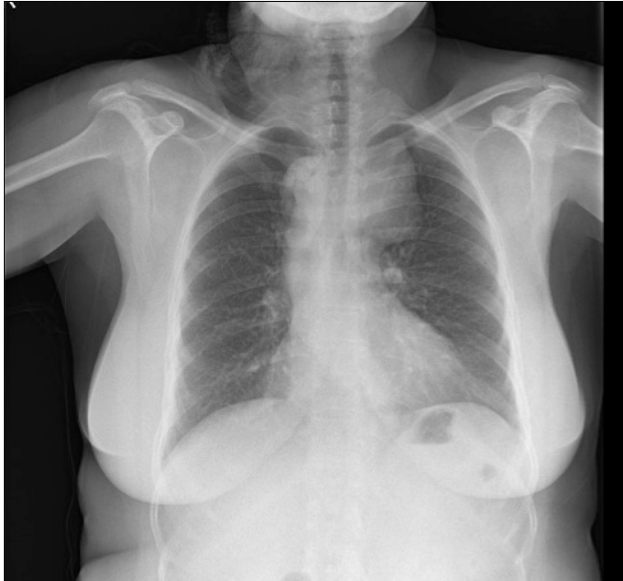

Figure 1. Posteroanterior chest radiography of the patient at the first admission

Keywords: Bronchogenic cyst, mediastinal cyst, right-sided arcus aorta

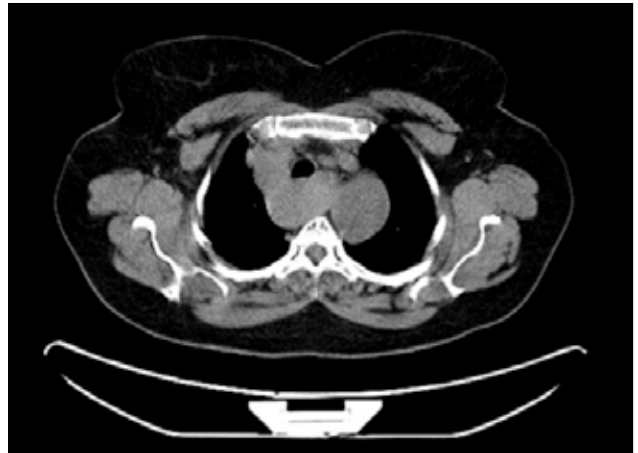


Figure 2. In Positron Emission Tomography-Computed Tomography (PET-CT), view of bronchogenic cyst with right-sided arcus aorta

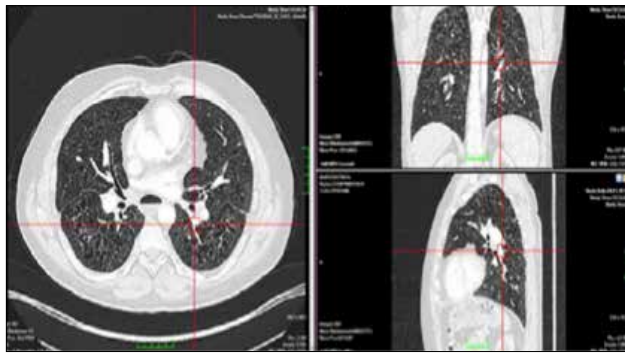
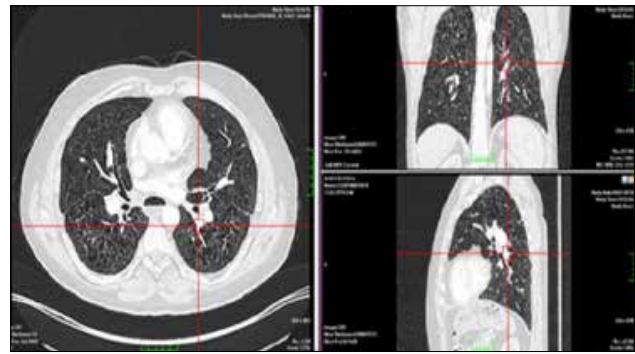[Abstract:0350] EPS-136 [Accepted: E-Poster] [Pulmonary Pathology]**Cladribine in Treatment of Langerhans Cell Histiocytosis- X:**

Zenfira Alasgarova, Nurdan Köktürk, Nilgün Yılmaz Demirci

Department of Chest Diseases, Gazi University School of Medicine Hospital, Ankara, Turkey

Adult pulmonary langerhans cell histiocytosis (PLHH) is a rare disease of unknown etiology seen in adults aged 20-40 years. Pulmonary involvement is characterized by focal langerhans cell granulomas, destroying distal bronchioles. The basic method of diagnosis is imaging. High resolution computed tomography (HRCT) typically shows a combination of koid nodules, thick and thin-walled cysts. Intracellular S100 protein and CD1a antigen staining, intracytoplasmic 'Birbeck granules' in electron microscopy is assisted in the diagnosis. The disease may also present with extrapulmonary findings. Until today, no effective treatment has been found. Although the disease is being tested with immunosuppressive agents. Transplantation can be considered in advanced cases. Cladribine (chlorodeoxyadenosine-2-CDA) is purine analog, antineoplastic agent, effects monocytes directly. It is generally used in the treatment of chronic lymphocytic leukemia and hairy cell leukemia. There are case reports of cladribine use of in LHH. This report describes a case of LHH treated with cladribine therapy.

A 46-year-old male patient who had been using cigarette 20 packs/year, quitted smoking 13 year ago, have applied to our center with a recent increase in dyspnea, dry cough, and chest pain complaints for 13 years. On physical examination, the general condition was middle, orthopneic, tachypneic, cyanotic, and there were crackels at subscapular area. Patient had hypertension and coronary artery disease. The patient required 10 L/min oxygen. The patient was diagnosed with diabetes insipidus associated with LHH and therefore he was using desmopressin. Ilioprost was started in the last 1 year due to Pulmonary Hypertension and he benefited symptomatically. 80 mg/day steroid therapy was started in the last 9 months. The

**Figure 1.** Thorax CT before Cladribine therapy-17.06.16**Figure 2.** Thorax CT after cladribine therapy-12.12.16**Table 1.** Changes in 6MWT

Date	Time	Distance	Saturation	Dispne score	Fatigue score	Symptom
09.07.15	-	240m	-	-	-	-
09.06.16	2min	30m	%95-%89 (14L)	3-8	5-8	CP, dyspnoea, leg pain
16.08.16	2min	60m	%96-%90 (7L)	3-6	3-7	CP, dyspnoea, fatigue
26.12.16	1min30sec	120m	%86-%72 (6L)	1-5	1-4	dyspnoea

Table 2. Changes in SFT

DATE	FVC-ml	FVC-%	FEV1-ml	FEV1-%	FEV1/FVC	DLCO
30.10.2013	4330	%106	3570	%88	%69	37
06.06.2016	4140	%95	2730	%77	%66	-
15.08.2016	4420	%126	2860	%95	%65	-
24.10.2016	4750	%104	3000	%81	%63	-
02612.16	4770	%105	2910	%79	%61	-

Changes in SFT

patient benefited from the treatment at the beginning, treatment terminated due to non-response to treatment. Patient was given a transplantation decision. In addition to supportive therapies, a total of 4cycles of cladribine treatment were started with 0.1mg/kg sc and 5days per month for bridging treatment. The patient was evaluated for side effects. He had no complication. When the treatment was completed, the patient was evaluated by functional and imaging methods. There were no changes in functional parameters and radiological examinations. Patient was symptomatically beneficial from Cladribine and regressed from dyspnea mMRC4 to 3, whose oxygen requirement decreased to 4-5lt/min. The patient was followed up with supportive care.

Eight months after admission to our clinic, the patient died because of cardiac arrest after myocardial infarction, following acute cholecystitis, perforation of the bile duct at a different center.

Keywords: Torax high resolution computer tomography, histiocytosis, langerhans cell, cladribine

[Abstract:0352] PS-115 [Accepted:Poster Presentation] [Pulmonary Rehabilitation and Chronic Care]

Fatigue, Quality of Life and Exercise Tolerance in Patients with Bronchiectasis

Aslıhan Çakmak¹, Deniz İnal İnce¹, Melda Sağlam¹, Cemile Bozdemir Özel¹, Hazal Sonbahar Ulu¹, Naciye Vardar Yağlı¹, Ebru Çalık Kütükcü¹, Hülya Arıkan¹, Lütfi Çöplü², Ziya Toros Selçuk²

¹Department of Physiotherapy and Rehabilitation, Hacettepe University, Health Sciences School, Ankara, Turkey

²Department of Chest Diseases, Hacettepe University School of Medicine, Ankara, Turkey

Objectives: Fatigue has inhibitive effects on physical functioning and performance in patients with chronic lung diseases. In this study, we aimed to investigate the relationship between fatigue, quality of life and exercise tolerance in patients with bronchiectasis.

Methods: Thirty patients with bronchiectasis (18F, 12M, mean age=37.07±17.33 years) were included. Pulmonary function testing and incremental shuttle walk test (ISWT) were performed. Fatigue perception was assessed using the Fatigue Impact Scale (FIS). Dyspnea perception using the Modified Medical Research Council Dyspnea Scale (MMRC) was determined. The quality of life was evaluated with the St George's Respiratory Questionnaire (SGRQ).

Results: Exercise tolerance was negatively correlated with cognitive, psychosocial, and physical fatigue dimensions of the FIS ($r=-0.422$, $r=-0.442$, and $r=-0.366$, respectively; $p<0.05$). Total FIS score also had a negative correlation with exercise tolerance ($r=-0.419$, $p<0.05$). There was strong positive correlation between all dimensions and the total score of the FIS and MMRC score, impact and the total score of SGRQ ($p<0.0001$). Total score of SGRQ explained 58.4% of the variance in the FIS.

Conclusion: Fatigue was found to be associated with dyspnea, quality of life, and exercise tolerance in patients with bronchiectasis. This finding suggests that particular evaluation of fatigue in this population is required for addressing its interaction with other functional parameters in a comprehensive manner.

Keywords: Bronchiectasis, exercise, fatigue, quality of life

[Abstract:0354] PS-122 [Accepted: Poster Presentation] [Clinical Problems - Pulmonary Vascular Diseases]

Hughes-Stovin Syndrome: A Rare Cause of Hemoptysis

Gülru Polat, Enver Yalnız, Gülistan Karadeniz, Merve Keskin, Görkem Veyisoğlu, Melih Büyüksirin, Fatma Demirci

Dr Suat Seren Chest Diseases and Surgery Training and Research Hospital, İzmir, Turkey

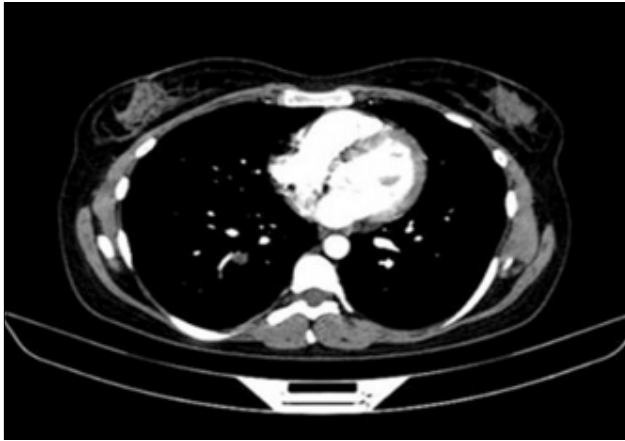


Figure 1.

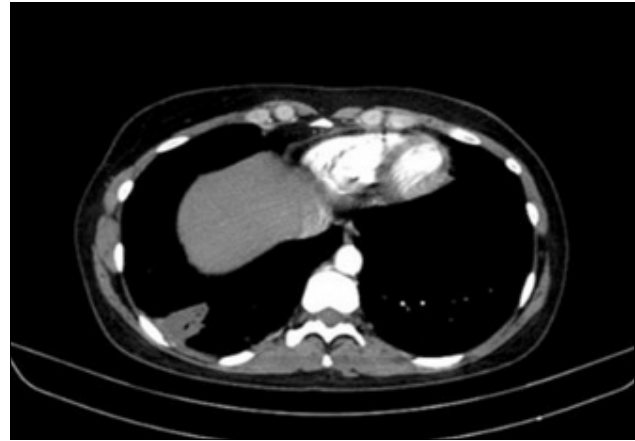


Figure 2.

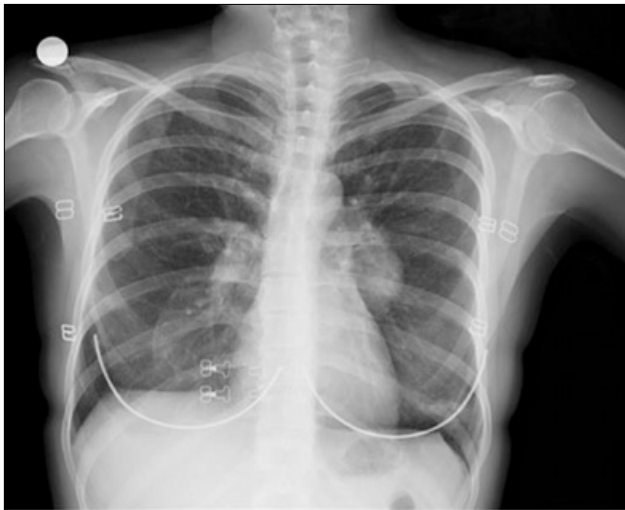


Figure 3.

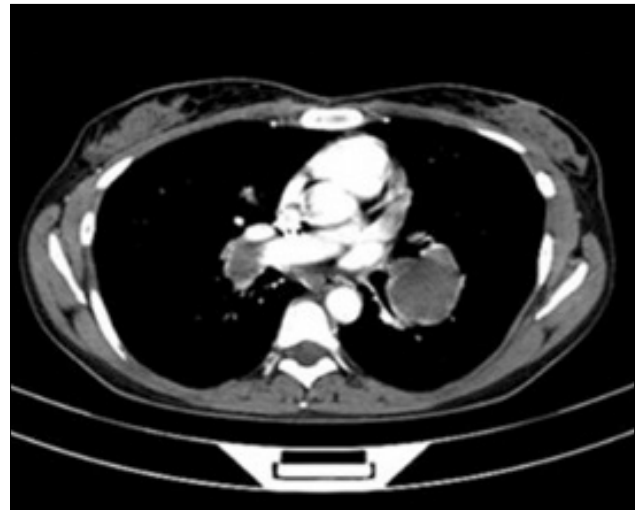


Figure 4.

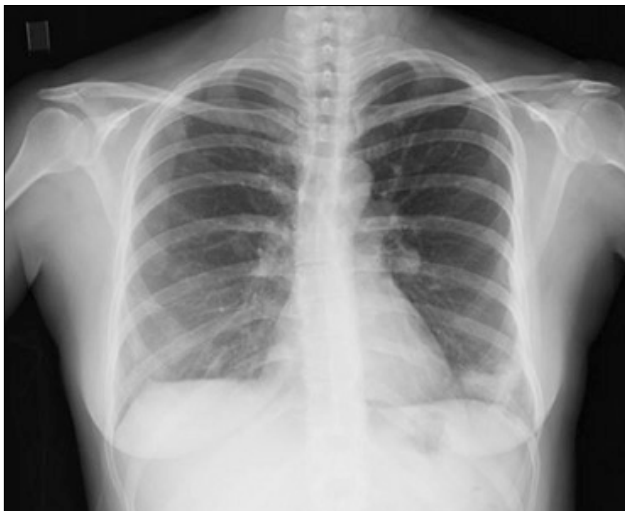

Figure 5.

Hughes-Stovin syndrome (HSS) is a rare disorder of unknown etiology. It is characterized by the combination of multiple pulmonary artery aneurysms (PAA) and deep vein thrombosis often involving the vena cava. Many authors consider it as an incomplete form of Behçet disease. PAA sometimes result in hemoptysis.

A 28-year-old female patient was admitted to emergency service with fever and chest pain 6 months ago. The thorax angiographic computerized tomography (CT) (Figure 1) was taken with the prediagnosis of pulmonary embolus. In CT, embolism-compatible filling defect in descending branch of the right pulmonary artery and consolidated area in the right lower lung lobe were observed. Low-molecular-weight heparin and oral warfarin treatment was started with the diagnosis of pulmonary embolism.

She applied with the severe chest pain at the third month. Thoracal CT (Figure 2) showed cavitary lesion on the left lower lobe. Transthoracic lung needle aspiration applied.

The pathological evaluation was benign. Antibiotherapy was initiated. The lesion was evaluated in favor of infarct and anti-coagulant treatment was continued. At the sixth month, the patient was interned because of haemoptysis story that lasted 1 week. Bilateral hilar enlargement observed on chest X-ray (Figure 3) . Thrombotic dilatations were detected in both pulmonary arteries on thoracal CT (Figure 4) .

Magnetic resonance (MR) angiography wanted. The left pulmonary artery terminates acutely after giving the branch leading to the upper lobe. 3.5 cm long and 3 cm wide aneurysm and complete thrombus seen. Similar appearance is seen in the lower lobe artery of the right pulmonary artery as nonaneurysmatic and short segment thrombosis in.

The rheumatological and serological tests of the patient were negative. There was no evidence of malignancy. No other signs of Behcet's disease were observed. No deep vein thrombosis was observed. However, inferior vena cava thrombosis was observed on MR angiography.

Patient was evaluated as Hughes stovin syndrome. After pulse steroid for 5 days, 1 mg/kg prednisolone treatment was started. The patient's hemoptysis decreased in 2 weeks. In the 3rd month of the steroid treatment, significant regression was observed in the hiler enlargement on PA (Figure 5) .

After the exclusion of malignancy, in the absence of diagnostic criteria for Behcet's disease, in a young patient with haemoptysis, HSS was diagnosed. We present the case, because of its rather rare appearance and typical radiological appearance.

Keywords: Hemoptysis, hughes stovin syndrome, pulmonary artery aneurysm

[Abstract:0355] PS-227 [Accepted:Poster Presentation] [COPD]

Relationship between Existence of Comorbidity and Pulmonary Function Tests, Life Quality, Exercise Capacity in Individuals with Chronic Obstructive Pulmonary Disease

Zehra Ekinçi¹, Öznur Yıldız²

¹Department of Pulmonary Diseases, Nevsehir State Hospital, Nevsehir, Turkey

²Department of Pulmonary Diseases, Ankara University School of Medicine, Ankara, Turkey

Objectives: Chronic Obstructive Pulmonary Disease (COPD) , a common preventable and treatable disease, is characterized by persistent airflow limitation that is usually progressive and associated with an enhanced chronic inflammatory response in the airways and the lung to noxious particles or gases. Comorbid diseases affect prognosis of COPD adversely. The aim of this study is to provide integrated perspective in pursuit of patients by demonstrating impact of comorbidities on pulmonary function tests, life quality, exercise capacity.

Methods: 60 patients with COPD admitted to Pulmonary Diseases Department in stable period were included in study. Cases are studied in two groups, as with and without comorbidities; number of comorbidity and the Charlson comorbidity index were calculated. Patients underwent pulmonary function tests. Life qualities were estimated by St. George's Respiratory Questionnaire, CAT scores and Clinical COPD Questionnaire. 6-minute walk test was performed to measure exercise capacity. Impacts of comorbidities on all these variables were evaluated.

Results: Groups with and without comorbidity show similar distributions in terms of gender, age, smoking, duration of disease and GOLD stage. Lower FVC values have been observed in case with comorbidities by evaluating relationship between comorbidities and pulmonary function tests. DLCO/VA ratio was significantly higher in the group with comorbidities, while there is no significant difference DLCO percentage of between two groups. It has been shown that increase in Charlson index causes decrease in FVC, FRC ve TLC and increase in FEV1/FVC. It has been presented that SGRQ activity, impact and total scores are higher in group with comorbidity. It has been seen that increase in Charlson comorbidity index score and comorbidity number cause higher SGRQ scores. In group with commordity, significantly higher CCQ functional scores have been determined. An increase in total and function scores of CCQ has been seen with increase in Charlson index. In accordance with this, cases with higher number of comorbidities have much higher CCQ functional score. A significant difference between CAT scores was not observed. In 6-minute walk test; significant decrease in walking distance of patients with comorbidities was observed. As Charlson comorbidity index score and comorbidity number increase, reduction was observed within walking distance.

Conclusion: In this study, it has been showed that comorbidities cause deterioration in different parameters in respiratory function of patients with COPD individuals, and affect quality of life and exercise quality negatively.

[Abstract:0357] PS-270 [Accepted:Poster Presentation] [Sleep-related Disorders]

Assessment of The Relationship Between The Risk of Obstructive Sleep Apnea and Nocturia

Bora İrer¹, Yelda Varol²¹Department of Urology, Izmir Metropolitan Municipality Eşrefpaşa Hospital, İzmir, Turkey²Department of Chest Diseases, Health Sciences University Dr Suat Seren Chest Diseases and Chest Surgery Training and Research Hospital, İzmir, Turkey**Objectives:** The aim of this study was to evaluate the relationship between the frequency of nocturia and the risk of obstructive sleep apnea (OSA) in patients who applied to the urology clinic with nocturia.**Table 1.** Demographic data of patients

Age (mean±SD) (Range)	52.6±12.8 (25-76)
Age (n,%)	
>50 year	59, 59%
<50 year	41, 41%
Gender (n,%)	
Male	81, 81%
Female	19, 19%
Frequency of Nocturia (mean±SD)	2.5±1.2 (1-5)
BMI (mean±SD)	28.8±4.3 (19.5-41.4)
BMI (n,%)	
>35 kg/m ²	14, 14%
<35 kg/m ²	86, 86%
Number of Comorbidity (mean±SD)	0.7±0.9 (0-3)
Systemic disease (n,%)	
Yes	54, 54%
No	46, 46%
Smoking packet/year (mean±SD)	16.8±20.3
Total IPSS score (mean±SD)	12.1±7.4 (1-31)
IPSS quality of life score (mean±SD)	3.5±1.5 (0-6)
Severity of IPSS (n,%)	
Mild	28, 35.0%
Moderate	39, 48.8%
Severe	13, 16.3%
Total OABSS score (mean±SD)	17.5±9.3 (4-40)
OAB (n,%)	
Yes	83, 83%
No	17, 17%
Total Epworth test score (mean±SD)	9.4±5.5 (0-24)
Risk of OSA (n,%)	
Low	26, 26%
Moderate	19, 19%
High	55, 55%

OAB, Overactive Bladder; SD, Standard Deviation; BMI, Body Mass Index; IPSS, International Prostate Symptom Score; OABSS, Overactive Bladder Symptom Score. OSA; Obstructive Sleep Apnea

Methods: In the study, 100 patients with nocturia complaints included. To determine the nocturnal frequency, male patients were asked to fill the International Prostate Symptom Score (IPSS) form and Overactive Bladder Symptom Score (OABSS) questionnaire, while female patients were asked to fill form OABSS only. The STOP-Bang Questionnaire and the Epworth Sleepiness Test were administered to patients for assess the OSA risk. Patients were divided into three OSA risk groups according to the STOP-Bang Questionnaire results. The IPSS, OAB survey results and frequency of nocturia of each group were compared and the relationship between OSA risk and nocturia was investigated. Patients treated for benign prostatic hyperplasia and OAB were not included in the study.**Results:** In the study, the mean age of the patients was 52.6±12.8 and 26% of patients had low OSA risk, 19% had moderate and 55% had high OSA risk. The demographic data of the patients are presented in Table 1. There was a statistically significant difference in the frequency of nocturia, total OABSS scores, the OAB presence, total IPSS and IPSS severity in patients with low, moderate and high OSA risk (Table 2) . Statistically significant differences were observed between groups in terms of age, presence of systemic disease, BMI, smoking history and comorbidity numbers (Table 2) . In this study, correlation analysis showed that as the frequency of nocturia increases in patients, the level of OSA risk increases. There was a statistically significant correlation between frequency of nocturia, total IPSS, the IPSS severity, total OABSS scores and the OAB presence and the level of OSA risk (p<0.00, r=0.706) . Other factors affecting the increase in OSA risk level were age, BMI, smoking, total IPSS, IPSS severity, total OABSS scores and the OAB presence (r=0.567, p<0.001; r=0.325, p=0.001; r=0.321, p=0.001; r=0.432, p<0.001; r=0.366, p=0.001; r=0.341, p=0.001; r=0.310, p=0.002, respectively) .**Conclusion:** In conclusion, it has been shown that the OSA risk was higher in patients with more frequent nocturia, the level of OSA risk should be determined in patients with OAB and severe lower urinary system symptoms and these patients should be evaluated with a multidisciplinary approach. However, there is a need for wider series of studies in which polysomnography is also performed, to be able to demonstrate nocturia and other voiding symptoms among OSA risk factors.

Table 2. Distribution and relationship of nocturia and other possible risk factors according to risk levels of OSA

	Low OSA risk n= 26, 25%	Moderate OSA risk n= 19, 15%	High OSA risk n=55, 60%	P value
Age (year) (mean±SD)	39.7±9.7	55.5±8.6	57.7±11.1	<0.001
Gender (n, %)				
Male	20, 76.9%	12, 63.2%	48, 87.3%	0.069
Female	6, 23.1%	7, 36.8%	7, 12.7%	
BMI (kg/m ²) (mean±SD)	26.4±3.1	28.9±4.3	29.9±4.5	0.004
Frequency of Nocturia (mean±SD)	1.3±0.5	1.9±0.9	3.2±1.0	<0.001
Systemic Disease (n, %)				
Yes	4, 15.4%	4, 21.1%	38, 69.1%	<0.001
No	22, 84.6%	15, 78.9%	17, 30.9%	
Total IPSS score (mean±SD) (only men)	7.3±6.4	9.9±7.1	14.6±7.8	<0.001
Severity of IPSS (n, %)				
Mild	12, 60.0%	6, 50.0%	10, 20.8%	0.018
Moderate	7, 35.0%	5, 47.1%	27, 56.3%	
Severe (only men)	1, 5.0%	1, 2.9%	11, 22.9%	
IPSS Quality of life score (mean±SD) (only men)	2.4±1.2	3.0±1.4	4.1±1.4	<0.001
Total OABS score (mean±SD)	12.6±8.6	16.7±10.4	20.0±8.3	0.002
OAB (n, %)				
Yes	17, 65.4%	15, 78.9%	51, 92.7%	0.008
No	9, 34.6%	4, 21.1%	4, 7.3%	
Total Epworth Test score (mean±SD)	5.4±3.7	6.3±4.1	12.3±4.8	<0.001
Smoking packet year (mean±SD)	8.2±11.4	11.1±16.0	22.8±23.0	0.003
Number of Comorbidity (mean±SD)	0.2±0.7	0.3±0.5	1.1±1.0	<0.001

OAB, Overactive Bladder; SD, Standard Deviation; BMI, Body Mass Index; IPSS, International Prostate Symptom Score; OABSS, Overactive Bladder Symptom Score. OSA; Obstructive Sleep Apnea One-Way ANOVA test for continuous variable and Chi-square test for categorical variable

Keywords: Nocturia, risk factors, sleep apnea

[Abstract:0358] PS-064 [Accepted:Poster Presentation] [Thoracic Surgery]

Rare Cause of Pleural Nodularity and Mediastinal Lymphadenopathy: Splenosis

İsmail Can Karacaoğlu¹, Alper Avcı¹, Cemal Özçelik¹, Derya Gümürdülü²

¹Department of Thoracic Surgery, Çukurova University School of Medicine, Adana, Turkey

²Department of Pathology, Çukurova University School of Medicine, Adana, Turkey

Splenosis is a rare condition described as ectopic splenic tissue autotransplantation generally after a splenic rupture, most often an incidental finding on chest computed tomography, typically showing solitary or multiple welldefined, noncalcified pleural nodules of variable size in the left hemithorax. Splenosis is a benign disease, and the diagnosis can be challenging as the multiple incidentally found nodules could mimic malignancy.

A 42-year-old male patient who had a history of splenectomy operation due to gunshot wound 24 years ago was referred to our hospital with hypermethabolic lesion on left upper pulmoner lobe, left hiler lymphadenopathy and pleural hypermethabolic nodules on positron emission computed tomography (PET/CT) . CT guided transthoracic lung biopsy from the mass on left upper lobe reported non-small cell lung cancer. Left thoracotomy was attempted. During the intraoperative observation,

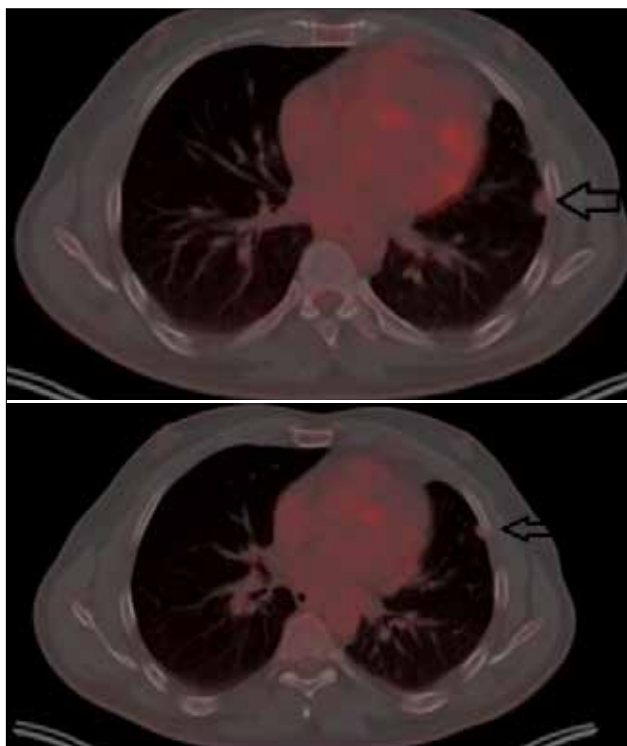


Figure 1. PET/BT

dark colored, soft, multipl nodular lesions were observed. Intraoperatively biopsies were taken from parietal pleural nodules and frozen section showed reactionary lymph nodes. The mass was showing invasion to lower lobe through the fissure. In exploration, mediasten pleural nodules and subaortik lymph nodes were found and biopsies were taken. Frozen was attempted. Mediasten pleural nodules were reported as reactionary lymph nodes, subaortik lymph node was reported as metastatic lymph node. Left pneumonectomy and mediastinal lymph node dissection was attempted. The histopathological examination of the specimen showed splenic tissue in the parietal and mediasten pleura and number 10 hilar lymph node so the lesions were accepted as splenosis. The mass was 3*3*2 cm (T2A) , number 5, 6 and 10 mediastinal lymph nodes were metastatic (N2) , M0, Stage 3A.

Patient went chemotherapy and still under follow-up.

Most of the splenosis cases involve the abdomen. Rarely, splenic tissue may gain access into the thorax either from a diaphragmatic tear or through diaphragmatic foramina, and seed the pleural space. Splenic implants derive their blood supply from surrounding tissue and grow into mature splenic tissue.

In conclusion, a preoperative diagnosis of thoracic splenosis can prevent unnecessary biopsy or thoracotomy in patients with multiple, asymptomatic, left-side pleura-based lesions if the patient has an appropriate history of splenic injury. However, if a biopsy is performed without knowing the patient's history, the pathologists should consider the possibility of thoracic splenosis, even if the slide is offered for frozen diagnosis intra-operatively.

Keywords: Thoracic, splenosis, lung, cancer, gunshot, trauma

[Abstract:0364] PS-220 [Accepted:Poster Presentation] [COPD]

Investigation of Relationship Between Four Meter Gait Speed Test And Cardiopulmonary Exercise Test to Determine Exercise Capacity in COPD Patients

Oğuz Karcioğlu, Sevinç Sarınc Ulaşlı, Ahmet Uğur Demir

Department of Pulmonary Diseases, Hacettepe University School of Medicine, Ankara, Turkey

Objectives: Exertional dyspnea and exercise intolerance due airway obstruction and air trapping caused by parenchymal destruction are the major symptoms of chronic obstructive pulmonary disease (COPD) . 6 minute walking test (6MWT) and cardiopulmonary exercise tests (CPET) are the main tests for the diagnosis and follow-up of exercise intolerance in COPD. 4 meter gait speed test (4MGS) is usually used to follow the exercise capacity of geriatric population. Aim of the study is to investigate the correlations between 4MGS, 6MWT and CPET.

Methods: CPET was performed to totally 23 COPD patients admitted to the outpatient clinic of the Pulmonary Diseases Department. After 24 hours and at the same period of day, patients carried out 6MWT and 4MGS. Spirometry and hand-grip tests were also performed.

Results: The mean age of the patients was 58.1±7.3 years. 21 (91.3%) of the patients were male and 2 (8.7%) were female. 16 (69.5%) patients were in GOLD group A, 6 (26%) were in group C and 1 (4%) was in group B. There were significant relationships between 4MGS with 6MWT distance and peak VO₂ measurements (p<0.001, p=0.029 respectively) . 4MGS

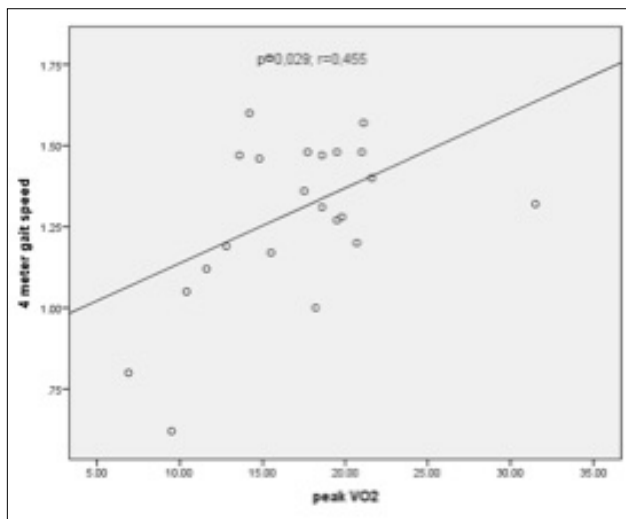


Figure 1. Relationship between 4 meter gait speed and peak VO2 in COPD patients

was significantly correlated with peak VO2 ($p=0.029$, $r=0.455$) (Figure 1) Additionally 4 meter gait speed was also strongly correlated with COPD assesment test (CAT) and BODE index ($p<0.001$, $r=-0.712$; $p= 0.002$, $r=-0.600$ respectively) .

Conclusion: 4MGS strongly correlated with 6MWT distance and CPET parameters. 4MGS is an easy and short test which may be used to follow exercise capacity of patients with COPD.

Keywords: Cardiopulmonary exercise test, COPD, dyspnea, four meter gait speed test

[Abstract:0367] SS-062 [Accepted:Oral Presentation] [Experimental Investigations]

Liquid Biopsy Profiles of Lung Cancer Patients

Yasemin Saygıdeğer¹, Atıl Bişgin²

¹Department of Pulmonary, Cukurova University School of Medicine, Adana, Turkey

²Department of Genetics, Cukurova University School of Medicine, Adana, Turkey

Objectives: Diverse oncogenic driver mutations have been discovered over the last decade explaining variety in response to lung cancer treatment and thus, directed the treatment options towards personalized therapy strategies. Therefore genetic profiling of tumors has become extremely important. Tissue biopsy is the gold standard for genotyping the tumors but there is a limitation in using the patients' small biopsy samples. Furthermore, single tumor biopsies usually do not represent the entire genomic profile of the tumor. Liquid biopsy is a new non-invasive approach to detect disease biomolecules in blood, urine and other body fluids. It is a useful method when the tissue sample is limited, sample contains insufficient tumor tissue,

Table 1. ccfDNA Profile of NSCLC Patients

Sample No	Pathology	Gene and Exon	Nucleotide exchange	Amino acid change
1	Adenocarcinoma	EGFR (Exon 19)	NM_005228.4: c.2236_2250delGAATTAAGAGAAGCA	p.E746_A750del
2	Adenocarcinoma	MET (Exon 14)	NM_001127500.2: c.2958A>T	p.L986F
		MET (Exon 14)	NM_001127500.2: c.2996A>G	p.D999G
3	Adenocarcinoma	MET amplification (+)	-	-
4	Squamos cell	-	-	-
5	Adenosquamos	PIK3CA (Exon 10)	NM_006218.3: c.1633G>A	p.E545K
6	Adenocarcinoma	-	-	-
7	Squamos cell	-	-	-
8	Adenosquamos	ERBB2 amplification (+) EGFR amplification (+)	-	-
9	Adenocarcinoma	KRAS (Exon 2)	NM_004985.4: c.35G>T	p.G12V
10	Adenocarcinoma	MET (Exon 14)	-	p.R988C
		ERBB2 (Exon 17)	-	p.I655V

ccfDNA: circulating cell-free DNA, NSCLC: Non small cell lung cancer

tumors are hard to reach or regular monitoring is needed. Recent studies have revealed that patients with tumors have increased circulating cell free DNA (ccfDNA) comparing to normal individuals, and currently, next generation sequencing (NGS) is the best method to detect mutations in the ccfDNA. In this study, we aimed to detect mutations in blood samples of NSCLC patients, whose biopsy samples are not sufficient to analyze tissue genotyping, via NGS system.

Methods: NSCLC patients diagnosed with bronchoscopy, and had insufficient tumor material for tissue genotyping, between September 2017 and December 2017, included in the study. Blood samples were collected into PAXgene Blood ccfDNA tubes (Qiagen) that have ability to stabilize ccfDNA levels in plasma and prevent DNA crosslinking. Next, We performed the complete NGS workflow, and sequenced the cell free tumor DNA extracted from NSCLC patients. The multi-gene panel includes 15 lung cancer related genes (AKT1, ALK, BRAF, DDR, ERBB2, ESR1, KIT, KRAS, MAP2K1, NRAS, NTRK, PDGFRA, PIK3CA, PTEN and ROS) to sequence and additional copy number variations of 5 genes (RICTOR, EGFR, MET, FGFR1 and ERBB2) that all were selected to represent the most actionable genes. The sequencing was performed using a NGS platform (GeneReader NGS System, Qiagen) .

Results: Overall, in 3 months 40 patients with mass in their lungs recruited to the fiber-optic bronchoscopy unit and 23 of them were diagnosed lung cancer according to their bronchoscopic biopsy materials. 4 of the patients were SCLC (%17) and 19 were NSCLC (%83) . None of the materials were found sufficient for tissue genotyping. 10 of 19 patients at stage IV were further analyzed via liquid biopsy, and mutations or amplifications were detected in %70 of them (n=7) . List of the results is given in Table 1.

Conclusions: Liquid biopsy is a non-invasive useful tool to genotype NSCLC.

Keywords: Liquid biopsy, NSCLC, genotyping

[Abstract:0370] EPS-023 [Accepted: E-Poster] [Clinical Problems - Diffuse Parenchymal Lung Disease]

A Case of Bronchiolitis Obliterans Related to Chronic Graft Versus Host Disease

Serap Argun Barış, Ece Yetişgin, Haşim Boyacı, İlknur Başyığıt

Department of Pulmonary Diseases, Kocaeli University School of Medicine, Kocaeli, Turkey

Introduction: Patients undergoing allogeneic stem cell transplantation (allo-SCT) are often confronted with various infectious or non-infectious pulmonary complications. The major late post-transplantation complication is chronic pulmonary graft-vs.-host disease (cGVHD) . Bronchiolitis obliterans (BO) characterized with reduced FEV1, evidence of air-trapping or small airway thickening on chest-CT and the absence of opportunistic pulmonary infections is the dominant manifestation of cGVHD. Furthermore, bronchiectasis related to GvHD is rare.

Case Presentation: A 48-year-old woman admitted to outpatient clinic with progressive dyspnea and non-productive cough for 1 year. She had diagnosis of multiple myeloma. She underwent allogeneic SCT 2 years ago and autolog SCT 4 months after recurrence. She was treated with mycophenolate mofetil during this period. The symptoms of the patient were started 6 months after last SCT. Physical examination of the chest by auscultation revealed prolonged expiration and ronchi.

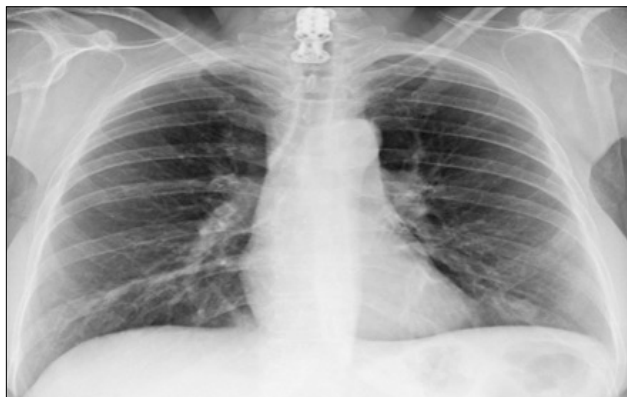


Figure 1. Chest x-ray

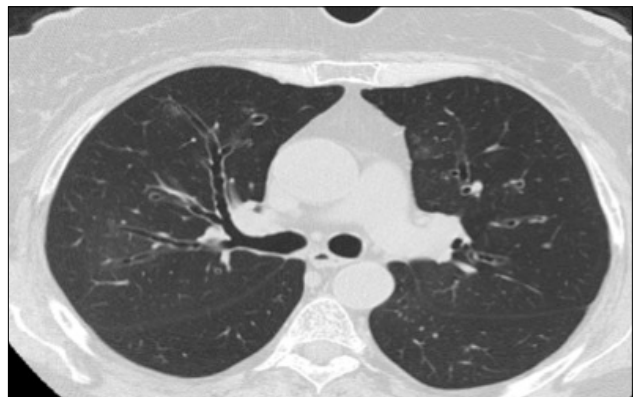


Figure 2. High resolution CT

Pulmonary function test parameters were as follows; FVC: 1.53 (%50) , FEV1: 0.63 (%24) and FEV1/FVC: %41. There was an increase in bronchovascular traces on PA chest X-ray (Figure 1) . HRCT revealed diffuse bronchial wall thickness, tubular bronchiectasis, air trapping areas which evaluated as bronchiolitis obliterans with having SCT history (Figure 2) . Fiberoptic bronchoscopy showed normal bronchoscopic findings. Bronchial lavage culture was normal. Opportunistic infections were excluded. During hospitalization, corticosteroid, nebulized bronchodilator therapy and oxygen were administered to control clinical signs. Long-term oxygen therapy has begun due to a significant reduction in oxygen saturation in the room air. Pulmonary rehabilitation and nutritional support were recommended.

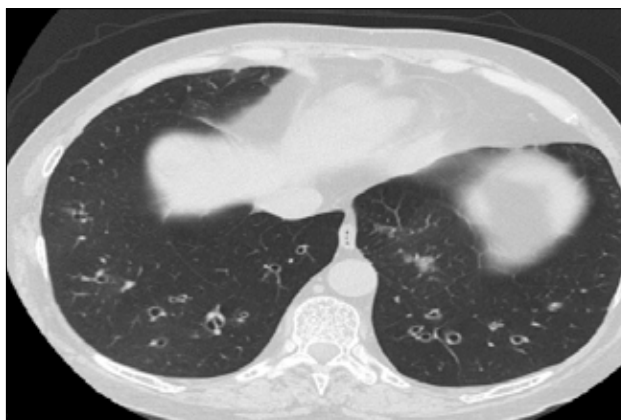


Figure 3. High resolution CT

Conclusion: In patients with allogenic stem cell transplantation, bronchiolitis obliterans should be considered in the presence of shortness of breath and wheezing, respiratory functions and HRCT screening should be planned for diagnosis.

Keywords: Air Trapping, allogenic stem cell transplantation, bronchiolitis obliterans, dyspnea

[Abstract:0371] EPS-141 [Accepted: E-Poster] [Pulmonary Rehabilitation and Chronic Care]

Respiratory Function in High and Low Resistance Brass Players

Dilara Saklıca, Deniz İnal İnce, Naciye Vardar Yağlı, Melda Sağlam, Ebru Çalık Kütükçü, Hülya Arıkan

Department of Physiotherapy and Rehabilitation, Hacettepe University School of Medicine, Ankara, Turkey

Objectives: Wind instrument playing may differ according to resistance of the wind instrument. The purpose of this study was to compare pulmonary function, respiratory muscle strength and endurance in low and high resistance (LR and HR, respectively) brass players.

Methods: Twenty-five subjects (18-58 years, 13 M, 12 F) participated in this study. Pulmonary function testing was performed, respiratory muscle strength was measured. Respiratory endurance was evaluated using incremental threshold loading test.

Results: The forced expiratory volume in one second (FEV1) and forced expiratory flow of 25% to 75% (FEF25-75%) was significantly lower in LR brass players as compared with HR brass players ($p<0.05$) . There was a significant decrease in maximal inspiratory and expiratory pressure (MIP and MEP, respectively) in LR brass players than those of HR brass players ($p<0.05$) . Respiratory muscle endurance was higher in LR players than HR brass players ($p<0.05$) .

Conclusion: Large and small airway function, inspiratory and expiratory muscle strength were lower but respiratory muscle endurance was higher in The reason for the findings probably due to the fact that embouchure of the LR is open to air, and therefore impedance is lower during LR playing.

Keywords: Brass players, MEP, MIP, respiratory function, respiratory muscle endurance

Table 1. Respiratory Parameters

Variable	LR (n=10)	HR (n=15)	p
Age (years)	28.80±11.62	29.47±7.70	0.876
Height (cm)	169.90±5.30	175.40±10.40	0.096
Weight (kg)	58.60±9.68	74.33±14.79	0.004*
Body mass index (kg/m ²)	19.64±2.00	23.84±2.91	<0.001*
Duration of playing (years)	16.90±11.39	15.73±6.67	0.775
Duration of daily practice (hours)	4.60±1.77	3.27±0.96	0.050
Smoking (pack-years)	5.20±5.94	6.96±6.50	0.491
FVC (%)	98.20±12.79	97.87±10.19	0.333
FEV1 (%)	89.60±10.12	98.93±11.74	0.046*
FEV1/FVC	93.90±13.73	98.80±11.06	0.027*
PEF (%)	84.90±17.15	97.60±14.74	0.072
FEF25-75% (%)	67.30±16.56	89.93±21.60	0.007*
MIP (cmH ₂ O)	99.70±24.78	120.00±15.32	0.037*
%MIP	98.55±19.42	98.09±21.68	0.957
MEP (cmH ₂ O)	108.10±24.69	149.07±26.26	0.001*
%MEP	159.10±31.33	144.783±33.98	0.292
Incremental threshold loading	26277.80±13975.33	13089.33±12028.13	0.026*

* $p<0.05$. Student t test

[Abstract:0372] SS-048 [Accepted: Oral Presentation] [Sleep-related Disorders]

The Relationship between Body Mass Index and Sleep Parameters in Morbidly Obese Patients

Bilge Yılmaz Kara¹, Songül Özyurt¹, Süleyman Kalcan², Dilek Karadoğan¹, Ünal Şahin¹¹Department of Pulmonary Diseases, Recep Tayyip Erdogan University School of Medicine, Rize, Turkey²Department of General Surgery, Recep Tayyip Erdogan University School of Medicine, Rize, Turkey

Objectives: The incidence and severity of obstructive sleep apnea syndrome (OSAS) are increasing in obese patients. The aim of our study is to investigate the relationship between body mass index (BMI) and sleep parameters in morbidly obese patients who are scheduled for bariatric surgery.

Methods: Thirty-two morbidly obese patients (BMI \geq 40 kg/m²) who were scheduled to undergo bariatric surgery between January and December 2017 were enrolled. Patients with limited life expectancy due to irreversible cardiopulmonary or

Table 1. Demographic, anthropometric and polysomnographic data of all patients.

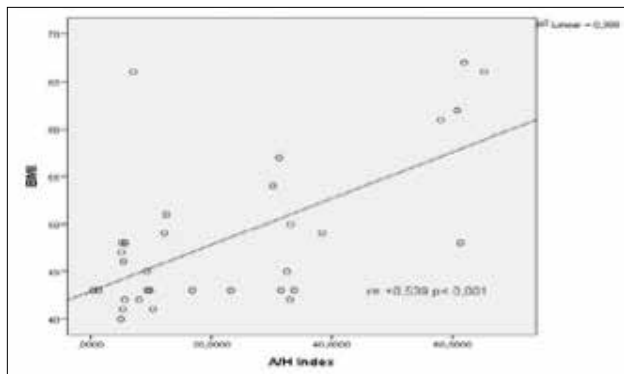
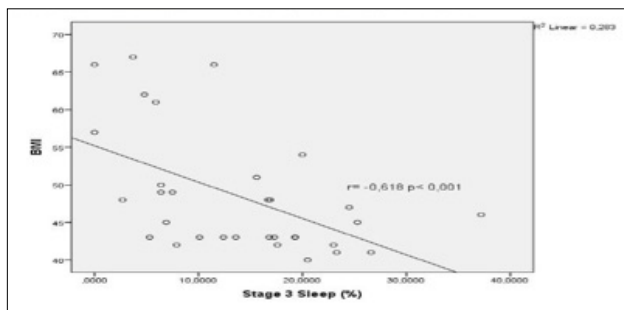
Parameters	Median	IQR	Minimum	Maximum
Demographic - anthropometric				
Age (years)	43,5	18,2	18	61
Gender (female/male)	21 / 11			
Height (cm)	164,5	16	153	185
Weight (kg)	132	26	96	224
BMI (kg/m ²)	45,5	7	40	66
Neck circumference (cm)	41,5	6	36	51
Waist circumference (cm)	136,5	19	109	170
Polysomnography				
Respiratory Parameters				
A/H Index	12,3	27,4	0,4	65,2
Number of central apneas	1,7	3	0	21
Number of obstructive apneas	17	98	0	445
Number of hypopneas	31,5	61	0	211
Snore index*	122,5	242	0	641
Minimum saturation (%)	80,5	16	50	92
Maximum saturation (%)	98	1	94	100
Average saturation (%)	93	4	84	96
Percentage of desaturation (%)**	11,5	45,7	0	97,9
Sleep Stages				
Stage 1 (%)	2,6	1	1,5	5
Stage 2 (%)	50,8	11,8	36,3	76,2
Stage 3 (%)	14,6	13,4	0	37,2
REM (%)	11,4	9,5	1,7	21,7
Level of Daytime Sleepiness				
Epworth score	5	7	0	16

IQR: Interquartile range, BMI: Body mass index, A/H Index: Apnea hypopnea index, Snore index*: Number of snores per hour of sleep, Percentage of desaturation**: Percentage of the total sleep time when recorded SaO₂ is < 90%, REM: Rapid eye movements

Table 2. Correlation analysis between polysomnographic parameters and BMI (kg/m²)

BMI (kg/m ²)	R	P
Respiratory Parameters		
A/H Index	+0,539	<0,001
Number of central apneas	-0,224	0,210
Number of obstructive apneas	+0,644	<0001
Number of hypopneas	-0,137	0,446
Snore index*	+0,374	0,032
Minimum saturation (%)	-0,482	0,004
Maximum saturation (%)	-0,438	0,011
Percentage of desaturation (%)**	+0,500	0,003
Sleep Stages		
Stage 1 (%)	+0,084	0,643
Stage 2 (%)	+0,305	0,084
Stage 3 (%)	-0,618	<0,001
REM (%)	-0,100	0,578
Level of Daytime Sleepiness		
Epworth score	+0,310	0,090

BMI: Body mass index, A/H Index: Apnea hypopnea Index, Snore index*: Number of snores per hour of sleep, Percentage of desaturation**: Percentage of the total sleep time when recorded SaO₂ is < 90%, REM: Rapid eye movements

**Figure 1.** The relationship between BMI (kg/m²) and A/H Index**Figure 2.** The relationship between BMI (kg/m²) and Stage 3 Sleep (%)

$p < 0.001$. There was no significant correlation between BMI and central apnea, hypopnea, stage 1-2, REM (%) and Epworth score (Table 2) . There was a statistically significant positive correlation between BMI and AHI (Figure 1) and a negative correlation between BMI and stage 3 (%) sleep (Figure 2) .In the ROC curve, BMI was associated with severe OSAS with a cut-off value of 47.5 kg/m² with 69.2% sensitivity and 75% specificity (Figure 3) .

other end-organ failure and metastatic or inoperable malignancy were excluded from the study. Preoperative demographic and antropometric data was recorded. All patients underwent full night polysomnographic recording. Respiratory parameters (apnea-hypopnea index (AHI) ,central and obstructive apneas, hypopneas,snore index, minimum and maximum oxygen saturation,percentage of desaturation) and sleep stages (percentage of stages 1, 2, 3 and REM) were recorded.Epworth sleepiness scale was applied to all patients with polysomnography (PSG) .

Results: Thirty two morbidly obese patients who are scheduled for bariatric surgery (21 female, median age:43 years, minimum (min.) -maximum (max.) age:18-61 years) underwent overnight PSG. Median BMI was 45.5 kg/m² (min-max.: 40-66 kg/m²) . Median AHI was 12.3 (min-max: 0.4-65.2) . Two patients (6.3 %) had AHI<5,15 patients (46.8%) had AHI between 5-15, 2 patients (6.3 %) had AHI between 5-15 and 13 patients (40.6) had AHI>30. Median Epworth sleepiness score was 5 (min-max:0-16) (Table 1) . Correlation analysis between BMI and polysomnographic parameters revealed a positive correlation with AHI (r:+0.539, $p < 0.001$) , number of obstructive apneas (r:+0,644, $p < 0,001$) and snore index (r:+0,374, $p:0,032$) and a negative correlation with minimum saturation (r:-0,482, $p:0.004$) ,maximum saturation (r:-0.438, $p:0.011$) ve stage 3 sleep (%) (r:-0.618,

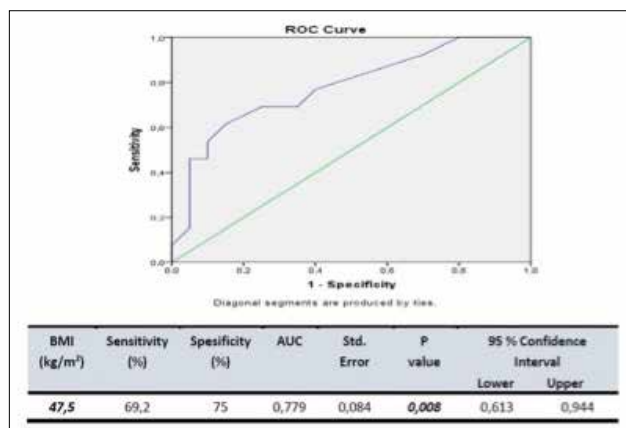


Figure 3. ROC analysis of the relationship between BMI (kg/m²) and severe OSAS (AHI >30)

Conclusion: In bariatric surgery candidates with morbid obesity, only 6,3% of patients had normal AHI values and severe OSAS was detected in 40.6% of patients. As BMI increased, the severity of OSAS increased and stage 3 (%) sleep decreased. BMI was associated with severe OSAS with a cut-off value of 47.5 kg/m² with 69.2% sensitivity and 75% specificity. Since there was no correlation between BMI and Epworth score in our study, morbidly obese patients should be screened by PSG for OSAS, even if they have no sleep related complaints.

Keywords: Obesity, obstructive sleep apnea syndrome, body mass index, polysomnography, sleep disorder

[Abstract:0373] EPS-094 [Accepted: E-Poster] [Lung and Pleura Malignancies]

3 Years Survival of Patients with Lung Cancer

Cengiz Özdemir¹, Kaan Kara², Nurdan Kalkan¹, Sedat Altın¹, Handan Altın¹

¹Health Sciences University Yedikule Chest Diseases and Surgery Training and Research Hospital, İstanbul, Turkey

²Ağrı Doğubeyazıt State Hospital, Ağrı, Turkey

Objectives: Although it is known that our patients with lung cancer have been living for a mean of 12 months, we aimed to investigate the recent status due to the increase of early diagnosis and the development of new treatment options in recent years.

Methods: Survival rates for 36 months were calculated using Ministry of Health and TUIK data. Comparisons were made with the Kaplan-Meier Survival Analysis.

Results: 5.603 (63.1%) (12.954 males, 2.649 females) of 19.289 (78.9%) males and 5.111 females total of 24.200 patients who were diagnosed with C34 lung cancer by ICD10 code in 2014, the mean survival time was 17.3+4.5 months, and the median survival was 11 months, in which the patient died and 8.597 patients (6.135 male, 2.462 female) were alive. 12.610 (52.1%) patients (10.591 (10%) died in the first month of diagnosis (2018 (10.6% male and 392 (7.7%) female) 55.5 male and 2.019 (39.5% female) were found to have died at the end of the first year. At the end of the 24th month, 14.950 (61.8%) of the patients (12.435 (65.1%) of the men died and 2.515 (49.2%) of the women), 1341 women). At the end of the 3rd year, 16.4% of the men and 26.2% of the women, 18.5% of the total were alive. In our study where 1 year survival rate was 47,9%, 2 year survival rate was 38.2% and 3 year survival rate was 18.5%, the rate of 3 years surveillance was 33.5%, that of radiotherapy was 2982 13.4% of the patients were treated with chemotherapy, 21,2% of the patients were treated with chemotherapy (42.9%), and 14.7% were treated with only palliative treatment (8.5%). While 1 year surplus is calculated as 44.5% for men, 34.9% for 2 years, and 16.4% for 3 years, the rate of 1 year surcharge is 60.5% for women, 2 years surcharge is 50.8% and 3 years surcharge is 26% It was found as 2. Survival rates of lung cancer in females were higher than males (p<0.001).

Conclusion: In our country, the 3-year follow-up of lung cancer is more frequent in female patients, and the histological type may be different as well as the stage differences which are one of the limitations of our study.

Keywords: Survey, lung cancer, Turkey

[Abstract:0374] EPS-138 [Accepted: E-Poster] [Pulmonary Pathology]

A Case of Ankle Spondylitis Detected by Pleural Effusion in Diabetic Patient

Elvin Çetiner, Gülşah Ethemoglu

Mehmet Akif İnan Training and Research Hospital, Şanlıurfa, Turkey

Apical pleural thickening with fibrobullous disease is common in pleuropulmonary manifestation of ankylosing spondylitis (AS). Other forms of pleural disease are rare and there are few reports of treatment of pleural effusions associated with AS. We report a case of persistent exudative pleural effusion in AS and the therapeutic thoracentesis. A 56-year-old male with a 2-year history of diabetes documented and had been treated with antidiabetics, with a 6-month history of persistent shortness of breath and increase of dyspnea with chestpain. A chest radiograph showed left pleural effusion CT scan also showed pleural effusion measured 4 cm in the widest place on the left hemithorax and in the lung parenchyma adjacent to the effusion minimal compression atelectasis was seen. Despite several pleural punctures over the next 4 months, the effusion reaccumulated rapidly and the characteristics did not change. We started oral prednisolone therapy even if uncontrolled blood sugar and diabetes over following 3 months. Fortunately the effusion did not reaccumulate or increase over the following 13 months, and his forced vital capacity improved from 630 mL to 910 mL. Although blood sugar regulation provided even if we used systemic steroid.

The pathogenesis of subpleural inflammation in pleuritis with AS remains unknown. Transbronchial biopsy specimens of the lung in AS showed interstitial fibrosis. The fibrosing inflammatory process of pleura might have been caused by contiguous extension of the vertebral inflammatory fibrosis into the pulmonary parenchyma and subpleural space.

There are no reports of a temporal relationship between activity in the spinal column and pleural disease, or of the response to the treatment of pleural effusion in AS. Kinnear et al. reported a case with bilateral pleural effusion complicating AS, and the effusion resolved completely after systemic administration of 30 mg of prednisolone. This case has some similarities to our case, but we are not able to explain the mechanism of the therapeutic effect of prednisolone. On the other hand, pericarditis is a rare association of AS which responds well to steroids and uveitis associated with AS also responds to local steroid therapy. These were the reasons for choosing the successful steroid therapy.

Keywords: Ankle spondylitis, pleural effusion, steroid

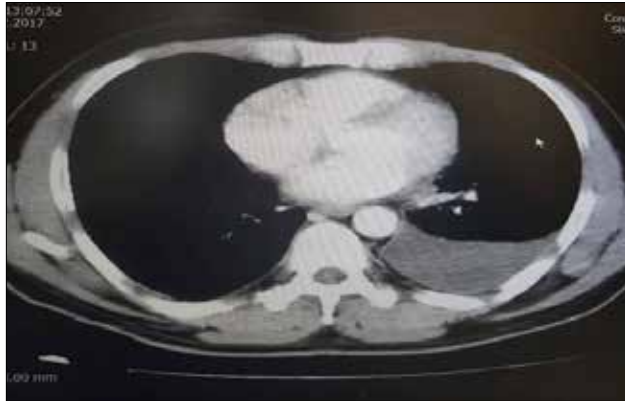


Figure 1. Left pleural effusion measured 4 cm in the widest place on the left hemithorax, mediastinal sight

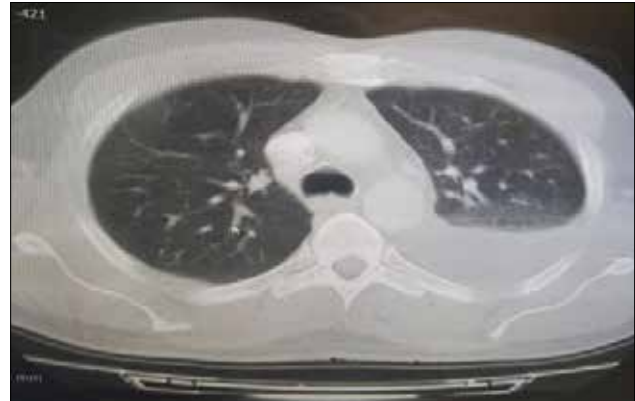

Figure 2. Left pleural effusion measured 4 cm in the widest place on the left hemithorax parenchymal sight

[Abstract:0375] PS-118 [Accepted:Poster Presentation] [Pulmonary Rehabilitation and Chronic Care]

An Evaluation of Respiratory Muscle Strength and Posture in Professional Dancers

Bilge Taşkın, Naciye Vardar Yağlı

Department of Physiotherapy and Rehabilitation, Hacettepe University School of Health Sciences, Ankara, Turkey

Objectives: It has been shown that in the literature, lung capacity increases, lung function develops and postural control increases in professional dancers. Respiratory muscle strength and static posture were not investigated. Our study was aimed to determine respiratory muscle strength and posture in professional dancers.

Methods: Twenty professional dancers (mean age: $22.95 \pm 3,5$ years, mean duration of dance 8 ± 6 years) participated in this study. Maximal inspiratory pressure (MIP) and maximal expiratory pressure (MEP) were measured using a portable mouth-piece pressure device. For postural analysis, a mobile phone application called "Posture Zone" was used.

Results: In professional dancers, mean MIP was 90.9 ± 27.38 cm H₂O, mean MEP was $103 \pm 33,5$ cmH₂O. According to the anterior posture analysis, the average lateral tilt of the dancers was 0.685 ± 0.47 degrees, the average of the shoulders was 1.29 ± 0.86 degrees, the mean pelvic inequality was 1.56 ± 1.36 degrees, 34 ± 0.82 degrees, with a mean shoulder protraction of 1.36 ± 0.91 degrees and anterior pelvic tilt an average of 1.34 ± 0.94 degrees. In 10% of the dancers, there was a lateral head tilt, 45% of shoulder inequality, 50% of pelvic inequality, 65% of anterior head tilt, 65% of shoulder protraction and 45% of anterior pelvic tilt. There was no statistically significant correlation between respiratory muscle strength and postural analysis parameters ($p > 0.05$).

Conclusion: Although respiratory muscle strengths of dancers were high, they were not significantly elevated. Mostly lumbal lordosis increased, kyphosis developed and head was anteriorly displaced. Postural problems can develop in dancers and respiratory distress can be seen. These parameters should be evaluated in detail in the rehabilitation of professional dancers.

Keywords: Dancers, respiratory muscle strength, postural analysis

[Abstract:0377] EPS-113 [Accepted: E-Poster] [Lung and Pleura Malignancies]

Primer Pulmoner Adenoid Kistik Karsinom

Gülru Polat, Gülistan Karadeniz, Filiz Güldağ, Merve Keskin, Özdal Güneş, Enver Yalınz

Dr Suat Seren Chest Diseases and Surgery Research and Training Hospital, Izmir, Turkey

Pulmonary adenoid cystic carcinoma (PACC) is malignant epithelial tumor and is rare in primary lung cancers. Slow growth, long life expectancy, asthma or recurrent pneumonia are hallmarks. Because of its rare occurrence, we wanted to present our case in the context of the literature.

A 63-year-old female patient was diagnosed as asthma for 3 years. She had dyspnea, cough, and increased sputum complaints for the last one month. On the chest x-ray (Figure 1) she had consolidation and atelectasis findings. On the chest computed tomography (Figure 2 a, b), soft tissue density narrowing the right main bronchus, consolidation-obstructive pneumonia on the right lower lobe and right pleural fluid findings were monitored and the patient was referred to our hospital for further examination and treatment.

On bronchoscopy, right main bronchus was compressed from the outside and obstructed with polypoid tissue. TBNA and forceps biopsies were performed. The cytology was malignant and endobronchial biopsy came as Adenoid Cystic Carcinoma. Immunohistochemical SMA (+), S-100 (+), p63 (+), CK7 (+), TTF-1 (-). The cranial MR scan were normal. There was a

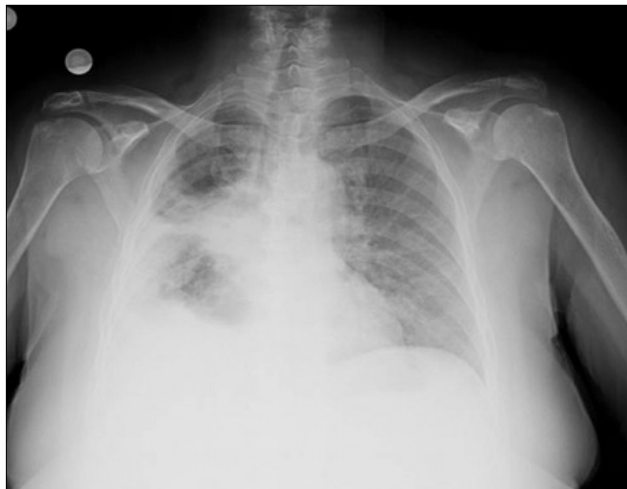

Figure 1.

3.2 cm soft tissue lesion extending to the subcarinal area accompanied by atelectatic, consolidative changes in the periphery surrounding the right main bronchus and increased FDG in the subcarinal lymph node (SUVmax: 5.5), increased FDG uptake in the consolidation area (SUVmax: 6.7) involving the left lower lobe showed FDG uptake in the same level as surrounding tissue, Increased FDG uptake (SUV max: 10.3) was present in hypodense lesion that tended to merge with 7 cm diameter in the liver on PET-CT. Patient staged as T3N2M1- Stage 4. Cisplatin-gemstabin chemotherapy was initiated due to adenoid cystic carcinoma.

Adenoid Cystic carcinoma originates mainly from the major and minor salivary glands.

Tracheobronchial adenoid cystic carcinoma is found in the main bronchus and distal part of the trachea in 2/3. It is typical for polypoid lesions in the trachea and bronchi.

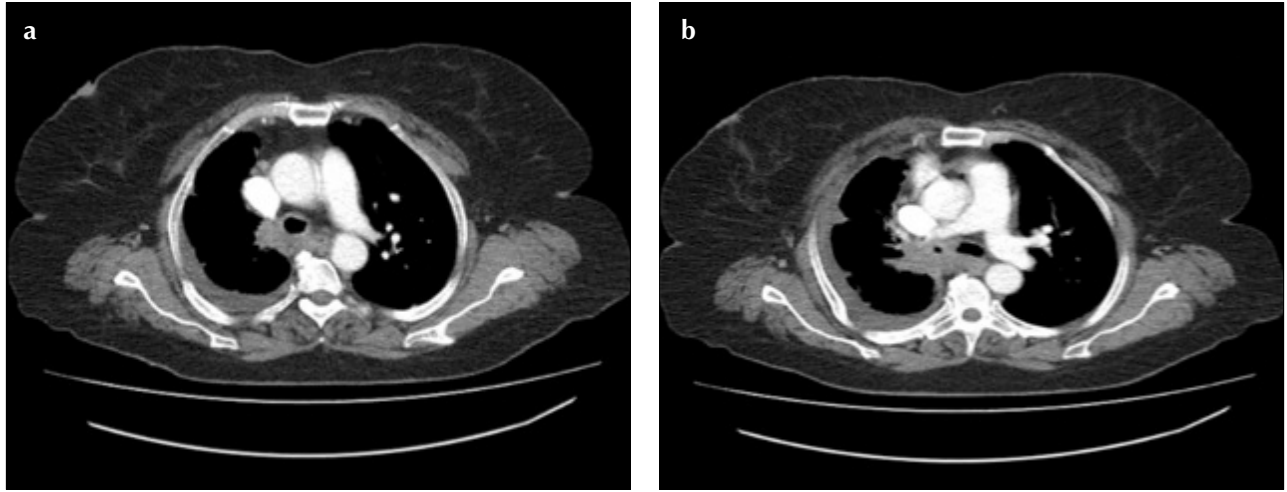


Figure 2. a, b.

Therefore, airway obstruction is clinically detected. Breathlessness, coughing, wheezing are the most common symptoms and patients are mistakenly diagnosed with asthma or recurrent pneumonia. We presented the case because she was followed as asthma for 3 years, it was rare, and rarely seen in the right main bronchial localization, and caused pneumonia.

In 1859, Billroth first described cilindroma, but nowadays the term “adenoid cystic carcinoma” is used. Mostly seen at fifty years, seen equally in both gender

Keywords: Adenoid cystic carcinoma, lung, treatment

[Abstract:0379] EPS-240 [Accepted: E-Poster] [Thoracic Surgery]

Tracheal Diverticulum as a Cause of Recurrent Pneumonia_

Sinem Nedime Sökücü¹, Cengiz Özdemir¹, Ali Cevat Kutluk², Buğra Celal Sezen², Özlem Kahya¹, Salih Bilen², Celalettin Kocatürk²

¹Department of Chest Diseases, Yedikule Chest Diseases and Chest Surgery Training and Research Hospital, İstanbul, Turkey

²Department of Chest Surgery, Yedikule Chest Diseases and Chest Surgery Training and Research Hospital, İstanbul, Turkey

Tracheal diverticulum is an air cyst that develops with a single or multiple invaginations of the tracheal wall to the paratracheal region. Although it is a rarely reported condition, it is encountered at the rate of 1% in autopsies. It generally displays no symptoms. Its diagnosis is often incidentally established during radiological imaging such as computed tomography performed for another reason. A 50-year-old male patient consulted to our outpatient clinic due to the complaints of cough and purulent sputum. In his anamnesis, he had no other comorbid disease. He had a history of 30 packs/year smoking and a history of nonspecific antibiotic use due to the diagnosis of pneumonia for four times in the last one year (Figure 1). In the thoracic computed tomography, bilateral apical paraseptal emphysema areas and a 14x10 tracheal diverticulum in the right paratracheal region were observed (Figure 2). In the bronchoscopy that was performed due to the suspicion of diverticulum, a fistula opening was observed on the posterior wall after the 5th cartilage ring at the entry from the vocal cords (Figure 3).

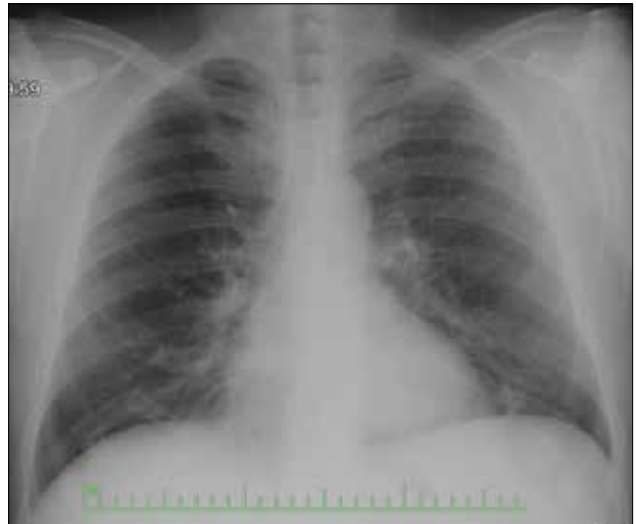

Figure 1. PA chest radiography of the patient

Besides that, the right and left bronchus system was open and normal. The patient whose tracheal diverticulum was bronchoscopically verified was referred to the department of chest surgery for operation with the decision of patient surgery council. He was performed collar incision under general anesthesia and tracheal diverticulum was palpated in the posterolateral region at the level of the 5th cartilage after vocal cords. Then, tracheal diverticulum was excised. The procedure was ended without any complication. The patient was followed-up without any symptoms. Tracheal diverticulum can be congenital or acquired. In congenital tracheal diverticulum, which is generally seen in men as in our case, there is a narrow space and it is localized on the right posterior-lateral wall of the trachea at the rate of 98%. The patients with tracheal diverticulum are often asymptomatic. They do not need treatment unless other malformations coexist and frequently recurring tracheo-bronchial infections develop. Our patient was operated with the decision of council due to recurrent infection attacks and he is asymptomatic in his follow-up.

Keywords: Tracheal diverticulum, tracheal surgery, pneumonia

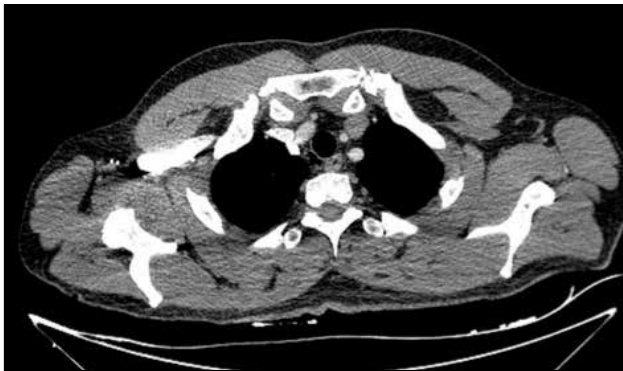


Figure 2. In the image of axial computed tomography, tracheal diverticulum observed in the right posterior-lateral region of the trachea

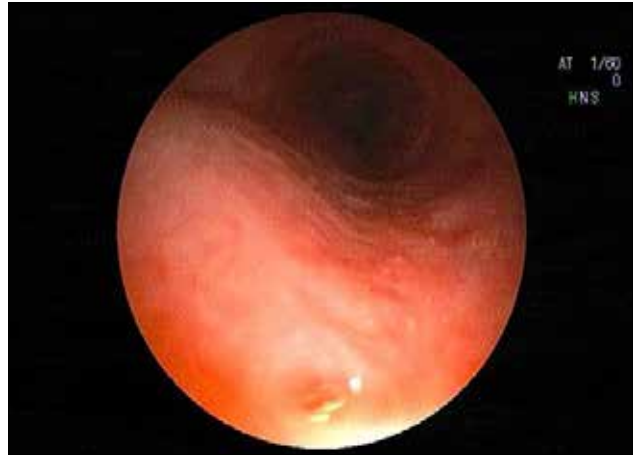

Figure 3. A hole-shaped 2 mm defect on the right posterior side of the tracheal wall

[Abstract:0380] EPS-019 [Accepted: E-Poster] [Clinical Problems - Diffuse Parenchymal Lung Disease]

A Rare Interstitial Lung Disease: Pulmonary Lymphangiomyomatosis

Hakan Keskin, Makbule Ergin, Sermin Tayfun, Abdullah Erdoğan

Department of Chest Diseases, Akdeniz University School of Medicine, Antalya, Turkey

Introduction: Lymphangiomyomatosis (LAM) is a rarely seen, low-degree neoplasia that is characterized by proliferation of alveolar smooth muscle cells and cystic degradation of the lung parenchyma. While pulmonary symptoms of LAM include progressive dyspnea, recurrent pneumothorax, and chylothorax-like effusions, its extrapulmonary findings include renal angiomyolipoma. LAM emerges sporadically or it is associated with tuberous sclerosis complex.

Case Presentation: A 26-year-old female patient was inserted chest tube due to pneumothorax in an external center about one month ago. In the thoracic computed tomography of the patient, cystic formations with thick walls were observed in both lungs (Figure 1) and tuberous sclerosis was scanned with the prediagnosis of LAM. In the lower and upper abdominal tomography, no significant finding, except focal cortical thinning in the right kidney, was detected. Wedge resection was performed for tissue diagnosis. The result of pathology was reported as LAM, which was consistent with the prediagnosis. The patient, who developed no postoperative complication, was directed to the departments of chest diseases and medical oncology and then discharged. At the end of the postoperative 1st month, the patient has not begun medication treatment.

Discussion: LAM is included in the family of "perivascular epithelioid cell tumors", which typically coexpresses myogenic and melanocytic markers, consists of histologically and immunohistochemically distinctive perivascular epithelioid cells, and is a heterogeneous mesenchymal tumor group. The patients are women in reproductive age group. The first reason for applying to the hospital is generally dyspnea. Dyspnea can be associated with cystic formations in the lung parenchyma, pneumothorax, or

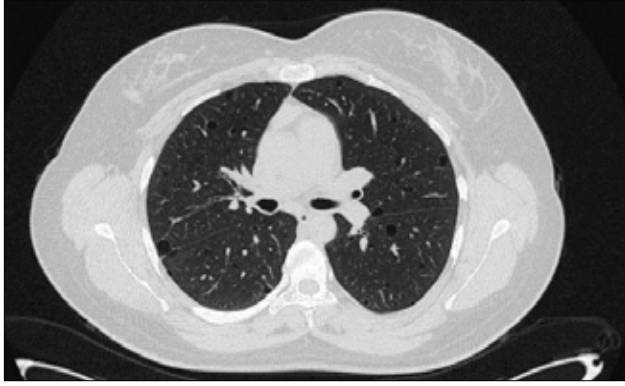


Figure 1. Multiple cystic formations in both lungs

chylothorax. Radiological findings are very important in the diagnosis of LAM. The most common findings observed in thoracic computed tomography include the presence of multiple thin-walled cysts. Other abnormalities are lymphadenopathy, pleural effusion, pneumothorax, ground-glass opacities, and pericardial effusion. It has been demonstrated in multicentered clinical studies that sirolimus and everolimus provided improvement in the respiratory function tests of LAM patients and they stabilize the results. In addition, sirolimus is recommended for patients with findings such as renal angiolipoma and chylothorax-like effusions. Despite the use of sirolimus, some LAM patients can need lung transplantation (LT) in association with progressive pulmonary dysfunction. LT significantly increases chance of survival and quality of life. Although the time of taking LAM patients to a transplantation program is

not exactly known, severe dysfunction (FEV_1 (forced expiratory volume in the first second) lower than 30% of expected) and/or hypoxemia at rest are reported as indications for transplantation by some authors. Only 1% of patients undergoing LT are those diagnosed with LAM. The main reasons for this include that the disease is rarely seen and its progression can be stopped by medication therapy. In patients undergoing LT due to LAM, the rate of survival is similar to those with other LT indications.

Conclusion: If cystic structures are detected in both parenchymas of young women applying with pneumothorax or chylothorax in the thoracic computed tomography, the diagnosis of lymphangioleiomyomatosis should be remembered. The diagnosis should be confirmed as soon as possible and medical treatment should be initiated.

Keywords: Interstitial, lymphangioleiomyomatosis, pneumothorax, pulmonary

[Abstract:0382] EPS-253 [Accepted: E-Poster] [Thoracic Surgery]

Recurrent Desmoid Tumor with Supraclavicular Localization

Fahmin Amirov, Eren Erdoğan, Melike Ülker, Berk Çimenoglu, Berker Özkan, Murat Kara, Alper Toker

Department of Chest Surgery, İstanbul University İstanbul School of Medicine, İstanbul, Turkey

Desmoid tumors are rarely seen tumors with locally aggressive course, which arise from connective tissue fascia and musculoaponeurotic fibrous tissues. While they often occur in the abdominal wall, they can rarely be encountered in the chest wall. These tumors are defined as rapidly growing benign lesions which make invasion to the surrounding tissues but no metastasis. The most effective surgical technique is radical surgery and local recurrence rate can be decreased with postoperative adjuvant therapy. In this study, we presented a resection performed to a case of desmoid tumor located in the anterior wall of the right chest, invading brachial plexus and right innominate vein, and recurring locally 15 months after primary operation. Moreover, the diagnosis and treatment stages of chest wall reconstruction were presented with literature.

Keywords: Desmoid tumor, primary chest wall tumor, chest wall resection, chest wall reconstruction

[Abstract:0385] PS-265 [Accepted: Poster Presentation] [Experimental Investigations]

Effect of Rutin on Cytarabine-Induced Pulmonary Edema and Oxidative Stress in Rats

Bahadır Süleyman¹, Renad Mammadov¹, Edhem Ünver², Fatih Özçiçek³, Ferda Keskin Çimen⁴, Mehmet Soytürk⁵, Nezahat Kurt⁶, Halis Süleyman¹

¹Department of Pharmacology, Erzincan University School of Medicine, Erzincan, Turkey

²Department of Pulmonology, Erzincan University School of Medicine, Erzincan, Turkey

³Department of Internal Medicine, Erzincan University School of Medicine, Erzincan, Turkey

⁴Department of Phathology, Erzincan University Faculty of Medicine, Erzincan, Turkey

⁵Department of Radiology, Erzincan University Faculty of Medicine, Erzincan, Turkey

⁶Department of Biochemistry, Atatürk University Faculty of Medicine, Erzurum, Turkey

Objectives: Cytarabine, a pyrimidine nucleoside analog, is one of the most effective drugs in the treatment of adult acute leukemia. However, the fatal pulmonary edema seen during the use of cytarabine causes the treatment to be interrupted. It has been argued that cytarabine pulmonary edema is caused by the increased vascular permeability of alveolar capillaries. Cytokine and free radical formation are considered to be responsible for the increase in cytarabine-induced vascular permeability. It has been reported that rutin suppressed proinflammatory cytokine and oxidant production and prevented endemic edema caused by capillary permeability increase and plasma infiltration into tissues. In the literature, there is no information on the counteracting effects of the rutine against cytarabine-induced pulmonary edema. The aim of the present study was to investigate radiologically, biochemically and histopathologically the effect of rutin on cytarabine-induced pulmonary edema in rats.

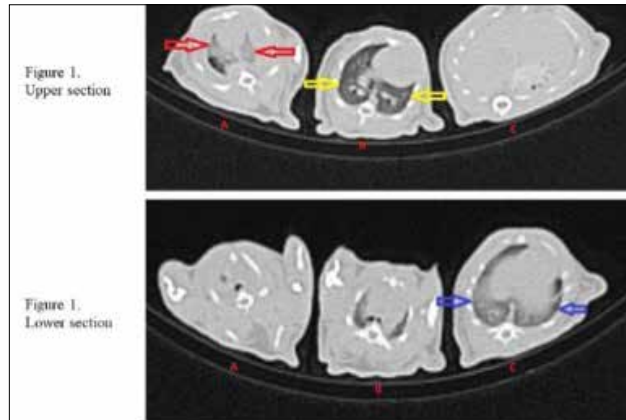


Figure 1. As shown in the upper section of Figure 1a, radiological examination with MDCT revealed diffuse pulmonary edema (Figure 1A) in the lung of the CYT group. However, no edema was seen in both lungs of the RC group treated with Rutin (upper section picture 1B) . At the lower section of Figure 1C, the normal appearance of both lungs of the SG animal group is observed

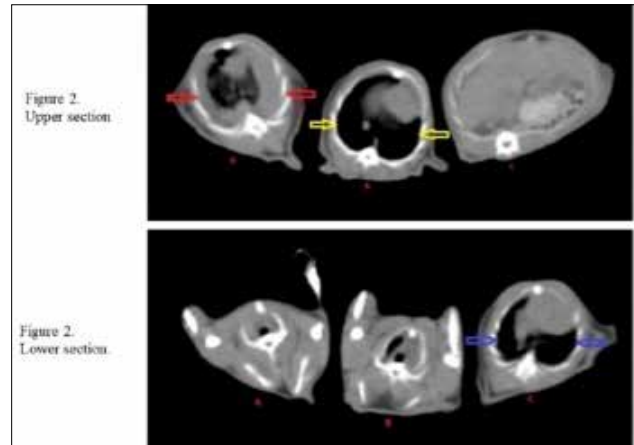


Figure 2. Radiological examination with MDCT shows bilateral pleural effusion in the lung of the rats in the CYT group (upper section, picture 2A) . In the RC group given Rutin (upper section, picture 2B) , both lungs are normal. In the lower section, normal lungs of healthy SG group rats are presented (Figure 2C)

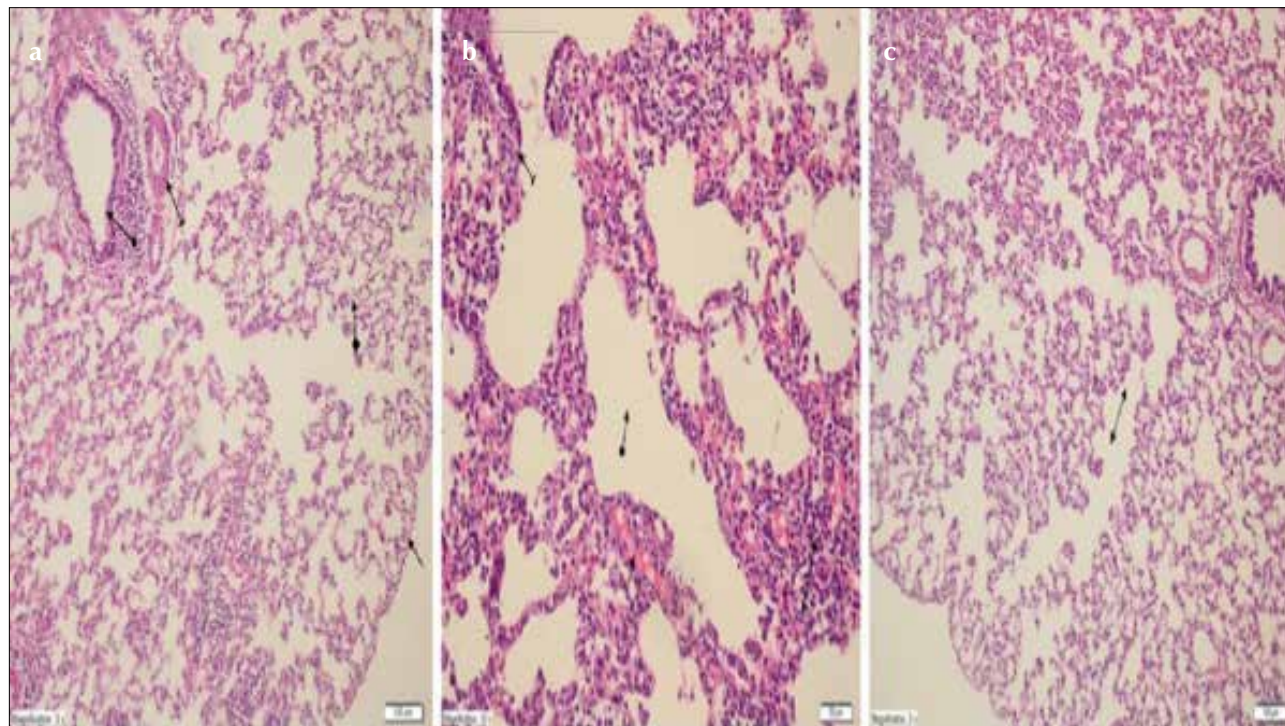


Figure 3. a-c. Figure 3a. Healthy visceral pleura (plain arrow) , alveoli (square arrow) , pulmonary artery (striated arrow) , bronchial (round-end arrow) structures in lung tissue of SG group are displayed (HEX-100) . Figure 3b. CTR group given cytarabine showed diffuse edema (round-end arrow) , dilate congested blood vessel (straight arrow) , diffuse chronic inflammatory cell infiltration (double-sided arrow) and bronchial damage (striated arrow) in the lung tissue (HEX200) . Figure 3c. Except for mild edema (double-sided arrow) , a healthy tissue-like appearance (HEX100) is observed in the pulmonary tissue of the RC group given Rutin

Methods: RC (Rutin+Cytarabine, n=8) groups of rats were administered Rutin by oral route at a dose of 50 mg/kg. CTR (Cytarabine, n=8) and SG (Control, n=8) groups were administered physiological saline (0.9% NaCl) orally in the same volume as a solvent. After one hour from Rutin and 0.9% NaCl administration, intraperitoneal injection of cytarabine 200 mg/kg was applied to the RC and CTR groups. This procedure was repeated once a day for 14 days.

Results: There was lung edema in 50% of the animals taken cytarabine, but not in Rutin group. Biochemical findings: Rutin significantly decreased the amounts of cytarabine-induced MDA, TNF- α , and NF- κ B in the lung tissue; Also, it was a significant inhibitive factor for the reduction of tGSH by nitric oxide. Diffuse edema, dilate congested blood vessels, diffuse chronic inflammatory cell infiltration and bronchial damage were observed in the cytarabine group while only slight edema was observed in the Rutin group.

Conclusion: This suggests that Rutin may be clinically beneficial to minimize the development of cytarabine-associated pulmonary edema.

Keywords: Rutin, cytarabine, pulmonary edema, oxidative stress

[Abstract:0386] EPS-272 [Accepted: E-Poster] [Thoracic Surgery]

One Patient with Six Primary Cancers

Merve Şatır Türk, Aynur Baş, Anıl Gökçe, Anar Süleymanov, Ali Çelik

Department of Chest Surgery, Gazi University School of Medicine, Ankara, Turkey

Introduction: The presence of more than one lung cancer in a patient is a rare condition. The incidence of multiple lung cancers is about 1.6% and this rate varies between 0.5% and 3.9%.

Case Presentation: A 66-year-old female patient consulted due to the complaints of dyspnea and cough. Her thoracic CT revealed mass lesions, the largest of which was about 14 mm in diameter in the left side, with spiculated margins and with suspicion of metastasis in the upper lobes of both lungs. The mass in the left upper lobe posterior region was performed transthoracic needle biopsy. The result of pathology was reported as invasive adenocarcinoma. In PET-CT, pathologically increased FDG involvement was observed in a 1,5 cm hypodense nodule in the left lobe of the thyroid gland (SUVmax: 3,5) ; in lymph nodes, the largest of which was 1 cm in diameter, in the bilateral hilar region (SUVmax: 2,2) ; in solid parenchymal nodule, the widest point of which was about 18 mm, with spiculated margin in the apicoposterior segment of the left lung upper lobe (SUVmax: 3,0) ; in a solid 18 mm nodule with spiculated margin in the mediobasal segment of the right lung lower lobe (SUVmax: 5,6) ; in 2 parenchymal nodular infiltration areas with ground-glass density in the superior segment of the right lung lower lobe, the largest of which was 2 cm in diameter, (SUVmax: 1,1) ; in nodules observed in both lungs, the largest one of which was 13 mm in the superior segment of left lung lower lobe, (SUVmax: 0,9) ; and in the stomach (SUVmax: 5,2) (physiologic??) . In further examinations performed for the thyroid gland and stomach, no pathology was detected. The patient was performed right lung Wedge resection and lymph node dissection on October 2017. Five nodules were removed. The pathological results of the nodules were reported as; 1) invasive adenocarcinoma, papillary dominant pattern, 2) invasive adenocarcinoma, lepidic dominant pattern, 3) microinvasive adenocarcinoma, lepidic dominant pattern, 4) invasive adenocarcinoma, papillary dominant pattern, and 5) in-situ adenocarcinoma. On January 2018, the left lung Wedge resection and mediastinal lymph node dissection were performed. The result of pathology was reported as; 1) in-situ adenocarcinoma, 2) invasive adenocarcinoma, acinar dominant pattern, and 3-4) lung parenchyma not including specific pathology. The patient was discharged without any complication on the postoperative 5th day.

Conclusion: Synchronous primary lung cancer is seen in 0.5% of lung cancer patients. The diagnosis of synchronous multiple primary lung cancer is generally established through chest radiographies and CT. While most of these tumors are incidentally found in bronchoscopy or surgery, some are detected by pathologists during the examination of resected samples. After the establishment of synchronous tumor diagnosis, the approach to patient and surgery that will be performed vary depending on the localization of tumor in the same or contralateral lung and respiratory reserve of patient. Criteria related to synchronous cancers were defined by Martini and Melamed. According to these criteria, the first and main criterion in the diagnosis of synchronous lung cancer is the detection of cancers at the same time. The detected cancers must be physically separate from each other and histologically different types. In cancers of the same histological type, they must be located in different segments or lobes or lung, one must be in situ carcinoma or no lymphatic spread must exist in both, and there must be no extrapulmonary metastases.

Keywords: Lung cancer, synchronous, multiple

[Abstract:0387] EPS-187 [Accepted: E-Poster] [Thoracic Surgery]

A Case of Pulmonary Tumorlet

Suzan Temiz, Gönül Gülmez, Oğuzhan Turan, Ömer Önal, Ömer Faruk Demir

Department of Chest Diseases, Erciyes University School of Medicine, Kayseri, Turkey

Introduction: Neuroendocrine cell hyperplasia mostly occurs by not penetrating basal membrane in the airway mucosa. If cell proliferation passes basal membrane and converts into micronodular structure, the lesions are called tumorlet or if the lesion becomes larger than 0,5 cm, it is called carcinoid tumor. This neuroendocrine cell hyperplasia and tumorlets are frequently detected around scar tissues and bronchiectasis and emphysematose regions in the lung during the microscopic evaluation of surgical specimens or autopsy materials (3) . In this study, we aimed to present a case who was operated due to fungal infection and who had tumorlet accompanying to fungal hyphae and bronchiectasis in the histopathological evaluation of surgical specimen.

Case Presentation: A 60-year-old female patient was referred to our department by an external center due to hemoptysis and lesion in the right lung. The thoracic tomography report of the patient demonstrated a 6x3 cm mass lesion in the upper lobe of the right lung and bronchiectasis appearances in its neighborhood. In FOB, the entry of the right upper lobe was edematous and narrowed by external compression. And there were petechiae in the tissue. In the samples that were taken, galactomannan was positive. Biopsy was reported as bronchial biopsy. With the recommendation of the department of infectious diseases, antimycotic therapy was increased to 6 weeks. In PET-CT, the lesion was evaluated as primary malignant process and no distant organ metastasis was observed (Figure 1a-1b) . With the re-order of biopsy by the department of infectious diseases for treatment plan, the patient was performed transthoracic biopsy and the diagnosis was reported as 'chronic inflammatory event and interstitial thickening'. Surgery was planned for the patient. Wedge resection was applied in the upper lobe of the right lung. The result of intraoperative frozen section was reported as 'no fungal infection and epithelial tumor was observed, there is intense lymphoplasmic infiltration, and reactive neoplastic differentiation will be performed in paraffin'. Her final pathology was reported as a tumorlet with lesion diameter of 500 micron, neuroendocrine cell hyperplasia, bronchiectasis and secondary changes (fibrosis, lymphoid infiltration, and organizing pneumonia) , and fungal hyphae. No hemoptysis was observed in her follow-ups and she was directed to the departments of chest diseases and oncology. The patient was not given an additional treatment and no abnormality was found in her CT (Figure 2a-2b) .

Discussion: Pulmonary neuroendocrine cell hyperplasia is a rare clinical pathological condition. Tumorlet and peripheral carcinoid tumor is the lesion that rarely displays metastasis and lymphoid invasion. In the histological classification of lung tumors by the World Health Organization, tumorlets are also classified as preinvasive lesions. Therefore, even if primary cause of pulmonary tumorlet is benign, these cases should be followed up with regard to lymphatic metastasis as in carcinoid cases. The coexistence of bronchiectasis and tumorlet, which was also found in our case, bronchiectases form a basis for

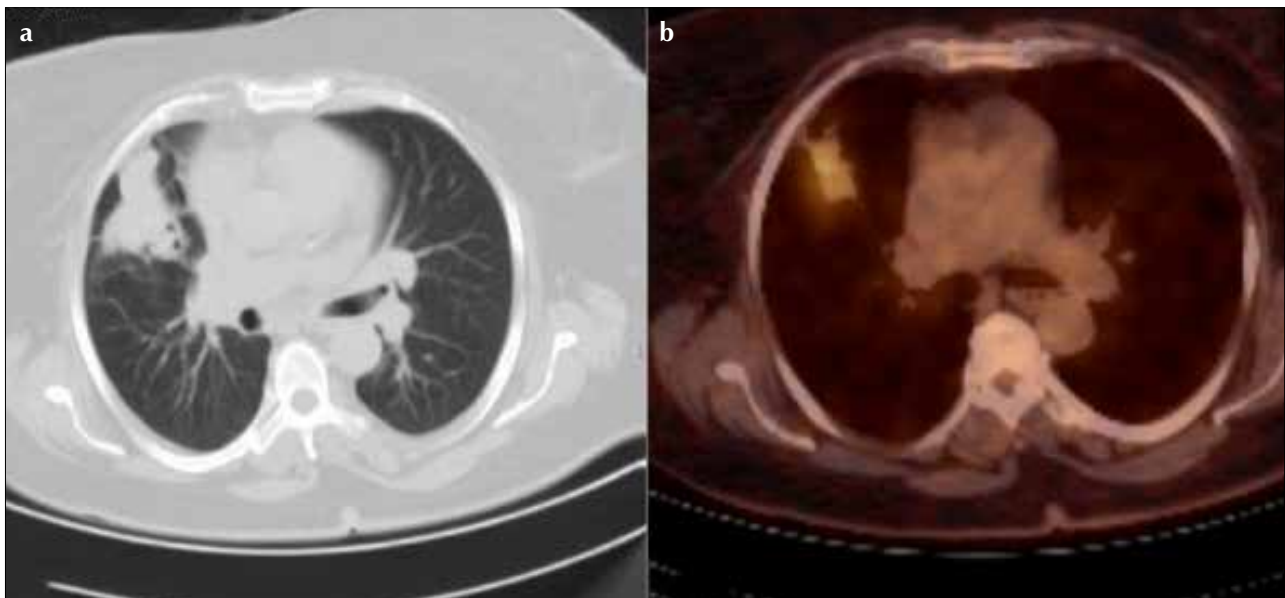


Figure 1. a, b. In CT and PET-CT of the patient, a 57x29 mm hypermetabolic mass lesion is observed in the anterior segment of the right lung upper lobe and with contact to anterolateral pleural surface

pre-malignant lesions in addition to known complications such as hemoptysis and recurrent infections. In bronchiectasis cases that do not give response to medical treatment, it should be taken into consideration that early surgical treatment prevents the development of recurrent symptoms and helps to avoid lesions with malignancy potential that can occur in future.

Keywords: Bronchiectasis, neuroendocrine cell hyperplasia, pulmonary tumorlet

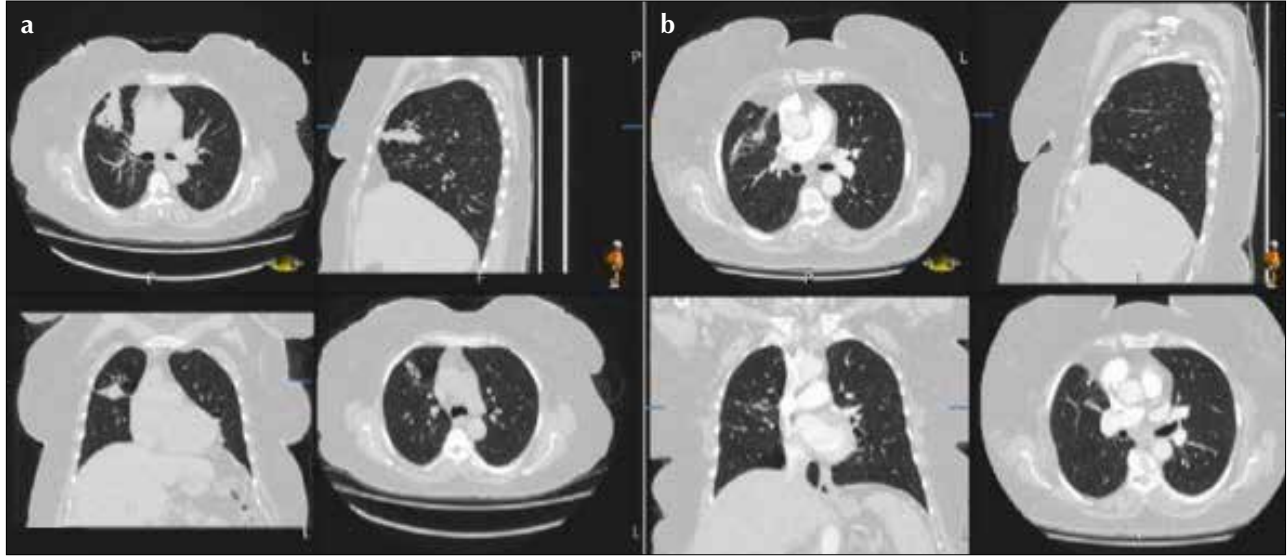


Figure 2. a, b. A 6x3 cm mass lesion is viewed in the upper lobe of the right lung after completing 6 weeks of anti-mycolytic therapy; 2b: Fibrotic changes secondary to operation are viewed in tomography performed one year after the operation

[Abstract:0388] PS-184 [Accepted:Poster Presentation] [Pediatric Pulmonary Diseases]

Pulmonary Involvement in Patient with Infantile Crohn's Disease on Infliximab Therapy

Lina Mohammed Al Shadfan¹, Hakan Öztürk², Neslihan Ekşi Bozbulut², Özgür Ekinci³, Buket Dalgıç², Ödül Gürkan², Nurcan Ünver⁴, Hakan Yazan¹, Erkan Çakır¹

¹Department of Pediatric Pulmonology, Bezmialem Vakif University School of Medicine, Istanbul, Turkey

²Department of Pediatric Gastroenterology, Gazi University School of Medicine, Ankara, Turkey

³Department of Pathology, Gazi University School of Medicine, Ankara, Turkey

⁴Department of Pathology, Bezmialem Vakif University School of Medicine, Istanbul, Turkey

A 2 year old boy who was diagnosed to have infantile crohns disease after he was presented with chronic bloody mucoid diarrhea that started at age of 1 year.He was on regular follow up at gastroenterology departrment. Endoscopy showed pan-gastritis, bulbitis and multiple white exudating linear ulcers involving the duedonum. Colonoscoy revealed diffuse inflammation,crypts and crypt abscess formation and normal terminal ileum. Biopsies from the duedenal and colonic mucusa showed multiple granuloma and diffuse inflammation,cryptitis,and abscess formation,respectively.

He was treated with several drugs such as daltacortril, salofalk, azatioprin till the initiation of infliximab after which a significant improvement noticed. He presented with histry of chronic wet cough and shortness of breath for 3 months duration for which he was admitted to the hospital for 3 times. He diagnosed to have pneumina and treated with antibiotics but with mild improvement.There is positive family history of eczema and allergic rhinitis.On physical examination he was distressed with his weight and hieght below 3rd percentiles. Chest finding include bilateral fine crackles, inspiratory wheezes on auscultation, the reminder of systemic examination was unremarkable. His initial laboratory investigation showed normochromic normocytic anemia, leukocytosis with neutrophila and elevated platelet count, elevated CRP and ESR and elevated IgE.Chest xray showed bilateral diffuse lung opacities and infiltrates more on the right side (Figure 1) . Chest CT scan with contrast showed pneumonic consolidations, atherosclerotic nodules, ground glass densities and peribronchial thickening (diffuse bronchopneumonia) in all lobes and segments (figure 1) . The rest of work up including liver function and enzymes,kidney functions and electrolytes, urin analysis and culture,spot urin for calcium,immunoglobulins level and WBC subgroups complements,ANCA, anti -ds DNA,ANA, RF,aspergillus specific antigen, QuantiFERON, nasopharyngeal culture, blood culture

were negative. Echocardiography showed mild pulmonary hypertension secondary to lung disease. Bronchoscopy that was normal. Lung biopsy revealed non caseating granuloma. Providing all the clinical, laboratory, radiological and histopathological data, the patient was diagnosed to have extraintestinal pulmonary involvement of his infantile crohns disease. He was treated with oral prednisone therapy and after 4 month of treatment his clinical, physical and radiological findings were significantly improved.

This case was presented because of the rarity of extra-intestinal pulmonaty manifestation of IBD.

Keywords: Infantile crohn's, Pulmonary involmnet, infliximab

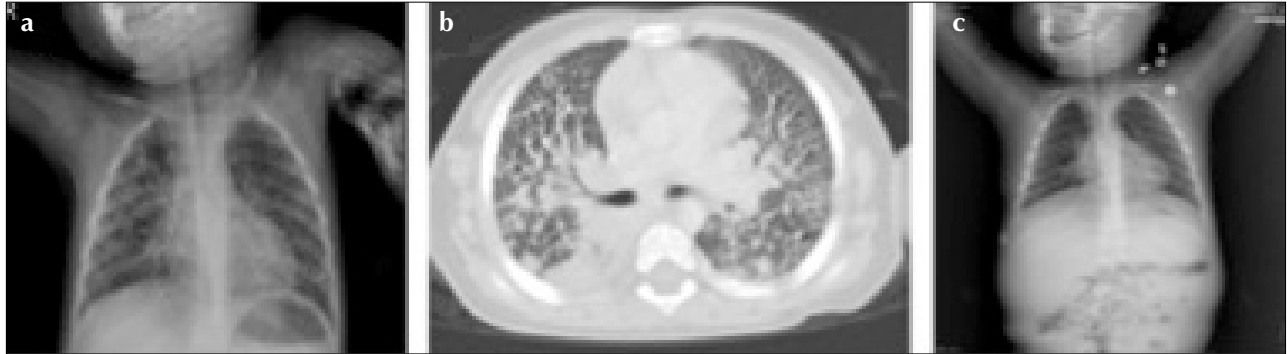


Figure 1. a-c. A,B chest xray and thorax CT showing diffuse nodular infiltration before starting treatment. C improved finding on chest xray after treatment

[Abstract:0391] EPS-292 [Accepted: E-Poster] [Tobacco Control]

Look with This Aspect Also To Smoking Cessation Polyclinic

Şerif Kurtuluş¹, Remziye Can²

¹Department of Chest Disease, Ceylanpınar Government Hospital, Şanlıurfa, Turkey

²Pınar Vocational and Technical Anatolian High School, Public Health Nursing, Şanlıurfa, Turkey

Objectives: Smoking cessation polyclinic (SCP) are services tobacco fighting. Medical treatment and behavioral therapies. The aim of this study is to evaluate factors affecting smoking cessation in patients referred to the SCP.

Table 1. Distribution by Month SCP first application and control patients'

(N:1861)	Number of patients with first application n(%)*	Number of Patients Controlled n(%)*	Number of Patients Total n(%)**
January	96 (%73.2)	35 (%26.8)	131 (%7.0)
February	104 (%80.6)	25 (%19.4)	129 (%6.9)
March	141 (%83.9)	27 (%16.1)	168 (%9.0)
April	118(%88.7)	15(%11.3)	133(%7.2)
May	140 (%96.5)	5 (%3.5)	145 (%7.7)
June	137 (%97.1)	4 (%2.9)	141 (%7.5)
July	32 (%96)	2 (%4.0)	34 (%1.8)
August	253 (%99.6)	1 (%0.4)	254 (%13.7)
September	127 (%100.0)	0 (%0.0)	127 (%6.8)
October	137 (%97.1)	4 (%2.9)	141 (%7.5)
November	58(%93.5)	4 (%6.5)	62 (%3.4)
December	364 (%91.9)	32 (%8.1)	396 (%21.3)
Total	1705(%91.7)	156(%8.3)	1861(%100.0)
n(%)* Percentage has been by line total		n(%)** Percentage has been by column total	

Methods: This study which designed retrospective registry scan type was performed between the dates January -December 2017. The extent of the study, was created the patients who applied to SCP in district state hospital in Şanlıurfa. The reports of the patients who was applied to SCP were evaluated monthly quarterly and annually. The obtained data were calculated as percentage and frequency.

Results: Totally 1861 patients registered to 1705 of them were initial application, 156 of them were for control. When the first application rates were compared according to the month, it was determined the highest with 21.2% in December (Table 1) . It was found that 80.1% of the patients received behavioral therapy and 19.9% received pharmacological treatment (Table 2) . In this study, the total smoking cessation rate of was 20.7%. %27.4 of patients who applied SCP and received pharmacological treatment quited smoking was found, 27.4% of them continued smoking, %45.2 of them isn't known whether they quited or not (Table 3) . 18.9% of patients who applied SCP and received behavioral therapy quited smoking was found, 45.2% of them continued to smoke and 35.9 % of them isn't known whether they quited or not (Table 4) .

Conclusion: This study, the one of every five patient who applied to SBP was quited smoking. The high being pharmacological treatment in November, the Ministry of Health complaining that smoking cessation medications are sent out and being given free of charge, depends on this, can be explained only pharmacological treatment requirements, rejected behavioral treatments by the patients. The rate of control visits to the patient's was higher than the other months, during the months

Table 2. Distribution by month tretment method to SCP applied patients'

(N:1861)	<u>Number of Patients Pharmacologically Treated</u> n(%)*	<u>Number of Patients Behavioral Therapy</u> n(%)*	<u>Number of Patients Total</u> n(%)**
<u>January</u>	131 (%7.0)	131 (%7.0)	131 (%7.0)
<u>February</u>	129 (%6.9)	129 (%6.9)	129 (%6.9)
<u>March</u>	168 (%9.0)	168 (%9.0)	168 (%9.0)
<u>April</u>	133(%7.2)	133(%7.2)	133(%7.2)
<u>May</u>	145 (%7.7)	145 (%7.7)	145 (%7.7)
<u>June</u>	141 (%7.5)	141 (%7.5)	141 (%7.5)
<u>July</u>	34 (%1.8)	34 (%1.8)	34 (%1.8)
<u>August</u>	254 (%13.7)	254 (%13.7)	254 (%13.7)
<u>September</u>	127 (%6.8)	127 (%6.8)	127 (%6.8)
<u>October</u>	141 (%7.5)	141 (%7.5)	141 (%7.5)
<u>November</u>	62 (%3.4)	62 (%3.4)	62 (%3.4)
<u>December</u>	396 (%21.3)	396 (%21.3)	396 (%21.3)
Total	372(19.9)	1489(80.1)	1861(100.0)
n(%)* Percentage has been by line total n(%)** Percentage has been by column total			

Table 3. Smoking status in 3 monthly of pharmacological treatment patient'

	<u>Quit Smoking</u> n(%)*	<u>Continued To Smoke</u> n(%)*	<u>Unknown</u> n(%)*	<u>Total</u> n(%)**
<u>January-February-March</u>	12(%75.0)	4(%25.0)	0(%0.0)	16(%4.4)
<u>April-May- June</u>	25(%34.2)	10(%13.6)	38(%52.2)	73(%19.6)
<u>July--August-September</u>	20(%20.8)	46(%48.0)	30(%31.2)	96(%25.8)
<u>October-November-December</u>	45 (%24.0)	42(%22.5)	100(%53.5)	187(%50.2)
Total	102 (%27.4)	102(%27.4)	168(%45.2)	372(% 100.0)
n (%)* Percentage has been by line total n (%)** Percentage has been by column total				

when smoking cessation medicines were given free of charge. It's seen that the rates of control visits of the patients are higher than the other months when smoking cessation drugs are free. Consequently; The application of pharmacological treatment together with behavioral therapy is increasing the success of treatment. The health ministry's free drug distribution policy can be caused of resistance, SBP can directly affect, the cause of illness and resistance to behavioral therapies We recommend; that the drugs used for smoking cessation treatments should be provided from the pharmacies by submitting reports such as drugs used in the treatment of other chronic diseases.

Keywords: Behavioral Therapy, health policy, pharmacological treatment, smoking cessation, smoking cessation polyclinic

Table 4. Smoking status in 3-monthly of behavioral therapy patient'

	Quit Smoking n(%)*	Continued To Smoking n(%)*	Unknown n(%)*	Total n(%)**
January-February-March	88(%21.4)	274(%66.5)	50(%12.1)	412(%27.7)
April-May- June	87(%25.1)	80(%23.1)	179(%51.8)	346(%23.3)
July–August-September	32(%9.9)	167(%52.5)	120(%37.6)	319(%21.4)
October-November-December	75(%18.2)	151(%36.6)	186(%45.2)	412(%27.6)
Total	282(%18.9)	672(%45.2)	535(%35.9)	1489(%100.0)
n (%)	*Percentage has been by line total		n (%)** Percentage has been by column total	

[Abstract:0394] PS-274 [Accepted:Poster Presentation] [Sleep-related Disorders]

A New Approach for the Diagnosis of OSAS with Body Analysis; Artificial Intelligence Network

Mustafa Saygın¹, Önder Öztürk², Fatih Ahmet Şenel³, Rahime Rana Saygın⁴

¹Department of Physiology, Süleyman Demirel University, Isparta, Turkey

²Department of Chest Diseases, Süleyman Demirel University, Isparta, Turkey

³Division of Computer Engineering, Süleyman Demirel University, Isparta, Turkey

⁴Diet Polyclinic, Isparta City Hospital, Isparta, Turkey

Objectives: In this study, it was aimed to predict the severity of obstructive sleep apnea syndrome (OSAS) according to apnea-hypopnea index (AHI) by body analysis (TANITA) data.

Methods: Twenty-three parameters of body analysis were used for each patient who had been diagnosed as OSAS and admitted to diet polyclinic. Data mining modeling has been done by running different body analysis data selected algorithms. As a result, the most successful result was obtained by Correalation – based Feature Selection (CFS) . According to the CFS method, four features resulted successfully in the classification process in this study. Selected features included of model were Weight, Metabolism Age, Extracellular Fluid and Waist circumference. The success of the results was compared by using six classification methods (Naive Bayes Classifier Algorithm, Support Vector Machine, K* Algorithm, Reptree Algorithm, ZeroR Algorithm, Artificial Neural Network) in this study.

Results: The best results obtained from each classification method. The estimated ratio of AHI for all groups was 65% for ANN model. The classification was done according to AHI by using the models; mild OSAS (153 patient) , moderate OSAS (43 patient) , severe OSAS (43 patient) , and powerfull estimate are shown SVM %100, ZeroR %100, ANN %100 90.85 for mild OSAS. Results are shown in the table 1 and 2.

Table 1. Models

Model Name	Correct classification	Wrong classification	Accuracy Percentage	MAE	RMSE
Naive Bayes	153	86	64,0167	0,32	0,4094
SVM	153	86	64,0167	0,3388	0,4162
KStar	148	91	60,251	0,3171	0,4436
Reptree	153	86	64,0167	0,3388	0,42
ZeroR	153	86	64,0167	0,3517	0,4186
ANN	157	82	65,6904	0,3048	0,4102

MAE: mean absolute error. RMSE: root mean square error

Table 2. Models for according to OSA group

Model Name	Correct classification	Wrong classification	Accuracy Percentage	1	2	3	OMH	OKHK
Naive Bayes	153	86	64,02	88,89	0,00	39,53	0,32	0,41
SVM	153	86	64,02	100,00	0,00	0,00	0,34	0,44
KStar	148	91	60,25	77,78	23,26	34,88	0,31	0,44
Reptree	153	86	64,02	96,08	4,65	9,30	0,34	0,42
ZeroR	153	86	64,02	100,00	0,00	0,00	0,35	0,42
ANN	157	82	65,69	90,85	20,93	20,93	0,30	0,41

MAE: mean absolute error. RMSE: root mean square error. 1: Mild OSAS; 2: Moderate OSAS; 3: Severe OSAS.

Conclusion: When the results are examined, it is predicted that the AHI estimation can be performed by using body composition data with the classification methods. The best classification method was obtained with Artificial Intelligence Networks, ZeroR and SVM models. We think that new studies are needed with larger populations in order to obtain better estimate percentages.

Keywords: Body analysis, OSAS, artificial intelligence networks

[Abstract:0395] SS-045 [Accepted: Oral Presentation] [Sleep-related Disorders]

The Software Development for EPWORTH Used as Pre-scan Test in OSAS

Mustafa Saygın¹, Önder Öztürk², Fatih Ahmet Şenel³

¹Department of Physiology, Süleyman Demirel University, Isparta, Turkey

²Department of Chest Diseases, Süleyman Demirel University, Isparta, Turkey

³Division of Computer Engineering, Süleyman Demirel University, Isparta, Turkey

Objectives: It was aimed to develop a software program which was Windows based, easy application, taking no time, quickly evaluation and archived for Epworth Sleepiness Scale (ESS) used to measure the sleepiness in sleep laboratories.

Methods: The ESS was transformed to digital software by using the Microsoft Visual Studio program with the C# programming language. At first, the program starts with a welcome screen for entering patient information and then another screen which had questions (2 pages) is displayed. When all the questions are answered, patient information and test results are recorded in detail to the database. As the file number or ID number is used at the patient entry, the patient's test results can be examined retrospectively and the output in excel or pdf format can be retrieved. The information about how many percent of the patients registered to the database and had sleeplessness is shown graphically on the main entry screen (Figures 1-6) .

EPWORTH UYKULULUK ÖLÇEĞİ

Tc Kimlik Dosya No: 111

Ad: Uyku

Soyad: Laboratuvarı

Tarih: 29.1.2018

BAŞLA

Figure 1. Software

Results: The ESS test routinely used as a pre-test in sleep laboratories was transformed into a fast-rated program with a simple and clear interface. As the patient's data were archived in bulk, the patients were able to make their own assessments. It was seen that the software provided error-free, fast and reliable results because it did not allow the test to be completed without answering each question when compared with the manual evaluation.

Conclusion: The use of this software will facilitate the gathering and storage of data and follow-up of patients in sleep laboratories. If it is thought that most sleeping patients are not aware of their illness, we think that such software widely disseminated in the digital age will increase social awareness against sleeping diseases.

Keywords: Epworth sleepiness scale, software, C#

EPWORTH UYKULULUK ÖLÇEĞİ

Filtrele

TC/Dosya No: Ad: Soyad:

Kayıt No	TC/Dosya No	Ad	Soyad	Tarih	1	2	3	4	5	6	7	8	Durumu	Sđ
1	111	Uyku	Laboratuvarı	29.1.2018	2	1	2	3	2	1	2	3	Hasta	Sđ

Figure 2. Software

EPWORTH UYKULULUK ÖLÇEĞİ

SORU: Aşağıdaki durumlarda hangi sıklıkla uyuklama eğilimindediniz?
(Lütfen kendinizi yorgun hissettiğiniz zamanları değil uyuklama eğiliminde olduğunuz zamanları işaretleyiniz.)
Bu test son zamanlardaki durumunuzu yansıtmak üzere planlanmıştır. Aşağıdaki bazı durumlarla son zamanlarda karşılaşmadıysanız bile son karşılaştığımız zamanlarda nasıl olduğunuzu hatırlamaya çalışınız.

0-Hiçbir zaman uyuklamam 1-Nadiren t

5) Öğleden sonra uzanınca uyuklarmısınız? 3

6) Birisi ile oturup konuşurken uyuklarmısınız? 3

7) Alkol alınmış, öğle yemeğinden sonra sessiz ortamda otururken uyuklarmısınız? 0 1 2 3

8) Trafik birkaç dakika durduğunda, kırmızı ışıkta, arabada beklerken uyuklarmısınız? 0 1 2 3

DİKKAT

Toplam Skor:16
Uykululuk haliniz mevcuttur. En yakın uyku bozuklukları merkezine başvurunuz.

Tamam

Figure 3. Software

EPWORTH UYKULULUK ÖLÇEĞİ

SORU: Aşağıdaki durumlarda hangi sıklıkla uyuklama eğilimindedesiniz?

(Lütfen kendinizi yorgun hissettiğiniz zamanları değil uyuklama eğiliminde olduğunuz zamanları işaretleyiniz.)

Bu test son zamanlardaki durumunuzu yansıtmak üzere planlanmıştır. Aşağıdaki bazı durumlarla son zamanlarda karşılaşmadıysanız bile son karşılaştığımız zamanlarda nasıl olduğunuzu hatırlamaya çalışınız.

0-Hiçbir zaman uyuklamam 1-Nadiren uyuklarım 2-Sıklıkla uyuklarım 3-Her zaman uyuklarım

5) Öğleden sonra uzanınca uyuklarmısınız? 0 1 2 3

6) Birisi ile oturup konuşurken uyuklarmısınız? 0 1 2 3

7) Alkol almamış, öğle yemeğinden sonra sessiz ortamda otururken uyuklarmısınız? 0 1 2 3

8) Trafik birkaç dakika durduğunda, kırmızı ışıkta, arabada beklerken uyuklarmısınız? 0 1 2 3

Figure 4. Software

EPWORTH UYKULULUK ÖLÇEĞİ

SORU: Aşağıdaki durumlarda hangi sıklıkla uyuklama eğilimindedesiniz?

(Lütfen kendinizi yorgun hissettiğiniz zamanları değil uyuklama eğiliminde olduğunuz zamanları işaretleyiniz.)

Bu test son zamanlardaki durumunuzu yansıtmak üzere planlanmıştır. Aşağıdaki bazı durumlarla son zamanlarda karşılaşmadıysanız bile son karşılaştığımız zamanlarda nasıl olduğunuzu hatırlamaya çalışınız.

0-Hiçbir zaman uyuklamam 1-Nadiren uyuklarım 2-Sıklıkla uyuklarım 3-Her zaman uyuklarım

1) Oturur durumda gazete ve kitap okurken uyuklarmısınız? 0 1 2 3

2) Televizyon seyredirken uyuklarmısınız? 0 1 2 3

3) Pasif olarak toplum içinde otururken, sinemada yada tiyatrodada uyuklarmısınız? 0 1 2 3

4) Ara vermeden en az 1 saatlik araba yolculuğunda uyuklarmısınız? 0 1 2 3

Figure 5. Software




Figure 6. Epworth Sleepiness Scales

[Abstract:0399] SS-105 [Accepted:Oral Presentation] [Clinical Problems - Diffuse Parenchymal Lung Disease]

Pulmonary Alveolar Proteinosis: Experience in a Tertiary Care Center

Nazan Bayram

Department of Pulmonary Diseases, Gaziantep University School of Medicine, Gaziantep, Turkey

Objectives: Pulmonary alveolar proteinosis (PAP) is a rare syndrome of surfactant deposition in alveoli as well as alveolar macrophages. Although the etiology is not clearly defined, it is attributed to a structural defect in surfactant molecule or deficiency in the clearance of surfactant. PAP can be autoimmune, secondary, or congenital. 90% of the cases are autoimmune PAP.

Methods: Between 2010 and 2017, 4 cases with PAP were diagnosed among patients admitted to our department. Clinical, laboratory, radiological characteristics and follow-up findings were reviewed.

Results: Three of the patients were male and their ages were 27, 31, 47 and 52 at the time of diagnosis. The main complaints were shortness of breath, cough, sputum production, fever, malaise and weight loss. The duration of symptoms ranged from 2 to 6 months. On the chest radiographs there were areas with irregular consolidations in the mid-lower zones bilaterally. Interlobular and intralobular septal thickening and patchy areas of ground glass, typical of crazy paving pattern were seen on HRCT scan in all patients. Diffusion capacity was normal in one patient and decreased in three patients. All patients underwent fiberoptic bronchoscopy with bronchoalveolar lavage (BAL) and transbronchial lung biopsy was performed in one patient. BAL findings were macroscopically and microscopically compatible with alveolar proteinosis. GM-CSF autoantibody levels were measured in 3 patients and all were elevated (50.6, 159.7 and 279.4 mcr/ml). The clinical severity and radiological extent of the disease and GM-CSF levels were evaluated as unrelated. STAT5 phosphorylation index was assessed in 2 patients and found to be negative. Whole lung lavage was performed 3 times in 1 patient, 2 times in 1 patient, and once in 2 other patients. Total lung lavage was performed in separate sessions for both lungs. Further administration of inhaled sargomastim upon deterioration of lung function in follow up resulted in control of symptoms in one patient.

Conclusion: In conclusion, it is important to consider PAP in the presence of long-standing symptoms and desaturation in patients with pneumonia-like presentation. Infections resulting from dysfunctional GM-CSF may mimic disease progression. Clinically significant improvement can be detected after whole lung lavage, which is the standard treatment. GM-CSF therapy (sargomastim), B-cell suppressive therapy with rituximab and plasmapheresis can be used in patients with recurrent progressive disease.

Keywords: Pulmonary alveolar proteinosis, whole lung lavage, gm-csf

[Abstract:0400] PS-260 [Accepted:Poster Presentation] [Health Policies]

Evaluation of 10-years Our Patients with Chest Diseases by Joinpoint Regression Analysis

Sedat Altın¹, Celalettin İbrahim Kocatürk¹, Ali Kemal Güler², Erkut Bolat³

¹Health Sciences University Yedikule Chest Diseases and Surgery Research and Education Hospital, İstanbul, Turkey

²Health Sciences University Mazhar Osman Psychiatry Research and Education Hospital, İstanbul, Turkey

³Department of Biostatistic, İstanbul University Faculty of Medicine İstanbul, Turkey

Objectives: In recent years, it was aimed to investigate the increase in the numbers of patients with chest diseases in the number of outpatient, emergency and inpatient periods.

Methods: By using the computer data between 2007-2016 years, Chest Diseases patients who applied to Yedikule Chest Diseases and Chest Surgery Training and Research Hospital were compared according to years. The Joinpoint Regression Analysis was used to determine the statistically significant change in patient numbers over the years during the study period. The most appropriate spot where the change in death counts (decrease or increase) was determined. Annual Percent Change (APC) is calculated for each trend.

Results: During the study period, 1,174,484 patients (67.1%) of 1,750,559 outpatient patients were outpatients with chest diseases. Of these, 466,891 (26.7%) appeal to our emergency clinic. 96,301 (83.2%) of 115,758 inpatients were in chest diseases. Between 2007 and 2014, there was a significant increase in the annual number of outpatient clinics of chest diseases by 3.83% (95% Confidence Interval: 2.0 to 5.7) ($p < 0.001$). 2.34% change between 2014 and 2016 is not significant ($p < 0.70$). The number of emergency outpatient clinics increased by 12.11% (8.5-15.8) between 2007 and 2014 ($p < 0.001$). The 2.14% change between 2014-2016 is not significant. The annual increase in the number of patients with chest diseases between 2007 and 2012 is significant with 7.00% (5.1-9.0) ($p < 0.001$). There was a significant decrease with -6.65% (-9.0 - -4.2) between 2012 and 2016 ($p < 0.001$). Of the polyclinic patients, 25% of them referred to my hospital one year later, 11% after 2 years, 6% after 3 years, 3.8% after 4 years and 2.5% after 5 years respectively. While range of patients who applied to our outpatient clinic was 60.3% (58.6-62.1%) once per year, 77.4% (75.5-79%) of the chest patients who came to the emergency polyclinic were single admission ($p < 0.001$). When we examined the annual change in the number of patients who came to the chest once, there was a significant increase ($p < 0.001$) with a change of 3.48% (0.5-6.6) between 2007 and 2014. There was a significant increase 14.64% (7.3-22.5) between the years 2010-2016 in the number of patients who were once admitted urgent clinic ($p < 0.001$). Decrease of -3.13% between 2007-2010 is not meaningful. When we examined inpatient numbers in chest clinics, significant increase with 5.93% (4.4-7.5) between 2007-2012 and significant decrease with -7.14 (-9.1-5.2) between 2012-2016 ($p < 0.001$).

Conclusion: It has been determined that increases the number of outpatient clinics and the number of emergency patients between 2007 and 2014 years and the number of inpatients between 2007 and 2012 are not significant. In addition, since 2014, repetitive rates have increased and new patient applications have decreased.

Keywords: Joinpoint regression, chest diseases, patient increase

[Abstract:0408] PS-056 [Accepted:Poster Presentation] [Lung and Pleura Malignancies]

Retrospective Analysis of Clinicopathological Characteristics, Diagnosis and Treatment of Lung Cancer Patients in Our Research Center

Şenay Yılmaz¹, Güntülü Ak¹, Selma Metintaş², Filiz Boğar³, Muzaffer Metintaş¹

¹Department of Chest Diseases, Lung and Pleural Cancers Research and Clinical Center and Medical Faculty, Eskisehir Osmangazi University, Eskisehir, Turkey

²Department of Public Health, Lung and Pleural Cancers Research and Clinical Center and Medical Faculty Eskisehir Osmangazi University, Eskisehir, Turkey

³Lung and Pleural Cancers Research and Clinical Center, Eskisehir, Turkey

Objectives: It is known that lung cancer is the leading cause of cancer-related deaths in the world. The risk of lung cancer is driven by cigarette smoking and knowing which type of cancer the patient has is important because it affects the treatment options and prognosis. Treatment of lung cancer can involve a combination of surgery, chemotherapy, targeted therapy, immunotherapy, and radiation therapy. The aim of the study was to analyze the clinicopathological characteristics, diagnosis and treatment of lung cancer patients referred to our department, retrospectively.

Methods: A total of 3702 lung cancer patients who were diagnosed and treated in Eskisehir Osmangazi University Hospital, Turkey, were reviewed retrospectively. Clinical data, including age, gender, histology, stage and treatment history were analysed for all the lung cancer patients.

Results: The median age of 3702 patients were 61.5 ± 9.6 years (range: 21-87). The proportion of lung cancer patients in age groups were "20-49 years" (11%), "50-64 years" (48.8%) and "65+" (40.1%). Among them, 299 (8.1%) were females and 3403 (91.9%) were males. The rate of current smokers (58.3%) is higher than exsmoker (33.9%) and nonsmoker (7.8%) patients. The most common histological type was squamous cell carcinoma (SCC), (n=1396, 37.7%), followed by adenocarcinoma (n=844, 22.8%) and small cell lung cancer (n=726, 19.6%). In terms of staging 48.1% of the patients were at stage IV at diagnosis, compared with 4.1% at stage I, 5.9% at stage II and 39.1% at stage III. The Karnofsky Performance Status score (KPS) was ≤ 80 points in 61.3% of cases and >80 points in 38.7% of cases. The patients treated with surgery with/without chemoradiotherapy (9.4%), chemoradiotherapy (%21.5), chemotherapy (%59.2), radiotherapy (%0.6) and supportive care (%8.5).

Conclusion: Patients diagnosed with lung cancer in our clinic are primarily men, SCC is still the most common histological subtype and with stage of 4 at the time of diagnosis. Due to the fact that most of the patients were stage 4 and KPS ≤ 80 , there are difficulties in implementing effective treatment options for the disease. Since the number of patients recommended for surgery is low, it is important to conduct 'screening' for early detection of lung cancer in our region. The treatment cost can also be effectively reduced if early diagnosis is provided.

Keywords: Lung cancer, clinicopathology, treatment

[Abstract:0416] SS-123 [Accepted:Oral Presentation] [Lung and Pleura Malignancies]

Tumor Mutation Analysis in Stage 4 Non-small Cell Lung Cancer (NSCLC)

Türkan Dizdar, Serir Özkan, Gülcan Ürpek, Derlen Özgeç, İlker Özdemir

Department of Chest Diseases, SBU Dr. Suat Seren Chest Diseases and Surgery Training and Research Hospital, İzmir, Turkey

Objectives: Epidermal growth factor receptor (EGFR) mutations, anaplastic lymphoma kinase (ALK) fusion gene and programmed death-ligand 1 (PD-L1) expression were investigated in order to determine appropriate treatment options in patients with stage 4 non-small cell Lung Cancer (NSCLC).

Methods: Between January 2017 and January 2018, 18 male and 7 female patients with stage 4 NSCLC were included in the study. Expression of PD-L1 in tumor tissue samples of all patients was investigated. ALK fusion was researched in 21 patients with adenocarcinoma. EGFR mutation analysis could not perform due to failure of tumor tissue in 3 patients with adenocarcinoma. Whereas this analysis was performed with liquid biopsy technology in 2 of them.

Results: In this study group, 21 adenocarcinomas (84%) and 4 squamous cell carcinomas (16%) were diagnosed. EGFR mutation analysis was positive in 2 (10%) of 20 patients with adenocarcinoma. ALK analysis was positive in 2 (9.5%) of 21 patients with adenocarcinoma. The test was positive in 7 (28%) of 25 NSCLC patients who underwent PD-L1 expression analysis. PD-L1 expression was negative in all 4 patients with stage 4 squamous cell lung carcinoma. Thus, PD-L1 expression was positive in 7 (33.3%) of 21 patients with lung adenocarcinoma. Both PD-L1 expression and ALK analysis were positive in 1 (4.7%) patients with adenocarcinoma. Except this, both PD-L1 expression and EGFR mutation analysis were positive in 1 patient (5.9%) with adenocarcinoma.

Conclusion: In pulmonary adenocarcinomas, PD-L1 expression is the most common, followed by EGFR and ALK positivity. More rarely, in some adenocarcinoma tissues PD-L1 expression positivity can be seen together with alk or EGFR mutation positivities. The results of these analyzes are important in terms of treatment options that would be recommended in patients with stage 4 NSCLC.

Keywords: ALK, EGFR, PDL-1, NSCLC

[Abstract:0418] PS-278 [Accepted:Poster Presentation] [Sleep-related Disorders]

Evaluation of Overactive Bladder and Nocturia on Obstructive Sleep Apnea-Hypopnea Diagnosed Patients

Yeşim Önder¹, Ömer Tamer Doğan¹, Esat Korğalı¹, Ruhsel Cörüt²

¹Department of Chest Disease, Department of Urology, Cumhuriyet University, Sivas, Turkey

²Department of Chest Disease, Giresun, Turkey

Objectives: Obstructive sleep apnea hypopnea syndrome (OSAHS) is a syndrome characterized by recurrent complete or partial obstruction of the upper respiratory tract during sleep, and often accompanied by decreased oxygen saturation and arousals. OSAHS with many nocturnal and daytime symptoms is a heterogeneous disorder. Polysomnography (PSG) is the gold standard in the diagnosis of the disease. OSAHS may affect whole body systems due to oxidative stress, systemic inflammation, increased sympathetic activity. In this study, we researched whether OSAHS is associated with overactive bladder and nocturia in OSAHS-diagnosed patient population and whether it is related to severity of OSAHS.

Methods: The study was conducted between OSAHS diagnosed-PSG performed patient group and the control group without OSAHS diagnosis between 20/02/2017-1/05/2017 in the C.U.T.F Chest Diseases clinic. All cases have been measured with uroflowmetry and ultrasonographic postmicturition residue in order to evaluate lower urinary system function; all patients have been asked for answer to Overactive Bladder (OAB) questioning form; and OAB scores, uroflowmetry parameters and PMR values of patients and control group have been compared.

Results: As a result of our study, it was found that there was significant difference between the groups ($p < 0.05$) when compared to individuals with nocturia, overactive bladder, psychological effect, nokturia related, fatigue and postmictive residual volume (pmrv) but social influences on daily life and peak flow rate were not significant ($p > 0.05$). Compared to patients with OSAHS severity, OAB, psychological effect, nocturia, social effects, daily life effects, fatigue and pmrv measurements were found to be insignificant ($p > 0.05$).

Conclusion: As a result of our study, the coexistence of OSAHS, OAB and nocturia attracted attention. It should be considered that one of the factors that reduce the quality of life of OSAHS patients may be OAB and nocturia.

Keywords: OSA, lower urinary system, uroflowmetry

[Abstract:0421] EPS-180 [Accepted: E-Poster] [Thoracic Surgery]

Nursing Care in Patients Undergoing Minimally Invasive Pectus Deformity Repair

Neriman Onaran, Serdar Evman, Serkan Bayram, Aysun Kosif, Levent Alpay, Çağatay Tezel, Volkan Baysungur

Department of Thoracic Surgery, Sureyyapasa Chest Diseases and Thoracic Surgery Training and Research Hospital, İstanbul, Turkey

Objectives: Pectus excavatum (as sunken/funnel chest) and pectus carinatum (keel-shaped deformity of the chest) are the most common congenital chest wall deformities in children. Cosmetic and psychosocial complaints arise when deformities become more prominent in puberty, and the need for treatment of patients is increasing. At the present time, the most preferred operations are the Nuss and Abramson techniques, which are minimally invasive correction surgical methods. In this study, we aimed to share our experience of preoperative and postoperative nursing care in patients who underwent surgical correction.

Methods: We retrospectively reviewed all patients who underwent minimally invasive surgical procedure between January 2013-December 2017 for pectus deformity correction in our hospital. Gender, age, length of hospital stay, duration of operation and Visual Analogue Scale (VAS) pain score and postoperative pain scores were examined.

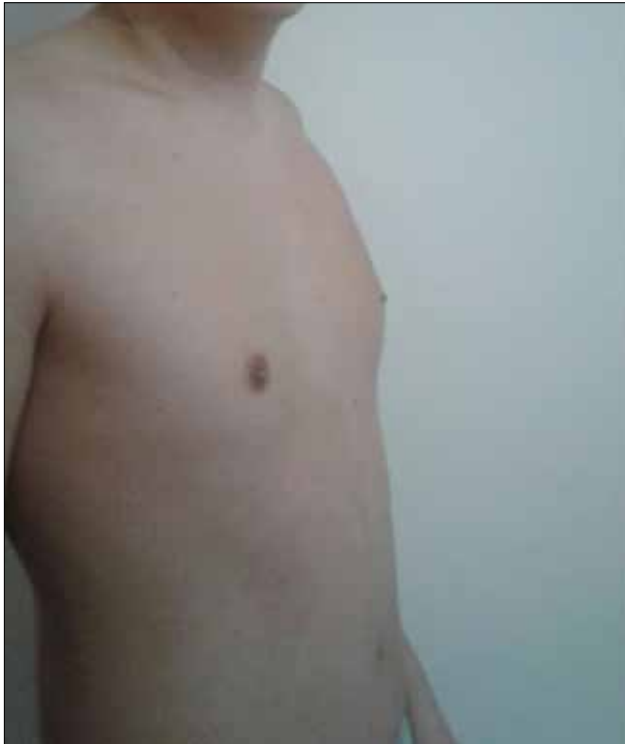

Figure 1. Pectus excavatum

increases as the pain score decreases, and self-confidence increase by seeing that the chest deformity disappears. Patient discharge training should include information about pain control, mobilization, the bar can be prevented from sticking to the skin by light massage, exercise, nutrition, deep breathing exercises and 'bar removal' after an average of 2.5-3 years postoperatively.

Keywords: Nuss, Pectus carinatum, Pectus excavatum

Results: Of 58 patients, 47 were males, 11 were females and the median age was 18.6 (range, 11-37) years. The type of deformity was pectus excavatum in 47 patients, pectus carinatum in 8, and pectus arcuatum in 3 of the patients. Operations performed were Nuss in 49 patients, modified Ravitch in 1, Nuss+modified Ravitch in 1, superficial cartilage shaving in 6 patients, and cartilage excision in 1 patient. Two patients underwent bar revision after 1 and 4 months after Nuss procedure, due to the occurrence of bar rotation / malposition. Minor complications seen were minimal pneumothorax not requiring drainage in 7 patients and serous incision drainage in 7 patients. No major complication or mortality was seen. The mean duration of operation was 60 minutes (range, 30-200 min) . Patient mobilization and respiratory exercises were initiated at 6 hours postoperatively. On postoperative day 0, VAS pain score was 6 (0-10) and postoperative 1st day average was 3 (0-10) . The average hospital stay was 3.5 days (1-7) .

Conclusion: Although cardiovascular and pulmonary problems do not occur frequently in patients with chest wall deformities, they psychologically disturb the person and cause self-esteem deterioration. The high postoperative pain score prevents mobility and affects the mood of the patient. For this reason, pain assessment of patients should be done frequently and the pain should be controlled. Mobilization

[Abstract:0422] PS-018 [Accepted:Poster Presentation] [Clinical Problems - Diffuse Parenchymal Lung Disease]

Bleomycin-Induced Interstitial Lung Disease and Pneumomediastinum

Volkan Altinkaya¹, Oktay Taşolar¹, Şadiye Nuray Voyvoda², Sinan Arslan¹, Fatma Emre Turan Taşolar¹

¹Department of Pulmonary Disease, Derince Training and Research Hospital, Kocaeli, Turkey

²Department of Radiology, Derince Training and Research Hospital, Kocaeli, Turkey

Introduction: Bleomycin is a cytotoxic antibiotic, which is obtained from streptomyces verticillus strains and is used in the treatment of various malignancies. Depending on the use of the drug, the lung damage occurs in 3-40% of the cases. Pulmonary fibrosis is seen in 10% of these cases.

Case Presentation: A 54-year-old male patient with testicular cancer admitted to our polyclinic with complaints of shortness of breath. His medical history revealed that he had been diagnosed with cancer and had received chemotherapy two years ago (bleomycin / etoposide) , upon recurrence after 9 months of follow up without treatment, chemotherapy was repeated with the same drugs. Upon development of dyspnea, the patient was directed to the department of Pulmonary Diseases. Physical examination of the patient revealed tachypnea, dyspnea and bilateral basal crackles on auscultation. Saturation of the patient with 3-4 L/min oxygen was around 95%, which was desaturated in the room atmosphere (O2 sat. with pulse-oximeter was 85%) . Restrictive pattern was present in pulmonary function tests (FEV1=1,51 Lt (%42) , FVC=1,71 Lt (%38) , FEV1/FVC=% 88) . Findings of HRCT scan were compatible with pulmonary fibrosis, therefore systemic steroid therapy was

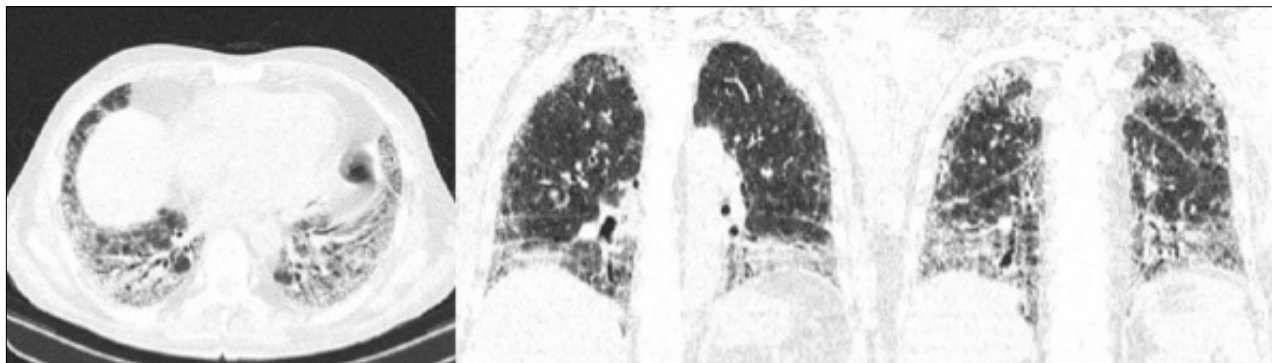


Figure 1. In the HRCT scan of the lungs, diffuse ground-glass opacity areas and interlobular septal thickening are observed in the axial and coronal cross sections, being more prominent in the lower lobes and subpleural areas in lungs bilaterally

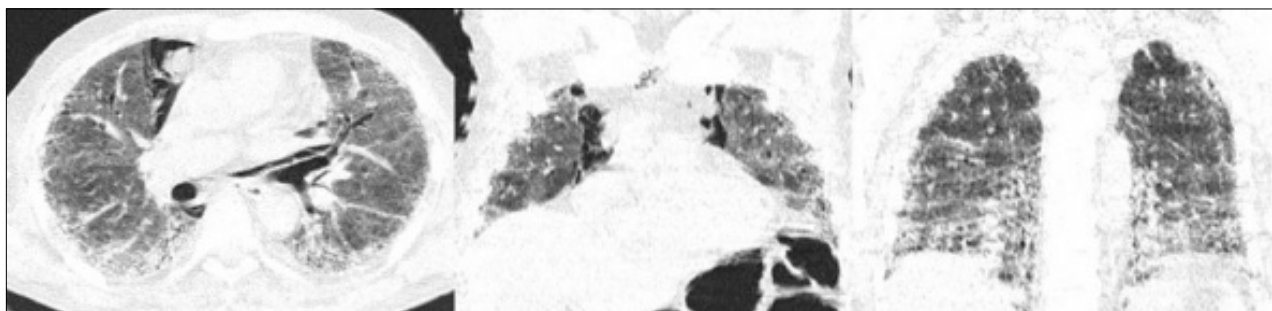


Figure 2. Post-treatment control HRCT revealed no response to treatment and showed that pneumomediastinum developed

initiated (1 mg/kg methylprednisolone) with the diagnosis of bleomycin-induced ILD. Echocardiography during the cardiology consultation was normal and the rheumatological markers (ANA, ANTI DS DNA, C- ANCA, P- ANCA, APA, ASMA, AMA) were negative. Despite the treatment, the patient's symptoms and need of oxygen showed a rapid progression, and HRCT scan was performed again. Upon detecting radiologic progression in the form of ground-glass opacity with pneumomediastinum, pulse steroids (1000 mg/day) were administered for 3 days. The patient died following the treatment of pulsed steroids.

Conclusion: Bleomycin is one of the causes of drug-induced ILD. Bleomycin-induced ILD has been reported in a small number of cases in the literature in which pneumomediastinum and pneumothorax develop during the course of the disease.

Keywords: Bleomycin, pulmonary fibrosis, pneumomediastinum

[Abstract:0423] PS-207 [Accepted:Poster Presentation] [Asthma and Allergy]

Use of Combined Drug Preparations in Allergic Rhinitis in Turkey

Sedat Altın, Handan Altın, Gülşah Günlüoğlu, Nurdan Kalkan

Health Sciences University Yedikule Chest Diseases and Surgery Research and Education Hospital, İstanbul, Turkey

Objectives: In the PARFAIT study, the prevalence of allergic rhinitis was reported to be 14% in adult males and 18.7% in females. The combination of antihistaminic and leukotriene antagonists is increasingly used in our country in recent years in the treatment of allergic rhinitis. The combined preparations used in the year of 2017 were compared with other preparations.

Methods: By using the 2017 TUIK data and IMS 2017 data for men and women over 15 years of age, an inference were made. 2014 and 2017 IMS data was compared. Increase / decrease percentages compared with one another.

Results: In 2017 in pharmaceutical market, 280 million boxes were sold in respiratory market and 40 million boxes (14.3%) were nasal preparations (10 million nasal steroids) and 12.5 million (4.5%) boxes were antileukotrien preparations (4.5%) . 5.6 million (45%) boxes were antihistamine + montelukast preparations. 4 products containing desloratadine from combined

preparations present in the market sold 2.5 million boxes (44.8%) while the product containing 5 levocetirizine sold 3.1 million boxes (55.2%) . By contrast, only 12 preparations containing 10 mg montelukast were able to sell 4.2 million boxes. Combined preparations of asthma over 15 years of age and seasonal allergic rhinitis and combination asthma medication with allergic rhinitis and allergic rhinitis over 15 years of age and symptom relief indications combined with antilokotrien medicines licensed for annual symptomatic treatment of allergic rhinitis were sold in total 9.8 million boxes. In 2017, approximately 1.6 million patients with asthma, allergic rhinitis and adult asthma + allergic rhinitis were used, montelukast and combination. Similarly, the number of patients using nasal steroids with the diagnosis of allergic rhinitis was estimated to be 1.6 million in the same year. The number of patients using both groups was not determined. According to the population of the year 2017 in our country, it is reported that there are 29,999,893 men and 30,514,135 women over the age of 15 years. The estimated number of patients with allergic rhinitis is around 9.9 million, including 4.2 million men and 5.7 million women. It is observed that the number of patients diagnosed and started treatment in these patients is 25%.

Conclusion: Sales of antihistamine+montelukast combined preparation increased by 101.5% in 2017, sales of montelukast box increased by 14.6%, and total antilokotriene market grew by 52.2% in 4 years compared to 2014. It should be known that the sales of this group of drugs will gradually increase if it is considered that about 25% of currently anticipated allergic rhinitis patients are treated.

Keywords: Alerjik rhinitis, montelukast, antihistaminic

[Abstract:0425] PS-203 [Accepted:Poster Presentation] [Asthma and Allergy]

The Evaluation of The Asthma Patients Control Status Regarding to Asthma Diagnosis and Follow-Up Period by Pulmonologists: Preliminary Results

Mehmet Atilla Uysal¹, Sacide Rana Işık², Dilşad Mungan³, Elif Yelda Niksarlıoğlu¹, Gülfem Elif Çelik³, Ali Fuat Kalyoncu⁴

¹Health Sciences University, Yedikule Hospital For Chest Diseases and Thoracic Surgery, Training and Research Hospital, İstanbul, Turkey

²Health Sciences University, Yedikule Hospital For Chest Diseases and Thoracic Surgery, Training and Research Hospital, Allergy Unit, İstanbul, Turkey

³Department of Allergy and Immunology, Ankara University Faculty of Medicine, Ankara, Turkey

⁴Department of Allergy and Immunology, Hacettepe University Faculty of Medicine, Ankara, Turkey

Objectives: The target of asthma treatment is full control according to Global Initiative for Asthma (GINA) criteria. Asthma Control Test (ACT) has also been recommended as a useful tool instead of GINA. There is not enough available data about the implementation of control criteria by pulmonologists in daily routine practice in our country. We aimed to evaluate the utilization of control criteria regarding GINA and ACT by pulmonologists.

Methods: The questions in the questionnaire were: age, gender, hospitals/regions, asking the patients' control status, GINA/ACT usage, GINA criteria as questions, ACT questions, recording the patients' status, evaluation time, and if the survey caused the awareness of the asthma control evaluation. The questionnaire has been filled cross-sectional and face to face in the meetings of Turkish Thoracic Society (TTS) . Attention was paid to include pulmonologists from all regions of Turkey.

Results: 286 pulmonologists and pulmonology residents filled the questionnaire (F:183/M:103) , Mean age was 42.66±10.12 (25-73) . Majority of the physicians (78.37%) have been working in training and research hospitals. While 49.30% of the pulmonologists were evaluating the control status for all patients, 30.42 % of them were using only GINA, 7.62% only, ACT and 39.86% both. Of the pulmonologists using GINA 52.48%, 56.44%, 64.36 %, and 56.93 % were asking daily symptoms, daily activity, night symptoms, and reliever use, respectively. Of the ACT users 30.10%, 40.82%, 41.33%, 48.47% and 28.06% were evaluating daily life restriction, the frequency of dyspnea, night symptoms, usage of inhaler drugs and perception of the asthma control by the patient, respectively. The control status was recorded by 18.4 % of the physicians, and 56% were evaluating their patients in less than ten minutes. We found that when the time spent for the patient was increased, the rate of questioning and recording of the control status seemed to be significantly higher (p<0,01, p<0.001, respectively) . The questionnaire caused awareness for the participant pulmonologists, 36.3% were completely, 37.02% partly of the asthma control questioning.

Conclusion: Our results show that GINA criteria were used more frequently than asthma control test. Implementation of all questions of GINA was proportionally higher than ACT steps. Although there was no systematical approach to evaluate the asthma control status by the pulmonologists, most of them were asking the frequency of daily and night symptoms. Furthermore, the pulmonologists did not take advantage of self-application of ACT by the patient and were not able to evaluate asthma control status due to time shortage.

Keywords: Asthma, control, physician

[Abstract:0426] SS-063 [Accepted:Oral Presentation] [Experimental Investigations]

Publication of Theses on Chest Diseases in Turkey and Related Factors

Özge Yılmaz¹, Ahmet Uğur Demir², Ali Naycı³, Ayşe Bilge Öztürk⁴, Canan Demir⁵, Figen Deveci⁶, Hasan Yüksel⁷, Öner Dikensoy⁸, Yasemin Saygıdeğer⁹, Hasan Bayram¹⁰

¹Department of Pediatric Allergy and Immunology, Celal Bayar University School of Medicine, Manisa, Turkey

²Department of Chest Diseases, Hacettepe University School of Medicine, Ankara, Turkey

³Department of Pediatric Surgery, Mersin University School of Medicine, Mersin, Turkey

⁴Department of Chest Diseases, Koç University School of Medicine, İstanbul, Turkey

⁵Department of Endocrinology, Memorial Ankara Hospital, Ankara, Turkey

⁶Department of Chest Diseases, Firat University, Elazığ, Turkey

⁷Department of Pediatric Allergy and Immunology, Department of Pediatric Chest Diseases, Celal Bayar University School of Medicine, Manisa, Turkey

⁸Department of Chest Diseases, Acıbadem University School of Medicine, İstanbul, Turkey

⁹Department of Chest Diseases, Doğu Private Hospital, Manisa, Turkey

¹⁰Department of Chest Diseases, Koc University School of Medicine, İstanbul, Turkey

Objectives: Writing a thesis contributes to the improvement of candidate specialist in terms of both making a scientific research and evaluating scientific articles while reading. Moreover, the contribution of thesis to scientific literature is important for cost-effectiveness and it establishes a criterion for the assessment of scientific competence. However, it is not known whether theses conducted in Turkey meet these expectations adequately or not. The aim of this study is to evaluate the contribution of theses on chest diseases to scientific literature and to examine the factors that can affect this.

Methods: In this study, theses on chest diseases, which are recorded in the system of the Council of Higher Education (YOK), between 2006 and 2016 were examined (<https://tez.yok.gov.tr/UlusalTezMerkezi>). The theses that were reached were evaluated in terms of publication by using the name of thesis advisor in PubMed and Google Scholar. The submission date of thesis, the type of educational institution where thesis was performed, title of the theses advisor, publication date of article, current impact factor of the journal in which article was published, index of the publishing journal, number of writers of article, the first author of article, and the current institution of person conducting the thesis were recorded. The theses that were published or not published as articles were compared.

Results: A total of 661 theses recorded in thesis center from the Department of Chest Diseases between 2006 and 2016 were detected. Of these theses, 99% were submitted from university hospitals and 54 were published as articles. While the rate of publication was 23.6% for theses completed between 2006 and 2010, it was 18.6% for those between 2011 and 2016 ($p=0.002$). While the rates of publication as articles were 21.9%, 21.9%, and 17.9% for those whose thesis advisors had academic titles of professor, associate professor, and assistant professor, respectively, this rate was 36.8% for those whose thesis advisors were specialists ($p=0.02$). Most of journals in which these articles were published were indexed by PubMed and Science Citation Index (SCI) (31.6%). The mean number of authors was 5.6 ± 2.2 . The first author was thesis executive at the rate of 83.9% and thesis advisor at the rate of 11.6%. The rate of publication of thesis as an article was significantly higher for theses whose executive worked in an university than those whose executives worked in Training and Research hospitals, state hospitals, and private hospitals (39.8%, 19.1%, 23.3%, and 14.9%, respectively; $p=0.002$). It was found that 26.5% of chest diseases specialists whose theses were published as articles and 11.4% of those whose theses were not published as articles were academic staff ($p<0.001$).

Conclusion: Based on these findings, it can be concluded that the rates of theses published as articles are highly low and these rates are affected by personal academic features. It has been understood that the academic title of thesis advisor has no effect on publication rate of thesis, but thesis executive's being an academic staff increases the possibility of its publica-

tion. Therefore, instructors without any academic concern can be recommended to get education of basic scientific research techniques through different ways.

Keywords: Chest diseases, thesis, Turkey

[Abstract:0427] SS-091 [Accepted:Oral Presentation] [Tobacco Control]

Digital Epidemiology: Can Google Trends Give Some Information about Electronic Cigarette Use in Turkey?

Mehmet Atilla Uysal¹, Elif Yelda Niksarlıoğlu¹, Aslı Çarkoğlu², Ömer Uysal³, Ali Cevat Kutluk¹, Bülent Karadağ⁴

¹Health Sciences, Yedikule Hospital For Chest Diseases and Thoracic Surgery, Training and Research Hospital, İstanbul, Turkey

²Department of Psychology, Kadir Has University, İstanbul, Turkey

³Department of Biostatistics, Bezmialem University School of Medicine, İstanbul, Turkey

⁴Department of Pediatric Chest Diseases, Marmara University School of Medicine, İstanbul, Turkey

Objectives: “Google trends” is a service provided by google that shows search trends on google search. It refers to searches on google that differ from other searches by showing an increase over normal. By selecting time periods, it also shows which regions are more popular for search. Use of electronic cigarettes is banned since June 2013. It is thought that both sale and usage have increased in recent years, there is no healthy data on this issue. We analyzed the results of google trends using “electronic cigarettes” as search terms between 2011-2017, aimed to find out the changes between 2014 and 2017 and predicted the search interest in next two years.

Methods: We used “electronic cigarette” search terms in “web, shopping and, youtube” in google trends between 2011 and 2017 in Turkey. The trends graphs were drawn using Stata 15.2 software. Due to the prohibition of electronic cigarette use in June 2013, there was extensive data. So, the period for trend analysis has been performed since 2014. Data were analyzed using SPSS 22 and GMDH Shell DS programs. We compared the search terms’ popularity using repeated measures ANOVA according to years, GMDH Shell DS program automatically compared the regression methods to yield best predictive results and generated two years predictions.

Results: Visual review of the graphs reveals that the relevance of the web is highest in May and June in 2011, and started to rise again in early 2016. Shopping interest showed, fluctuations but the trend has been increased. Youtube interest has increased markedly since 2016 (Figure 1). Interest in web, shopping, and youtube was found to be statistically higher com-

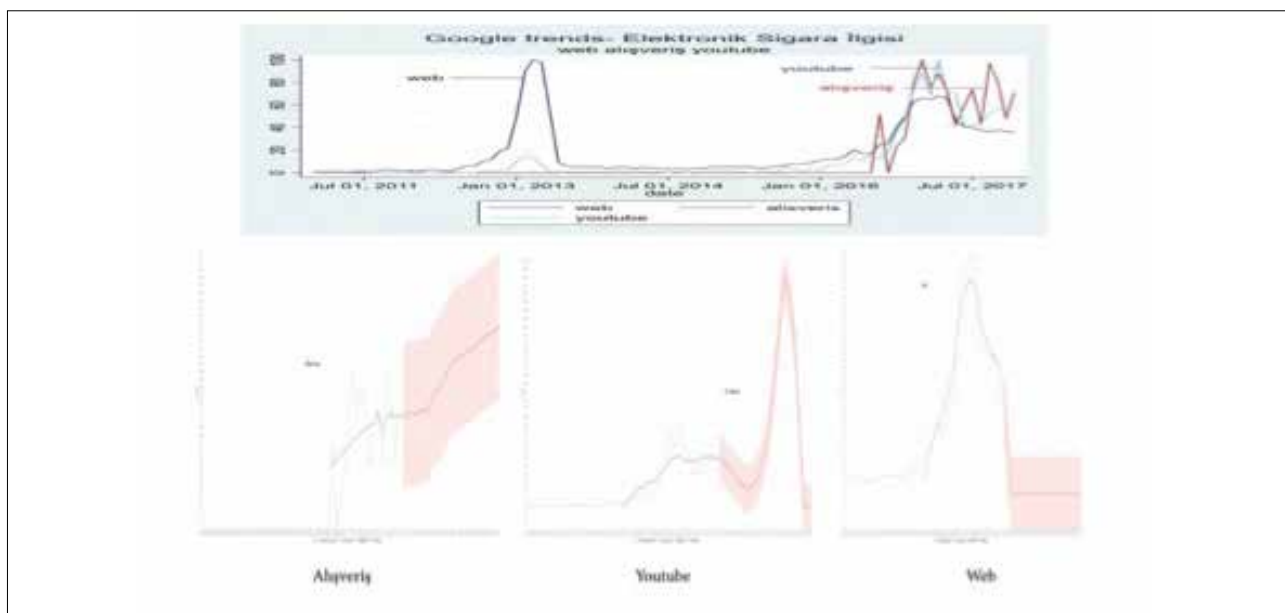


Figure 1. Google trends and forecasting

pared other years (2014, 2015, 2017) ($p<0.001$, $p<0.001$, $p<0.001$, respectively) . As a result of the time series analysis, 2018 and 2019, shopping and youtube interest will be dramatically increased in 2018. The web interest will be raised in 2018 but declined in 2019 (Figure 1).

Conclusion: Using google trends analysis, we have found that electronic cigarettes usage regarding the web, shopping and youtube were statistically higher in 2016 compared to other years. (especially for shopping and youtube) . Shopping and youtube interest may increase in 2018, but youtube and web interest are expected to decrease in 2019. We believe that measures are inadequate for the sale of prohibited electronic cigarettes and additional legal regulations are necessary.

Keywords: Electronic, cigarette, media, monitoring

[Abstract:0428] SS-057 [Accepted:Oral Presentation] [Environmental and Occupational Lung Diseases]

The Relationship Between Mortality and Radiological and Functional Changes Developing in 5-Year Follow-Up in Cases with Pneumoconiosis

Nur Safak Alici¹, Türkan Nadir Öziş², İbrahim Onur Alici³

¹Department of Chest Diseases, Dokuz Eylül University School of Medicine, İzmir, Turkey

²Department of Chest Diseases, Ankara Occupational Diseases Hospital, Ankara, Turkey

³Dr. Suat Seren Chest Diseases and Chest Surgery Training and Research Hospital, İzmir, Turkey

Objectives: Pneumoconiosis, which is the mostly encountered occupational disease, is an important public health concern with its high morbidity and mortality. Although radiological changes progressing despite the cessation of exposure and gradual respiratory function loss are often emphasized, there are no sufficient data on the amount of these pathologies and their

Table 1. Various features of patients with pneumoconiosis

Number (n)	41
Age of diagnosis (mean±SD, min-max)	45.1±12.43 (24-71)
History of smoking [n (%)]	30 (%73.17)
Cigarette (pack/year) (mean±SD, min-max)	13.17±11.52 (0-50)
Age of employment (year) (mean±SD, min-max)	21.83±7.69 (13-64)
Duration of exposure (month) (mean±SD, min-max)	190.63±100.66 (30-564)
Duration of latency (mean±SD, min-max)	62.85±85.31 (0-360)
Sector	
Coal worker	19 (46.3%)
Iron foundry worker	6 (14.6%)
Antimon mine worker	6 (14.6%)
Quartz and glass grinding worker	5 (12.2%)
Others	5 (12.2%)
Complaints	
Cough	30 (60%)
Sputum	19 (38%)
Dyspnea	37 (74%)
RFT in diagnosis	
FEV1 (%±SD) (min-max)	82.37±14.6 (54-121)
FVC (%±SD) (min-max)	88.2±14.75 (62-128)
FEV1/FVC (%±SD) (min-max)	75.80±7.86 (53-88)
MEF25-75 (%±SD) (min-max)	72.61±29.18 (22-145)
DLCO (%±SD) (min-max) n=28	82.82±20.93 (49-127)

relationship with mortality. In this study, it was aimed to demonstrate radiological and functional progression developing in time after the diagnosis of pneumoconiosis in a reference center and to assess its relationship with mortality.

Methods: Among patients from different business sectors who were diagnosed with pneumoconiosis in Ankara Occupational Diseases Hospital, data of those who applied for control at least five years later and who were evaluated radiologically and functionally were retrospectively analyzed. Patients' demographic features, ages of employment, duration of exposure, time passing from the first exposure to present, smoking histories, complaints, functional states, and radiological findings were recorded. Chest radiographies of patients at the time of diagnosis and after five years were classified according to the ILO classification system and findings of the respiratory function tests were recorded. Radiological progression was defined as at least one-step progression of category, profusion, or large opacity. Cases in which an increase over 10% in FEV1, 10% in FVC, and 15% in DLCO were determined. Cases with mortality were detected and possible related variables were analyzed.

Results: 41 patients who were diagnosed in the years of 2000-2005 and whose 5-year follow-up data were reached were included in the study. Various features of cases are presented in Table 1. All patients were male. 23 (56%) patients were diagnosed with silicosis and 18 (44%) were diagnosed with coal worker's pneumoconiosis (CWP). The presentations of chest radiographies according to ILO classification are shown in Table 2. In the evaluation performed after five years, progression was radiologically detected in 31 cases (75,6%). In respiratory function tests performed five years later, a significant decrease was observed in FEV1, FVC, and DLCO (Table 3). The numbers of cases in which a decrease of more than 10% in FEV1, 10% in FVC, and 15% in DLCO were 26 (63,4%), 25 (61,0%), and 13/28 (46,4%), respectively. Eight of patients (19,5%) were learned to be exitus. Of them, 4 (50%) was diagnosed with silicosis and 4 (50%) with CWP. The mean time of being exitus was 10,3±4,9 (6-17) years after the last control. It was observed that only exposure (168,8±77 vs 280,6±137,5 p=0,004) and latency durations (49,8±80 vs 116,6±88,4 p=0,045) among variables were significantly higher in the group developing mortality. No relationship was found between radiological and functional deterioration and mortality. It was seen that this relationship was continued when cases with silicosis and CWP were separately examined.

Conclusion: In consistency with literature, radiological progression and functional loss develop over time in cases of pneumoconiosis. However, the relationship of these variables with mortality could not be demonstrated. Exposure and latency durations were determined as primary risk factors for mortality.

Keywords: Pneumoconiosis, mortality, radiological progression

Table 2. Diagnosis and functional changes after five years

	Values at the time of diagnosis	Values after five years	p
FEV1 (%±SD) (min-max)	82,37±14,6 (54-121)	64,8±16,8 (27-92)	<0,001
FVC (%±SD) (min-max)	88,2±14,75 (62-128)	70,3±16,0 (34-100)	<0,001
DLCO (%±SD) (min-max) (n=28)	100±23,93 (49-127)	82,8±20,9 (49-127)	0,005
Paired samples t-test			

[Abstract:0430] SS-138 [Accepted: Oral Presentation] [Respiratory Failure and Intensive Care]

Tracheostomy Practices in Intensive Care Units in Turkey: Turkish Thoracic Society Critical Care Assembly Point Prevalence Trial

Özlem Ediboğlu¹, Özlem Yazıcıoğlu Moçin², Ezgi Özyılmaz³, Cüneyt Saltürk², Hüseyin Arıkan⁴, Begüm Ergan⁵, Turgay Çelikel⁴, Tuğba Onalan⁶, Zerrin Özçelik⁷, Sema Turan⁸, İskender Kara⁹, Atilla Kara¹⁰, Emine Dağlı¹¹, Selma Duru Bülbül¹¹, Kadriye Kahveci¹², Metin Dinçer¹², Nimet Şenoğlu¹³, Hüseyin Özkarakas¹³, İlhan Bahar¹⁴, Melike Cengiz¹⁵, Atilla Ramazanoğlu¹⁵, Burcu Çelik¹⁶, Ümmügülsüm Gaygısız¹⁶, Gülay Kır¹⁷, Ahmet Bindal¹⁸, Belgin Akan¹⁸, Işıl Özkoçak Turan¹⁸, Fatma Yıldırım¹⁹, Burcu Başarık²⁰, Zeliha Arslan Ulukan²¹, Serdar Efe²², Murat Sungur²³, Şahin Temel²³, Seval İzdeş²⁴, Derya Hoşgün²⁴, Nurhan Karadeniz²⁵, Eylem Tunçay², Nezihe Çiftarlan Göksenoglu², İlim İrmak², Utku Datlı²⁶, Avşar Zerman²⁷, Devrim Akdağ²⁸, Levent Özdemir²⁹, Gülseren Elay³⁰, Yücel Karaçayır³¹, Arzu Topeli³², Pervin Hancı³², Esat Kıvanç Kaya³², Pinar Güven³³, Hilal Sazak³⁴,

Semih Aydemir³⁴, Gülbin Aygencel³⁵, Yusuf Aydemir³⁶, Zahide Doğanay³⁷, Özgür Kömürcü³⁷, Volkan Hancı³⁸, Emre Karakoç³⁹, Didem Sözütek³⁹, Güven Coşkun⁴⁰, Güngör Ateş⁴¹, Civan Tiryaki⁴¹, Ayşe Nur Soytürk⁴², Nermin Kelebek Girgin⁴², Gülbahar Çalışkan⁴², Oben Bıyıklı⁴³, Necati Gökmen⁴⁴, Uğur Koca⁴⁴, Aydın Çiledağ⁴⁵, Kezban Özmen Süner⁴⁶, İsmail Cinel⁴⁷, Mustafa Kemal Arslantaş⁴⁷, Fethi Gül⁴⁷, Sena Ataman¹, Cenk Kiraklı¹, Recai Ergün⁴⁸, Nafiye Yılmaz⁴⁹, Defne Altıntaş⁵⁰, Leyla Talan⁵⁰, Murat Yalçınsoy⁵¹, Mehmet Nezir Güllü⁵², Perihan Ergin Özcan⁵³, Günseli Orhun⁵³, Yusuf Savran⁵⁴, Murat Emre okur⁵⁴, Serdar Akpınar⁵⁵, Pelin Şen⁵⁶, Gül Gürsel⁵⁷, İrem Şerifoğlu⁵⁸, Ender Gedik⁵⁸, Öner Abidin Balbay⁵⁹, Türkay Akbaş⁵⁹, Sinem Cesur⁵⁹, Hülya Yolaçan⁶⁰, Seda Beyhan Sagmen⁶¹, Pervin Korkmaz Ekren⁶², Feza Bacakoğlu⁶², Begüm Ergan⁵, Ersin Günay⁶³, Muzaffer Sarıaydın⁶³, Dursun Ali Sağlam⁶⁴, Hüseyin arıkan⁴, Saif Karakurt⁴, Emel Eryüksel⁴, Turgay Çelikel⁴, Funda Öztuna⁶⁵, Emine Sevil Ayaydın Mürtezaoğlu⁶⁵, Hakan Cinemre⁶⁶, Ahmet Nalbant⁶⁶, Öznur Yağmurkaya⁶⁶, Tuğba Mandal⁶⁷, Belgin İkidığ⁶⁸

¹Health Sciences University, Dr. Suat Seren Chest Diseases and Surgery Training and Research Hospital, İzmir, Turkey

²Health Sciences University, Süreyyapaşa Chest Diseases and Surgery Training and Research Hospital, İstanbul, Turkey

³Çukurova University School of Medicine Balcalı Hospital, Adana, Turkey

⁴Marmara University Pendik Training and Research Hospital, İstanbul, Turkey

⁵Dokuz Eylül University School of Medicine, İzmir, Turkey

⁶İzmir Çiğli District Hospital, İzmir, Turkey

⁷Balıkesir State Hospital, Balıkesir, Turkey

⁸Ankara Yüksek İhtisas Training and Research Hospital, Ankara, Turkey

⁹Konya Numune Hospital, Konya, Turkey

¹⁰Sivas Numune Hospital, Sivas, Turkey

¹¹Tarsus State Hospital, Mersin, Turkey

¹²Ankara Ulus State Hospital, Ankara, Turkey

¹³Health Sciences University, İzmir Tepecik Training and Research Hospital, İzmir, Turkey

¹⁴Van Training and Research Hospital, Van, Turkey

¹⁵Akdeniz University Hospital, Antalya, Turkey

¹⁶Erzurum District Education Research Hospital, Erzurum, Turkey

¹⁷Gaziosmanpaşa Taksim Training and Research Hospital, İstanbul, Turkey

¹⁸Ankara Numune Training and Research Hospital, Ankara, Turkey

¹⁹Ankara Dışkapı Yıldırım Beyazıt Training and Research Hospital, Ankara, Turkey

²⁰Denizli State Hospital, Denizli, Turkey

²¹Medicana International İstanbul Hospital, İstanbul, Turkey

²²Trakya University Health Research and Application Hospital, Edirne, Turkey

²³Erciyes University School of Medicine Hospital, Kayseri, Turkey

²⁴Ankara Atatürk Training and Research Hospital, Ankara, Turkey

²⁵Manisa State Hospital, Manisa, Turkey

²⁶Kütahya Evliya Çelebi Training and Research Hospital, Kütahya, Turkey

²⁷Adana Numune Training and Research Hospital, Adana, Turkey

²⁸Çukurova University School of Medicine Balcalı Hospital, Adana, Turkey

²⁹Dörtöyol State Hospital, Hatay, Turkey

³⁰Gaziantep Dr. Ersin Arslan Training and Research Hospital, Gaziantep, Turkey

³¹Muğla Sıtkı Koçman University Training and Research Hospital, Muğla, Turkey

³²Hacettepe University School of Medicine Hospital, Ankara, Turkey

³³Bolu İzzet Baysal State Hospital, Bolu, Turkey

³⁴Ankara Atatürk Chest Diseases and Surgery Training and Research Hospital, Ankara, Turkey

³⁵Gazi University School of Medicine Hospital, Ankara, Turkey

³⁶Sakarya University Training and Research Hospital, Sakarya, Turkey

³⁷Samsun Training and Research Hospital, Samsun, Turkey

³⁸Dokuz Eylül University School of Medicine Hospital, İzmir, Turkey

³⁹Çukurova University School of Medicine Balcalı Hospital, Adana, Turkey

⁴⁰Afyonkarahisar State Hospital, Afyonkarahisar, Turkey

⁴¹Memorial Diyarbakir Hospital, Diyarbakir, Turkey

⁴²Uludağ University School of Medicine Hospital, Bursa, Turkey

⁴³İzmir Central Hospital, İzmir, Turkey

⁴⁴Dokuz Eylül University School of Medicine Research and Application Hospital, İzmir, Turkey

⁴⁵Ankara University School of Medicine Hospital, Ankara, Turkey

⁴⁶Konya Training and Research Hospital, Konya, Turkey

⁴⁷Marmara University Pendik Training and Research Hospital, İstanbul, Turkey

⁴⁸Ankara Dışkapı Yıldırım Beyazıt Training and Research Hospital, Ankara, Turkey

⁴⁹Atatürk University Health Research and Application Hospital, Erzurum, Turkey

⁵⁰Ankara University School of Medicine Hospital, Ankara, Turkey

- ⁵¹Inonu University School of Medicine Hospital, Malatya, Turkey
⁵²Health Sciences University, Diyarbakir Gazi Yaşargil Training and Research Hospital, Diyarbakir, Turkey
⁵³Istanbul University School of Medicine Hospital, İstanbul, Turkey
⁵⁴Dokuz Eylul University School of Medicine Research and Application Hospital, İzmir, Turkey
⁵⁵Ankara Dışkapı Yıldırım Beyazıt Training and Research Hospital, Ankara, Turkey
⁵⁶Istanbul Başkent University School of Medicine Hospital, İstanbul, Turkey
⁵⁷Gazi University School of Medicine Hospital, Ankara, Turkey
⁵⁸Ankara Başkent University School of Medicine Hospital, Ankara, Turkey
⁵⁹Düzce University Health Research and Application Hospital, Düzce, Turkey
⁶⁰Eskişehir Yunus Emre State Hospital, Eskişehir, Turkey
⁶¹Health Sciences University, Dr. Lutfi Kırdar Kartal Training and Research Hospital, İstanbul, Turkey
⁶²Ege University Medical Faculty Hospital, İzmir, Turkey
⁶³Afyon Kocatepe University Ahmet Necdet Sezer Research and Application Hospital, Afyon, Turkey
⁶⁴Ankara Atatürk Training and Research Hospital, Ankara, Turkey
⁶⁵Karadeniz Technical University School of Medicine, Trabzon, Turkey
⁶⁶Sakarya University Training and Research Hospital, Sakarya, Turkey
⁶⁷Adıyaman University School of Medicine Hospital, Adıyaman, Turkey
⁶⁸SEV American Hospital, Gaziantep, Turkey

Objectives: Tracheostomy is a procedure which can be performed at the bedside in the intensive care unit (ICU) . The aim of this study is to evaluate tracheostomy practices of intensivists in the Turkish ICU.

Methods: A cross- sectional study was performed by the Respiratory Failure and Intensive Care Assembly of Turkish Thoracic Society. The survey included data about tracheostomy practices were completed between the dates October 26, 2016 at 08:00 and October 27, 2016 at 08:00. Data were collected through all participating centers via post or online.

Results: From 67 centers, nine hundred and twenty-two patients included the study. Median age, Glasgow Coma Scale (GCS) , APACHE II score, and median ICU day were 68 (55-79) , 11 (6-15) , 18 (12-24) , and 7 (3-18) day, respectively. The number of participated centers type were University Hospitals (UH) (n=29, 43%) , Training and Research Hospitals (TRH) (n=22, 33%) , State Hospitals (SH) (n=12, 18%) , and Private Hospitals PH) (n=4, 6%) . Percutaneous tracheostomy was the most using technique in UH (75%) and TRH (80%) , contrary to PH (50%) and SH (36%) . While tracheostomy was performed in PH by otorhinolaryngologist (100%) , in other type hospitals it was done by intensivists mostly. The main reason to perform tracheostomy was found prolonged intubation (79%) . The number of tracheostomy patients were 16 and the median day of tracheostomized patients was 23 (8-59) day, at relevant day.

Conclusion: Percutaneous tracheostomy was the most used technique in training hospitals, and performed by intensivists. Intensive care training programme are important to standardisation in our country.

Keywords: Tracheostomy, intensive care, prevalence

[Abstract:0433] PS-169 [Accepted:Poster Presentation] [Tuberculosis]

Side Effects and Frequency of Antituberculosis Drugs in Patients with Pulmonary Tuberculosis

Thiery Sibomana, Fatma Esra Günaydın, Nurdan Kalkan, Gülşah Günlüoğlu, Sedat Altın

Yedikule Hospital for Chest Disease and Thoracic Surgery, İstanbul, Turkey

Objectives: The tolerance of drugs in tuberculosis treatment is an important problem... The problems caused by drugs range from simple skin rashes to neurological symptoms and findings, from mild transaminase elevations to toxic hepatitis death. We aimed to evaluate retrospectively the side effects of the drug in tuberculosis polyclinic patients who were diagnosed with pulmonary tuberculosis and who were treated with first group antituberculosis drugs.

Methods: 100 patients who applied to our tuberculosis polyclinic and had a diagnosis of pulmonary tuberculosis and started antituberculosis treatment were retrospectively included in the study. Sex, case definitions, additional illness, non-TB drugs, treatment, alcohol and smoking habits, presence of active hepatitis (HBs Ag, anti HBs, other markers) ,

serologic status (HIV) , sputum smear status, sputum culture Status and initial liver enzyme status and drug side effects of these cases were analyzed.

Results: Mean age of 100 cases was $35,89 \pm 15.46$. 66 of them were male and 34 were female. 85 of the patients were new cases, 15 were recurrent cases and 18% had additional diseases. Side effects related to drugs were observed in 59% of the patients. 75.8% of them were female and 24.2% were male. 72 % of side effects were minor, and 28 % were major side effects. The most frequent side effect was hyperuricemia with 43%. Side effects such as hepatotoxicity and pruritus were followed by 23%. Ototoxicity and thrombocytopenia were observed in 2% of the patients with the least side effect. 15% of the patients with side effects need to be withdrawn. Patients with chronic alcoholism, hepatitis B, C infection have a higher incidence of hepatotoxicity than those without hepatotoxicity.

Conclusion: In our study, the most common adverse side effect during tuberculosis treatment was hyperuricemia. However, in any patient, treatment has not risen to the point that it should be discontinued and does not cause any significant symptoms. Again, as expected, patients with prior hepatitis, HCV and HBsAg positivity and nausea and vomiting complaints were found to be important in terms of hepatotoxicity development, so patients with these characteristics should be more careful and biochemically examined more frequently. Although the proportion of female patients included in the study was lower, side effects were found to be more elevated in female than in male patients. It is thought that women should be followed more carefully in terms of side effects.

Keywords: Tuberculosis, side effects, drug toxicity

[Abstract:0437] EPS-193 [Accepted: E-Poster] [Thoracic Surgery]

Our First Experience in Bronchoscopic Lung Volume Reduction

Gürcan Koşal¹, Tamer Altınok¹, Korkut Bostancı², Barış Sarıçoban¹, Şebnem Yosunkaya³

¹Department of Chest Surgery, Necmettin Erbakan University Meram School of Medicine, Konya, Turkey

²Department of Chest Surgery, Marmara University Pendik Training and Research Hospital, İstanbul, Turkey

³Department of Chest Diseases, Necmettin Erbakan University Meram School of Medicine, Konya, Turkey

Published studies investigating bronchoscopic LVR treatment in emphysematous pulmonary diseases show that treatment is applicable, has an acceptable safety profile, and is clinically effective in short term. A 62-year-old man who was diagnosed with COPD, received inhaler treatment and had a 40-pack/year smoking history indicated that his shortness of breath was gradually increasing. Bilateral paraseptal emphysema areas were seen in the thorax CT. In the patient in whom RFT was

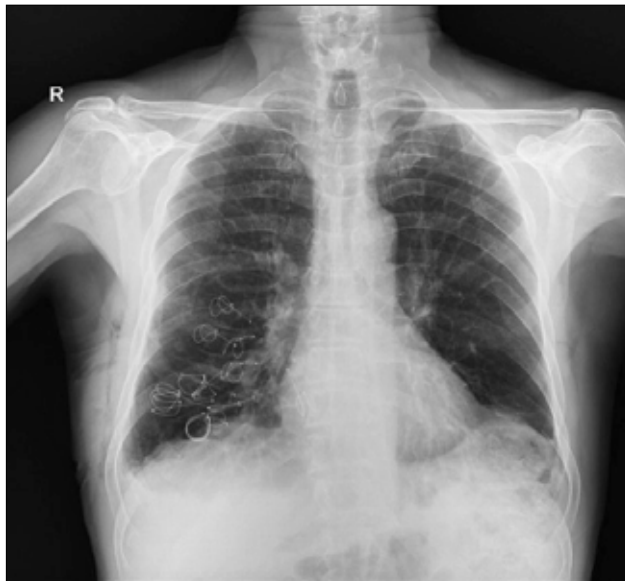

Figure 1. First COIL application

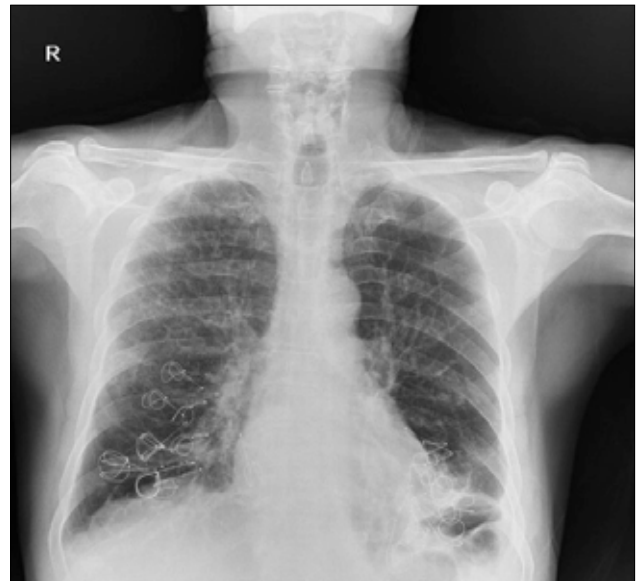

Figure 2. Second COIL application

performed preoperatively, FEV1 was measured as 0.89 lt (37%) , FVC as 1.31 lt (43%) and FEV1/FVC as 86. In the 6-minute walk test, the score was 1-3 and the distance was 346 meters. Bronchoscopic Volume Reduction Surgery (COIL) was performed in the right lung lower lobe of the patient. The patient in whom pneumothorax developed after the procedure was intervened with tube thoracostomy. RFT was repeated in the postoperative period. FEV1 was measured as 1,19 (50%) , FVC as 2,01 (67%) and FEV1/FVC as 75. The patient's FEV1 value increased by 33%. Bronchoscopic Volume Reduction Surgery (COIL) was applied to the left lung lower lobe of the patient 2 months later. An increase in FEV1 values and in the quality of life was found in the patient we presented. We present our patient in order to share the experience of our clinic in bronchoscopic volume reduction surgery.

Keywords: Volume reduction, COPD, bronchoscopic COIL application

[Abstract:0438] EPS-054 [Accepted: E-Poster] [COPD]

Comparative Analysis of Some Clinical-Instrumental and Laboratory Parameters in Patients with COPD and Ischemic Heart Disease (IHD)

Vasif Abdulla Abdullayev, Gülzar Rafiq Aliyeva

Pulmonology Department of Research Institute of Lung Diseases, Baku, Azerbaijan

Objectives: In modern approach, COPD is not only associated with lung damage, but also with systemic symptoms. Large-scale epidemiological studies have revealed that cardiovascular system diseases are found in 50% of cases with COPD. The cause of death during COPD is the severe respiratory failure in the first place, the second are heart failure and heart rhythm disturbances. The aim of the research is study of some clinical-instrumental and laboratory parameters in patients with COPD and IHD.

Methods: The study was conducted on the basis of clinical-instrumental examination of 352 patients. All examined are divided into 3 groups:

I group- 121 patients with COPD,

II group - 113 patients with COPD and IHD

III group - 118 patients with IHD.

All patients were subjected to medical examination, including clinical examination, blood biochemical examination, Holter ECG, echocardiography, X-ray examination, function of external respiration.

Results: In the clinical scenario of patients with a more severe course of COPD, dyspnea complaints were predominant during minor physical loading. They have stenocardia with very cognitive apnea. That is, these arrests have been developed more on "asthmatic type", while the occurrence of ischemia has been confirmed by ECG during retention or by Holter monitoring results. According to the findings, symptoms of bronchial and pulmonary lesions have been found in about 1/3 of the patients with COPD and IHD. Apparently, the actual spread of these disorders in Group II was higher, since the radiological method is more restrictive for detection of their initial stages. Only right ventricular hypertrophy and sinus tachycardia were found to be distinct, which was typical for patients with IHD along with COPD.

Conclusion: Thus, changes in the lipoprotein spectrum of the blood have been unchanged in patients with I and II groups: In addition to COPD, the levels of cholesterol (Ch) and triglycerides (TG) were significantly higher in patients with IHD, but more were recorded for lower Ch HDL. As a result, the atherogenic coefficient of lipid metabolism was generally significantly higher in the isolated IHD, along with both IHD and COPD. All of these show that the atherogenic efficacy is moderately acute, and the risk of developing atherosclerosis in both observation groups is severe.

Table 1. The mean values of lipids and atherogenic coefficients in blood plasma in I and II groups

Indicators	I group (COPD)	II group (COPD+IHD)
General cholesterol mmol/L	5.69±0.19	6.64±0.2
Ch HDL, mmol/L	0.988±0.04	0.978±0.06
TG, mmol/L	2.192±0.14	2.53±0.09
Ch LDL, mmol/L	3.71±0.17	3.75±0.21
Atherogenic coefficient	4.76±0.34	4.77±0.4

Keywords: COPD, ischemic heart disease, lipoproteins

[Abstract:0441] EPS-178 [Accepted: E-Poster] [Thoracic Surgery]

Placental Transmogrification: Case Report

Gürcan Koşal¹, Sami Ceran¹, Burhan Apilioğulları¹, Barış Sarıçoban¹, Sıddıka Fındık²

¹Department of Chest Surgery, Necmettin Erbakan University Meram School of Medicine, Konya, Turkey

²Department of Pathology, Necmettin Erbakan University Meram School of Medicine, Konya, Turkey

Placental transmogrification of the lung (PTL) is a rare cystic lesion of the lung. It has been so named because it resembles a morphologically immature placental structure, although it does not have the biological and biochemical properties of the placenta. Because it is a rare lesion, we aimed to present our case. The patient who received treatment in the department of chest diseases due to shortness of breath was referred to our clinic when a nodule was seen in the left lung. In the HRCT, a 12 mm nodule was observed in the left lung lingular lobe adjacent to the anterior pleura. In the patient who underwent PET-CT, an increased FDG uptake in the lingula (SUVmax: 2.96) and a nodular lesion that was 14 mm in diameter were observed in the left lung upper lobe. A lymph node which was 12 mm in diameter and which had slightly elevated FDG uptake (SUVmax: 2.71) was observed in the right paratracheal region. The transthoracic biopsy was reported as reactive hyperplasia, chronic inflammation, and fibrotic changes. The patient was operated. The nodule was removed from the left lung anterior region with wedge resection, and was sent to Frozen. It was reported as "Necrotic, small papillary structures were observed on the base. The material was identified as suspicious". After difficult intubation, the operation was terminated because intra-operatively, the lungs were not deflated enough. Postoperative pathology was reported as placentoid bullous lesion (placental transmogrification). The patient was stable during the postoperative period. Regular follow-ups of the patient are continuing. PTL is a very rare lesion and functions as a histologic subtype of bullous emphysema, and coarse bullous emphysema is radiographically found in the same side, and there is no associated nodule in the ipsilateral hemithorax. However, this type of bullous lesions was not seen in our case.

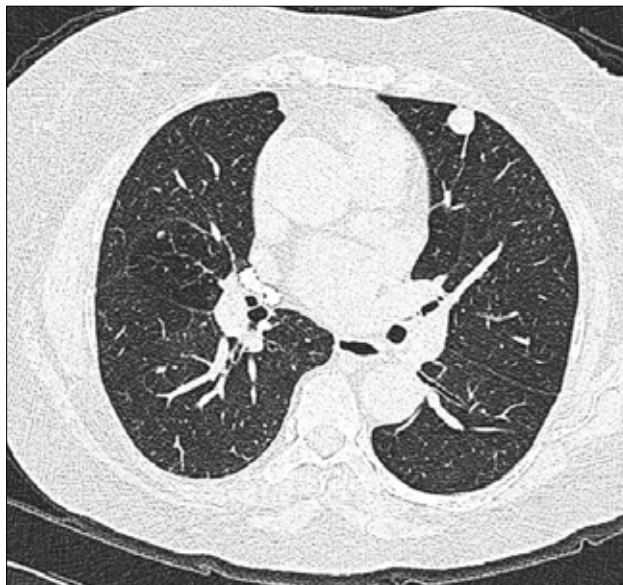


Figure 1. HRCT Section

Keywords: Placental transmogrification, surgery, nodule

[Abstract:0447] EPS-115 [Accepted: E-Poster] [Lung and Pleura Malignancies]

Nineteen-Year-Old Indonesian Tourist

Ece Kaya¹, Ekim Sağlam Gürmen²

¹Department of Chest Diseases, Salihli State Hospital, Manisa, Turkey

²Department of First Aid and Emergency, Salihli State Hospital, Manisa, Turkey

Nineteen-year-old Indonesian male patient came for a trip to Turkey with his mother. It was seen that the person was not breathing before getting off the bus at Salihli Sart Ruins and he was taken to the hospital. Massive hemoptysis occurred in the patient who was brought to the hospital dead. Despite all the interventions made, no response to the treatment was received. Postmortem investigations were performed. AST was 1145, and ALT was 1029. Leukocyte was 24.750, Potassium was 7.40, and Troponin was 0.877. In thorax CT, there were a large number of scattered masses in the bilateral lung parenchyma. In brain tomography; there was a mass in the right parietal lobe. In the abdominal tomography, the patient had a mass in the left testis, LAP in the para-aortic/caval area, and a mass in the right kidney.

Keywords: Indonesia, hemoptysis, tumor

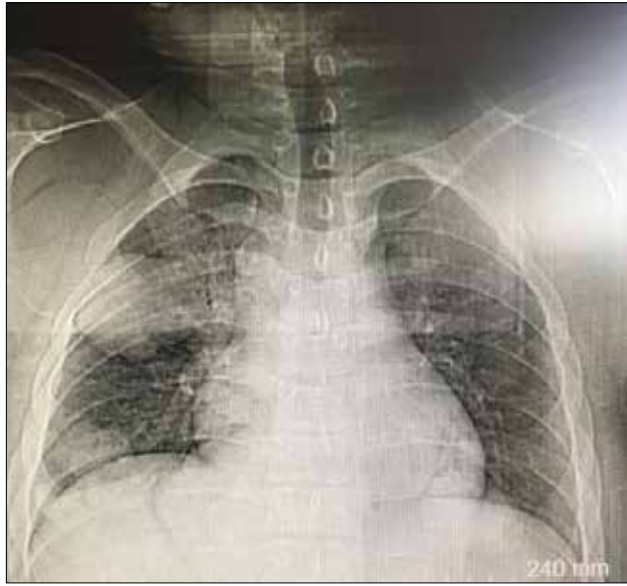

Figure 1. Chest radiogram

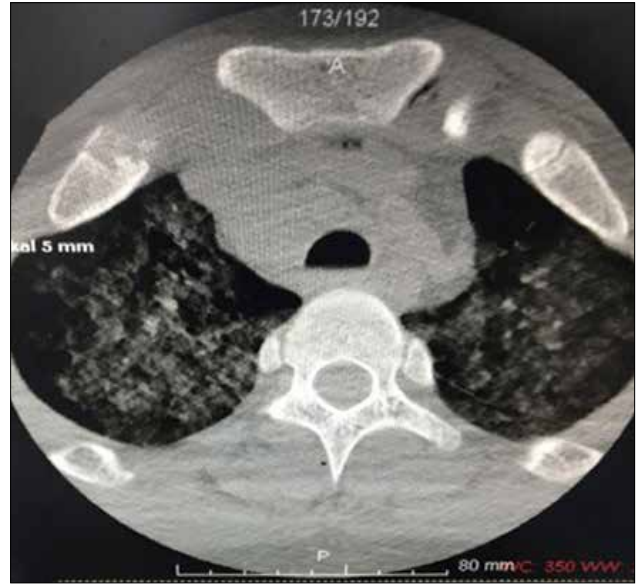

Figure 3. Thoracic CT

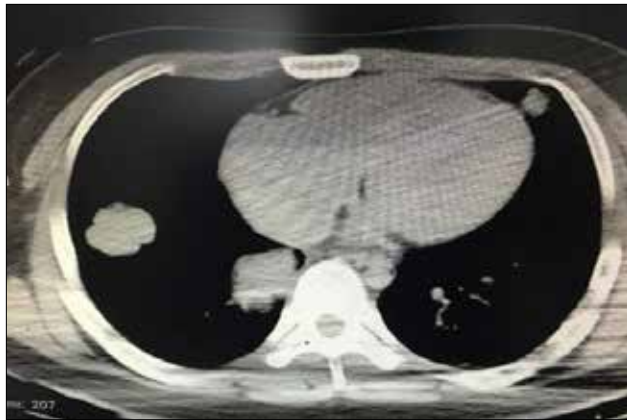

Figure 2. Thoracic CT

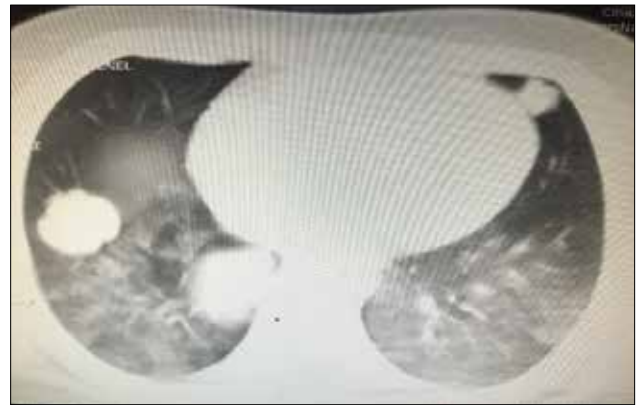


Figure 4. Thoracic CT

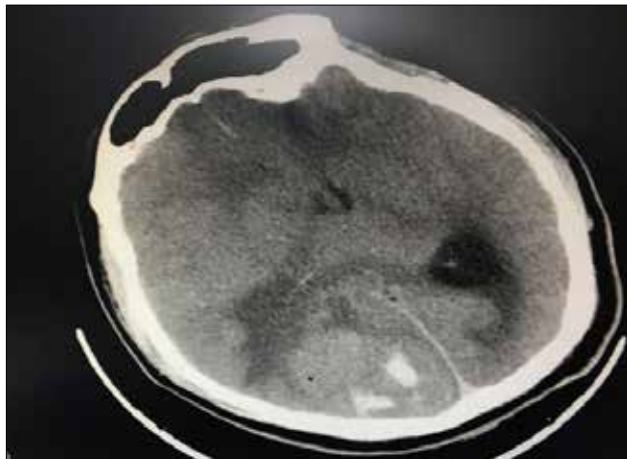


Figure 5. Brain CT

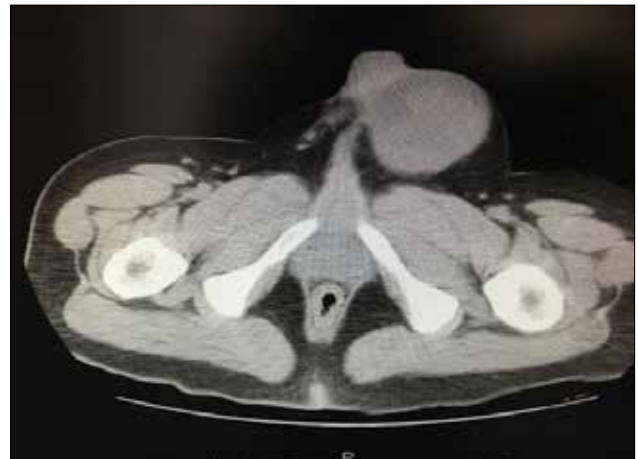

Figure 6. Abdominal CT

[Abstract:0451] PS-039 [Accepted:Poster Presentation] [Clinic Problems - Others]

The Association Between The Low Percentage of Forced Vital Capacity and Increased Mortality After LVAD Operation

Pervin Korkmaz Ekren¹, Serkan Ertugay², Pelin Ozturk², Ali Ozdil³, Sanem Nalbantgil⁴, Cagatay Engin², Tahir Yagdi², Mustafa Ozbaran²

¹Department of Chest Diseases, Ege University School of Medicine, İzmir, Turkey

²Department of Cardiovascular Surgery, Ege University School of Medicine, İzmir, Turkey

³Department of Thoracic Surgery, Ege University School of Medicine, İzmir, Turkey

⁴Department of Cardiology, Ege University School of Medicine, İzmir, Turkey

Objectives: Prior studies identified risk factors for survival in patients implanted artificial heart device. However, the effect of percentage of predictive forced vital capacity (FVC%) is not known on 28 day mortality.

Methods: This retrospective cohort study evaluated patients operated with left ventricular assist device (LVAD) from December 2010 to January 2016. The study population divided into two groups respect to their FVC% (≥ 60 and < 60).

Results: The study involved 131 (111 male, median age was 54 (47-59) years) patients. FVC% < 60 group included 18 patients. There were no significantly different in terms of preoperative parameters between two groups, except of left ventricular end-diastolic diameter. The diameter was significantly larger in FVC% ≥ 60 group ($p=0.036$). Ventilator free day to 28 days was shorter ($p=0.046$), length of intensive care unit (ICU) was longer ($p=0.011$) and 28 day mortality rate was higher (22.2% vs 9.7%, $p=0.12$) in low FVC% group. In multivariate analyses, FVC% < 60 was found as no associated with mortality [OR: 3.96 (95% CI 0.95-16.43), $p=0.058$]. Mortality was independently associated with prior cardiac operation history [OR: 4.40 (95% CI 1.19 – 16.20), $p=0.026$] and tricuspid valve repair at the LVAD operation [OR: 5.30 (95% CI 1.33-21.00), $p=0.018$].

Conclusion: Patients with low FVC% had increased 28 day mortality. Low FVC% was associated with prolonged postoperative ventilation day and ICU stay. These patients should be assessed carefully before the operation.

Keywords: Complications, heart-assist devices, heart failure, mortality, respiratory function rests

[Abstract:0453] EPS-050 [Accepted: E-Poster] [COPD]

Two Cases with Severe COPD of Lansoprazole and Esomeprazole Anaphylaxis with Cross Reactivity to All Proton Pump Inhibitors

Emel Atayık

Department of Immunology and Allergy, Konya Training and Research Hospital, Konya, Turkey

Introduction: Proton Pump Inhibitors (PPI's) are tolerated well. Allergic reactions from a single PPI are rarely reported. Although there is a cross reaction between PPI's, an allergy to all PPI's are quiet rare. Two cases are presented with hypersensitivity to all PPI's.

Case Presentation: A 52-year-old male patient with COPD for 10 years, with an annual emergency application of 5-6 times, hospitalized 3 times. During hospitalization 1 year ago, an increase in breath shortness was seen 5 minutes after oral intake of Lansoprazole, and respiratory arrest developed after urticaria. After CPR, he was followed in intensive care unit (ICU). The patient developing anaphylaxis in the IV esomeprazol again during his hospitalization 6 months ago was monitored in ICU. Drug provocation tests (DPT) were planned. An edema of 6x6mm was observed in the Lansoprazole skin prick test (SPT), esomeprazol SPT 2x3mm was dubiously positive, an edema of 10x10mm was seen in 1/100 intradermal skin test (IDT), and eritem of 35x45mm followed along with itching all over the body.

Pantoprazole DPT and 1/100 IDT were negative. An edema of 5x5mm in 1/10 IDT was followed by a faint eritem. There was urticaria which required intervention 15 minutes after one eighth of the pill was given orally. The tests were considered positive. Oral and parenteral DPT's carried out with Ranitidine and Famotidine as alternative drugs were detected to be negative. At 48 year-old male patients with COPD for 8 years, with an annual emergency application of 5-6 times, hospitalized once. From his history, he was learned to have anaphylaxis after IV pantoprazole was administered 6 months ago. DPT's were planned. An edema of 5x7 was seen in pantoprazole SPT; esomeprazole SPT was negative. An edema of 8x6 was seen in IDT. Eritem of 38x 45 was present. An edema of 12x12 was observed in Lansoprazole SPT. An edema of 3x4 was present in Rabeprazol SPT and 1/100 IDT. Eritem of 20x22 was dubiously positive; an edema of 10x10, eritem and itching all over the body as well as shortness of breath developed in 1/10 IDT. The tests were accepted positive.

Conclusion: PPI drug allergies are rarely reported. It would be a safe approach to choose the patients with allergies to such drugs using alternative drugs through SPT, IDT and oral-parenteral DPT. H2 receptor antagonists can be used as safe alternatives in PPI hypersensitive cases.

Keywords: COPD, drug allergy, proton pump inhibitors, drug provocation test

[Abstract:0456] PS-202 [Accepted:Poster Presentation] [Asthma and Allergy]

A 5-Year Real Life Clinical Usage of Omalizumab: A Single Center Experience

Emel Atayık

Department of Immunology and Allergy, Konya Training and Research Hospital, Konya, Turkey

Objectives: In this study, aim is to demonstrate omalizumab treatments and to evaluate the responses to this treatment.

Methods: The study is a retrospective, single center; 162 patients were included.

Results: 60.5% were women, 67.4% of the patients had chronic urticaria. Allergic severe persistent asthma (ASPA) 19.1%, non-atopic severe persistent asthma (NSPA) 7.4% and multiple food allergies (MFA) 4% were detected. Three patients diagnosed with ABPA, atopic dermatitis and Eosinophilic esophagitis (written consent was taken from the patients without indication) . In ASPA group, the average duration of the disease was 10 years, and the average level of serum total IgE was 140 U/mL. While a statistically significant increase was observed in the mean FEV1 and FVC values in the patients in this group before and during treatment, a statistically significant decrease was observed in their emergency applications, steroid usage, duration and frequency of hospitalization ($p<0.05$ for each) . In NSPA group, the average disease duration was 10 years and the average level of serum total IgE was 45 U/mL. Also in this group, while a statistically significant increase was observed in the mean FEV1 and FVC values in the patients in this group before and during treatment, a statistically significant decrease was observed in their emergency applications, steroid usage, duration and frequency of hospitalization ($p<0.05$ for each) . However, in the patient group with chronic urticaria, the average disease duration was 12 months, the average of serum total IgE was 114 U/mL, the skin prick test was negative in 67.9%. As for the treatments before Omalizumab, 58% used double antihistaminic, 24.8% a combination of antihistaminic, montelukast and oral steroid, whereas a significant decrease was seen in the amount of antihistamine and other treatments after Omalizumab. It was seen that 66.2% never received any treatments after omalizumab. Recurrence was observed in 19 patients after the treatment. During the omalizumab treatment with MFA, an increase was observed in some cases in the consumption of food. Also, a decrease was observed in the severity of allergic reactions based on such food. While the response of the patients with ABPA to omalizumab treatment was accepted as good, the response of the patients diagnosed with eosinophilic eugophasic and atopic dermatitis and treated with omalizumab was considered unresponsive.

Conclusion: According to the results of my study, the omalizumab treatment is understood to be tolerated well by the patients and efficient in ASPA, NSPA, chronic idiopathic urticaria and multiple food allergies.

Keywords: Allergic severe asthma, food allergy, chronic urticaria, nonallergic asthma, omalizumab

[Abstract:0459] EPS-092 [Accepted: E-Poster] [Lung and Pleura Malignancies]

A Case Report of Mucoepidermoid Carcinoma Causing Bronchiectasis

Seray Hazer, Necati Solak, Selim Şakir Erkmen Gülhan, Gülşen Yılmaz, Ebru Sayılır Güven

Department of Chest Surgery, Atatürk Chest Diseases and Chest Surgery Training and Research Hospital, Ankara, Turkey

Mucoepidermoid carcinomas are malignant tumors which arise from the submucosal bronchial glands, which are rarely seen in the tracheobronchial system, which constitute 0.1-0.2% of primary lung tumors and whose etiology is unknown. Although it can be seen in all ages (3-78 years) , 50% of them are observed under 30 years of age, and most of them in the 3rd-4th decades. In this study, a case of mucoepidermoid carcinoma, which is very rarely seen in the tracheobronchial system and causes bronchiectasis, has been presented in the light of the literature.

Bronchiectasis was detected in the right lower lobe of the 41-year-old male patient in whom thoracic CT was taken due to the complaints of coughing and sputum. After endobronchial lesion (EBL) which completely obstructed the entry of the right lower lobe basal segments was observed in the bronchoscopy of the patient who had no additional diseases, multiple bronchial biopsies were taken and the pathology was reported as bronchial mucosa with inflammatory changes. Lower lobectomy and lymph node dissection were performed with right thoracotomy in the patient. The drains of the patients were removed and he was discharged on the 7th postoperative day. In the pathological examination of the patient, a 2.5x1.5 endobronchial and smooth-surface nodular lesion was evaluated as low grade mucoepidermoid carcinoma, bronchiectatic lower lobe and reactive anthracotic lymph nodes number 4, 7, 8, 10, 11. CT and RT were not applied after discharge. The patient was alive in the first postoperative year and no recurrences were observed. Mucoepidermoid carcinomas of the tracheobronchial system are rarely seen tumors which constitute 0.1-0.2% of all lung malignancies, grow slowly and whose etiology is unknown. Clinically, it can be confused with foreign body aspiration or asthma like other endobronchial carcinomas. PA chest X-ray findings may be normal, but they may also vary from nodular mass to pneumonic consolidation or atelectasis. Tumor grade, the age of patient, TNM staging and the localization of tumor are important in determining the prognosis. Low grade mucoepidermoid tumors may remain asymptomatic for years. Conservative surgical treatment is preferred for low grade tumors. Regional lymph node metastasis was observed in less than 5% of these tumors. Our 41-year-old case consulted with the complaints of cough and sputum, and with the symptoms of bronchiectasis. Mucoepidermoid carcinoma was detected in right lower lobectomy performed in the patient in whom EBL was found in preoperative bronchoscopy but no diagnosis could be made through biopsy. It should be kept in mind that patients with bronchiectasis may have endobronchial lesions and should be evaluated by preoperative bronchoscopy. In this study, a case of mucoepidermoid carcinoma, which is very rarely seen in the tracheobronchial system and causes bronchiectasis, has been presented in the light of the literature.

Keywords: Bronchiectasis, mucoepidermoid carcinoma, endobronchial lesion

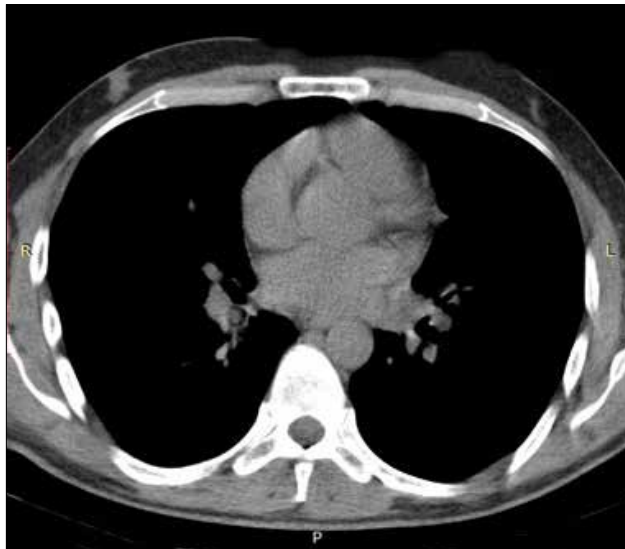

Figure 1. Thoracic CT: Endobronchial lesion

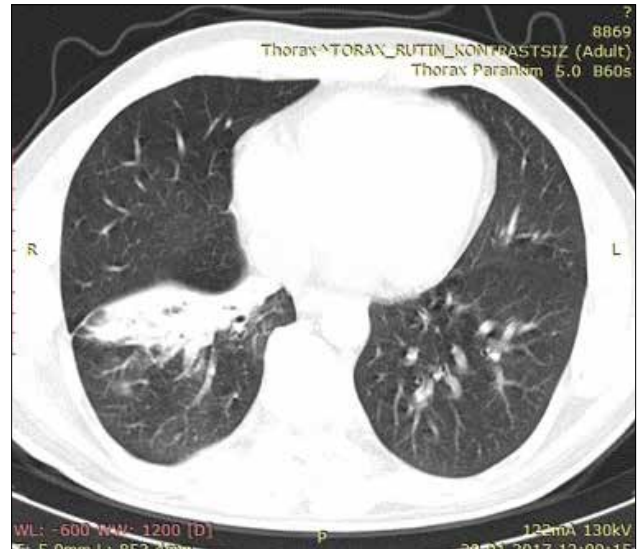
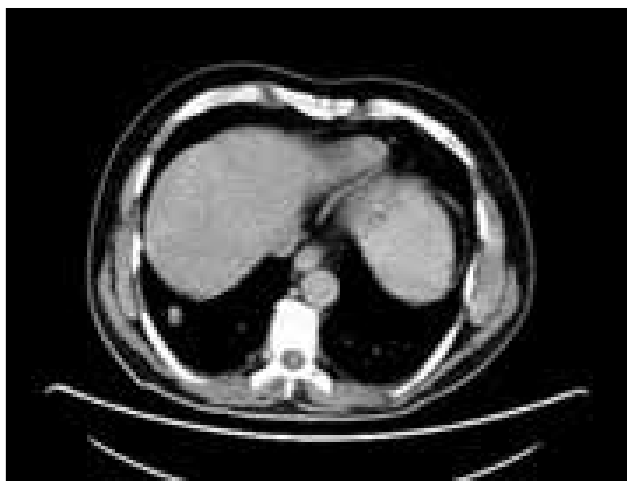
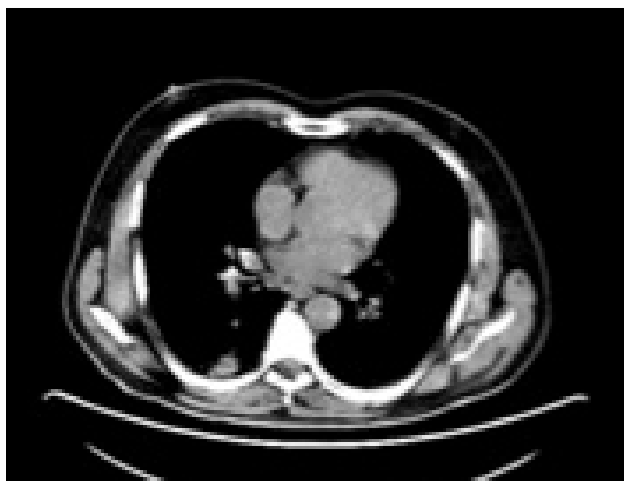


Figure 2. Thoracic CT: Pneumonic consolidation and bronchiectasis

[Abstract:0460] EPS-080 [Accepted: E-Poster] [Lung and Pleura Malignancies]**Two Different Lung Tumors in the Same Lobe:
Adenosquamous Carcinoma**Selim Şakir Erkmen Gülhan¹, Necati Solak¹, Seray Hazer¹, Funda Demirağ²¹Department of Chest Surgery, Atatürk Chest Diseases and Chest Surgery Training and Research Hospital, Ankara, Turkey²Department of Pathology, Atatürk Chest Diseases and Chest Surgery Training and Research Hospital, Ankara, Turkey

It is agreed that multiple primary lung cancer was first described by Beyretuther in 1924. Synchronous tumors are used to express a different primary lung cancer at the time of diagnosis. Although the incidence is reported to be 2% (0.8-14.5%) in various sources, and because of the reasons such as the development of imaging techniques, the early diagnosis of lung cancer and the modernization of surgical and other treatment modalities; the lifespan of the patients with lung cancer increases, and it is thought that the incidence of curative treatment is increasing. A 63-year-old male patient was admitted with the complaint of cough. A 3,3 cm nodular lesion was found in the superior lower lobe of the right lung and a 1,6 cm nodular lesion was found in right lung lower lobe posterobasal segment. Thereupon, the patient underwent right thoracotomy lower lobectomy, number 2.4.7.9.11 lymph node dissection and apical bullae excision. Two different tumoral masses were detected in the macroscopic pathology of the lobectomy material. One of the masses is located in the superior segment and its long diameter is 3.7 cm. The tumor in this region is composed of keratinized type squamous cell carcinoma that shows P63, P40 and keratin 5/6 positivity and has sporadic translucent-cell changes, accompanying TTF-1 negative adenocarcinoma showing Focal Napsin A and mucin positivity. The visceral pleura invasion was evaluated in verhoeff elastic stain, and the tumor infiltrated the visceral pleura and exceeded the elastic membrane. The second tumor is located on the diaphragmatic surface and has a long diameter of 2.1 cm. The tumor is composed of napsin A negative adenocarcinoma which is located in an inflamed lymphocyte-rich stroma, whose keratinization is observed in a small area with a non-keratinized large part, which shows P40 positivity, and mucin and keratin 7 positivity with a special staining. Both tumors are in the morphology of adenosquamous carcinoma. Because of the fact that the tumor in the superior segment had more diffuse keratinization and translucent-cell changes, that the stroma of the tumor on the diaphragmatic side had intense inflammation, that the squamous cell carcinoma component was nonkeratinized in large areas, and because of Napsine A positivity, both tumors were thought to be synchronous primer lung tumors. When a synchronous tumor diagnosis is made, the approach to patient and the surgery to be performed change depending on whether the tumor is in the same or opposite lung and on the the respiratory reserve of the patient. Lobectomy, bilobectomy, and pneumonectomy are recommended in the synchronous tumors detected in the same lung, and in bilateral tumors, sequential surgical resection is recommended with 4-6 week intervals in those with higher staging. In our case, two different tumors were detected in the superior and posterobasal segments of the right lower lobe. It should be kept in mind that if a different nodule is detected in the patients who are followed up for lung cancer, it may be a synchronous lung tumor. An adenosquamous carcinoma case with two different lung tumors in the same lobe has been presented in this study.

Keywords: Adenosquamous carcinoma, synchronous lung tumor, two different tumors in the same lobe**Figure 1.** Thoracic CT: nodule in the posterobasal segment of the right lower lobe**Figure 2.** Thoracic CT: nodule in the superior of the right lower lobe

[Abstract:0464] PS-019 [Accepted:Poster Presentation] [Clinical Problems - Diffuse Parenchymal Lung Disease]

A Case of 'Acute Fibrinous and Organizing Pneumonia' (AFOP) : A Rarely Seen Interstitial Lung Disease

Yağmur Kaptan¹, Recep Savaş², Deniz Nart³, Özen Kaçmaz Başoğlu¹, Özen Kaçmaz Başoğlu¹, Nesrin Moğulkoç¹

¹Department of Chest Diseases, Ege University School of Medicine, İzmir, Turkey

²Department of Radiology, Ege University School of Medicine, İzmir, Turkey

³Department of Pathology, Ege University School of Medicine, İzmir, Turkey

'Acute Fibrinous and Organizing Pneumonia' (AFOP) is a newly defined and rarely seen idiopathic interstitial pneumonia. It is a diagnosis which is elusive to make and overlaps with other lung pathologies. Here we submit a case of AFOP. A 74-year-old man complaining of a productive cough and dyspnea was investigated outwith our hospital. He was given an antibiotic for the provisional diagnosis of pneumonia. Having observed extensive bilateral infiltration on his chest x-ray, the diagnosis was amended to organizing pneumonia. Treatment was started with cortisone, after which the patient was referred to our hospital. During his inpatient stay, the patient was investigated. On physical examination, bibasilar fine crackles were auscultated. The chest radiograph showed extensive bilateral reticular infiltrates. However, he was not febrile and there were no raised laboratory markers of infection, so there was no indication to use antibiotic and the dosage of the cortisone for interstitial lung diseases was reduced. An underlying rheumatological disease was excluded. In response to continuing radiological deterioration, fiberoptic bronchoscopy with transbronchial lung biopsy (TBLB) and bronchoalveolar lavage (BAL) was undertaken. A BAL neutrophilia >30% was detected. No micro-organisms were identified on culture of BAL fluid. The

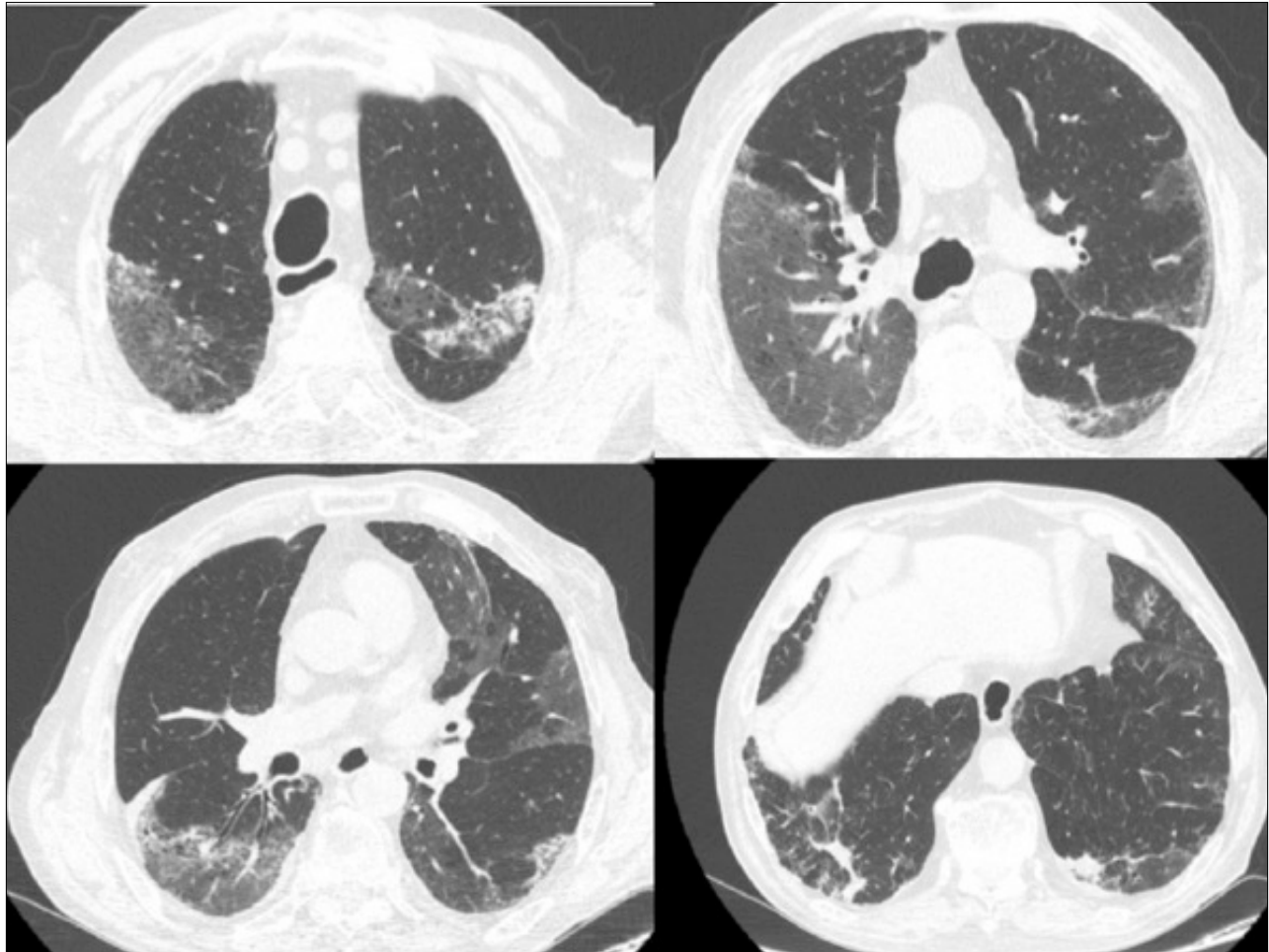


Figure 1.

transbronchial lung biopsy was reported as compatible with infection. On high resolution computed tomography, in the upper and lower lobes of both lungs, newly-apparent, peripherally localized, ground glass opacities, within which there were millimetre-size cystic conglomerations, were reported to be possibly consistent with the diagnosis of AFOP (Figure 1) . Symptomatically, the patient, whose methylprednisolone dosage was being increased, improved. Additionally, there was regression of the infiltrates on his chest radiography. Acute Fibrinous and Organizing Pneumonia is characterized by an extensive intra-alveolar accumulation of fibrin. It is an idiopathic interstitial lung disease, which can lead to acute pulmonary damage. Characterised by a sudden onset and rapid progression, AFOP has diverse clinical presentations and, therefore, should be considered in the differential diagnosis of idiopathic interstitial pneumonia.

Keywords: Fibrinous, organizing pneumonia, interstitial

[Abstract:0466] EPS-009 [Accepted: E-Poster] [Clinic Problems - Others]

The Effect of Clinical Findings on One-Year Course of the Disease in Adult Bronchiectasis Patients with Noncystic Fibrosis

Melihat Bekir¹, Sehnaz Olgun Yıldızeli², Derya Kocakaya², Berrin Ceyhan²

¹Department of Chest Diseases, Okan University School of Medicine, İstanbul, Turkey

²Department of Chest Diseases, Marmara University School of Medicine, İstanbul, Turkey

Objectives: A significant number of studies have been conducted in recent years on patients with noncystic fibrosis bronchiectasis. We have limited knowledge about long-term clinical course and the factors leading to deterioration in patients. We aimed to determine the effects of clinical, functional, psychological and microbiological factors on one-year disease progression in adult patients with noncystic fibrosis bronchiectasis.

Methods: Forty-five cystic non-bronchial hypertrophic patients were included in the study. FACED and BSI severity scores, and HADS scores were initially assessed. Demographic information, clinical examination, hospital admission rate, microbiological examination, quality of life questionnaire and respiratory function tests were evaluated at the beginning and one year later.

Results: Of the 55 patients (29 F/26 M, mean age: 45±17 years) , 42 (76%) had extensive disease and 13 (23%) had local disease. Twenty-one patients (38%) had anxiety, 26 (47%) patients had depression, and these were not related to disease severity. Six (11%) patients had newly defined comorbidities and 14 (25%) patients had new respiratory drug additions. In one year, a decline was detected in FVC from 2.8±1.0 L to 2.5±1.0 L (p:0.000) and from 1.97±0.97 L/s to 1.4±0.6 L/s (p:0.000) in FEV1. Pseudomonas reproduction in sputum was found to be associated with the decline in FVC (p:0.036) . However, the hospital admission rate decreased from 39/55 (71%) to 10/55 (18%) in one year (p:0.000) . In the quality of life questionnaire, respiratory scores decreased from 68.0±26.8 to 54.4±26.8 (p:0.008) and respiratory treatment scores increased from 44.4±23.6 to 57.0±29.1 (p:0.023) .

Conclusion: Although the decline in respiratory function tests and the increase in respiratory scores in the quality of life questionnaire, the decline in hospital admission rate in the last one year can be discussed. Close follow-up and appropriate treatment at the reference center in this period may have reduced the hospital admission rate. Future studies will focus on disease-specific treatment strategies in centers specialized in bronchiectasis patients.

Keywords: Bronchiectasis, quality of life, respiratory function tests

[Abstract:0468] PS-312 [Accepted:Poster Presentation] [Respiratory Infections]

Acute Respiratory Distress Syndrome and Polyneuropathy due to H1N1 Virus: A Case Report

Mihrican Yeşildağ¹, Hanife Cüce²

¹Department of Chest, BU Konya Education and Research Hospital, Konya, Turkey

²Department of Intensive Care, SBU Konya Training and Research Hospital, Konya, Turkey

Introduction: While H1N1 Virus may be asymptomatic in healthy individuals, it may be fatal in children, elderly people, pregnant women and those with underlying chronic diseases. We aimed to present a young, diabetic patient with acute respiratory distress syndrome (ARDS) and polyneuropathy due to H1N1 virus in terms of early diagnosis and treatment approaches.

Case Presentation: A 46-year-old female patient was admitted to our clinic with the complaints of fever, cough, and shortness of breath. She had diabetes in her history and her blood pressure 100/60 mmHg, body temperature 38.4°C, respiratory rate 35/min, Nb 100/L, glucose 208mg/L, LDH658U/L, CRP146 mg/L, arterial blood gas pH 7.43, pCO₂ 32.1 mmHg, pO₂ 47.1 mmHg, HCO₃ 22 mmol/L, SaO₂ 82.3%. Pulmonary widespread bilateral alveolar infiltrations were present on chest X-ray. Thorax CT showed widespread bilateral patch consolidation areas and consolidation areas containing air bronchograms. Nasopharyngeal specimens was obtained by PCR method at the hospital admission. Considering the viral pneumonia in the patient, a broad spectrum antibiotic and oseltamivir treatment was started empirically. Non-invasive mechanical ventilation (NIMV) was initiated and the patient was taken to intensive care with the decline in saturation values in a short span of time. Invasive mechanical ventilation (IMV) was initiated by considering ARDS for the reason that the saturation of the patient did not increase and the NIMV and PaO₂/FiO₂ ≤200. H1N1 virus were detected in her respiratory viral culture. In her EMC, bilateral sensory axonal polyneuropathy was noted in the patient. That she was initiated oseltamivir treatment on the first day

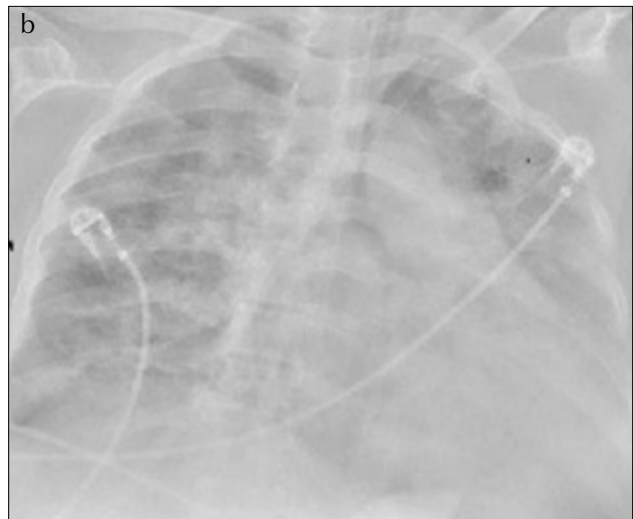
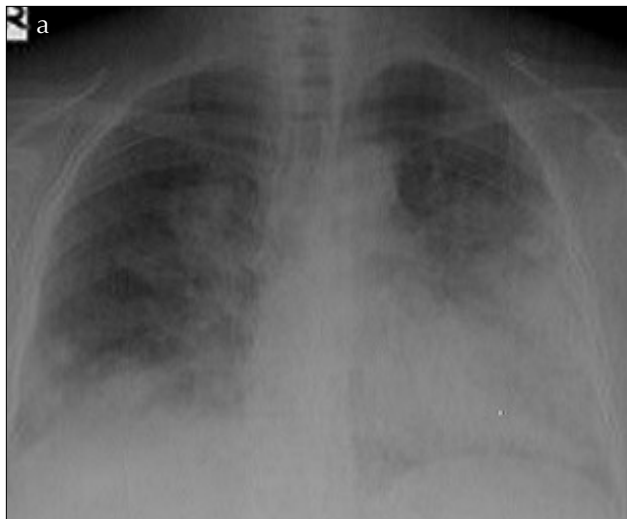
Figure 1. a, b. Initial Chest X-ray shows widespread bilateral pulmonary alveolar infiltrations (a). After five days Chest X-ray shows widespread bilateral pulmonary alveolar infiltrations (b)

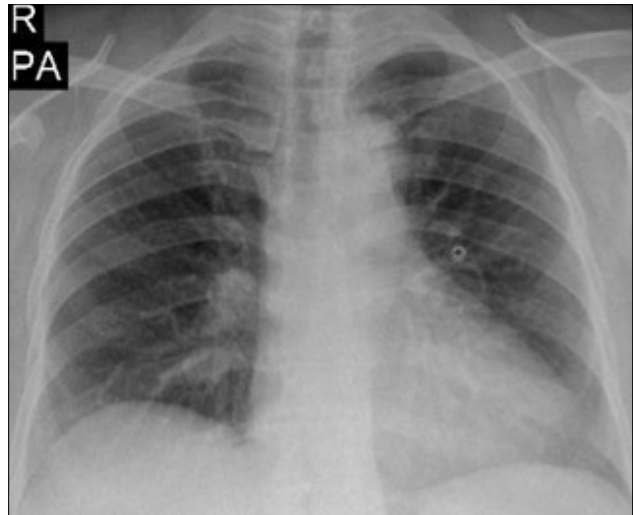
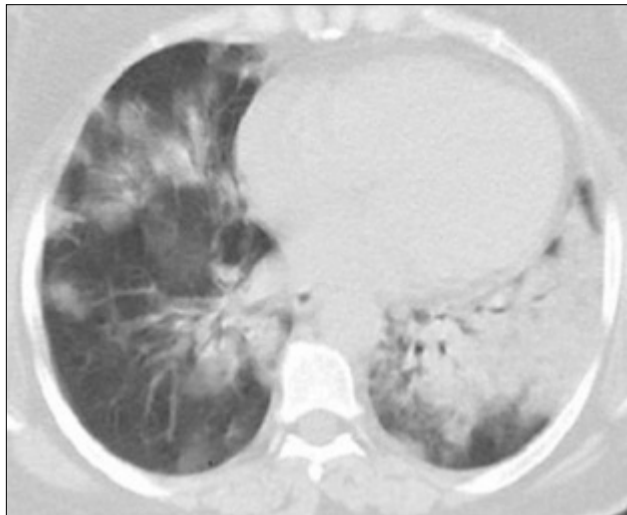


Figure 2. Thorax CT shows widespread bilateral patch consolidation areas and consolidation areas containing air bronchograms

Figure 3. Control Chest X-ray

and early intensive care support helped the patient get rid of ARDS situation. She was admitted to the physiotherapy program on account of polyneuropathy.

Discussion: The most frequent cause of intensive care hospitalization and death due to H1N1 virus is respiratory failure and ARDS. Among the neurological complications related to H1N1 virus are loss of consciousness, convulsions, encephalopathy, paralysis, and polyneuropathies. Studies have shown that there is a correlation between the elongation of the clearance of nasopharyngeal influenza viral RNA load and the severity of the disease and it was observed that a rapid decrease in viral load from the first day of oseltamivir initiation. These findings suggest that early onset antiviral therapy alters the course of the disease. We share the idea that early oseltamivir treatment and early mechanical ventilation support are important in the clinical improvement of our patient and in the emergence of the ARDS situation.

Keywords: ARDS, H1N1 Virus, polyneuropathy

[Abstract:0470] SS-069 [Accepted:Oral Presentation] [Health Policies]

What Has Changed in Respiratory System Drugs in the Last 4 Years?

Sedat Altın¹, Ethem Ünver², Handan Altın¹

¹Health Sciences University Yedikule Chest Diseases and Surgery Research and Education Hospital, İstanbul, Turkey

²Department of Chest Diseases, Erzincan University School of Medicine, Erzincan, Turkey

Objectives: Respiratory disease burden and mortality rates are gradually increasing. With the increase in the number of drug boxes used in the last 4 years, this increase was aimed to compare with disease burden and mortality rates.

Methods: 2014 and 2016 were compared using data from TUIK death statistics and health surveys using IMS drug box sales in 2014-2017.

Results: In 2016, the number of deaths due to respiratory system diseases increased by 19.4% to 48.532 by 2014. Again according to the Health Survey report in 2016, asthma-COPD disease burden has reached 15.6%.

In 2014, while 220 million boxes of respiratory system drugs were sold, this which increased by 26 % reached 267 million boxes in 2017. In 2014, total sales of R Class IMS data reached 53,794,671 boxes, which increased by 36.5% to 73,475,070 boxes. 34.4 million boxes of inhaler market in 2014 increased by 39.4% to 47.4 million boxes in 2017. It is noteworthy that the greatest increase is inhaler group with 75%, dry powder with 36.3% and nebul group with 17.6%. The highest increase in box sales was in short-acting combined bronchodilators with 108.4%, followed by 90.7% inhaler steroids and the least increase in combination with 16.4% (LABA-ICS) . Formoterol-Budesonide was found in 47% of the LABA-ICS combinations, Salmeterol-Fluticasone in 40%, Bekamethazone in 9% and Vilanterol-Fluticasone fumarate in 4%.

Conclusion: Drug consumption in 2017, according to the year 2014, continues to rise independently of disease burden and mortality was determined. The fact that the increase occurred in short-acting bronchodilators, which we used as the most salvage medication, also indicates incompatibility with guidelines.

Keywords: Drug box sales, disease burden, inhaler market

[Abstract:0472] PS-100 [Accepted:Poster Presentation] [Pulmonary Rehabilitation and Chronic Care]

Relationship Between the Cognitive Status and Functional Capacity, Physical Activity in Lung Cancer Patients

Kübra Kılıç¹, Naciye Vardar Yağlı¹, Melda Sağlam¹, Ebru Çalık Kütükcü¹, Hülya Arıkan¹, Deniz İnal İnce¹, Saadettin Kılıçkap²

¹Department of Physiotherapy and Rehabilitation, Hacettepe University School of Health Sciences, Ankara, Turkey²Department of Medical Oncology, Hacettepe University School of Medicine, Ankara, Turkey

Objectives: Mild cognitive dysfunction may be seen in lung cancer survivors. There are studies showing that physical activity has a positive effect on cognitive function. The purpose of the study was to investigate the relationship between cognitive function and functional capacity, physical activity in lung cancer patients.

Methods: Thirty patients with lung cancer (24 males, 6 females mean age=62.6±7.32 years) were included in the study. Cognitive status were assessed using Montreal Cognitive Assessment (MoCA) Scale. Functional capacities were measured with a six-minute walking test (6MWT) . Physical activity was assessed by the International Physical Activity Questionnaire (IPAQ) .

Results: The MoCA score was related with the 6 MWT distance ($r=0.321$, $p=0.083$) and the IPAQ total score ($r=0.390$, $p=0.033$) .

Conclusion: This study suggests that increased functional capacity and physical activity levels in lung cancer patients lead to better cognitive status levels. In order to reduce the side effects of treatment on cancer survivors, the importance of physical activity should be explained to patients.

Keywords: Cognition, exercise test, lung neoplasm, physical activity

[Abstract:0473] PS-052 [Accepted:Poster Presentation] [Lung and Pleura Malignancies]

The Role of Fluorodeoxyglucose Positron Emission Tomography/Computed Tomography Differential Diagnosis of Malignant-Paramalignant Pleural Effusion

Elif Torun Parmaksız, Bülent Akkurt, Coşkun Doğan, Seda Beyhan Sağmen, Nesrin Kırıl, Sevda Cömert, Ali Fidan, Saadet Akkuş

Department of Chest Diseases, İstanbul University of Health Sciences, Kartal Dr Lütfi Kırdar Training Hospital, İstanbul, Turkey

Objectives: Pleural effusion is a crucial problem in cancer patients as it adversely effects stage and prognosis and alters treatment. Differentiation of malignant and paramalignant fluid bears great importance. We aimed to evaluate the diagnostic utility of PET-CT in differential diagnosis of malignant pleural effusion.

Methods: The patients with pleural effusion and histologically proven cancer who underwent PE T-CT were prospectively studied. Thoracentesis was performed for all cases for measurement of biochemical parameters including glucose, LDH, albumin, total protein and pH. Serum concentrations of same parameters were synchronously measured. Pleural fluids were cytopathologically analysed.

Results: The study population consisted of 30 female and 39 male patients with a mean age of 63.55 (37-88) . The definitive diagnosis of malignant pleural effusion was confirmed by cytopathological analysis. In 16 cases, effusion was considered as paramalignant due to absence of malignant cells in cytopathological analysis and by clinical assessment and follow-up. Biochemical test results of malignant and paramalignant fluids is shown in Table 1. Fluid characteristics with respect to tumour types is shown in Table 2. The mean SUVmax was 1.43 in paramalignant effusions and 1.5 in malignant effusions, the difference was not statistically significant. Malignant cells were detected in fluids with no FDG uptake in 13 lung cancer, 3 mesothelioma, 2 breast cancer, 2 colon cancer, 1 ovarian cancer, 1 gastric cancer and 1 endo-

Table 1. The laboratory findings in paramalignant and malignant pleural effusion

	Paramalignant fluid	Malignant fluid	p
n	16	53	
Fluid protein	3.85	4.28	0.07
Fluid albumin	2.13	2.49	0.06
Fluid LDH	219	563	<0.001
Fluid glucose	135	106	0.015
Fluid pH	7.42	7.37	0.05
LDH ratio	1.01	1.99	0.003
Protein ratio	0.55	0.67	0.004
Albumin gradient	1.46	0.92	0.004
Fluid SUVmax	1.43	1.5	0.89

Table 2. The pleural fluid findings in different malignancies

	Fluid protein	Fluid albumin	Fluid LDH	Fluid glucose	Fluid pH	LDH ratio	Protein ratio	Albumin gradient
Lung	4	2.25	549	112	7.36	1.88	0.65	1.18
Breast	4.35	2.69	413	23	7.41	1.39	0.64	1.01
Mezothelioma	4.81	2.81	420	102	7.34	2.29	0.69	0.72
Ovarian	3.88	2.21	267	100	7.42	1.07	0.58	0.8
Colon	4.14	2.38	835	87	7.33	2.71	0.62	1.05
Gastric	4.56	2.52	386	96	7.67	1.91	0.65	1.04
Bladder	4.33	2.51	522	190	7.27	1.89	0.71	0.65
Lymphoma	2.92	1.13	440	124	7.47	0.78	0.45	2.01
Cervix	3.65	2.06	887	58	7.3	0.93	0.59	0.94
Soft tissue	5.08	3.08	302	86	7.37	1.80	0.73	0.92
Ewing sarcoma	4.02	2.68	238	102	7.56	1.17	0.6	1.32
Uterus	4.95	2.81	431	101	7.38	2.5	0.69	0.29
Rectum	3.11	1.77	202	138	7.50	0.73	0.43	1.63

metrium cancer cases. The sensitivity of PET-CT in malignant pleural effusion is found to be 56.6%, specificity 50%, positive predictive value 78.9% and negative predictive value 25.8%.

Conclusion: The efficacy of PET-CT in differential diagnosis of malignant-paramalignant pleural effusion is of limited value. Therefore, cytopathological analysis plays a major diagnostic role in diagnosing malignant effusion.

Keywords: Malign pleural effusion, PET-BT, cancer, paramalignant effusion

[Abstract:0475] PS-281 [Accepted:Poster Presentation] [Sleep-related Disorders]

The Distributions and Importance of Respiratory Events in the Patients with Severe Obstructive Sleep Apnea (OSA)

Esra Akman, Banu Eriş Gülbay, Turan Acıcan

Department of Pulmonary Disease, Ankara University School of Medicine, Ankara, Turkey

Objectives: The apnea hypopnea index that means predominantly obstructive respiratory events (apneas, hypopneas or RERAs) per hour of sleep during a PSG in the diagnostic criteria of obstructive sleep apnea (OSA) is used. However, in this definition, the effects of the excess of the patient's apnea or hypopnea on the current OSA and OSA results are unknown.

Methods: We retrospectively reviewed the files and polysomnography records of 81 (70 M/ 11 F) severe OSA patients who underwent polysomnography between 2012 and 2013. Patients were divided into two groups as the total apnea numbers> the total hypopnea numbers (group 1) , the total hypopnea numbers> the numbers of total apnea (group 2) . We compared comorbidities, and polysomnographic findings of the patients.

Results: There were 71 patients (10F/61M) in group 1 and 10 patients (1F/9M) in group 2. The mean age of the patients was higher in group 2 ($p=0.031$) . There was no difference in gender distribution ($p=0.592$) . Although, there were no statistically significant difference in terms of sleep architecture including total sleep time and the distribution of sleep stages between two groups, the sleep efficiency is lower in the group 2 ($p=0.01$) and the WASO is lower in the group 1 ($p=0.01$) . In the apnea dominant OSA group, the total AHI ($p = 0.025$) was higher. And, the mean apnea duration were higher in NREM stages of the patients with group 1 ($p = 0.012$) . While the mean hypopnea number was higher in the hypopnea dominant OSA group ($p<0.01$) , there were no difference in terms of the mean hypopnea duration both NREM and REM sleep stages (p ; 0.708 0.785, respectively) between the two groups. The total ODI was higher in the group 1 ($p=0.029$) , there were no statistically significant difference in terms of average oxygen saturation (SpO₂) , minimum SpO₂, and % of nocturnal oxygen

desaturation (p ; 0.669, 0.272, 0.193, respectively) between two groups. In group 1, the mean nighttime heart rate was higher in NREM and REM sleep (p : 0.570, 0.615, 0.980, respectively). Despite the shortcomings in the file information, the additional disease (15 patients) in the apnea dominant OSA group was significantly higher than that in the hypopnea dominant OSA group (5 patients).

Conclusion: Our study showed that patients with apnea dominant OSA had a heavier OSA and had more comorbidities at an earlier age, although the distribution of patients was not equal.

Keywords: Obstructive sleep apnea (osa), apnea hypopnea index (ahı), apnea dominant osa, hypopnea dominant osa

[Abstract:0477] PS-096 [Accepted:Poster Presentation] [Pulmonary Rehabilitation and Chronic Care]

Evaluation of Respiratory Muscle Endurance in Lung Cancer Patients

Kübra Kılıç¹, Naciye Vardar Yağlı¹, Melda Sağlam¹, Ebru Çalık Kütükcü¹, Deniz İnal İnce¹, Hülya Arıkan¹, Saadettin Kılıçkap²

¹Department of Physiotherapy and Rehabilitation, Hacettepe University School of Health Sciences, Ankara, Turkey

²Department of Medical Oncology, Hacettepe University School of Medicine, Ankara, Turkey

Objectives: Respiratory symptoms are seen in lung cancer survivors. Respiratory muscle endurance more accurately reflects respiratory muscle function. The purpose of this study was to evaluate respiratory muscle endurance in lung cancer patients and to compare healthy people.

Methods: Thirty lung cancer patients (24 males, 6 females mean age= 62.66±7.32 years) and 30 healthy people (24 males and 6 females, mean age = 59.86±5.99 years.) Power Breathe device was used to evaluate the respiratory muscle endurance. The respiratory muscle endurance test was performed with the resistance given at 60 % of the maximal inspiratory pressure (MIP) value of the people. The endurance value was recorded in snxcmH₂O.

Results: The endurance value of the lung cancer patients and healthy people were 3897.5±4387.69 snxcmH₂O and 8022.76±6906.47 snxcmH₂O respectively. There was a statistically significant difference in respiratory muscle endurance value between lung cancer and healthy subjects ($p=0.005$).

Conclusion: Respiratory muscle endurance values in lung cancer patients are lower than healthy people. The respiratory muscle endurance test should be added to the evaluation parameters for effective rehabilitation programs.

Keywords: Lung neoplasm, respiratory muscle, survivors

Abstract:0478] SS-039 [Accepted:Oral Presentation] [RespiratoryInfections]

The Rates of Influenza and Pneumococcal Vaccinations in Patients Hospitalized due to Acute Respiratory Insufficiency

İpek Candemir, Sema Türk, Merve Şahin, Pınar Ergün, Dicle Kaymaz

Atatürk Chest Diseases and Chest Surgery Training and Research Hospital, Ankara, Turkey

Objective: Knowledge on the effect of influenza and pneumococcus vaccinations on the prevention of mortality and morbidity in cases with chronic respiratory distress has increased. However, the rates of vaccination are low in adult age group in our country. In this study, it was aimed to investigate vaccination rates and factors affecting them in patients hospitalized due to acute respiratory insufficiency.

Methods: A total of 98 patients who were hospitalized in the chronic respiratory insufficiency clinic due to acute respiratory failure between November 2017 and January 2018 were applied a questionnaire. Their ages, diagnoses, educational status, reasons for hospitalization, histories of vaccination, information sources on vaccination, and thoughts were recorded.

Results: Of the patients, whose mean age was 67 ± 12 years, 45 were (46%) female and 52 were (53%) male. While 77 (79%) patients had primary lung disease, 16 (17%) patients had primary cardiac disease and one had respiratory failure secondary to neuromuscular diseases. 72 patients with lung disease (74%) had a diagnosis of COPD. In 28 (38%) of COPD patients, coexisting cardiac disease was observed. 13 (18%) were diagnosed with DM. In COPD patients, the median FEV1 was 36% of the expected value (13:91), FVC was 42% (16:99) and the ratio was 70 (30:70). Considering the reasons for hospitalization, 40 patients (41%) were hospitalized for infection, 41 patients for acute respiratory failure developing due to non-infectious reasons, and 15 (15%) patients for PTE. It was learned that 26 of 98 patients (26%) was vaccinated for influenza in the last year and 17 (17%) were vaccinated for influenza regularly within the last five years. While 15 patients (15%) was performed polysaccharide pneumococcal vaccination (PPSV23) in the last 5 years, conjugate pneumococcal (PCV13) vaccination was not performed in any patient. In patients with the diagnosis of COPD, 22 (30%) patients were performed influenza vaccine, but 12 (17%) were performed PPSV23. Information sources for vaccines were physician in 41 cases (42%), health staff except physician in 5 (5%), media in 7 patients (7%), and relatives and friends in 7 cases (7%). No statistically significant difference was observed between hospitalization due to infection and non-infection indications and vaccination of influenza and/or pneumococcal. Of the patients, 53 (54%) were primary school graduates, but there was no significant relationship between educational status and vaccination. It was found that 29 patients (30%) believed in the benefit of vaccination, 51 (52%) did not believe its benefit, and 17 (17%) had no exact information about the subject.

Conclusion: In our study, the rates of influenza and pneumococcal vaccination were found to be similar to those in literature and they were low. Individuals under risk should be informed by health professionals much more and their vaccines should be prescribed by their physicians.

Keywords: Acute respiratory insufficiency, influenza and pneumococcal vaccines, vaccination rates

[Abstract:0482] SS-040 [Accepted:Oral Presentation] [Respiratory Infections]

Phagocytic Ability of Granulocytes and Monocytes in Elderly Patients with Community Acquired Pneumonia

Elif Torun Parmaksız¹, Ali İnal², Benan Çağlayan³, Coşkun Doğan¹, Ali Fidan¹, Nesrin Kırıl¹, Sevda Cömert¹

¹Department of Chest Diseases, University of Health Sciences, Kartal Dr Lütfi Kırdar Training and Research Hospital, İstanbul, Turkey

²Department of Immunology, Başkent University İstanbul Hospital, İstanbul, Turkey

³Department of Chest Diseases, Koç University Hospital, İstanbul, Turkey

Objectives: Pneumonia is an infectious disease of the lung, usually presented with symptoms including cough, fever, dyspnea. The severity of the disease ranges from mild to severe and in some cases it leads to serious organ failure and even death. In the elderly, pneumonia has higher risk of fast progression and mortality. The reason for this fact is unclear, one explanation could be the altered immune functions in senior subjects. The objective of this study is to investigate the phagocytic ability of elderly cases having serious lung infections.

Methods: The study population consisted of pneumonia patients older than 65 year of age who were admitted to the hospital. The symptoms, detailed physical examination findings, comorbidities, smoking and alcohol consumption history were noted. The laboratory tests included complete blood count, CRP, procalcitonin, biochemical analyses, antiHIV and arterial blood gases. Sputum cultures (if possible) and blood cultures were taken. The phagocytic ability of neutrophils and monocytes is measured by using Phagotest flow cytometry method.

Results: The study was conducted in a group of 53 patients (41 men and 12 women) with a mean age of 74.04 (65-90). Of the group, 36 were over 70 and 14 were over 80 years of age. History of aspiration was present in 14 subjects (20.8%). Fourteen patients had no history of smoking (26.4%). History of alcohol consumption was present in 5 cases (9.4%). Seven (13.2%) cases were nursing home residents. Chest radiography was repeated 7-10 days after initiation of the treatment; 9 patients showed full regression, 23 regressed more than 50%, 19 had no regression and 2 progressed despite treatment. The mean phagocytic activity was 85.90 ± 24.45 for granulocytes and 68.28 ± 29.04 for monocytes. The phagocytic activity of

granulocytes and monocytes were 91.27 ± 14.40 and 84.06 ± 27.00 for subjects under and above 70 years of age, respectively ($p=0.27$ and $p=0.07$). Phagocytic activity was not found to be correlated with neutrophil count, procalcitonin, CRP, Ig levels and PSI. (p values for neutrophil count, procalcitonin, CRP, IgA, IgG and IgM were 0.19, 0.51, 0.59, 0.64, 0.49, 0.72 for granulocytes and 0.20, 0.80, 0.99, 0.24, 0.37, 0.36 for monocytes, respectively. Phagocytic activity was not related to response to treatment. Smoking history was not correlated to phagocytic activity, whereas in case of alcohol use activity of granulocytes ($p=0.013$) and monocytes ($p=0.03$) were statistically significantly lower.

Conclusion: The present study failed to show a correlation between phagocytic activity and severity of pneumonia in elderly subjects. It is proposed that immune response decreases with senescence. According to our findings, the severity and prognosis of lung infections in elderly is not dependent on phagocytic activity.

Keywords: Phagocytic activity, granulocyte, monocyte, community acquired pneumonia

[Abstract:0483] SS-034 [Accepted:Oral Presentation] [Respiratory Failure and Intensive Care]

Forced Expiratory Volume in First Second Unreliable Predictor for Mortality in Patients with Chronic Obstructive Pulmonary Diseases Who Use domiciliary Noninvasive Ventilation

Birsen Ocaklı, Zuhale Karakurt, Nalan Adıgüzel, Emine Aksoy, Sinem Güngör, Eylem Acartürk Tunçay, Nezihe Çiftaslan, İlim Irmak, Özlem Yazıcıoğlu Moçin, Gökay Güngör

Health Sciences University, İstanbul Süreyyapaşa Training and Research Hospital for Chest Diseases and Thoracic Surgery, İstanbul, Turkey

Objectives: Spirometry is well known test for diagnosis and staging for severity of COPD. Among dyspnea, walking distance, BMI, FEV1 (BODE) are used as mortality predictors. After optimum medical therapy, domiciliary NIV is used in COPD patients with chronic hypercapnic respiratory failure (CHRF) for respiratory support. When FEV1 levels below 1000 ml and below 500 ml, the life expectancy are thought be 5 to 1 year. The study hypothesized that the use of domiciliary NIV for patients with severe COPD; life expectancy should be longer than 1 year if patients with FEV1 less than 500ml.

Methods: Retrospective cohort study was done in a respiratory intensive care unit (ICU) outpatients' clinic in tertiary teaching government university hospital between January 1st 2009-December 31st 2016. All patients were followed up at least 12 months. All consecutive NIV prescribed previously diagnosed severe COPD patients were enrolled into the study. Patient demographics, spirometry values, ABG values were recorded from patients file. Patients NIV use compliance accepted as

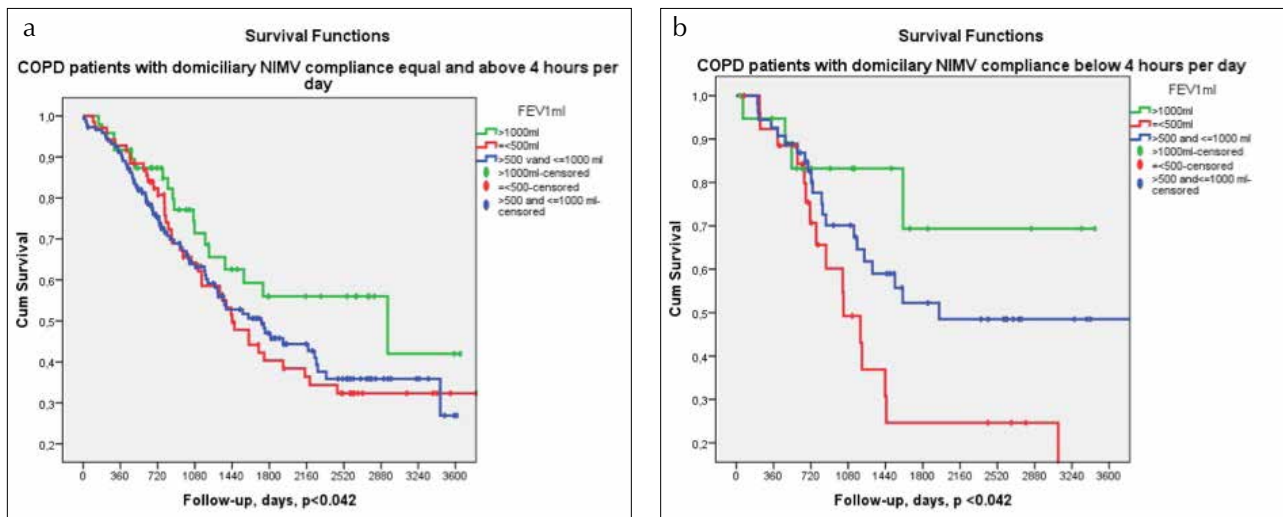


Figure 1. a, b.

more than 4 hour/day. Patients were grouped as dichotomously according to FEV1 as 500mL, 1000mL and according to NIV compliance (NIV use \geq 4h) . Patients' mortality was recorded from electronic system. Kaplan Meier Survival were done.

Results: In study period eligible 427 patients (75% male) were enrolled. FEV1 above 1000mL, below 500 and between 500-1000 mL were 19%, 25%, 56% respectively. NIV device hour was present in 364 patients. Median (interquartile range) follow-up days were 908 (591-1760) days. The mortality rates of 1-5 year in below 500 and in below 1000 were similar as follows: 9% vs 11%; 36% vs 37%; 56% vs 55%; 69% vs 67% and 77% vs 76% respectively ($p>0.05$) . Kaplan-Meier survival analysis showed similar in FEV1-500ml above and below group ($p>0.23$) and significantly higher in FEV1 1000mL above group than below ($p<0.049$) . NIMV device compliance was 62% (263/364) . Kaplan Meier Survival curves showed significantly shorter survival in COPD patients with NIMV use less than 4h according to different FEV1 strata for long term follow-up ($p<0.042$) (Figure 1 a, b) .

Conclusion: The life expectancy should be longer than 1 year if patients with FEV1 less than 500ml when the use of domiciliary NIMV in COPD patients with CHRF independent NIMV compliance; meanwhile those patients with NIMV compliant live as longer as patients with better FEV1 values. The NIMV compliance can equalize the chance for longer survival in COPD patients with FEV1 below 500ml like patients with better FEV1 values.

Keywords: Chronic respiratory failure, chronic obstructive pulmonary diseases, domiciliary noninvasive ventilation, mortality, survival

[Abstract:0485] EPS-259 [Accepted: E-Poster] [Thoracic Surgery]

Descending Necrotizing Mediastinitis: A Case Report

İbrahim Taylan, Hasan Ersöz

Department of Chest Surgery, İzmir Katip Çelebi University Atatürk Training and Research Hospital, İzmir, Turkey

Introduction: Mediastinitis is a serious infection of the mediastinal connective tissue and the structures surrounding them. Descending necrotizing mediastinitis (DNM) is a type of mediastinitis that begins rapidly and has a high mortality rate. DNM is usually seen in the 30-40 age group and is more common in men. The cause is usually an oropharyngeal infection or dissemination of the dental abscess into the mediastinum.

Case Presentation: A 56-year-old male patient. He was admitted to our hospital with the complaints of severe neck pain, general condition deterioration, inability to chew, fever and weakness, which began 2 days after he tried to treat the tooth abscess with a foreign body without consulting a doctor. Five days after hospitalization, tracheostomy was opened in the patient whose general condition was getting worse in spite of the administration of a broad-spectrum antibiotics. Upon the observation of air-fluid levels compatible with mediastinal infection in neck and thorax CT, the patient was taken to urgent operation with the diagnosis of "Acute descending necrotizing mediastinitis". With mediansternotomy, advanced inflammatory and infectious tissues were debrided and adhesions were eliminated. The pericardium was opened and the purulent material in it was emptied. Both pleural cavities were opened and the purulent fluid inside was aspirated; pleural adhesions were eliminated and decortication was applied sporadically. They were abundantly washed with saline containing thorax-betadine and rifosin. The patient was discharged from the intensive care unit and taken to the service on the 80th post-operative day. The tracheostomy was closed. After 25 days of care and treatment, he was discharged with full recovery. The patient who was healthy at the first year post-operative control in outpatient clinic was presented because he was a rare DNM case.

Conclusion: DNM is a rare disease with high mortality (14-46%) . It is crucial that the diagnosis is made promptly and the treatment options are applied quickly and aggressively. Open surgical debridement, broad spectrum antibiotherapy and adequate airway care are the basis of the treatment. Postoperative care is as important as surgery. DNM is an

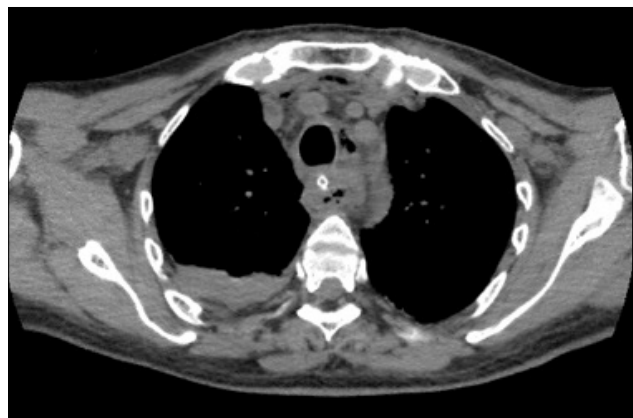

Figure 1. Preop. Thoracic CT. Mediastinal air densities produced by anaerop microorganisms

entity that can be fully cured when treated fast, aggressively and courageously; therefore, it should be kept in mind in patients with a compatible clinic.

Keywords: Mediastinal infection, descending necrotizing mediastinitis, dental abscess

[Abstract:0486] PS-228 [Accepted:Poster Presentation] [Tobacco Control]

The Effect of Smoking Cessation on Erectile Dysfunction in Male Patients with Ankylosing Spondylitis

Seyhan Dülger¹, İlknur Aykurt Karlıbel², Meliha Kasapoğlu Aksoy², Ali Rıza Türkoğlu³, Özlem Şengören Dikiş¹, Lale Altan², Muhammed Güzelsoy³, Tekin Yıldız¹

¹Department of Pulmonary Diseases, Training and Research Hospital, Bursa, Turkey

²Department of Physical Medicine and Rehabilitation, Health Sciences University Bursa High Education Training and Research Hospital, Bursa, Turkey

³Department of Urology, Health Sciences University Bursa High Education Training and Research Hospital, Bursa, Turkey

Objectives: Ankylosing spondylitis (AS) may cause erectile dysfunction (ED) due to multiple factors, including physical and functional disorders and disease activity in male patients. Smoking is one of the potential risk factors for ED. The purpose of this study is to examine the smoking habits of male patients with AS and the effect of smoking cessation on ED.

Methods: Seventy male patients with AS who were diagnosed as AS according to Modifiye New York criteria, at least 4 weeks of sexually active and aged between 18-57 were enrolled. Bath Ankylosing Spondylitis Functional Index (BASFI) , Ankylosing Spondylitis Quality of Life (ASQol) and Short-Form Health Survey (SF-36) , Beck Depression Scale (BDI) , Beck Anxiety Scale (BAI) . Patients were divided into two groups: smokers (Group 1) and non-smokers (Group 2) . In Group 1 patients Fagerström Nicotine Dependence Test (FNNT) , Carbon monoxide (Exp. CO) measurement in expiratory air. The per day cigarette and cumulative smoking load were recorded. The Erectile Function International Index (IIEF-5) questionnaire was administered in both groups. The baseline and 6th month data of Group 1 and Group 2 were compared statistically. AS disease activity scales at 6 months, IIEF-5, Exp. CO measurement, smoking habit inquiry was repeated. In group 1, compared with those who quit smoking (Group 1a) and those who continued smoking (Group 1b) .

Results: The median age of the 70 AS men studied was 34 years (18-57) and 70% (n=49) of patients were smoking. Of these, 30.6% (n=15) quit smoking (Group 1a) and 69.4% (n=34) continued to smoke (Group 1b) . There was no statistically significant difference between group 1a and group 1b between the IIEF-5 initial category and scores (p=0.37, p=0.42, respectively) and 6th month category and scores (p=0.86, p=0.8, respectively) . A statistically significant difference was found between the baseline and 6th month values of group 1a patients in terms of disease activity, life quality and ED.

Conclusion: Smoking cessation in AS patients should be considered as part of treatment; it should not be forgotten that patients who quit smoking will recover from ED, improve quality of life, improve physical mobility and disease activity.

Keywords: Ankylosing spondylitis, smoking cessation, erectile dysfunction

[Abstract:0488] EPS-123 [Accepted: E-Poster] [Pediatric Pulmonary Diseases]

Approach to Foreign Body in Children with Flexible Bronchoscopy

Gökçen Dilşa Tuğcu¹, Beste Özsezen¹, Güzin Cinel², Rabia Demir³, Doğuş Güney³, Emrah Şenel³

¹Department of Pediatric Chest Diseases, Hacettepe University İhsan Doğramacı Children's Hospital, Ankara, Turkey

²Department of Pediatric Chest, Diseases Child Health and Diseases, Hematology-Oncology Training and Research Hospital, Ankara, Turkey

³Department of Pediatric Surgery, Child Health and Diseases, Hematology-Oncology Training and Research Hospital, Ankara, Turkey

Objectives: In children, foreign body aspiration (FBA) with rigid bronchoscopy is the gold standard and common in our country as it is in the world. Flexible bronchoscopy has been used more and more frequently in recent years.

Methods: The records of 273 patients who underwent flexible bronchoscopy (FB) at Ankara Child Health and Diseases Hematology and Oncology Hospital, Children Chest Diseases Training Clinic between the years 2013 and 2018 were reviewed. Urological and endoscopic forceps (basket, engage) were used during foreign body aspiration (FBA) with FB.

Results: A foreign body was seen in 15 of 273 patients who underwent FB; 12 patients were intervened with rigid bronchoscopy (RB) by the department of pediatric surgery (PS) , and FB was used in 4. Our first patient in whom a foreign body was removed with FB was 9 months of age and was admitted due to widespread wheezing that did not respond to treatment. In the FB of the patient, 3 pieces of foreign body (seed) were detected in the trachea and left main bronchus, and they were removed with FB because the vocal cords could not be passed through with rigid bronchoscopy telescope. Our second patient was 2.5 years old; there was a history of recurrent pulmonary infection in the left lower lobe for the past 6 months, and there wasn't a picture of an obvious foreign body aspiration. Foreign body (seed) was removed from the left lower lobe of the patient with FB with the same method. The bronchial casts was detected in the third patient in whom FB was performed due to uncontrolled asthma and aspiration difference, and the casts that could not be removed with RB were removed with FB. In our last 3-year-old patient who underwent RB because of FFBA, FB was performed because partial foreign body was seen in distal localization. Three pieces of foreign body (walnut) were removed from the upper lobe of the left lung of the patient. No complications occurred during and after the procedure.

Conclusion: In children, RB is a reliable and recommended approach in FBA. A wide view and intervention area is obtained with RB. In distal and/or upper lobes, FB can be tried in FBA that cannot be reached with RB. In recent years, it has been reported that the frequency of interventions in FBA with FB increased; but further experience is needed in this regard.

Keywords: Foreign body aspiration, rigid bronchoscopy, flexible bronchoscopy

[Abstract:0490] EPS-096 [Accepted: E-Poster] [Lung and Pleura Malignancies]

A Rare Cause of Malignant Pleural Effusion: Spindle Cell Carcinoma of the Lung

Hüseyin Koşak¹, Dilek Karadoğan¹, Cüneyt Yurdakul², Songül Özyurt¹, Bilge Yılmaz Kara¹, Ünal Şahin¹

¹Department of Chest Disease, Recep Tayyip Erdoğan University School of Medicine, Rize, Turkey

²Department of Pathology, Recep Tayyip Erdoğan University School of Medicine, Rize, Turkey

Introduction: Spindle cell carcinoma (SpCC) is a very rarely seen type of lung cancer with an estimated incidence to be between 0.3% and 1.3% among all lung malignancies. In the literature search we could find only one case with pleura metastasis of SpCC that was detected by video-assisted thorascopic surgery. We present our case of SpCC, diagnosed by closed pleural biopsy, to emphasize the importance of minimally invasive approaches in the diagnosis and treatment of that aggressively progressing lung tumor.

Case Presentation: A 76-year-old male was admitted to our hospital's emergency department with complaints of drowsiness, chills, weakness and bloody sputum. He also reported persistent night sweats and weight loss for the last 1 year. He was a 20 pack/year current smoker without any other comorbid disease history. His vital findings were normal apart from the desaturation measured as 90% in the room air by pulse oxymetry. No respiratory sounds were heard in the right hemi-

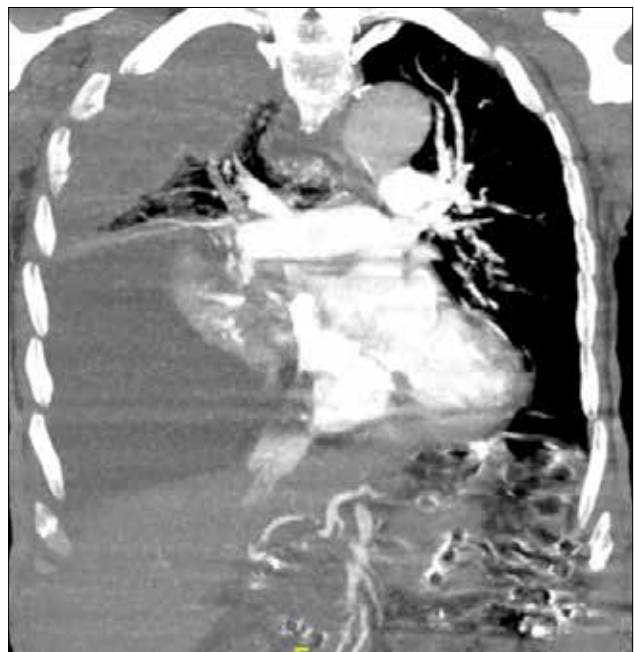


Figure 1. Massive pleural effusion in the right hemithorax and a giant mass in the right upper lobe

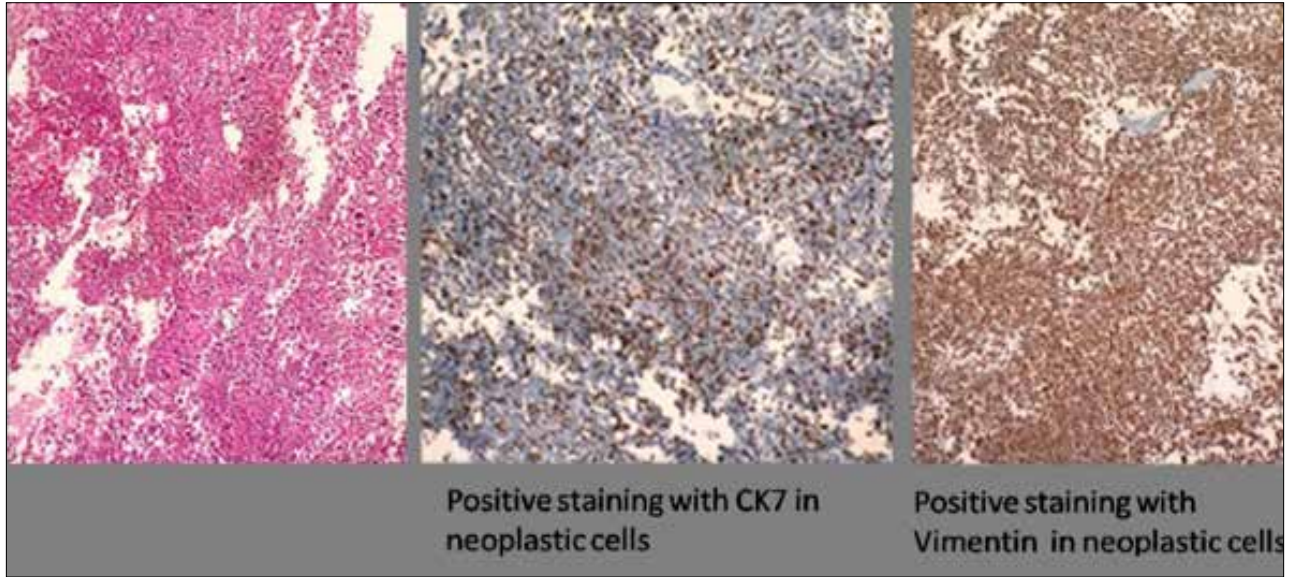


Figure 2. A tumor composed of cells with distinct pleomorphism with positive CK and vimentin staining in neoplastic cells

thorax of the patient by the auscultation and maturity was heard by the percussion. Right opacified lung was observed in chest X-ray. Thorax computerized tomography revealed massive pleural effusion in the right hemithorax and giant mass in the right upper lobe (Figure 1). Diagnostic thoracentesis was performed and the pH of the hemorrhagic exudative pleural fluid was 7.17, LDH: 1436 U/L with lymphocyte dominance. The patient underwent closed pleura biopsy by Abrams needle. Malignant cells were seen at pleural fluid cytology and a high-grade spindle cell malignant tumor infiltration -a tumor composed of cells with distinct pleomorphism- with positive CK and vimentin staining in neoplastic cells (Figure 2) were reported. Positron emission tomography scan revealed multiple distant metastasis and patient was evaluated available only for palliative care. A pleurocatheter was inserted for pleural effusion on the right hemithorax. Patient died 1.5 month after the diagnosis.

Conclusion: SpCC is a rarely seen and aggressive lung carcinoma. For its diagnosis and treatment firstly minimally invasive diagnostic methods should be tried.

Keywords: Spindle cell carcinoma, pleura biopsy, pleural effusion

[Abstract:0493] PS-037 [Accepted:Poster Presentation] [Clinic Problems - Others]

Recurrent Spontaneous Pneumothorax History in a Family: Birt- Hogg- Dube Syndrome

Hüseyin Koşak¹, Dilek Karadoğan¹, Yavuz Metin², Kerim Tülüce³, Serdar Ceylaner⁴, Songül Özyurt¹, Bilge Yılmaz Kara¹, Ünal Şahin¹, Adile Berna Dursun⁵

¹Department of Chest Diseases, Recep Tayyip Erdoğan University School of Medicine, Rize, Turkey

²Department of Radiology, Recep Tayyip Erdoğan University School of Medicine, Rize, Turkey

³Department of Chest Surgery, Recep Tayyip Erdoğan University School of Medicine, Rize, Turkey

⁴Intergen Genetic Diagnosis, Research and Application Center, Ankara, Turkey

⁵Department of Immunology and Allergic Diseases, Recep Tayyip Erdoğan University School of Medicine, Rize, Turkey

Introduction: Birt- Hogg- Dube Syndrome (BHDS) is a rarely seen autosomal dominant inherited disorder due to the mutations in the FLCN gene that gives clinical presentation with recurrent spontaneous pneumothorax, skin lesions and kidney tumors. To date over 600 families have been detected worldwide. Because of its rarity, most clinicians are not aware of the disease, therefore, most families can stay undiagnosed. In that report we present a case that we diagnosed as BHDS, who has also family members with similar findings, to attract attention of that rarely seen disease.

Case Presentation: A 58-year-old female with no active complaints was directed to our clinic for investigation of the causes of her previous respiratory symptoms. She had a past history of recurrent spontaneous pneumothorax; first 20 years ago suc-

cessfully treated with drainage and second one 5 years ago that was needed thoracotomy after drainage. She was a former smoker with 5 pack year smoking history and reported that she avoids travelling by plane due to the risk of pneumothorax. She also declared that some of her close relatives had also history of spontaneous pneumothorax. Her physical examination was normal, and oxygen saturation was 98% in the room air. The pulmonary function test of the patient was normal. Thorax high resolution computed tomography scan showed multiple thin-walled cysts in subpleural areas of basal parts of the lungs, which led to the suspicion of BHDS (Figure) . Genetic screening revealed that the patient had a known pathogenic mutation in FLCN gene (NM_144997.6 c.671_672delCA (p.T224Sfs*23) , which confirmed the diagnosis of BHDS. She had no skin lesions and her renal ultrasound scan was normal. Patient and her relatives were offered genetic counseling and investigation.

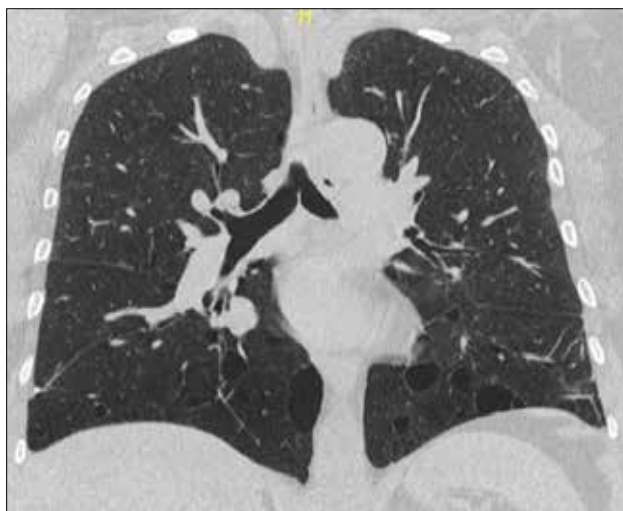


Figure 1. Multiple thin-walled cysts in subpleural areas of basal parts of the lungs

Conclusion: BHDS is a rare, poorly known, and undiagnosed genetic disorder that should be considered in cases with history of recurrent spontaneous pneumothorax. In addition to pulmonary involvement, skin lesions and renal tumors may develop as reported in the literature. Therefore, genetic counseling and periodic screenings are required.

Keywords: Recurrent pneumothorax, Birt-Hogg-Dube syndrome, FLCN gene

[Abstract:0494] PS-079 [Accepted:Poster Presentation] [Thoracic Surgery]

Examination of the Knowledge Levels of the Patients about the Procedure in whom Closed Underwater Drainage System was Applied

Neriman Onaran, Nilgün Alğan, Serdar Evman, Serkan Bayram, Aysun Kosif, Çağatay Tezel, Volkan Baysungur

Department of Chest Surgery, Health Sciences University, Süreyyapaşa Chest Diseases and Chest Surgery Training and Research Hospital, İstanbul, Turkey

Objectives: The right to be informed is one of the primary subjects of patient rights. In terms of clinical orientation, it is important for the patients to know about their diseases, the treatment method to be applied and things to do individually after the performed procedures. According to the literature studies, it was seen that the most common complaints were pain, anxiety and lack of knowledge in thorax drainage applications (mobility, diet, and the uncertainty that worries the patients about the amount/color/status of drainage) . In this study, the level of knowledge of the patients undergoing thoracic drainage about the procedure, and the effect of increased level of knowledge on clinical orientation were examined.

Methods: In our clinic, patients aged 18 years or older in whom chest drain was placed due to any indication between January and December 2017 and who volunteered to participate in the study were prospectively examined (postoperatively, patients were excluded from the study) . As a training material, patient education brochure was created as a result of literature review. After the pre-test procedure was applied, the patients were trained by using the oral expression method and the visual expression method. The pre-test was performed within the first 1-6 hours after the procedure and the last test within 24-36 hours, and thus, the socio-demographic characteristics, knowledge levels and clinical status of the patients were analyzed. Visual Analogue Scale (VAS) was used for pain and anxiety evaluation.

Results: A total of 536 patients, 415 men and 121 women, with a mean age of 52.04 (range 18-86) were trained and questionnaires were applied. When the level of knowledge about the drains was examined in 8 variables, the total score of correct answers in patients was calculated as 1992 in the pre-test and 4188 in the last test ($p < 0.001$) . It was determined that 98% of the patients did not know to perform deep breathing-cough exercise and 96% of them did not know how to carry the

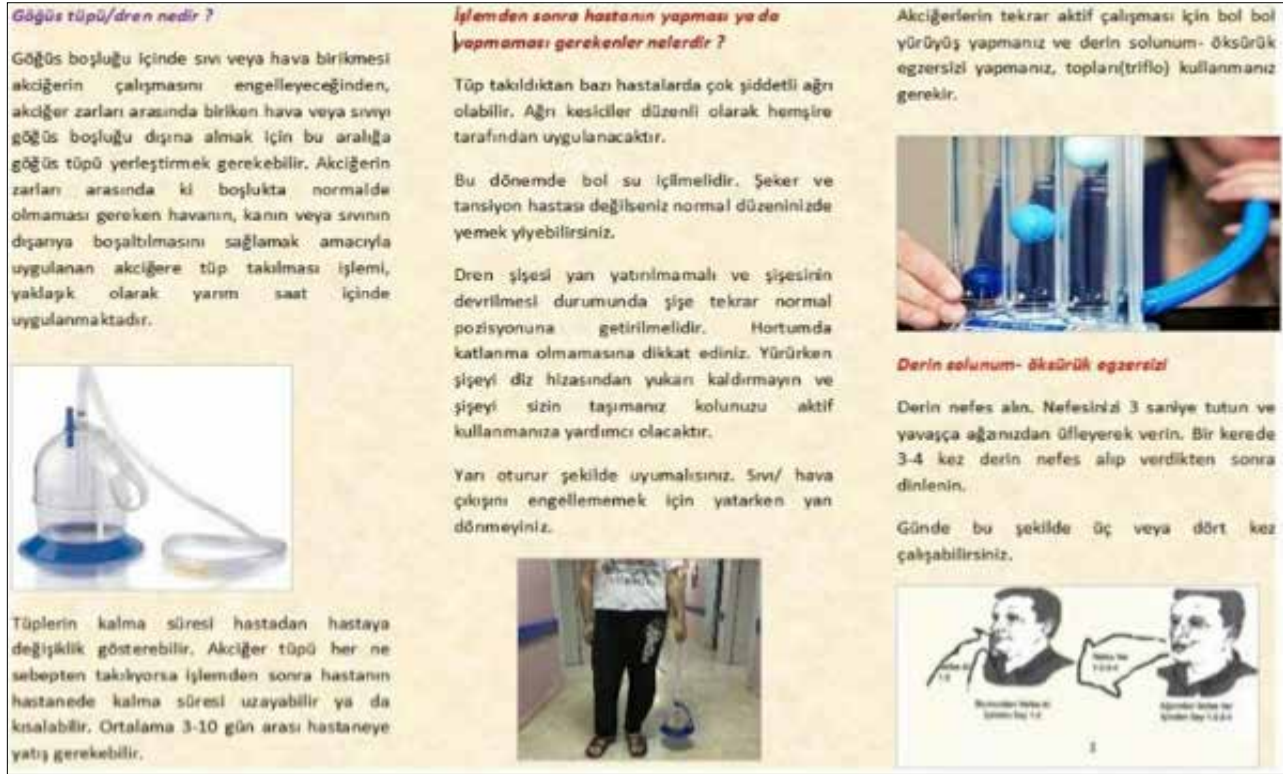

Figure 1. Patient Education Brochure

thorax drain and the correct lying position. VAS pain level was 4.19 in the pre-test and 1.48 in the last test ($p=0.002$). The level of anxiety which was 2.56 points in the pre-test decreased to 1.31 in the last test, in other words, it was observed that there was a statistically significant decrease at a rate of 48.8%.

Conclusion: The fact that the patients with thoracic drainage have no knowledge about the procedure causes them to lie in the wrong positions in the bed and causes incorrect mobilization, difficulty in pain control and anxiety development. Complications such as leakage in the drain hose due to bending that occurs while lying on it, pneumothorax that occurs while lying in wrong direction, and subcutaneous emphysema can be predicted/minimized by the trainings given to patients. The care and follow-up that we perform in professional nursing approaches is to be able to provide the compliance of the patients undergoing thoracic drainage to all situations that they may encounter in this period and to be able to perform a strict follow-up of the complications that may occur. With the increase in the level of knowledge, we provide the maximum participation of our patients in the treatment and follow-up periods. After the training provided, the patient's adaptation to the disease, the procedure to be performed and the clinic increased. It is thought that the increase in cooperation relieves the burden of the health personnel.

Keywords: Patient knowledge level, patient training, thorax drain

[Abstract:0495] PS-229 [Accepted:Poster Presentation] [Tobacco Control]

Complications of Electronic Cigarettes and Review of Literature

Aşkın Gülşen

Department of Pneumology, Research Center Borstel, Borstel, Germany

Objectives: Electronic cigarettes (e-cigarettes) are seen by many in society as a harmless alternative to classical tobacco cigarettes. Since 2004, with the increasing use of social media, e-cigarettes have become more popular worldwide and their use has been multiplying exponentially. According to a Study in Germany, every eight people in Germany smokes e-cigarettes. Studies on health effects are also increasing. The purpose of this article is to draw attention to the effects of e-cigarette on health and the various complications reported so far.

Table 1. Complication of E-cigarettes

Author	Year	Complications
Norii T.	2017	Explosion Resulting in a C1 and C2 Fracture
Vaught B.	2016	Facial trauma caused by electronic cigarette explosion
Archambeau BA.	2016	Complex Facial Fractures and Pneumocephalus
Paley GL.	2016	Corneoscleral Laceration and Ocular Burns
Rogér JM.	2016	Oral Trauma and Tooth Avulsion Following Explosion
Shastry S.	2016	Battery Explosion Causing Shotgun-like Superficial Wounds and Contusion
Chen BC.	2016	Death following intentional ingestion of e-liquid.
Ring Madsen L.	2016	Multiple pulmonary nodules imitating Metastatic Cancer
Maridet C.	2015	Nickel contact allergy
Thota D.	2014	Eosinophilic pneumonitis

Methods: The articles on complications of e-cigarettes published between 2004 and 2018 were retrieved by searching three international databases (PubMed, Science Citation Index and Google Scholar) . The keywords, such as e-cigarettes, case report, and complication were determined for the databases.

Results: By reviewing the literature, it has been observed that head and neck injuries were increased in recent years, especially device-related burst and explosions. Reported complications are C1 and C2 fractures, facial injury, corneoscleral injury, oral trauma, multiple lung nodules, eosinophilic pneumonia, nickel contact allergy and death (Table 1) . In an e-cigarette, flavored liquids are vaporized electrically. The devices consist of a power source (battery) , an electric heating element (nebulizer) and a cartridge for the liquid to be evaporated (liquid) . So there is no smoke, but an aerosol that is inhaled. More than 8,000 flavors are used such as from classic tobacco to strawberry and caramel to the taste of gummy bears, the least of which are tested for their effects in humans. In addition, The Federal Institute for Risk Research and the German Cancer Center warn against underestimating the potential dangers of e-cigarettes.

Conclusion: To warn the community, health hazard of e-cigarette's must be told correctly. However, I believe that it may be useful to emphasize the head-facial injuries that can occur with the device bursting and taking fire.

Keywords: E-cigarette, electronic cigarette, complications, case report, review of literature, head-neck injuries

[Abstract:0496] SS-092 [Accepted:Oral Presentation] [Tobacco Control]

Attitudes and Behaviors about Smoking and Electronic Smoking in Parents in Pregnancy; A Multicenter Cross-Sectional Study

Elif Yıldırım¹, Serap Duru², Tülin Sevim¹, Füsün Topçu³, Bilun Gemicioğlu⁴, İpek Özmen¹, Birsen Ocaklı¹, Eylem Tunçay¹, Yaşam Kemal Apak², Yelda Varol⁵, Gülru Polat⁵, Serir Özkan⁵, Neşe Dursunoğlu⁶, Derya Sakarya⁶, Pınar Yıldız Gülhan⁷, Özlem Erçen Diken⁸, Pelin Duru Çetinkaya⁹, Arzu Yorgancıoğlu¹⁰, Nursel Türkoğlu Selçuk¹¹, Füsün Yıldız¹², Tijen Ataçağ¹²

¹Health Sciences University, İstanbul Süreyyapaşa Chest Disease and Thoracic Surgery Training and Research Hospital, İstanbul, Turkey

²Health Sciences University, Dışkapı Yıldırım Beyazıt Training and Research Hospital, İstanbul, Turkey

³Pulmonary Diseases Department, Dicle University School of Medicine, Diyarbakır, Turkey

⁴Pulmonary Diseases Department, İstanbul University Cerrahpaşa School of Medicine, İstanbul, Turkey

⁵Health Sciences University, Dr Suat Seren Chest Disease and Thoracic Surgery Training and Research Hospital, İzmir, Turkey

⁶Pulmonary Diseases Department, Pamukkale University School of Medicine, Denizli, Turkey

⁷Pulmonary Diseases Department, Düzce University School of Medicine, Düzce, Turkey

⁸Pulmonary Diseases Department, Hitit University School of Medicine, Çorum, Turkey

⁹Çukurova Dr. Aşkım Tüfekçi State Hospital, Adana, Turkey

¹⁰Pulmonary Diseases Department, Celal Bayar University School of Medicine, Manisa, Turkey

¹¹Health Sciences University Antalya Research and Training Hospital, Antalya, Turkey

¹²Pulmonary Diseases Department, Dr. Suat Günsel University of Kyrenia Hospital, Girne, Turkish Republic of Northern Cyprus

Objectives: Smoking in pregnancy is a preventable risk factor affecting morbidity and mortality. A multicentre cross-sectional study was planned by "Turkish Thoracic Society Women and Lung Health As a task force group". The aim of the study is

to determine the attitudes of pregnant women and their surroundings to cigarettes and electronic cigarettes, which have become increasingly prevalent in recent years.

Methods: The study was conducted in 11 provinces and 15 centers in Turkey, between September 2017 and December 2017. A Questionnaires were conducted with face-to-face interviews to gynecology outpatients who agreed to participate in the study. There were a total of 60 questions regarding education, socioeconomic status and parents' habits of smoking cigarettes and electronic cigarettes.

Results: A total of 1123 pregnant women with a mean age of 27 ± 5.6 were enrolled. 48% of them were primary school graduates, 7% were not illiterate, and 56% were housewives. Fourty percent of the pregnant women were never nonsmoker and 10% of them were active smokers. Approximately 22% had stopped smoking before pregnancy, and 7% had quit smoking in pregnancy. Almost half of the spouses (49.3%) were still smoking. The most important factor in smoking cessation was the thought it could be harmful to the baby. Nevertheless, 30% of them thought electronic cigarette was not harmful to the baby. The rate of smoking electronic cigarettes among pregnant women was 3%. Twenty five percent of pregnant women thought that cigarette smoking was more harmful, and the 45% were not aware of the harms and addictive effects of electronic cigarettes.

Conclusion: These results are in the preliminary report of the ongoing multicentre study. Pregnant women and their spouses seem to need more information about cigarettes and electronic cigarettes lately, as if they were harmless. Educational sessions, planned together with the obstetricians and chest physicians would make a significant contribution to maternal and child health.

Keywords: Smoking, electronic cigarette, pregnancy

[Abstract:0497] PS-295 [Accepted:Poster Presentation] [Respiratory Failure and Intensive Care]

Extra Corporeal Membrane Oxygenation in Pregnant Patient with Acute Respiratory Distress Syndrome

Pelin Girgin¹, Aşkın Gülşen²

¹Department of Anesthesiology, Çiğli Regional Research Hospital, İzmir, Turkey

²Department of Pulmonary Diseases, Research Center Borstel, Borstel, Germany

Extracorporeal membrane oxygenation (ECMO) is a form of temporary life support for heart and lungs. In recent years, it has been suggested as a therapeutic option in younger patients with severe acute respiratory distress syndrome (ARDS). We report a case of community-acquired pneumonia in a pregnant woman who developed acute respiratory distress syndrome

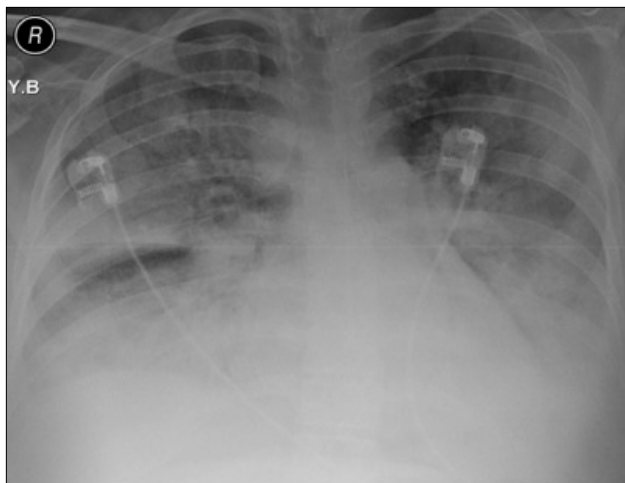


Figure 1. Chest radiograph on admission shows infiltration with airbronchogram in left lung

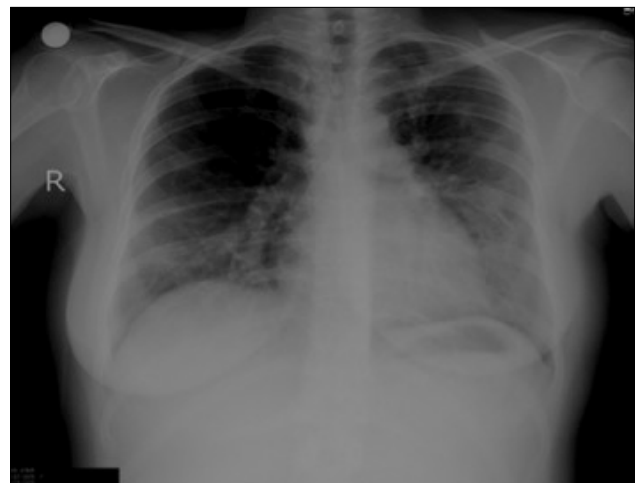

Figure 2. Chest radiograph on day 39 shows improvement of infiltration

Table 1. Ventilator settings during ECMO

	Mode	VT (mL/kg)	RR (breaths/min)	PEEP (cmH2O)	FiO2 (%)	PaO2/FiO2
Before ECMO	PC-AC	6	30	15	100	54
Day-1	PC-AC	6	12	10	30*	120
Day-3	PC-SIMV	6	12	10	30*	150
Day-7	PC-SIMV	6	14	8	60*	200
Day-12	SPN / CPAP/PS	10	14	6	40*	250

*With ECMO

(ARDS) managed with extracorporeal membrane oxygenation (ECMO). A 36-year-old, 26 week pregnant woman with twins developed rapidly progressive pneumonia with bilateral infiltrates on chest x-ray (Figure 1) and was confirmed to pneumonia due to *Streptococcus pyogenes* infection. Her condition deteriorated and she developed ARDS which was managed with veno-venous extracorporeal membrane oxygenation (VV-ECMO) and treated with antimicrobials. Therefore, veno-venous extracorporeal membrane oxygenation (VV-ECMO) cannulation was inserted in the right internal jugular vein and right femoral vein with a settings support of: FiO2: 100%, CO (cardiac output) : 4.5 L/min, 2500 RPM (rotation per minutes). In ICU she was sedated with Midazolam/Rocuronium bromide and remained ventilation during the whole period of ECMO treatment, with a pressure control ventilation (PC-AC) mode, positive pressure support of 10 cm H2O and FiO2 30% (Table-1). Her clinical symptoms and oxygenation gradually improved and the ECMO was discontinued on the 12th day. Patient was extubated after two days. The patient was discharged without sequela. Chest radiograph on day 39 shows improvement of infiltration (Figure 2). That case reported the successful treatment of using vvEcmo in ARDS. The ideal settings for mechanical ventilation is not exactly known; we recommended patient-specific settings with low tidal volume ventilation during ECMO.

Keywords: ECMO, ARDS, pneumonia, pregnancy, extracorporeal lung assist, acute respiratory failure

[Abstract:0499] SS-017 [Accepted:Oral Presentation] [COPD]

Prognostic Value of BUN / Albumin Ratio in COPD

Ayşe Baha¹, Zeynep Işıkdığan Fendoğlu², Nurdan Köktürk³, Hatice Kılıç⁴, Canan Hasanoğlu⁴, Sertaç Arslan⁵, Meral Gülhan⁵, Nalan Ogan¹, Evrim Eylem Akpınar¹, Aslıhan Alan⁶

¹Department of Pulmonary Medicine, Ufuk University School of Medicine, Ankara, Turkey

²Clinic of Pulmonary Diseases, Beytepe Murat Erdi Eker Public Hospital, Ankara, Turkey

³Department of Pulmonary Medicine, Gazi University School of Medicine, Ankara, Turkey

⁴Clinic of Pulmonary Diseases, Ankara Atatürk Training and Research Hospital, Ankara, Turkey

⁵Department of Pulmonary Medicine, Hitit University School of Medicine, Çorum, Turkey

⁶Department of Biostatistics, Ufuk University School of Medicine, Ankara, Turkey

Objectives: The BUN/albumin ratio is a cost effective, easily achievable and similar indicative result for prognosis in patients with pneumonia compared to hsCRP and procalcitonin. In COPD has been reported that renal function impaired during the exacerbation period is associated with poor prognosis. Also, COPD negatively affects nutritional status and this situation can reduced the albumine levels. There is no definite parameter in predicting short and long term prognosis in patients with COPD. Our aim is to evaluate the prognostic effect of serum BUN/albumin ratio in COPD patients.

Methods: The study was conducted as a multi-center (3 university hospitals, 1 education-research hospital) retrospective file scan. 337 patients were included in the study. Local ethics committee approval was obtained. Demographic characteristics, disease characteristics, comorbid conditions, short-term (death, transfer to intensive care unit, discharge) and long-term (1 year mortality and hospital readmission rate) prognosis information of patients were recorded and the data were analyzed by appropriate statistical method.

Results: Of 337 patients 261 (77.4%) were male, 76 (22.3%) were female and the mean age was 68.9±10.1 years. According to the spirometric GOLD staging, 122 patients (36.2%) were stage-2, 134 (39.8%) stage-3, 77 (22.8%) were stage-4 patients. In during the hospitalization period, 6 (1.8%) patients were death, 23 (6.8%) were transferred to the intensive care unit and 308 (91.4%) were discharged. The mean BUN/albumin ratio was 6.8±4.3. 189 patients (56.1%) were

hospitalized with infectious exacerbation, 73 (21.7%) with pneumonia and 20 (5.9%) with pulmonary embolism. BUN/albumin ratio (7.8 ± 4.9) was higher in patients in pneumonia related exacerbation ($p=0.02$). The 1-year mortality after discharge was 15.1% (50). 48.1% (40) of patients who had transfer to intensive care unit and 13% (10) of discharge patients were died after 1 year follow-up ($p<0.001$). The BUN/albumin ratio of the patients who died (10.4 ± 6.3) was higher than those who did not die (6.1 ± 3.6) ($p<0.001$). As the BUN/albumin ratio increased, the number of hospitalizations ($p<0.001$) and the number of transfer to intensive care ($p<0.001$) were found to increase. In univariate analysis, pneumonia ($p=0.03$), heart failure ($p=0.01$) and BUN/albumin ratio ($p<0.001$) were found to be effective on 1-year mortality. When these parameters were analyzed by multivariate analysis, only the BUN/albumin ratio was found to have a significant effect on 1 year mortality ($p<0.001$).

Conclusion: This is the first study to investigate the BUN/albumin ratio in COPD patients. It isn't possible to assess on short-term prognostic effect of BUN/albumin ratio in patients with COPD. However, BUN/albumin ratio increased in COPD patients is associated with 1-year mortality. There is need for prospective and with more patients studies.

Keywords: COPD, BUN/albumin ratio, prognosis

[Abstract:0500] EPS-106 [Accepted: E-Poster] [Lung and Pleura Malignancies]

Second Primary Squamous Cell Lung Cancer in a Patient Who Cured Small Cell Lung Cancer

Günseli Balcı, Aydan Mertoğlu, İpek Ünsal

Health Sciences University Dr. Suat Seren Chest Diseases and Thoracic Surgery Training and Research Hospital, İzmir, Turkey

It is known that the risk of developing a second primary tumor in respiratory tract and digestive system is high in treated cured small cell lung cancer. We present here a case of second primary squamous cell lung cancer developing in the seventh year of follow-up period.

A 57-year-old male patient was treated with chemotherapy and radiotherapy 7 years ago due to limited small-cell lung cancer in the right lung. PET CT revealed a 2.5 cm soft tissue lesion in the right lower lobe posterobasal segment of the right lung, 18 FDG uptake at the malignancy level in the right inferior jugular, right infraclavicular and subcarinal-paraesophageal area lymph nodes in the right soft tissue lesions at the seventh year of follow-up. Bronchoscopy revealed vegetative tumor lesion in the right lower lobe posteriorobasal segment. Tumor cells in the biopsy specimen; The IHC method is P63 (+), TTF-1 (-), CK7 (+). The findings were reported as compatible with "squamous cell carcinoma." Gemcitabine-cisplatin chemotherapy was started to the patient. Survival is more than two years in small cell lung cancer, and the risk of developing a second primary non-small cell lung cancer is 7-16 times more when compared to smokers and non-cancers. For this reason, the patients should be followed closely.

Keywords: Small cell lung cancer, cure, second primary lung cancer

[Abstract:0502] SS-026 [Accepted: Oral Presentation] [Pulmonary Rehabilitation and Chronic Care]

Effects of Comprehensive Pulmonary Rehabilitation on Functional Exercise Capacity, Inspiratory and Peripheral Muscle Strength, Respiratory Function and Dyspnea in Patients with Interstitial Lung Disease

İnci Hazal Ayas¹, Burcu Camcıoğlu¹, Zeynep Pelin Uğur Dündar², Zeliha Çelik¹, Hanım Eda Göktaş¹, Selin Bayram¹, Gülşah Barğı¹, Haluk Türktaş³, Meral Boşnak Güçlü¹

¹Department of Physiotherapy and Rehabilitation, Gazi University School of Health Sciences, Ankara, Turkey

²Department of Physiotherapy and Rehabilitation, Necmettin Erbakan University School of Health Sciences, Konya, Turkey

³Department of Chest Medicine Gazi University School of Medicine, Ankara, Turkey

Objectives: Interstitial lung disease (ILD) is a diffuse parenchymal disease that can cause severe morbidity and mortality. ILD is characterized by impaired exercise capacity, pulmonary and cardiac functions; decreased respiratory and peripheral muscle strength and increased dyspnea perception. In literature, studies demonstrated effects of pulmonary rehabilitation (PR) are limited and we aimed to investigate the effects of standardized and comprehensive PR program on inspiratory and peripheral muscle strength, pulmonary function, functional exercise capacity and dyspnea in patients with interstitial lung disease.

Methods: Fourteen patients (59.92±11.27 years, 8F/6M) included in rehabilitation group and 11 patients (54.90±14.22 years, 3F/8M) included in control group. Rehabilitation group received 42.40±29.22 sessions (2-3 day/6-8 week) of pulmonary rehabilitation program which containing inspiratory muscle training, upper and lower extremity aerobic exercise training and resistance training. Control group applied respiratory exercises for 42.00±00 sessions, 40 breaths/cycle, 3 cycle/session. Inspiratory muscle training performed at 40% of maximal inspiratory pressure (MIP) , aerobic exercise training at 60-80% of maximal heart rate and resistance exercise at 50-80% of one repetition maximum. Inspiratory muscle strength (MIP, MEP) were evaluated using mouth pressure device, pulmonary function using spirometry, peripheral muscle strength (knee extension, shoulder abduction and flexion, hand grip) using hand-held dynamometer, functional exercise capacity using 6 minute walk test (6MWT) , dyspnea using modified "Medical Research Council" (MMRC) dyspnea scale and modified Borg scale before and after rehabilitation in both groups.

Results: Baseline clinical and demographic characteristics were similar between groups ($p>0.05$) . MIP ($p=0.009$) , %MIP ($p=0.001$) , 6MWT distance ($p=0.05$) , %6MWT ($p=0.043$) , MMRC ($p=0.014$) , shoulder abduction strength (non-dominant $p=0.05$) and predicted percent of shoulder abduction (non-dominant $p=0.05$) were significantly improved in rehabilitation group compared with controls. There were no significant differences in pulmonary function parameters, MEP, %MEP, knee extension, shoulders flexion and hand-grip muscle strength and exertional dyspnea ($p>0.05$) between groups. MIP ($p=0.01$) , %MIP ($p=0.01$) , 6MWT distance ($p=0.004$) %6MWT ($p=0.006$) , hand-grip strength (dominant; $p=0.023$, non-dominant; $p=0.004$) , MMRC ($p=0.001$) were significantly improved within rehabilitation group and exertional dyspnea ($p=0.043$) increased within control grup.

Conclusion: Standardized and comprehensive PR program improves inspiratory and peripheral muscle strength, functional exercise capacity and dyspnea in patients with ILD. Present study confirms that comprehensive PR is feasible and effective in patients with ILD. All the components and intensities of rehabilitation programs should be selected according to the needs of the patients. New studies rehabilitation programs at different intensities, alternatives and frequencies with adequate sample size are needed.

Keywords: Comprehensive pulmonary rehabilitation, dyspnea, functional exercise capacity, interstitial lung disease, peripheral muscle strength, respiratory muscle strength

[Abstract:0504] EPS-234 [Accepted: E-Poster] [Thoracic Surgery]

Hemorrhage Causes and Treatment Approach after Non-small Cell Lung Cancer Resections

Kemal Karapınar, Sertan Erdoğan, Celal Buğra Sezen, Ali Cevat Kutluk, Cemal Aker, Cem Emrah Kalafat, Salih Bilen, Celalettin İbrahim Kocatürk

Department of Thoracic Surgery, Yedikule Training Hospital for Chest Diseases and Thoracic Surgery, İstanbul, Turkey

Objectives: The most effective treatment for early stage Non-Small Cell Lung Cancer (NSCLC) is surgery. One of the causes of early morbidity and mortality after surgery is postoperative hemorrhage. In this study, we tried to examine our postoperative hemorrhage cases in our clinic and our approach to these cases.

Methods: We retrospectively reviewed the files of patients who underwent postoperative hemorrhage after resection for lung cancer between January 2015 and December 2016 in our clinic. Postoperative hemorrhage; hemorrhage was considered as hemorrhage affecting the patient's general condition, arterial blood pressure, and pulse rate, even if there was a total of 600 cc or more hemorrhagic drainage in the first 6 hours or no draining in the thorax and/or lower bleeding in the thorax.

Results: 367 anatomic lung resections were performed due to NSCLC. E: 313, C: 54, mean age 63. Postoperative hemorrhage developed in 44 (12%) of the patients treated. The initial operations of these patients were lobectomy in 33 patients (75%), pneumonectomy in 8 patients (18%), and segmentectomy in 23 patients (6%). Bleeding control could be achieved by medical treatment in 27 patients (62%), and reoperation in 17 (38%) was necessary. The bleeding centers in the re-operated patients were intercostal artery (n:6), intercostal vein (n:1), bronchial artery (n:3), segmental artery (n:1), subcarinal lymph node detected. No bleeding center was found in 5 of the patients.

Conclusion: Early hemorrhage after malignant thoracic surgery is an important cause of morbidity and mortality. Therefore, the surgical team should be familiar with the causes and treatment of hemorrhage. Multidisciplinary approach to the patient should be approached and followed closely. Bleeding control in pneumonectomy patients should be done more carefully as there is no left lung tissue to press, and should be avoided as much as possible in surgery again due to the high risk of post-pneumonectomy empyema. Thoracoscopic approach should be considered as priority when re-surgery is considered, especially in VATS patients. Medical and surgeon combinations can be used in the treatment. We recommend that attention be paid to arterial bleeding centers, especially in the first operation.

Keywords: Lung cancer, postoperative complication, hemorrhage, hematoma

[Abstract:0510] EPS-085 [Accepted: E-Poster] [Lung and Pleura Malignancies]

A Case of Male Breast Cancer with Neurofibromatosis Type 1 Presenting with Multiple Pulmonary and Pleural Nodules

Susamber Dik Altıntaş, Bülent Altınsoy

Department of Pulmonary Medicine, Bulent Ecevit University, Zonguldak, Turkey

Neurofibromatosis Type 1 (NF-1) or Von-Recklinghausen disease is an autosomal dominantly inherited syndrome characterised by neurofibromas, cafe-au-lait spots and associated with increased risk of malignancy. We diagnosed NF-1 and breast cancer in a male patient that referred us because of multiple pulmonary and pleural nodules. We report this case because it's rare. A 58 year-old male referred our center with complaints of weight loss, cough and producing sputum. he was 40 pack-year smoker and has worked as coal miner for 20 years. There were right pleural effusion and thickening, bilateral multiple pulmonary and pleural nodules, subcarinal lymphadenopathy in his thoracic computerized-tomography (CT).

On examination, mutiple, soft, dome-shaped, skin-coloured nodules as neurofibromas and 6-7 hyperpigmented macular patches as cafe-au-lait were observed. There was history of similar findings in his family members so we diagnosed NF-1. Because of CT findings we made bronchoscopy and fine needle aspiration biopsy from subcarinal lymphadenopathy. An irregular, mobile, palpable mass noticed in subareolar area of right breast. We had a consultation request from department of general surgery for biopsy. In PET-CT 28x16mm hypermetabolic nodular

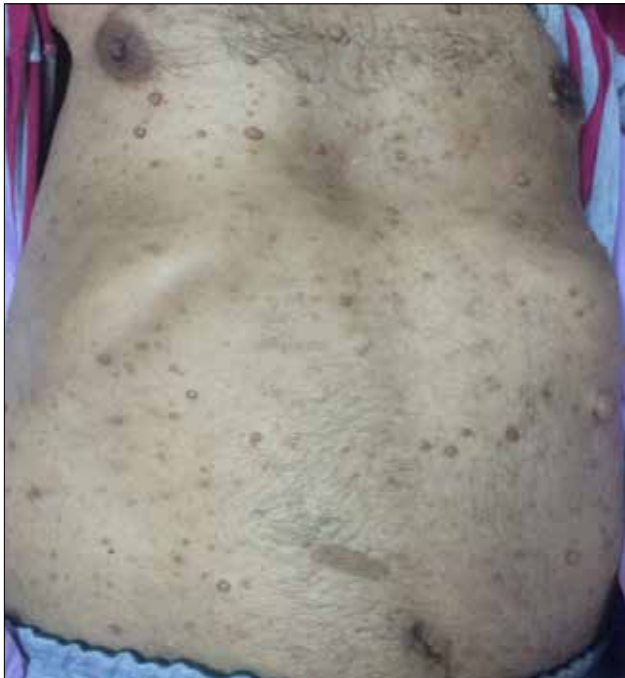

Figure 1. NF-1 Skin Lesions

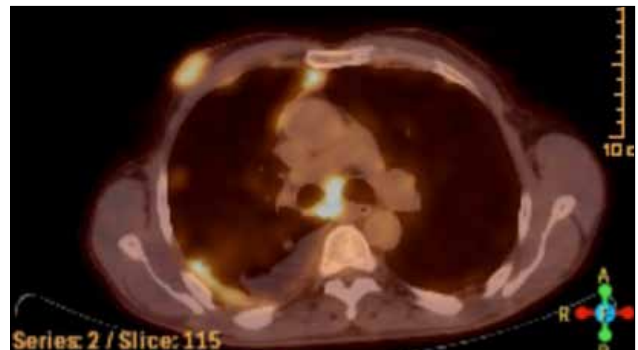


Figure 2. PET-CT Scan

lesion in right breast, 3cm hypermetabolic lymphadenopathy in right axilla, hypermetabolic subcarinal lymphadenopathy, bilateral multiple hypermetabolic metastatic pulmonary nodules and metastatic involvement in bones. Subcarinal needle aspiration biopsy result was positive for malign epithelial carcinoma infiltration, breast biopsy result was positive for invasive ductal carcinoma. NF-1 gene is a tumor suppressor gene, located on the long arm of chromosome 17, encodes neurofibromin protein. Loss of heterozygosity of NF-1 gene is predisposing for malignancy in NF-1 patients. Optic gliomas, soft tissue sarcomas, lung cancer, breast cancer, gastrointestinal stromal tumors are associated with NF-1 and they have worse prognosis. Although it's rare, thoracic manifestations of NF-1 includes; chest-wall deformities, parenchymal neurogenic tumors, pulmonary fibrosis, cystic lung disease, primary pulmonary hypertension. Women age of <50 with NF-1 have 4-5 fold increased risk in developing breast cancer and increased fatality risk compared to general population. The link of between NF-1 and breast cancer in women is well-known but the concurrent presentation of NF-1 and male breast cancer is very rare. There are only a few reported case in literature. Hence, we suggest early breast examination of males with NF-1 not to miss the diagnosis.

Keywords: Neurofibromatosis type 1, male breast cancer, pulmonary nodules

[Abstract:0511] SS-095 [Accepted:Oral Presentation] [Tobacco Control]

A Profile of E-cigarette Users, Reasons for Use and Use Behavior

Aslı Çarkoğlu¹, Ayşe Turan², Mehmet Atilla Uysal³

¹Department of Psychology, Kadir Has University, İstanbul, Turkey

²Adana Çukurova Dr. Aşkı Tüfekçi Government Hospital, Adana, Turkey

³Health Sciences University, Yedikule Training and Research Hospital for Chest Disease and Thoracic Surgery, İstanbul, Turkey

Objectives: Turkish government banned the sale of electronic cigarettes (e-cigarettes) in 2013. Yet, use of e-cigarettes has been expanding rapidly in the last few years. It is imperative to understand the reasons and ways in which this new tobacco product is being used, in order to prevent possible negative outcomes.

Methods: Aiming to better understand the user profile and use behavior, a survey was conducted with 234 e-cigarette users from a large city in the Mediterranean region of Turkey. The participants were recruited from the vaping community using snowball sampling method.

Results: Majority of the participants were male (89.74%), average age was 35±10, mostly married (52.99%). E-cigarette smokers in this study were mostly middle-class employed (27% civil servants, 20% employees, 13% healthcare professionals) with above average education (38.03% high school graduates and 47.86% were college graduate or above). Only 5.13% of the participants reported having never smoked conventional cigarettes before. Those who were ex- or current smokers reported smoking 20.48±7.64 cigarettes a day. 43.59% of the participants reported quitting conventional cigarettes after switching to e-cigarettes and 33.33% reported reducing to an average of 10 cigarettes after the switch (range is 4-10). Main reason for switching to e-cigarettes was to quit smoking (74.36%), followed by "avoiding the bad smell of cigarettes" (73.5%) and thinking that "e-cigarettes are less harmful than cigarettes" (67.09%); yet 51.28% continued to smoke cigarettes at some level. Participants reported using e-cigarettes for 3 months on average (range is 1-16 months). 45.73% reported providing the e-cigarettes via friend/acquaintance, 23.93% via online sales or 30.34% via "informal ways" such as illegal tobacco shops or smuggled good shops. 85.47% reported using e-cigarettes 6 or more times a day, inhaling 143.76±130.44 times. 69.96% of the participants reported using the e-cigarettes daily inside their homes; 44.44% regularly used it inside their work place; 30.77% reported using it in the presence of their children sometimes or on a regular bases.

Conclusion: Main reasons stated for the switch from conventional cigarettes to e-cigarettes were "to quit smoking" or "to reduce the harms of smoking". The fact that these "ready to quit" smokers were just switching tobacco products rather than quitting tobacco completely is a grave missed opportunity for the Turkish tobacco control community. This fact also serves as an urgent warning for us to re-evaluate the existing smoking cessation services available to the adult and currently healthy smoker demographic in Turkey.

Keywords: Electronic nicotine delivery systems, user profile, reasons for use

[Abstract:0515] PS-081 [Accepted:Poster Presentation] [Pulmonary Rehabilitation and Chronic Care]

Effects of Pulmonary Rehabilitation on Exercise Capacity, Muscle Strength and Quality of Life in Patient with POEMS Syndrome

Elif Sakızlı¹, Gülşah Barğı¹, Meral Boşnak Güçlü¹, Gülsan Türköz Sucak²

¹Department of Physiotherapy and Rehabilitation, Gazi University School of Health Science, Ankara, Turkey

²Department of Hematology, Bahçeşehir University, Medical Park International Hospital, İstanbul, Turkey

Objectives: Polyneuropathy, organomegaly, endocrinopathy, monoclonal gammopathy and skin changes (POEMS) syndrome is a rare paraneoplastic syndrome. The morbidity associated with POEMS syndrome depends on debilitating weakness and loss of function. Inactivity may also cause death. Moreover, morbidity may be reduced with early diagnosis and multidisciplinary approach since pulmonary rehabilitation is essential for patients. We aimed to investigate effects of pulmonary rehabilitation on pulmonary functions, respiratory and peripheral muscle strength, functional exercise capacity, physical activity, fatigue, depression and quality of life in a patient with POEMS syndrome.

Methods: A 35-year-old male, 23.23 kg/m² BMI, with complaints of decreased functional capacity and dyspnea. Rehabilitation program was initiated early after diagnosis. Pulmonary functions [spirometry], respiratory muscle strength (MIP, MEP) [mouth pressure device], muscle strength [hand-held dynamometer], functional exercise capacity [six-minute walk test (6-MWT)], fatigue [Fatigue Severity Scale], depression [Montgomery-Åsberg Depression Rating Scale (MADRS)], physical activity [metabolic holter device] and quality of life [European Organization for Research and Treatment of Cancer Quality of Life Questionnaire C30 version 3.0 (EORTCQLQ-C30)] were evaluated. Aerobic exercise (bicycle, 60-80% of maximum HR, 30 min/day, 2 days/week, 8 weeks) and inspiratory muscle training (IMT) (30% of MIP, 30 min/day, 7 days/week, 8 weeks) were applied.

Results: Patient's MIP ($\Delta 28\text{cmH}_2\text{O}$, 112 to 140; $\Delta 22\%$, 90% to 112%) , MEP ($\Delta 23\text{cmH}_2\text{O}$, 134 to 157) , 6-MWT distance ($\Delta 51.3\text{m}$, 562.2m to 613.5m) , fatigue ($\Delta 9\text{score}$, 23p to 14p) , depression ($\Delta 6\text{score}$, 10p to 4p) and global health status sub-scale of EORTCQLQ-C30 ($\Delta 8.4\%$, 41.6% to 50%) clinically improved; Quadriceps femoris muscle strength ($\Delta 75\text{N}$, 396N to 321N; $\Delta 15\%$, 79% to 64%) was decreased. Pulmonary functions and hand grip strength ($\Delta 4\text{kg}$, 27kg to 31kg) were protected. Total energy expenditure ($\Delta 694\text{joules}$, 12310j to 11616j) , physical activity duration ($\Delta 1.10\text{hours}$, 5.08h to 3.58h) and active energy expenditure ($\Delta 1277\text{joules}$, 5462j to 4185j) were decreased, sleep duration ($\Delta 0.50\text{hours}$, 5.53h to 6.43h) were increased, average metabolic equivalent (MET) remained same. After rehabilitation patient became minimal active as patient was previously active according to number of steps ($\Delta 5582\text{steps}$, 10773s to 5191s) .

Conclusion: This is a case report firstly demonstrating beneficial effects of pulmonary rehabilitation on functional exercise capacity, respiratory muscle strength, fatigue, depression and quality of life in a patient with POEMS syndrome. Rehabilitation program protects pulmonary functions and upper extremity muscle strength. Unfortunately, lower extremity muscle strength gradually reduced despite comprehensive program. Strengthening exercises must be applied in order to avoid rapid weakening.

Keywords: POEMS syndrome, pulmonary rehabilitation, exercise capacity

[Abstract:0518] PS-047 [Accepted:Poster Presentation] [Lung and Pleura Malignancies]

A Case of Breast Cancer Accompanied by Endobronchial Lesion that Completely Occludes the Left Main Bronchus

Necati Solak¹, Selim Şakir Erkmén Gülhan¹, Seray Hazer¹, Pınar Bıçakçioğlu¹, Zafer Aktaş²

¹Department of Chest Surgery, Ankara Atatürk Chest Diseases and Thoracic Surgery Training and Research Hospital, Ankara, Turkey

²Department of Interventional Pulmonology, Ankara Atatürk Chest Diseases and Thoracic Surgery Training and Research Hospital, Ankara, Turkey

Thorax is a region where distant metastases are frequently observed due to high hematologic and lymphatic vascularity. Various malignant neoplasms that develop can metastasize to lung, mediastinal lymph nodes, pleura, pericardium or chest wall. However, endobronchial metastases and involvement of extra pulmonary tumors are very rare. Depending on the metastases, symptoms may occur due to mass effect and invasion. Patients may be asymptomatic, but shortness of breath, dry cough, and localized rhonchus can be detected. In addition to these, pleural-pericardial effusion and associated dyspnea, chest pain and compression symptoms can be observed. In this case report, endobronchial lesion in the left main bronchus is described in the patient with breast cancer.

In the postero-anterior chest X-ray of a 65-year-old female patient who had undergone bilateral mastectomy operation due to breast cancer in 2014 and who received 6 months of chemotherapy and radiotherapy; a massive effusion was detected on the left side, and she was hospitalized for further examination and treatment of the complaint of shortness of breath. Ponction was performed in the patient in the left posterior side and serous fluid was removed, and a 10 F pluerocan catheter was inserted. Bronchoscopy revealed a hemorrhagic endobronchial lesion (EBL) that was open up to the right system subsegments and completely obstructed the left main bronchus, and biopsy was taken. The procedure was terminated due to hemorrhage. Chest CT revealed a central mass lesion which obliterated pleural fluid in the left hemithorax and left upper lobe bronchus in the left hilar region, whose borders were not distinguishable from the hilar LAP and distal collapse-consolidation areas, and which caused irregular narrowing in the left main bronchus. The clot that was completely obstructing the left main bronchus was coagulated with rigid bronchoscopy and EBL that was completely obstructing the distal part of the left main bronchus was coagulated and removed with mechanical resection. The left lower lobe was fully opened but the lesion invaded the left upper lobe entry and the entry was completely obstructed. The pathology of the left main bronchial EBL was reported as malignant epithelial tumor infiltration compatible with breast carcinoma metastasis. The closed pleurodesis was performed with talc in the patient whose effusion was drained, and the drainage was terminated after 1 day and the patient was discharged.

It may be necessary to obtain histological tissue from the lesions with the suspicion of metastasis in order to eliminate the possibility of the second primary tumor, particularly when a long time passes after the treatment of the primary tumor. Bronchoscopy may be useful in endobronchial involvement. Endobronchial lesion was observed with bronchoscopy in the patient who consulted with breast cancer and dyspnea, which was described in our case, and histological diagnosis was made by partial excision with rigid bronchoscopy. In conclusion, it should be kept in mind that patients with primary cancer and pleural effusion may have endobronchial lesions. In this study, a case of endobronchial lesion, which is a rare metastasis of breast cancer, has been presented.

Keywords: Breast cancer, endobronchial lesion, pleural effusion

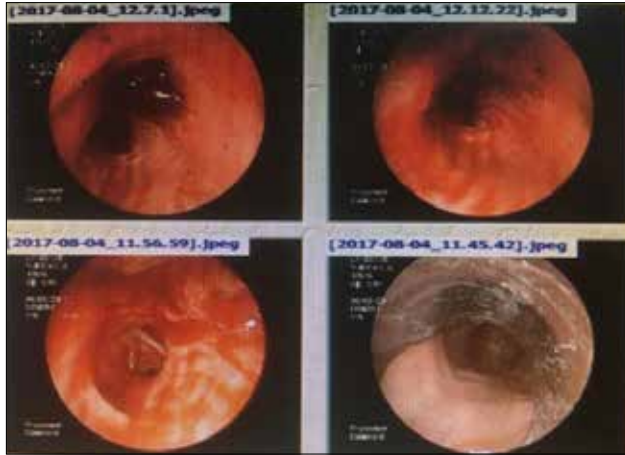

Figure 1. Rigid bronchoscopy: endobronchial lesion images

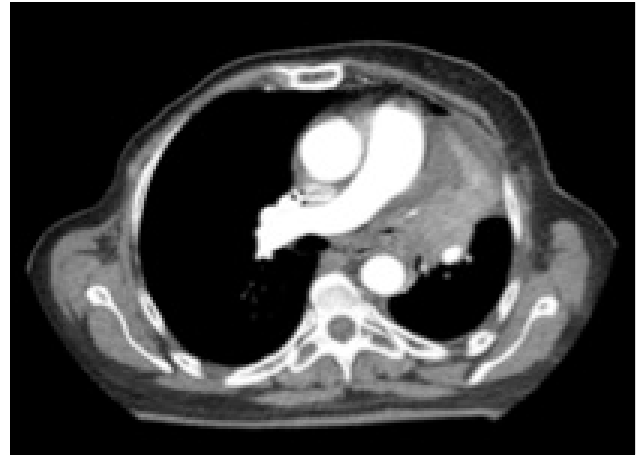


Figure 2. Thoracic CT: endobronchial lesion

[Abstract:0519] PS-156 [Accepted:Poster Presentation] [Clinic Problems - Others]

Airway Obstruction Causing Stridor: Omega Epiglottitis?

Önder Öztürk¹, Gönül Seven Yalçın¹, Deniz Dilek², Ahmet Akkaya¹

¹Department of Chest Diseases, Süleyman Demirel University School of Medicine, Isparta, Turkey

²Department of Otorhinolaryngology, Süleyman Demirel University School of Medicine, Isparta, Turkey

Introduction: Strictures in the airway develop due to congenital (webber, vascular anomalies, tracheomalacia, omega epiglott) and acquired causes (long-term intubation, tumoral structures, collagen tissue diseases, chronic inflammation) . We wanted to present our case because of being an interesting case that both congenital and acquired causes which lead to airway obstruction are seen together.

Case Presentation: A 38-year-old female patient admitted to our clinic due to increased dyspnea symptoms has a history of hypertension, myasthenia graves, and endovascular involvement caused by right and left internal carotid artery (ICA) aneurysms. The patient who has been a bite in her voice since childhood, has been using nebulizer device with asthma diagnosis for 7 years. 2 years ago, she was operated because of the residual thymus tissue. She had stridor in her physical examination. Patient underwent ENT examination. Omega epiglottis and subglottic tracheal stenosis were detected (Figure 1) . The stenosis was evaluated as post-intubation stenosis, where the epiglottis did not obstruct the airway passage (Figure 2 a-c) . She was referred to a center for tracheal surgery.

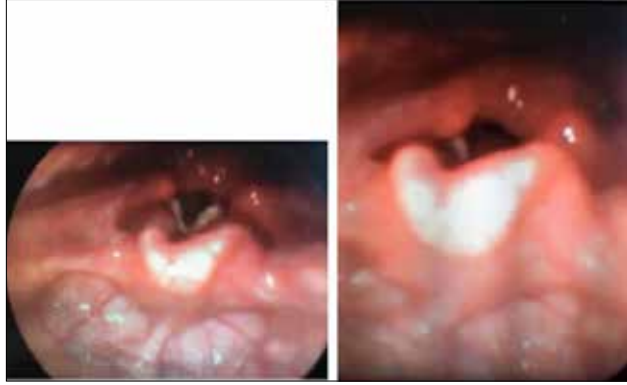

Figure 1. Omega epiglottis

Conclusion: In our case, it was decided that stenosis developed after intubation and omega epiglottis was not the reason of stenosis because of atrophy due to age. Omega epiglottis is especially detected in childhood, but rarely in adulthood and may be the reason of difficult intubation. As in our case, we think that it is necessary to evaluate the difficult intubation risk that can be caused by the pharyngolaryngeal abnormalities by indirect laryngoscope in order to prevent the development of stenosis after intubation.

Keywords: Tracheal stenosis, laryngeal abnormalities, stridor, omega epiglottis

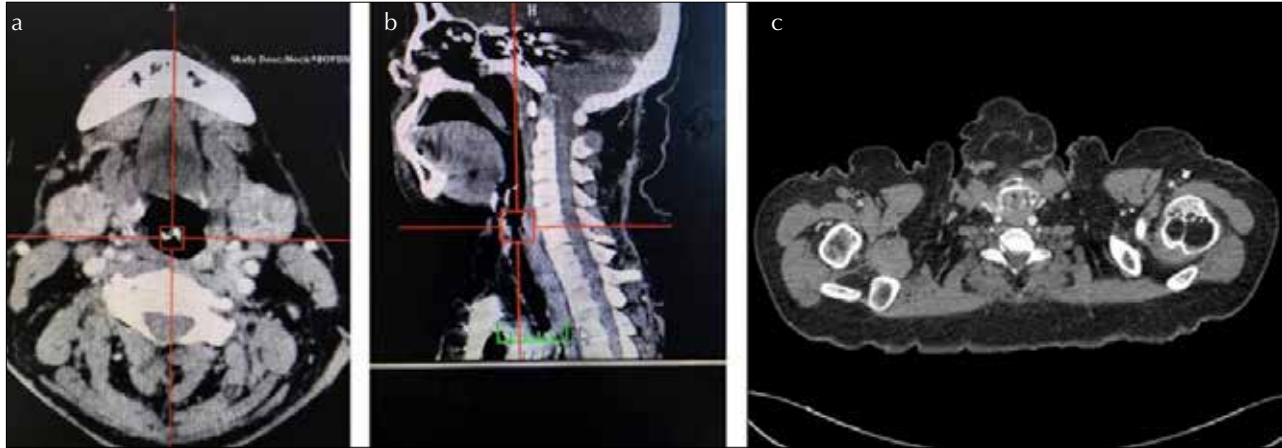


Figure 2. a-c. Omega glottis (a), Subglottic tracheal stenosis (b), Subglottic tracheal stenosis (c) shown on Thorax CT

[Abstract:0520] PS-293 [Accepted:Poster Presentation] [Respiratory Failure and Intensive Care]

Multiple Organ Failure due to Synthetic Cannabinoid 'Bonzai' Intoxication

Sinem Güngör, Burcu Fikri İleri, İlim Irmak, Ahmet Aytekin, Huriye Berk Takır, Cüneyt Saltürk, Özlem Yazıcıoğlu Moçin, Nalan Adıgüzel

Health Sciences University, İstanbul Süreyyapaşa Chest Diseases and Thoracic Surgery Training and Research Hospital, İstanbul, Turkey

Objectives: Synthetic cannabinoids 'bonzai' is easy to access and inexpensive, for these reasons its use is increasing day by day in all ages. Beside Bonzai's pleasurable features, it has simple complaints such as headache, nausea, palpitation, seizures, cardiac dysrhythmia, and serious problems as acute myocardial infarction, intracranial hemorrhage, rhabdomyolysis, coma.

Table 1. Laboratory follow-up of the case

	AST	ALT	BUN	Creatinin	CK-MB	INR	aPTT	WBC	Plt
First day	930	557	79	0.11	64762	3.03	90	25800	114000
2. day	1460	488	55	2.54	>302	1.7	102	17800	31000
3. day	1211	386	45	2.37	>302	1.0	43	17300	22000
7. day	261	163	77	2.47	23	1.10	35	13800	93000
14. day	88	62	95	2.35		1.18	38	20500	349000
21. day	41	17	90	3.56		1.16	41	20300	277000
28. day	31	50	153	2.78		1.32	47	15300	258000
35. day	23	66	66	1.10		1.22	42	11100	230000
Last day	27	58	57	0.78		1.03	28	9600	226000

We presented a case with multisystem organ failure due to bonzai in order to share the diagnosis and follow-up difficulties, clinical course, treatment management.

Case Presentation: A 30-year male was found to unconscious in street and was brought to emergency service. Anamnesis could not be taken because he has no relatives, GCS: 3, pH:6.96, PaCO₂:93, PaO₂:301, Be:-17, lactat: 6.9, SaO₂:99%, thorax, abdominal, cranial CT had done. Trauma findings were not detected and with preliminary diagnosis of intoxication patient transferred to the ICU. Orotracheal intubated patient started to follow with MV in PCV mode and FiO₂ 100%. At thorax CT, extensive infiltration of the left lung was seen and with suspicion of aspiration tazobactam was initiated. As patient was hypotensive IV hydration, noradrenalin and dobutamine were applied to make mean arterial pressure 65 mmHg. Because of bradycardia and elevated troponin patient was consulted with cardiology; EF was assessed as low, right ventricular dilatation, coronary spasm due to chemical toxicity determined, troponin and ECG follow-up was recommended. Continuous venovenous hemodiafiltration was initiated on BUN:80, Creatinine:3.7, K:5.2, HCO₃:17, CK:64762, rhabdomyolysis and oliguria. We learned from his family that he used bonzai. On the 8th day of hospitalization, he was extubated and followed by intermittent nasal oxygen and NIMV. Intermittent CVVHDF was continued by following urea, creatinine, CK levels and terminated on 26th day. On the third day of admission because of radiological progression and fever imipenem, anidulafungin and teicoplanin were started empirically. On the 3rd day of this treatment, thorax CT was performed due to continued fever. In CT, thin reticulonodular infiltration progressing to consolidation in all lung areas and groundglass densities in the central region were observed, radiologically it was found to be compatible with pneumocystis carini infection and treatment was continued with trimetoprim sulfamethoxazole, methylprednisolone was added. Clinical and radiological response was obtained, patient followed in room air, mobilized with physiotherapist, and discharged at 40th day of admission with recommendation of psychiatry and chest diseases polyclinic control.

Conclusion: The use of synthetic cannabinoid in cases with different clinical course and signs of intoxication should be considered and patients should followed closely.

Keywords: Bonzai, multiple organ failure, follow up

[Abstract:0521] PS-083 [Accepted:Poster Presentation] [Pulmonary Rehabilitation and Chronic Care]

Physiological Responses to Maximal Exercise Capacity and Muscle Strength in Survived Hematopoietic Stem Cell Transplantation Recipients

Gülşah Barğı¹, Meral Boşnak Güçlü¹, Gülsan Türköz Sucak²

¹Department of Physiotherapy and Rehabilitation, Gazi University School of Health Sciences, Ankara, Turkey

²Department of Hematology, Bahçeşehir University Medical Park Hospital, İstanbul, Turkey

Objectives: Pulmonary functions, exercise capacity and muscle strength deteriorate in survived hematopoietic stem cell transplantation (HSCT) recipients due to toxic effects of chemotherapy, radiotherapy, conditioning regimens and/or cortico-

steroid use before HSCT, prolonged stay of recipients in rooms with laminar airflow and strict infection control rules during process of HSCT. There are also limited number of studies demonstrated pulmonary function abnormalities, decreased maximal exercise capacity, respiratory and peripheral muscle weakness in recipients. Current study was planned since no study compared pulmonary functions, maximal exercise capacity, respiratory and peripheral muscle strength between recipients and healthy controls in the literature.

Methods: Allogeneic (91.7%, post-HSCT status >100 days) and autologous (8.3%) HSCT recipients (n=72, 40.04±14.16 years) and healthy controls (n=50, 37.86±11.21 years) were included and compared. Pulmonary functions [spirometry], maximal exercise capacity [Modified-Incremental Shuttle Walk Test (ISWT)], inspiratory and expiratory muscle strength (MIP and MEP, respectively) [mouth pressure device] and peripheral muscle strength [hand-held dynamometer] were evaluated. Vital signs, dyspnea and fatigue perceptions [Modified Borg Scale] were recorded as before and after measurements of Modified-ISWT.

Results: Recipients' Modified-ISWT distance (-173.83 m, 95%CI=-246.41 to -101.26 m, p<0.001) , Modified-ISWT% distance (p<0.001) , resting oxygen saturation (p<0.001) , Δ heart rate (p=0.036) , Δ diastolic blood pressure (p=0.001) , MEP (p=0.004) , MEP% (p=0.003) , left (p=0.006) and right (p=0.004) quadriceps femoris muscle strength were statistically significantly lower; resting heart rate (p=0.040) and Δ systolic blood pressure (p=0.004) were statistically significantly higher compared with healthy controls. Pulmonary functions and MIP were similar in groups (p>0.05) . Fifty three (73.6%) recipients' Modified-ISWT distance, 47 (65.3%) recipients' MEP and 40 (55.6%) recipients' quadriceps femoris muscle strength was lower than lower limit of 95%CI (781.69 to 884.31m) , (148.13 to 169.15cmH₂O) and (291.91 to 352.75N) of healthy controls, respectively.

Conclusion: Decreased maximal exercise capacity (80.6%) , lower extremity muscle weakness (88.9%) and expiratory muscle weakness are mostly prevalent rather than inspiratory muscle weakness among recipients, while recipients' pulmonary functions are preserved. Oxygen desaturation, abnormalities in blood pressure and heart rate values seen during resting and exertion show us poor cardiovascular and pulmonary responses to exercise in survived HSCT recipients. Effects of various exercise training programs on aforementioned outcomes should be investigated in survived HSCT recipients.

Keywords: Stem cell transplantation, pulmonary functions, muscle strength, exercise capacity

[Abstract:0522] SS-028 [Accepted:Oral Presentation] [Pulmonary Rehabilitation and Chronic Care]

Effects of Upper Extremity Aerobic Exercise Training on Cardiopulmonary Outcomes in Hematopoietic Stem Cell Transplantation Recipients

Gülşah Barğ¹, Meral Boşnak Güçlü¹, Zübeyde Nur Özkurt², Münci Yağcı²

¹Department of Physiotherapy and Rehabilitation, Gazi University School of Health Sciences, Ankara, Turkey

²Department of Hematology, Gazi University School of Medicine, Ankara, Turkey

Objectives: Pulmonary functions, exercise capacity, mood, peripheral and respiratory muscle strength deteriorate in patients with hematopoietic stem cell transplantation (HSCT) . Healing effects of various exercise training programs except upper extremity aerobic exercise training on aforementioned parameters has been demonstrated in recipients. Moreover, while lower extremity muscle functions are preserved during process owing to lower extremity exercises, upper extremity muscle functions and exercise capacity are impaired in recipients. Therefore, we aimed to investigate effects of upper extremity aerobic exercise training on pulmonary functions, maximal exercise capacity, respiratory and peripheral muscle strength, anxiety and depression in HSCT recipients.

Methods: Of 46 HSCT recipients, only 32 recipients met inclusion criteria and were included in this prospective, randomized controlled and single-blinded study. Recipients were divided into intervention (n=16, 46.88±13.08 year, 5M, 13 allogeneic) and control (n=16, 42.75±15.29 year, 10M, 13 allogeneic) groups. Upper extremity aerobic exercise training (60-80% of maximum heart rate, 30 min/day, 3 days/week, 6 weeks) was applied to intervention group. Alternate, combined arm and breathing exercises were given as home program to control group. Pulmonary function using spirometer, maximal exercise capacity using Modified-Incremental Shuttle Walk Test (ISWT) , respiratory muscle strength (MIP, MEP) using mouth pressure

device, peripheral muscle strength using hand-held dynamometer, anxiety and depression using Hospital Anxiety and Depression Scale were evaluated. Vital signs, dyspnea and fatigue perceptions (Modified Borg Scale) were recorded before and after Modified-ISWT.

Results: Baseline demographic and clinical characteristics were similar in groups ($p>0.05$). After 6-week training program, Modified-ISWT distance ($p<0.001$), maximal heart rate ($p=0.019$), percent heart rate reserve ($p=0.009$), resting systolic blood pressure ($p=0.007$), Δ respiratory rate ($p=0.016$), Δ fatigue ($p=0.035$), MIP ($p=0.012$) and MEP ($p=0.039$) significantly improved in intervention group compared with controls. Changes in pulmonary functions, peripheral muscle strength, anxiety and depression were similar between groups ($p>0.05$). FEV1/FVC, PEF, Modified-ISWT distance, MIP, MEP, depression, workload, quadriceps femoris and handgrip muscle strength significantly improved within intervention group; Modified-ISWT distance and quadriceps femoris muscle strength were significantly increased, anxiety was decreased within control group ($p<0.05$).

Conclusion: Upper extremity aerobic exercise training improves maximal exercise capacity, respiratory muscle strength and cardiopulmonary responses to exercise in recipients with survived hematological malignancies. It is also effective and safe method as an alternative to lower extremity aerobic exercise training in recipients. To improve peripheral muscle strength, pulmonary functions and mood in recipients, effects of upper extremity aerobic exercises combined with other exercise modalities such as progressive resistance exercises, inspiratory and expiratory muscle trainings should be investigated.

Keywords: Hematopoietic stem cell transplantation, upper extremity, aerobic exercise training, pulmonary functions, exercise capacity, muscle strength

[Abstract:0523] SS-132 [Accepted:Oral Presentation] [Pulmonary Rehabilitation and Chronic Care]

Predictors of Maximal Exercise Capacity in Hematopoietic Stem Cell Transplantation Recipients

Gülşah Barçın¹, Meral Boşnak Güçlü¹, Gülsan Türköz Sucak²

¹Department of Physiotherapy and Rehabilitation, Gazi University School of Health Sciences, Ankara, Turkey

²Department of Hematology, Bahçeşehir University Medical Park Hospital, İstanbul, Turkey

Objectives: While hematopoietic stem cell transplantation (HSCT) recipients are struggling against hematological malignancy itself and toxic effects of its treatments after transplantation, they encounter considerable decline in maximal exercise capacity. Despite the fact that maximal exercise capacity evaluated using Incremental Shuttle Walk Test (ISWT) of recipients has been investigated in a few studies, determinants of decreased maximal exercise capacity is not still known. Therefore the aim of this study was to investigate the relationship between maximal exercise capacity and blood levels, pulmonary functions, respiratory and peripheral muscle strength, corticosteroid use before and after HSCT and also to determine the best predictor of maximal exercise capacity in HSCT recipients.

Methods: Seventy two HSCT recipients (40.04 ± 14.16 years, 28F, 44M, 66 allogeneic (post transplantation status over 100 days), 6 autologous) were included. Blood levels of hemoglobin, platelet, albumin, total protein, as well as status of corticosteroid use before and after HSCT of recipients were recorded. Pulmonary functions using spirometry, inspiratory and expiratory muscle strength (MIP and MEP, respectively) using mouth pressure device, peripheral muscle strength using hand-held dynamometer and maximal exercise capacity using Modified-ISWT were evaluated.

Results: Modified-ISWT distance of 58 (80.6%) recipients was lower than 80% of predicted values. Modified-ISWT distance was statistically significantly correlated with age ($r=-0.637$, $p<0.001$), height ($r=0.289$, $p=0.014$), quadriceps femoris muscle strength ($r=0.410$, $p<0.001$), hemoglobin ($r=0.556$, $p<0.001$), platelet ($r=0.263$, $p=0.026$), albumin ($r=0.446$, $p<0.001$), total protein levels ($r=0.339$, $p=0.008$), MIP ($r=0.267$, $p=0.023$) and MEP ($r=0.411$, $p<0.001$). There was no correlation between Modified-ISWT distance and pulmonary functions, quadriceps femoris muscle strength%, MIP%, MEP%, corticosteroid use before and after HSCT ($p>0.05$). Multiple regression analysis conducted in 72 recipients demonstrated that 60.1% variance in Modified-ISWT distance was explained by age ($R^2=58.7\%$, $p<0.001$), MEP ($R^2=31.3\%$, $p=0.002$) and non-dominant quadriceps femoris muscle strength ($R^2=23.7\%$, $p=0.018$).

Conclusion: Age, expiratory and lower extremity muscle strength are considerable predictors of reduced maximal exercise capacity in HSCT recipients. Maximal exercise capacity worsens with decreasing height, blood levels of hemoglobin, platelet, albumin, total protein, respiratory and peripheral muscle strength as well as increasing age. Pulmonary functions and corticosteroid use at any time of HSCT do not influence maximal exercise capacity. Respiratory and peripheral muscle strengthening exercises to improve or protect exercise capacity are needed in survived HSCT recipients.

Keywords: Stem cell transplantation, pulmonary functions, muscle strength, exercise capacity

[Abstract:0524] PS-257 [Accepted:Poster Presentation] [Health Policies]

Is There a Business Stagnation in Private Hospitals?

Sedat Altın, Fatma Esra Günaydın, Thierry Sibemona, Esmâ Nur Aktepe, Sibel Emre, Handan Altın

Health Sciences University Yedikule Chest Diseases and Surgery Training and Research Hospital, İstanbul, Turkey

Objectives: Despite the increasing private sector investments in the health care system, it has been reported that satisfaction with health care given in private hospitals is lower than in the public sector. It was aimed to investigate the situation of the private sector from the data of health services in 2016.

Methods: Percent proportional comparisons were made in the estimates from the 2015 and 2016 Health Statistics Yearly data. $p < 0.05$ was considered significant.

Results: While 29.2% (22.655) of specialist doctors active in 2015 worked specially, this number decreased to 28.2% with the decrease of 484 specialist physicians in 2016. In total, the total number of outpatient clinics decreased from 77.217.044 (18.4% of the total) in 2015 to 6.071.668 (7.8%) in 2016 and to 71.147.878 (15.9%) . Both numerical and proportional decline in terms of 2015 was significant ($p < 0.05$) . The private medical center decreased by 35 (4.4%) compared to 2015 in 2016, while the number of private outpatient clinics decreased by 19 (5.3%) . In the number of private hospitals, the number of beds increased by 3,500, from only 20% to 21.6%, despite only three increases. In private medical centers, 27 million inspections in 2015 decreased by 18% to 22 million. The number of examinations in private outpatient clinics also decreased by 12% to 461.013 in 2016 from 523.694 in 2015. The reduction rates in the number of examinations in private medical centers and private clinics were statistically more significant ($p < 0.01$) than the decrease in private hospitals. 31,3% (4.237.453) of 13.533.117 patients admitted to a total hospitalization in 2015 were hospitalized in private hospitals, which decreased 4.5% in 2016 to 4.048.696. The decrease in total hospitalization rate was calculated as 1.2%. Despite the 0.4% decrease in total admission, the increase in the public was 1.2%. No significant difference was found ($p > 0.05$) . On the other hand, the number of days of participation increased by 4.1% in the public sector ($p < 0.05$) while it decreased by 2.6% in 2016 according to 2016. 11.3% of the chest diseases polyclinic services employed by the private sector and 20.2% of the inpatient services are covered in the private sector by 20% (405 experts) of the chest diseases specialists. Bronchoscopy from interventional procedures was also performed in private hospitals with a total of 7.7%. Among the imaging methods, the private sector owns 23%, 14% in CT, 20% in USG, 14% in Doppler, 18% in Eko and 27% in Mammography.

Conclusion: It has been seen that the share of the private sector, which has a relatively higher share of the health system rapidly after 2007, is gradually decreasing. Although private health spending has increased over the years, the share of private health care institutions has decreased from 32.5% to 21.5% of total expenditure.

Keywords: Private hospital, health service, health expenditure

[Abstract:0526] SS-101 [Accepted:Oral Presentation] [Thoracic Surgery]

Tracheo-bronchial Foreign Body Aspirations Resulting in Death

Ömer Önal, Ömer Faruk Demir

Objectives: Foreign body aspirations are one of the most important causes of accidental deaths in childhood. The aim of this study is to evaluate the fatal complications that may be encountered during and after bronchoscopy and to discuss the issues that need to be considered to prevent these complications.

Methods: Under 16 years of age, 1953 patients in whom foreign body was removed between January 1987 to January 2017 with rigid bronchoscopy were retrospectively evaluated. Seventeen cases that resulted in death were included in the study. The age and gender of the patients, foreign body type, aspiration location and the complications causing death were evaluated.

Results: The mortality rate was found to be 0.87%. Of the patients, 58.8% (n=10) were male. The mean age was 5.2 ± 2.4 (6 months-9 years) . Foreign bodies and their localizations are summarized in Table 1. Most of the foreign bodies were found to be located in the carina (64.7%) . Of the aspirated foreign bodies, 76.5% had a characteristic of swelling by absorbing water. Difficulty in ventilation was seen in these patients because during the removal, the foreign body broke into pieces and spread in the distal airways. A transparent foreign body just below the vocal cords in a patient could not be noticed in the first entrance. It was able to be detected while withdrawing the bronchoscope. The complications that occurred during and after bronchoscopy and caused death are presented in Table 2. The most common complications were hypoxia, bradycardia (41.2%) and bronchospasm (35.2%) , respectively. Two patients had destruction due to prolonged exposure to foreign body in respiratory tracts. Bleeding developed with the removal of the foreign body, and the pus, which accumulated in the distal side, spread to the respiratory system. Bleeding was stopped with cold saline irrigation but the patients died due to sepsis and respiratory insufficiency in the intensive care units.

Conclusion: Foreign bodies such as stone, soil, cement, sugar, cooked dry legumes which have the potential to absorb liquid can swell and cause complete obstruction of the airways. At the same time, it can easily break down and obstruct the distal airways and require the application of high ventilation pressure. This may increase the risk of pneumomediastinum and pneumothorax development. In addition; as the number of operations in the respiratory tract increases, such as the use of excessive amount of saline for washing and recurrent aspirations, the frequency of laryngospasm and bronchospasm increases. Transparent foreign bodies can easily be missed out by sticking to the mucous membranes of the respiratory tract. For this reason, the region immediately under the vocal cords should be examined carefully with bronchoscope while both entering and exiting. Foreign bodies may swell with secretion in the respiratory tracts and may easily break into pieces, or by causing edema and spasms in the respiratory tract, they may cause sudden respiratory failure. Therefore, we recommend rigid bronchoscopy as soon as possible in the presence of foreign body aspiration.

Keywords: Bronchoscopy, child, foreign body aspiration

Table 1. Foreign bodies removed from patients and their localizations

Foreign Body	Localization	Number of Patients (n/%)
Stone - soil	carina	3 (17.6)
Medication tablet	carina	2 (11.8)
Piece of plastic toys	carina	2 (11.8)
Powder cement	carina	2 (11.8)
Candy	carina	2 (11.8)
Boiled white beans	Right main bronchus/ left main bronchus	2 (11.8)
Dried nuts	Right main bronchus/ left main bronchus	2 (11.8)
Pen cap	Trachea	1 (5.9)
Transparent plastic	Trachea	1 (5.9)

Table 2. Complication developing during bronchoscopy and then and causing deaths

Complications	Number of patients n (%)
Hypoxia and bradycardia during bronchoscopy	7 (41.2)
Laryngeal edema, laryngeal spasm, bronchospasm requiring mechanical ventilation	6 (35.2)
Endobronchial bleeding and purulent secretion	2 (11.8)
Pneumothorax, pneumomediastinum	2 (11.8)

[Abstract:0527] EPS-026 [Accepted: E-Poster] [Clinical Problems - Diffuse Parenchymal Lung Disease]

A Case of Sarcoidosis with Respiratory Failure

Demet Polat, Bahar Ulubaş

Department of Chest Diseases, Mersin University School of Medicine, Mersin, Turkey

A 45-years-old female patient. He presented to the emergency department with progressive shortness of breath for a week. He has had dry cough and dyspnea for 3 years. His medical history was he had pulmonary sarcoidosis for 3 years and used prednisolone for 6 months. He had been using prednisolone 32 mg over the last 15 days. He has used an oxygen concentrator at home because of hypoxic respiratory failure. He never smoked. Family history of the patient was insignificant. There was not occupational and environmental exposure. Laboratory parameters were as follows: leukocyte count: $23.52/\text{mm}^3$ (68% neutrophil), C-reactive protein: 3.57, sedimentation:37 mm/saat. Serum electrolytes, renal and liver function tests were normal. Arterial blood gas was: pH: 7.39, PO_2 : 49 mmHg, PCO_2 : 54 mmHg, HCO_3 : 32 mmol/L and SPO_2 : 78.9 (on room air). Posteroanterior chest x-ray showed bilaterally reticulonodular infiltrates in the middle and lower zones (Figure 1). The patient was hospitalized for further examination and treatment. Empirical antibiotics started. Pulmonary function test results were as follows: Fev_1 : 1.43 50%, Fvc : 1.46 44% and Dlco : 74%. In thorax computed tomography (CT); Mediastinal and bilaterally hilar, lymph nodes were present (the largest 15-20 mm. in diameters) . Bilateral diffuse ground glass opacity and occasional air bronchograms were detected (Figure 2). Antinuclear antibody, perinuclear antineutrophil cytoplasmic antibody (P-ANCA) , cytoplasmic-ANCA tests were negative. Methotrexate (7,5 mg/week) was initiated considering the progressive clinical status of the patient who received 32 mg/day prednisolone

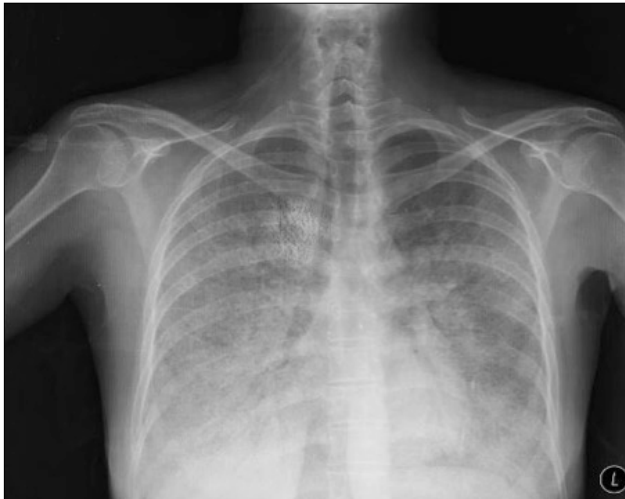

Figure 1. Bilateral reticulonodular densities on PA chest X-ray

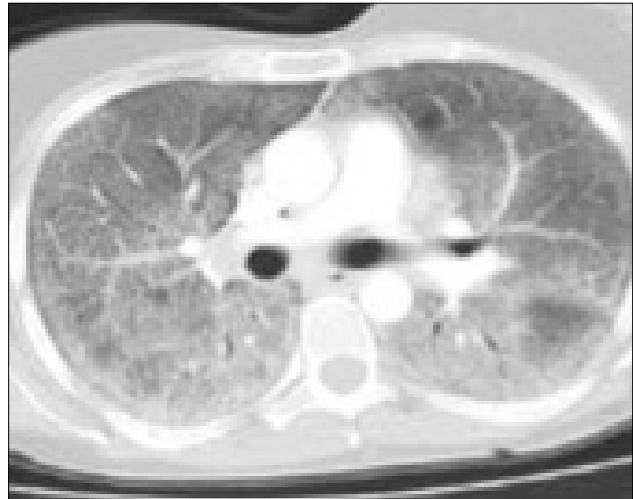


Figure 2. Thorax CT section before methotrexate treatment

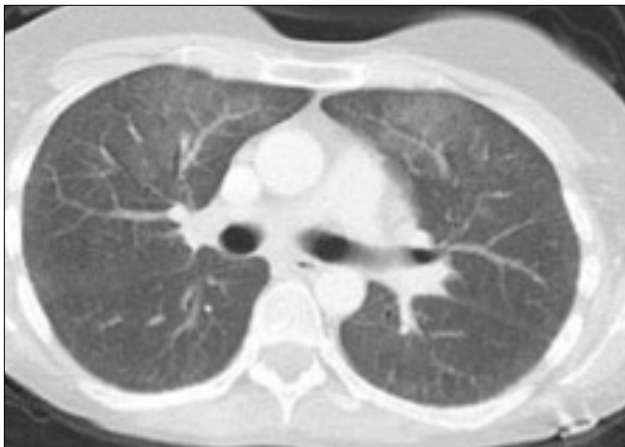

Figure 3. Thorax CT section at 6th month of methotrexate treatment

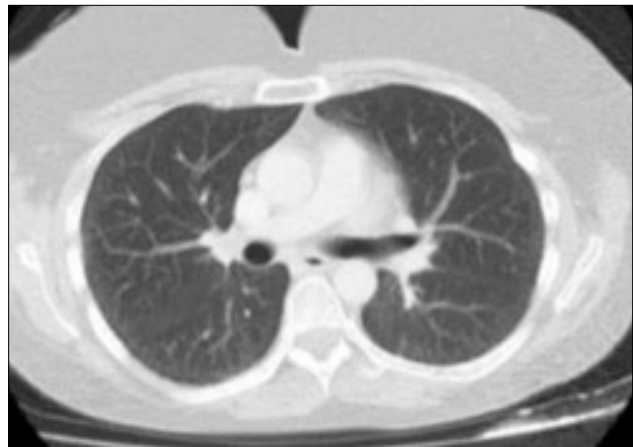

Figure 4. Thorax CT section at the 12th month of methotrexate treatment

therapy with sarcoidosis diagnosis. Clinical improvement was observed in the first 2 weeks. There were no side effects. At 6 months of treatment, control thorax computed tomography revealed that mediastinal and bilaterally hilar lymph nodes were present (the largest 12 mm. in diameters). There was regression of ground glass densities in both lung parenchyma. Control pulmonary function test results were as follows: Fev1: 2.42 88%, fvc: 2.51 79%, fev1/fvc: 96%. In arterial blood gas taken at the 6th months of treatment: pH: 7.40 pCO₂: 42 mmHg pO₂: 105 mmHg SpO₂: 98 (on room air). At 12th months of treatment, control thorax computed tomography revealed that mediastinal, non-pathologic lymph nodes were detected. Other findings were evaluated as stable according to 6th month's tomography (Figure 4). The patient has been followed asymptotically for 6 years.

Keywords: Methotrexate, respiratory failure, sarcoidosis

[Abstract:0529] PS-237 [Accepted:Poster Presentation] [Tobacco Control]

Electronic Cigarette and Quit smoking Quest in Twitter: Preliminary Study

Mehmet Atilla Uysal¹, Aslı Çarkoğlu², Ahmet Kurnaz³

¹Health Sciences University, Yedikule Training and Research Hospital for Chest Disease and Thoracic Surgery, İstanbul, Turkey

²Department of Psychology, Kadir Has University, İstanbul, Turkey

³Department of Political Science and Public Administration, Çanakkale Onsekiz Mart University School of Political Science, Çanakkale, Turkey

Objectives: Use of electronic cigarettes (e-cigarettes) has been dramatically increased in last few years. Although the sales of e-cigarettes were banned since 2013, they can still be easily purchased via online sales, and its' advertisement is rife in the social media. Users can easily exchange advise on how to produce and use e-cigarettes with interested others and recruit new users. Thus, we aimed to take a closer look at the contents of the shared information about e-cigarettes on one such media outlet, Twitter.

Methods: Scraping data progressively on social media is a new cost-free method. Thus, we tracked twitter for 102 days (from 25.09.2017-26.01.2018) searching for key words "electronic cigarettes", "ecigarettes", or e-cigarettes" using R3.2.3 software and collected 515 tweets via Representational State Transfer-Application Programming Interface (REST-API). Terms not within 99.99% of the resulting data matrix were eliminated, terms with median=0.74 and larger that are weighted using the tf-df method. This data was classified using unsupervised topic modelling. Resulting dataset was further reduced and classified via scraping (LDA) and 15 topics were established.

Results: 15 possible topics and keywords which were extracted from analyses were presented in Table. First 10 terms under each topic were prioritized for this presentation. Words such as tobacco (1), dependence (2), cancerogen (3), substance (4), containing (7), waterpipe (12), liquid (13), liver (23) indicated a general "harms of e-cigarettes" idea. Terms such as liquid (1) atomiser (4) , IQS (9) , health, aroma, variety, price, e-cigarette device pointed to "product advertising and marketing" whereas topic 12 terms such as ---- were more concentrated around "sales". Text under topic 8 was more concerns with legalization issues, idicated by text such as "Iqos" (6), "omnibüs bill" (7), "legal" (9). Text under topics 9 and 10 and the videos under topic 11 are mostly related to constraints in use and safety issues.

Conclusion: Social media is an important resource for tobacco control. Results of this study Show that chatter in the social media in Turkey is mostly geared towards those cigarettes users contemplating quitting due to health risks involved in smoking. This indicates an important opportunity for tobacco control community in Turkey to better inform the public about healthy ways of tobacco cessation and making cessation services more readily available to all.

Keywords: Electronic cigarettes, text mining, text classification

Table 1. 15 Topics and Words Regarding These Topics

B1	B2	B3	B4	B5	B6	B7	B8	B9	B10	B11	B12	B13	B14	B15
Tütün	İsm	Elektronik	Zararlı	Likit	#Çalışmıyorum	İçin	#elektroniksigara	Farklı	Sigara ya	Adan	İçin	Büyük	İşgaretsiz olan	Ak
Bağımlılık	Özellik	Biriktiler	Çok	Anadoluya	#Atatürk	Olacak	#esigara	Likit	Yeni	Sigara	Sipariş	Sigara	Değişim	Sen
Kanser ojen	Kabot	İsm	İttifak	İçin	#Hemiyon	Elektronik	Çalışıyor	Yasak	Karşı	#youtubec	Vermek	Zararlı	Uygun	Fikriyatın
Madde	Tutuk	Sistem	Stok	Atomizer	#Halkın	Konak	Miydi	Aşkamlıklar	Sağlık	Patlayıcı	Kir	100birim	Gere	Ejderha
Bazılar	Çok	Sağlık	Sen	İçin	Başarı	Zaman	Dünyanın	İçin	Alınan	Büyük	Büyük	Abi	Olun	oaklı
Paşazade	Değer	Likit	Ayrı	İçin	Çok	Anadoluya	#İçin	Farklı	Klasik	Sig	212	Çok	Normal	Talimat
İçerisinde	Görünüm	Özellik	Çok	İçin	Mevcut	Elektronik	#torbayasa	İçin	Yasak	Değerli	519	Farklı	İçin	Gereklilik
Ortaklık	İçin	Alınan	İçin	İçin	Sigara	Gerekli	Notları	Mevcut	Yeni	Sen	Almak	İyi	Neke	Kullanıcı
Yapın	2018	İçin	Özellik	İçin	Yasak	Sigara	Yasal	Sigara	Kayıp	Ankara	Değerli	Yüksek	Dünya	verin
Yapın	Alınan	İçin	Yasak	Kolay	2018	Zararlı	Sağlık	Zaman	Yalanlar	Mevcut	2018	Zararlı	İçin	Zaman
Büyük	Farklı	Mevcut	Abi	Akademik	Elektronik	Görünüm	İçin	Açık	Aroma	İçin	Smok	Destek	Kullanıcı	Çalışıyor
Nargile	İçin	Özellik	Büyük	İçin	Mevcut	Mevcut	İçin	Değerli	Bilimsel	Bombası	Vaporeso	Elektronik	Torba	Alınan
Likit	Elektronik	Sistem	Çok	Değerli	Çalışıyor	Senelik	Çok	Değerli	Yeni	Değerli	519	Hediye	İçin	Kullanıcı
Yeni	Tutuk	Tutuk	Paşazade	Fabrikatör	Sağlık	Yapın	İçin	Değerli	Yeni	Çok	eleaf	Kullanıcı	İçin	İçin
Ülkemizde	Değerli	Yeni	Kullanıcı	Çok	Yüksek	Ankara	Yüksek	Farklı	150	Len	Hediye	İçin	Kat	Bırakmak
Dünya	Görünüm	Zararlı	Kullanıcı	İçin	Akademik	İçin	Ankara	İçin	Çok	Likidi	Likitleri	İçin	İşgaretsiz olan	İçin

[Abstract:0532] SS-128 [Accepted:Oral Presentation] [Pulmonary Rehabilitation and Chronic Care]

Effectiveness of Pulmonary Rehabilitation Initiated after Exacerbation of Chronic Obstructive Pulmonary Disease

Tuğba Gökta1ay¹, Lale Cerrahoğlu², Yavuz Havlucu¹, Necati Balcı², Arzu Yorgancıoğlu¹

¹Department of Pulmonology, Manisa Celal Bayar University School of Medicine, Manisa, Turkey

²Department of Physical Therapy and Rehabilitation, Manisa Celal Bayar University School of Medicine, Manisa, Turkey

Objectives: Pulmonary rehabilitation (PR) is a interdisciplinary treatment approach that aims at improving physical and emotional status and at providing health-sustaining behaviors in symptomatic patients with chronic respiratory disease (primarily COPD) who have a reduced ability to perform activities of daily living. There are studies evaluating the effectiveness of pulmonary rehabilitation programs during exacerbations, especially in stable patients with COPD. From this point, it was aimed to evaluate the effectiveness of PR which was initiated in the early post-discharge period in patients hospitalized due to COPD exacerbation.

Methods: Patients who were hospitalized due to COPD exacerbation and who came for check within 15 days after discharge were included in the study. While patients who agreed to participate in the PR program were included in the intervention group, patients who did not agree to participate in the PR program were included in the control group. Socio-demographic data of all patients were recorded. The 6-Minutes Walking Test (6MWT) and the Incremental Shuttle Walking Test (ISWT) were performed to assess the functional capacity. The Modified Borg Scale (mBS) and the Modified Medical Research Council Dyspnea Scale (mMRC) were used to assess dyspnea. The COPD Assessment Test (CAT) and the St. George's Respiratory Questionnaire (SGRQ) were filled out to assess quality of life. The intervention group underwent a personalized structured PR program 3 days (2 days at hospital and 1 day at home) per week during 8 weeks. All assessment tests were re-administered to the intervention group at the end of the program and to the control group after 3 months.

Results: Of the 61 patients included in the study, 60 (98.4%) were male. The mean age was 63±8.9 years. The mean BMI was 25±3.7 kg/m². The mean pack years of cigarette smoking was 59.8±36.4. 38 (62.3%) of the patients underwent the PR program. There was no significant difference between the two groups (p>0.05). A statistically significant change was found in all parameters except the Modified Borg Scale in the intervention group (p<0.05). However, there was no significant change in the control group (Table 1).

Conclusion: The result obtained from our study has suggested that the structured pulmonary rehabilitation program which is initiated early after exacerbation in COPD patients can be effective as in stable period. Encouraging these patients to participate in this program can contribute to increasing the functional capacity of patients and improving their quality of life.

Keywords: COPD, exacerbation, pulmonary rehabilitation

Table 1. Assessment parameters of intervention and control groups

	PR Group (mean±SD) (n=38)		Control Group (mean±SD) (n=21)	
	First assessment	Final assessment	First assessment	Final assessment
BORG (rest)	1.10±1.12	0.69±0.80	1.47±1.64	1.51±1.32
mMRC	3.08±0.96	2.08±0.85*	2.96±1.29	2.91±1.34
6MWT (meter)	379±123	434±109*	363±173	379±178
ISWT (meter)	324±122	375±135*	342±142	350±154
CAT	19,58±8.03	15.61±8.19*	19.87±10.55	20.48±10.33
SGRQ				
Symptom	57.00±24.06	37.90±23.18*	56.52±21.92	55.76±22.08
Activity	57.62±24.76	48.63±27.21*	63.49±31.14	61.67±31.85
Impact	46.32±25.89	33.50±26.93*	50.59±31.75	49.63±32.50
Total	51.52±23.17	39.07±22.86*	55.36±28.12	54.17±28.89

* p<0.05

[Abstract:0533] EPS-126 [Accepted: E-Poster] [Pediatric Pulmonary Diseases]

Left Main Bronchial in Foreign Body Aspiration Case

Şerif Kurtuluş¹, Zafer Hasan Ali Sak², Remziye Can³, Rukan Karaca⁴

¹Department of Chest Disease, Ceylanpınar State Hospital, Şanlıurfa, Turkey

²Department of Chest Diseases, Harran University School of Medicine, Şanlıurfa, Turkey

³Pınar Vocational and Technical Anatolian High School, Şanlıurfa, Turkey

⁴Department of Radiology, Ceylanpınar State Hospital, Şanlıurfa, Turkey

Introduction: Foreign body aspiration (ICA) is an important cause of morbidity and mortality in childhood. The asphyxia event occurs, if there is obstruction near-complete at the level of the trachea. In contrast, foreign bodies traversing the lower levels of the trachea-bronchial tree is causing respiratory system problems due to deterioration of airflow and predisposition to infection. Children especially aspirate toys, coins, chickpeas, nuts, peanuts, seeds, dry legumes and sugar. While adults are more common food, bone, turban needle, metallic objects and denture aspiration. Rigid bronchoscope is gold standard for foreign body removal.

Case Presentation: A 13-year-old girl child, applied to an urgent with complaint of aspirating a turban needle. The anamnesis and physical examination didn't have any features. On postero-anterior (A) and lateral (B) chest X-ray, was observed a foreign body extending from the trachea to the left main bronchus (Figure 1). Scanogram in images was observed linear courising, metallic density, located in the left main bronchus and trachea. The patient had a rigid bronchoscope was't

observed any pathology on a level with oral, glottic area, trachea and main bronchi. Foreign body (turban needle) was removed that it observed left main bronchus. No complications observed during the procedure. The patient was discharged with amoxicillin clavulanic acid. The patient's was normalised re-examination in polyclinic Patient D.H. and her custodian (her father) were consent by giving information.

Conclusion: FBA can be applied to the hospital at any age and with different clinical complaints. Turban needle aspiration is seen more in adult period, also is seen in childhood, that it was improved sensitivity. Those who use the turban needle should not to keep the needle in their mouths.

Keywords: Aspiration, foreign body, tracheobronchial system, turban needle

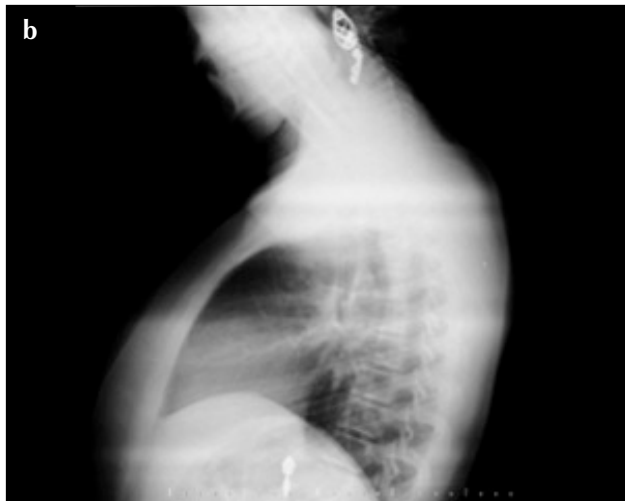
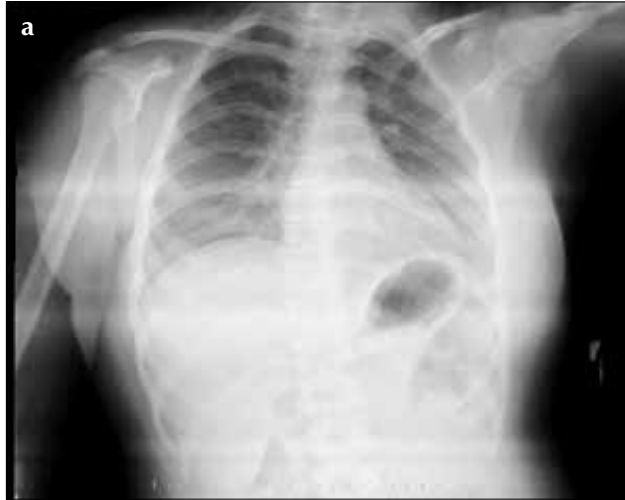
Figure 1. a, b. Postero-anterior (A) and lateral (B) chest X-ray, foreign body extending from the trachea to the left main bronchus (a). Postero-anterior (A) and lateral (B) chest X-ray, foreign body extending from the trachea to the left main bronchus (b).

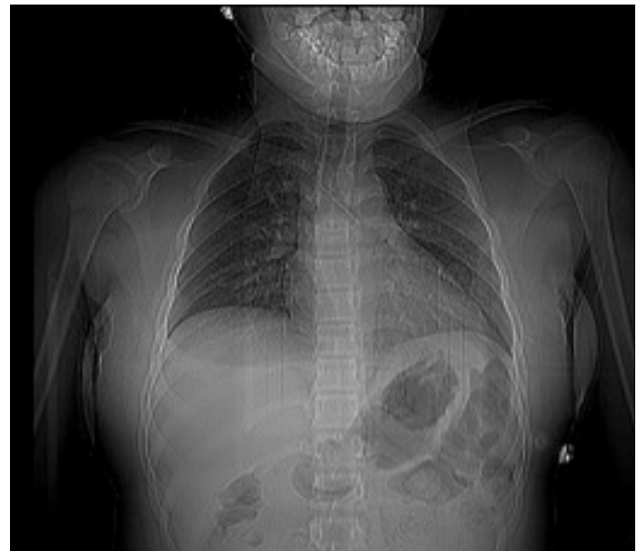

Figure 2. Scanogram images. Scanogram in images linear courising, metallic density, located in the left main bronchus and trachea

[Abstract:0534] EPS-264 [Accepted: E-Poster] [Thoracic Surgery]

Bilateral Elastofibroma Dorsi Developing with Eight-year Intervals and Accompanying Aberrant Right Subclavian Artery Anomaly

Seray Hazer, Gülşen Yılmaz, Necati Solak, Erkmén Gülhan, Can Kutlay

Department of Thoracic Surgery, Health Sciences University, Ankara Atatürk Chest Diseases and Thoracic Surgery Training and Research Hospital, Ankara, Turkey

Elastofibroma dorsi is a soft tissue mass that does not come to mind as a prediagnosis during physical examination. It can easily be missed out in patients who consult to outpatient clinics due to back and shoulder pain. It is frequently found on the lower edge of the scapula, between the latissimus dorsi and serratus anterior muscles, adherent to the periosteum of the thorax wall. The lesion was called elastofibroma dorsi (EFD) because of its characteristic subscapular-infrascapular location. The rubbing of the scapula to the thorax wall or the genetic factors is considered responsible in its occurrence in people working with arm-power. Thoracic computed tomography (CT) and magnetic resonance imaging (MRI) are the most commonly used imaging modalities. Surgical excision is a good treatment option in symptomatic cases. In this study, we present our patient with bilateral elastofibroma dorsi whom we operated on due to clinical complaints with 8-year intervals, because of the accompanying aberrant right subclavian artery anomaly.

Aberrant right subclavian artery (ARSA) is a rare and congenital anomaly that is usually asymptomatic. Because the most common complaint in adult patients with ARSA is the difficulty in swallowing, it is also called as "dysphagia lusoria". Respiratory complaints are much less common. Awareness of this anomaly is clinically important because it can be associated with the symptoms of tracheoesophageal compression, aneurysm formation, or aneurysm rupture.

In our present case, the postoperative diagnosis was EFD in a 46-year-old female patient who was operated 8 years ago due to severe back pain and swelling in the right scapular region. The patient who expressed complaints about swelling and severe pain under the left scapula during the follow-up at an external center due to pneumonia consulted to the clinic again. Thorax CT showed a lesion in soft tissue density between the chest wall and scapula. Tomography examination revealed a rare, accompanying aberrant right subclavian artery anomaly in the patient. This anomaly is of great importance in adulthood in terms of complications such as atherosclerotic aneurysm, esophageal fistula, rupture, thrombosis and embolism. Total excision with left pos-

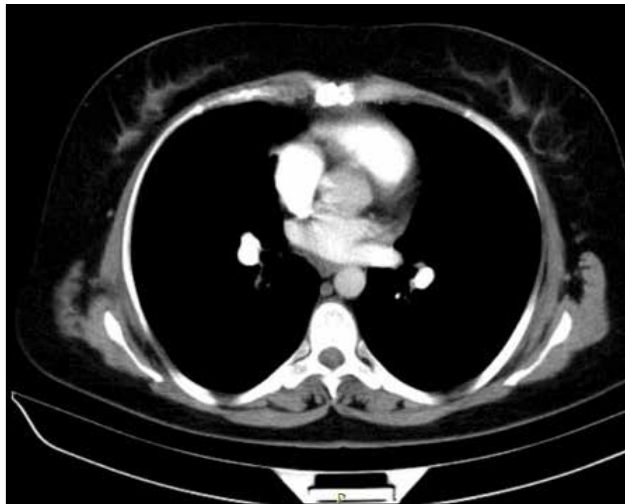

Figure 1. No lesion was available in the left subscapular region in the postoperative control tomography performed 8 years ago

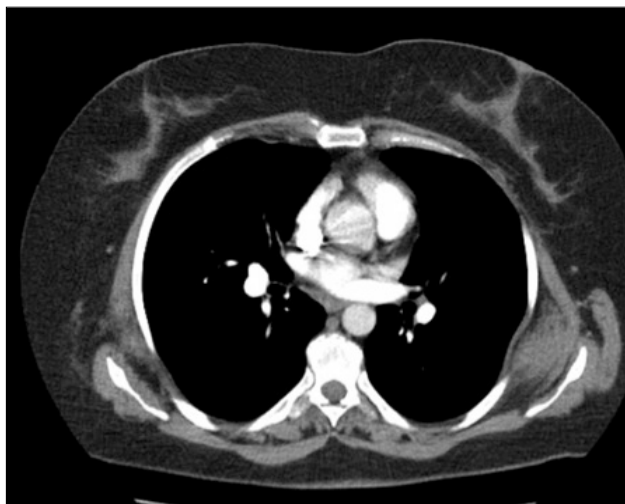

Figure 2. Lesion in the left subscapular region in the tomography performed in 2017

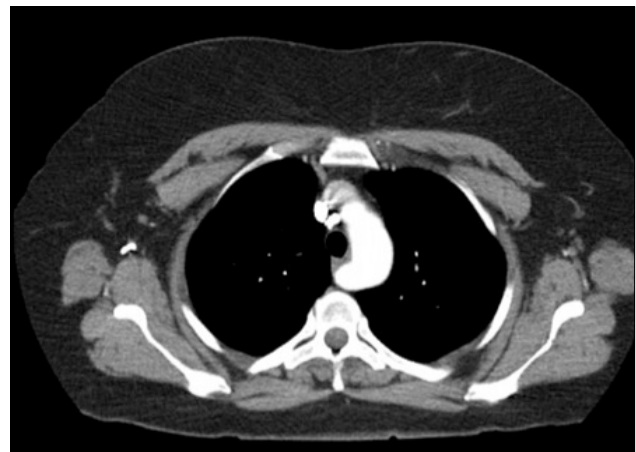

Figure 3. Aberrant right subclavian artery in tomography

terior subscapular incision was performed for diagnostic and therapeutic purposes. Postoperative pathology result was evaluated as an elastofibroma.

Key words: Aberrant right subclavian artery, elastofibroma dorsi, back pain

[Abstract:0535] SS-056 [Accepted:Oral Presentation] [Environmental and Occupational Lung Diseases]

Respiratory Findings of Kebab Restaurant Workers due to Indoor Air Pollution

Zafer Hasan Ali Sak¹, Şerif Kurtuluş², Birsen Ocaklı³, İbrahim Bayhan⁴, M. İrfan Yeşilnacar⁴, Peri Arbak⁵

¹Department of Chest Diseases, Harran University School of Medicine, Şanlıurfa, Turkey

²Department of Chest Diseases, Ceylanpınar State Hospital, Şanlıurfa, Turkey

³Department of Chest Diseases, Süreyyapaşa Chest Diseases and Thoracic Surgery Training and Research Hospital, İstanbul, Turkey

⁴Department of Environmental Engineering, Harran University School of Engineering, Şanlıurfa, Turkey

⁵Department of Chest Diseases, Düzce University School of Medicine, Düzce, Turkey

Objectives: Particulate matter (PM) and other toxic gases and fumes resulting from cooking with coal or petroleum-based fuels lead to acute and long-lasting respiratory disturbance. The comparative analysis of the effects of the fumes generated during the cooking process in the kebab establishments, which are common in Urfa, on the respiratory health of the employees and those working in other enterprises in the immediate vicinity.

Methods: PM10 and PM2.5 measurements were performed in the indoor environment of 2 kebab restaurant, 1 bakery, 1 dried fruit and nut shop in the center of Urfa province. Questionnaire involving respiratory complaints and past medical history and respiratory function tests were performed on male workers (42 kebab workers, 32 other employees) in these enterprises.

Results: The forced vital capacity (FVC, 98.7%, $p=0.046$) of the kebab workers, the first volume of the forced expiratory volume in one second (FEV1) was significantly lower than the other workers (96.4% to 104.4%, $p=0.018$). The peak expiratory flow rates of the kebabs (80.6% to 84.6%, $p=0.335$) and the maximal mid expiratory flow rate were lower than the other workers (94.5% to 98.1%, $p=0.496$). The incidence of burning in the nose and throat, cough (97.6% to 50%, $p<0.001$), sputum (97.6% to 43.8%, $p<0.001$), eye burning sensation (97.6%, $p<0.001$) (6.3% to 97.6%, $p<0.001$) were significantly higher than other workers. Mean levels of PM10 and PM2.5 (PM10: 1626 $\mu\text{g}/\text{m}^3$ and PM2.5: 495 $\mu\text{g}/\text{m}^3$) measured in the kebab restaurants were significantly higher than those measured at other workplaces (PM10: 470 $\mu\text{g}/\text{m}^3$ to PM2.5: 190 $\mu\text{g}/\text{m}^3$, $p<0.001$). Synchronously measured outdoor environment PM10 (300 $\mu\text{g}/\text{m}^3$) and PM2.5 (130 $\mu\text{g}/\text{m}^3$) levels are significantly lower than PM levels of kebab restaurants and other workplaces. The levels of PM10 and PM2.5 were significantly higher in workplace of workers with cough complaints than those without complaints. PM10 and PM2.5 levels were significantly higher in workplace of subjects with sputum complaints than those without complaints.

Conclusion: Respiratory complaints of Kebab workers increased and respiratory functions were effected. It is important to ensure proper indoor ventilation and respiratory protection in the kebab manufacturing business, which produces high levels of PM pollution.

Keywords: Kebab workers, PM10, PM2.5, respiratory functions

[Abstract:0538] PS-219 [Accepted:Poster Presentation] [COPD]

Inhaled Corticosteroid Usage in COPD Patients Hospitalized with Pneumonia

Muzaffer Onur Turan, Niyazi Can Ertürk

Objectives: COPD is a disease with progressive airway obstruction and exacerbations. It has been discussed that inhaled corticosteroids (ICS) , which is used in COPD therapy, may increase the risk of being pneumonia. It was aimed to investigate frequency and properties of using ICS in COPD patients hospitalized with pneumonia.

Methods: COPD patients who had been hospitalized in our clinic with the diagnosis of pneumonia in last 5 years were included. Data about hospitalized patients with ICD codes of COPD and pneumonia between January 2013 and December 2017 was obtained. The diagnosis of COPD and pneumonia were confirmed by anamnesis, epicrisis and medical examinations. Medical history and drugs were recorded.

Results: There were 81 patients (70.4% men, 29.6% women) with the mean age of 69.8 ± 11.6 who met the inclusion criteria. The mean smoking index was 49 (package x year) . Besides, 11.5% of patients were still smoking. Most of the patients (87.7%) had at least one comorbidity other than COPD. There was blood eosinophilia (in stable time) in 22.2% of participants. The mean FEV1 level was 0.87 lt (42.6%); 64.7% of the patients had severe obstruction. Eighty percentage of the patient group had COPD exacerbation in last year. The mean exacerbation number was 1.5/year. There were COPD group C and D in 97.2% of all. Two-thirds of patients had adherence to COPD guideline (GOLD) as treatment. There were ICS usage in 86.7% of participants (budesonide: %60.6, fluticasone: 31%, beclometazone: 8.4%). There was no meaningful relationship between ICS usage and age higher than 55, blood eosinophilia, gender, active smoking and severe obstruction (p: 0.436, 0.621, 0.250, 0.729 and 0.287 respectively). ICS usage was statistically high in patients who had COPD exacerbation in last year (p=0.001).

Conclusion: It was remarkable that COPD patients with pneumonia had high ages, comorbidities, advanced COPD stages and low lung reserves. There was not a negative result about the increased risk of pneumonia in COPD patients who were using fluticasone as ICS, in contrast with the discussion in recent years. COPD patients with blood eosinophilia may also be considered about the usage of ICS. A study including all COPD patients which compares the groups with and without pneumonia will objectively interpret if ICS usage is a risk factor for pneumonia or not.

Keywords: COPD, inhaled corticosteroid, pneumonia

[Abstract:0542] PS-051 [Accepted:Poster Presentation] [Lung and Pleura Malignancies]

Adenocarcinoma Case in the Appearance of Interstitial Lung Disease

Bahriye Parça, Betül Cengiz, Neşe Dursunoğlu

Department of Chest Diseases, Pamukkale University School of Medicine, Denizli, Turkey

Interstitial Lung Diseases are a group of diseases that cause inflammation, fibrosis and structural deterioration in the lung parenchyma at various grades and it can be confused with malignant diseases that give this radiological appearance. This case was followed up with the prediagnosis with ILD and diagnosed with primary pulmonary adenocarcinoma as a result of transthoracic fine needle aspiration biopsy (TTFNAB). A 72-year-old male patient was admitted to our outpatient clinic with the complaints of dyspnea and dry cough continuing for 4 months. He had a smoking history of 20 packs/year. His general condition was moderate, there were inspiratory rales in the left lung middle-lower zone and in the right lung lower-zone in auscultation, and other system examinations were usual. PA chest X-ray showed a peripheral infiltration area in the bilateral middle and lower zones (Figure 1). Peripheral focal lobular ground-glass areas and consolidation area containing air bronchograms were observed in both upper lobes and lower lobes of the lung in thorax CT (Figure 2). The patient was hospitalized with the diagnosis of pneumonia, and cryptogenic organising pneu-

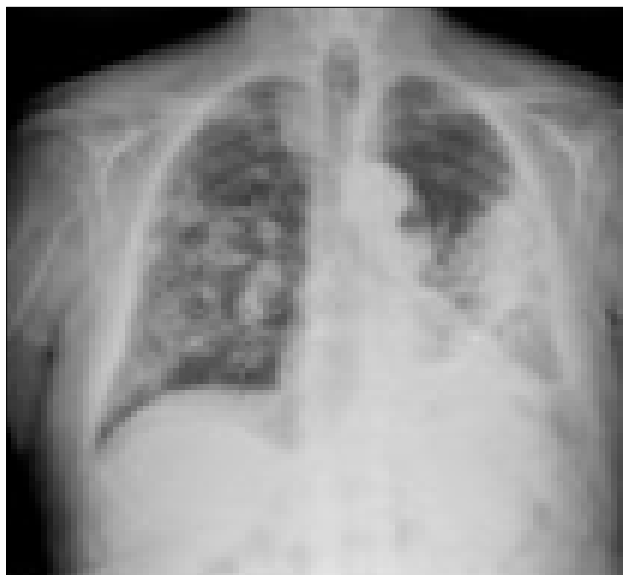

Figure 1.

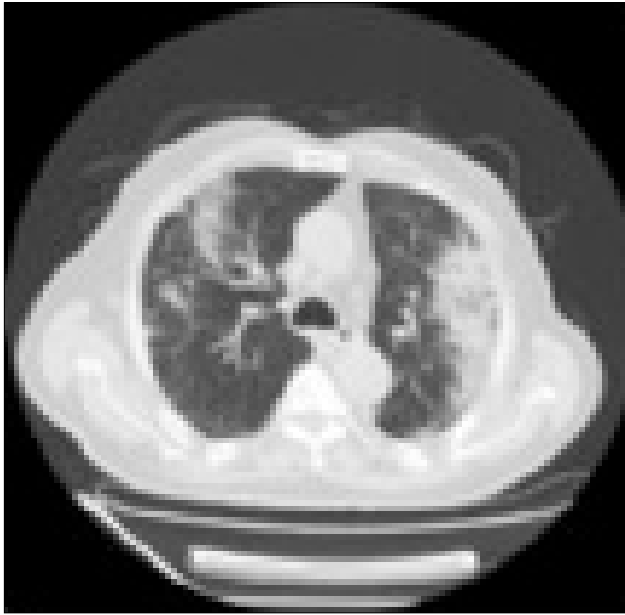

Figure 2.

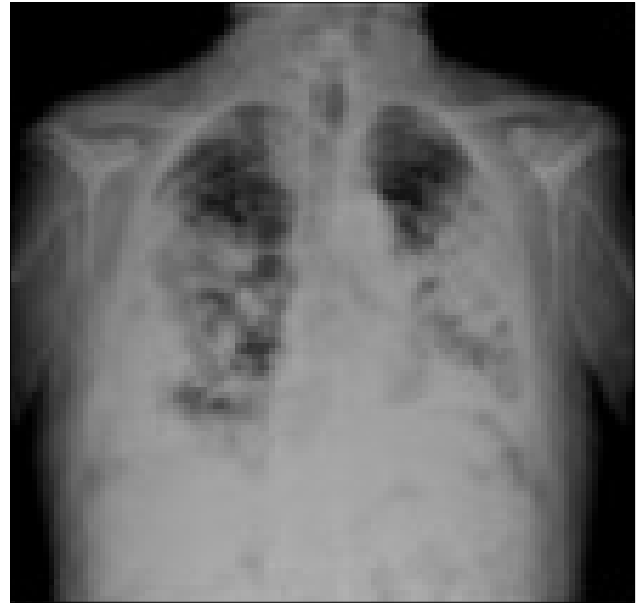

Figure 3.

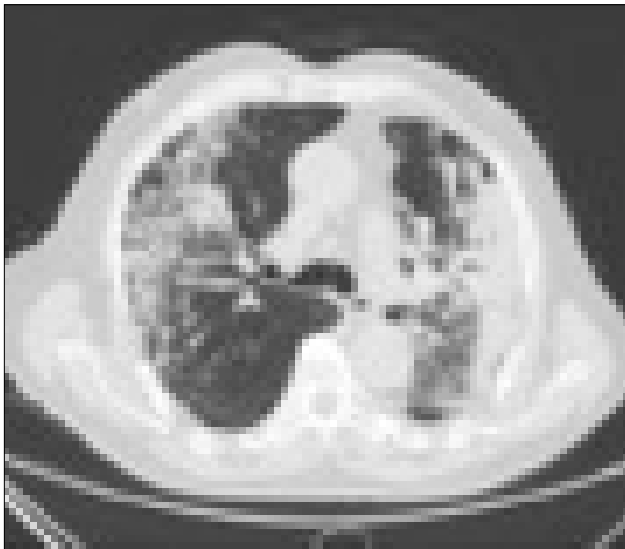


Figure 4.

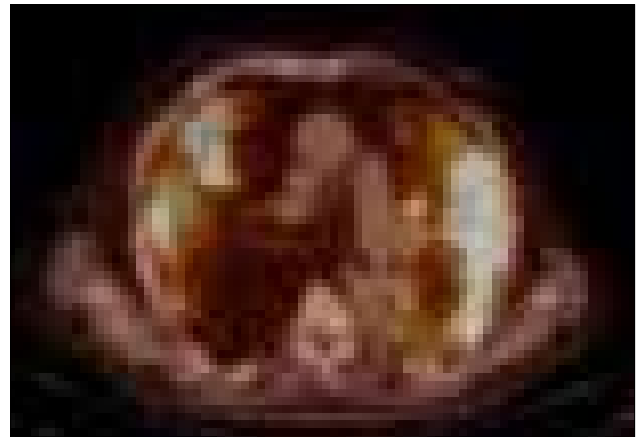

Figure 5.

to 1 in the follow-up of the patient. After receiving meropenem for 9 days, CRP decreased to 0.5. Because the infiltration areas did not regress in the chest X-ray despite the treatment, bronchoscopy was performed. No endobronchial lesions were seen in bronchoscopy. Purulent secretion from left main bronchus was seen and lavage was taken. Bronchoalveolar lavage and biopsy were not performed because of the low saturation during the procedure. When a small number of neutrophil leukocytes in the fibrinous zone, lymphocytes, alveolar macrophages and bronchial epithelial cells with natural appearance were seen in the pathology result, prednisolone 120 mg/day was initiated with the clinical and radiologic prediagnosis. The patient with *Klebsiella pneumoniae* reproduction in control sputum culture was intravenously given ciprofloxacin 1x400 mg for 8 days. When the infiltrations were seen to regress partially in the control chest x-ray after 120 mg/day prednisolone treatment for 8 days and 100 mg/day for 5 days, the patient was discharged with 64 mg/day prednisolone. One month later, the patient was admitted to the hospital because the complaints increased under prednisolone treatment, and an increase in bilateral infiltrations was seen in PA chest X-ray and thoracic CT (Figure 3-4). It was seen in blood tests that Hgb was 15.7 g/dL, Hct was 49%, white blood cell was 17060 / mm³, and CRP was 0.18. TMP-SMX 3x4 gr iv, and levofloxacin 1x500 mg iv were administered in the patient for 14 days upon the reproduction of *Stenotrophomonas maltophilia* in sputum culture. PET/CT of the patient was taken with the prediagnosis of primary pulmonary cancer because PA infiltrations in the chest X-ray did not regress despite the treatment (Figure 5-6). Ultrasonography-guided transthoracic fine needle aspiration was performed in both lung parenchymas of the patient who had common hypermetabolic infiltration areas with ground-glass appearance,

monia (COP). In the laboratory examination, Hg was 16.5 g/dL, Hct was 49.7%, white blood cell was 10670/mm³ and CRP was 0.54 mg/dL. Meropenem 3x1 gr iv treatment was started. There was no reproduction in sputum cultures taken from the patient at the time of hospitalization. CRP increased

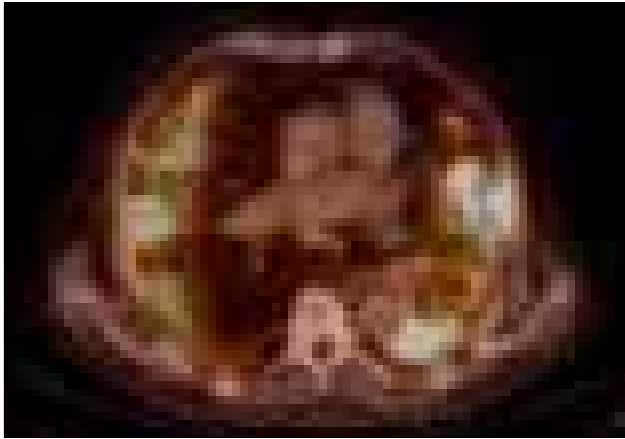

Figure 6.

which were considered to be malignant at first plan (adeno Ca/bronchoalveolar Ca), and who did not have any pathologic FDG involvements in the other parts of the body. According to the biopsy result, the patient was referred to the oncology department with the diagnosis of primary lung adenocarcinoma.

This case has been presented in order to emphasize that the patients in whom cryptogenic organizing pneumonia is radiologically and clinically considered and in whom an apparent mass formation is not seen may have lung adenocarcinoma.

Keywords: Interstitial, lung, disease, adenocarcinoma

[Abstract:0543] PS-072 [Accepted:Poster Presentation] [Thoracic Surgery]

Iliopsoas and Gluteus Abscess Presented with Pneumomediastinum

Hüseyin Yıldırım¹, Tuba Şahinoğlu²

¹Department of Thoracic Surgery, Kars Harakani State Hospital, Kars, Turkey

²Department of Thoracic Surgery, Konya Numune State Hospital, Konya, Turkey

Pneumomediastinum defines being air in the mediastinal plans. It can be seen with pneumothorax. It may be traumatic and iatrogenic, as well as spontaneous. Our case is interesting because of the development of pneumomediastinum secondary to the abscess caused by aerobic infection.

A 78-year-old patient with chronic renal disease was admitted to emergency room with a neck pain and physical examination of the patient revealed subcutaneous crepitation starting from the right side of the neck and proceeding to the shoulder. In the thorax CT pneumomediastinum and subcutaneous air were detected and patient was consulted to our clinic. Patient's general condition was good, consciousness is obvious. It was learned that complaints about difficulty while walking, fatigue and weakness have been existing for a long time. There was no trauma or hospitalization story. There was no respiratory tract infection or known respiratory disease. Patient was admitted for follow-up and examination. Orthopedic consultation was requested for complaints of difficulty in walking, however pathology was not detected on radiogram and orthopaedic control was suggested. However; on the third day after admission, the patient's complete blood count and infection markers were checked and found to be stable, except mild leukocytosis. For evaluation of pulmonary or possible intraabdominal pathology, the thorax and the entire abdominal CT were applied. Pneumomediastinum was partially persisted in the thorax CT of the patient. However, abdominal CT revealed diffuse subcutaneous emphysema in the gluteal region and abscess formation in the iliopsoas muscle, which gave air-fluid level within the iliopsoas muscle. The patient was consulted to the general surgery and infectious diseases clinics. There was no subcutaneous crepitation and abscess in the right gluteal region palpation of the patient. After the abscess was diagnosed, it was learned from the patient's anamnesis that she frequently used intramuscular analgesics many years ago due to wide-

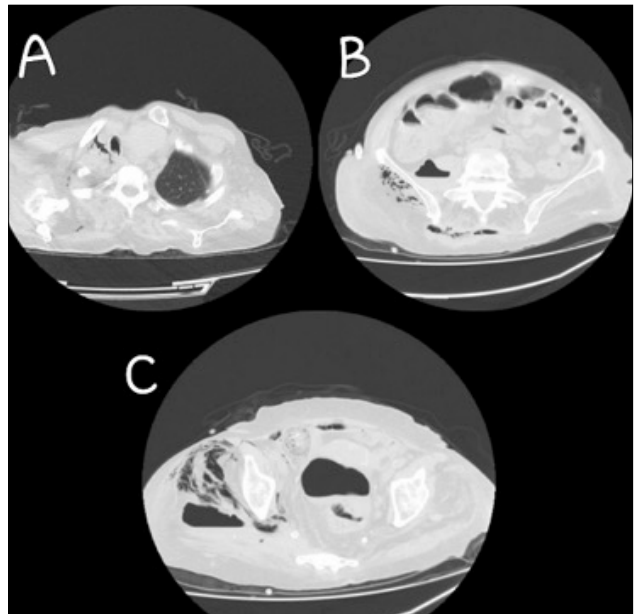


Figure 1. a-c. a) Pneumomediastinum image in thorax BT, b) Air-fluid level within the iliopsoas muscle in abdominal BT, c) Abscess formation in the gluteus muscle in pelvic BT

spread jointpain. The culture result of the purulent sample taken from the right gluteal abscess was *Enterococcus faecium* and *Escherichia coli*. A broad-spectrum intravenous antibiotic was initiated and was transferred to the general surgery clinics. Although pneumomediastinum is a clinical condition that develops secondary to the pathology of intrathoracic organs, it may also occur due to the subcutaneous emphysema spreaded from abscess to mediastinum. In such cases, detailed anamnesis and physical examination may lead to definitive diagnosis.

Keywords: Gluteus abscess, iliopsoas abscess, pneumomediastinum

[Abstract:0544] EPS-287 [Accepted: E-Poster] [Thoracic Surgery]

Solitary Fibrous Tumor Diagnosed by Spontaneous Hemopneumothorax

Hüseyin Yıldırım¹, Tuba Şahinoğlu²

¹Department of Thoracic Surgery, Kars Harakani State Hospital, Kars, Turkey

²Department of Thoracic Surgery, Konya Numune State Hospital, Konya, Turkey

Spontaneous pneumothorax describes the collapse of the lung with air passage to the pleural space from the lung parenchyma without an external effect. In etiology, there are mostly bullae and blebs located in the lung parenchyma, especially in the peripheral and upper lobes. Spontaneous haemothorax clinic is the result of rupture of pleural vascular structures around the bullae or apical pleural adhesions with parenchymal tension after pneumothorax development. Our case is interesting because it is incidentally diagnosed with pleural solitary fibrous tumor when operated with spontaneous hemopneumothorax.

A 38-year-old male was admitted to the emergency room with a right chest pain and chest x-ray revealed a partial hydro-pneumothorax in the right hemithorax. It was observed that the general condition was good at the evaluation of the patient at the time of the onset, and there was no pathological examination finding except the decreased respiratory sounds on the right hemithorax were taken at the physical examination. There was a story of smoking in his history. Computed thorax tomography of the patient revealed bullae and pleural fluid in the right side. Videothorascopical bullae resection was planned. No pathology was found in the preoperative blood tests. In videothorascopical exploration; bullae with air leak and pleural adhesions with fibrotic nodules adjacent to the bullae in the apex of right upper lobe. It was determined that there were about 500cc hemorrhagic fluid at costophrenic sinus and micronodular fibrotic nodules at 4-5. costal level of parietal pleura. Apical bullae were removed by wedge resection through two port incisions. Hemorrhagic fluid was aspirated. Bleeding due to pleural adhesions adjacent to the bullae in the apex was controlled. A subclavian artery branch was seen in the pleural adhesion and it was cauterized. Excisional biopsies were taken via partial decortication from pleural nodules. The pathology was reported as; pulmonary parenchyma including congestion hemorrhagia, focal interstitial fibrosis, bronchiectasis and bulla formation in wedge resection material; chronic pleuritis in decortication material. Pleural nodule was reported as soliter fibrous tumor. The patient with full expansive lung was discharged on the third postoperative day. The patient was directed for medical oncology follow-up. Solitary fibrous tumor is a rare tumor that is located in the pleura, mostly derived from visceral pleura. Although it had been evaluated as mesothelioma historically, it is evaluated separately from mesothelioma because of its different clinical and aetiolog-

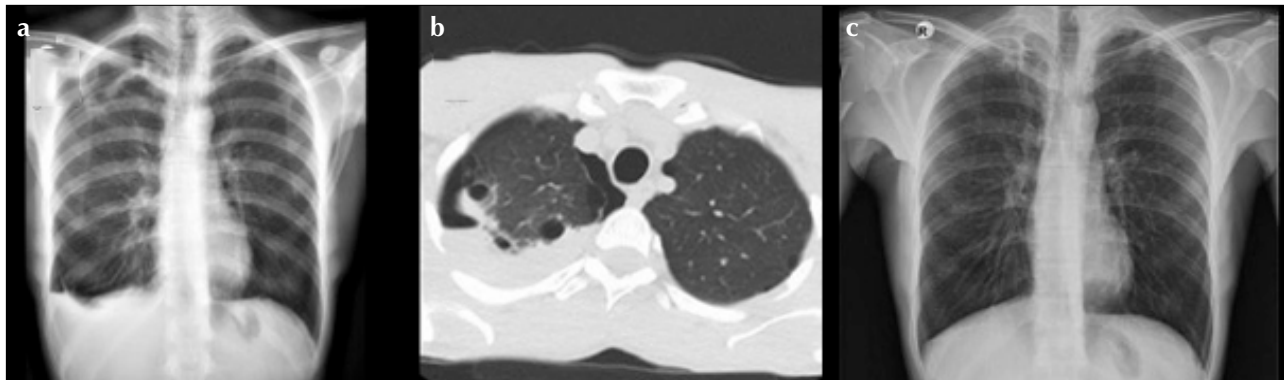


Figure 1. a-c. a) Patient's preoperative chest x-ray revealed a partial hydro-pneumothorax in the right hemithorax, b) Image in thorax BT of the patient revealed bullae and pleural fluid in the right side, c) Postoperative chest X-ray of the patient

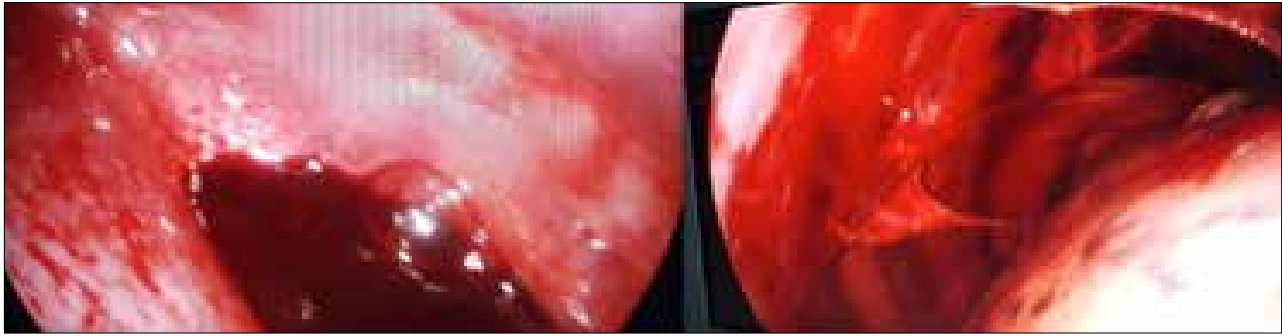


Figure 2. Videothoroscopic image that shows about 500cc hemorrhagic fluid at costophrenic sinus and micronodular fibrotic nodules at 4-5. costal level of parietal pleura

ic factors. The majority are asymptomatic, but in large masses there may be chest pain or cough by pressure. Both diagnosis and treatment are surgery. These cases should be followed up due to the recurrence

Keywords: Solitary fibrous tumor, spontaneous hemopneumothorax

[Abstract:0545] SS-093 [Accepted:Oral Presentation] [Tobacco Control]

Electronic Cigarette Awareness

Ayşe Turan¹, Ramazan Azim Okyay²

¹Çukurova State Hospital, Adana, Turkey

²Department of Public Health, Kahramanmaraş Sütçü İmam University School of Medicine, Kahramanmaraş, Turkey

Objectives: Manufacturers of electronic cigarettes (e-cigarettes) have claimed that the steam produced in e-cigarettes is isolated from toxic chemicals and carcinogenic substances, as e-cigarettes do not involve the burning of tobacco leaves like traditional cigarettes and they have launched them as alternative products. Awareness and perception play a key role in the acquisition of new habits. This study aims to determine the level of information and perception about e-cigarettes.

Methods: The questionnaire form prepared by the researcher was filled in by face to face method after obtaining the volunteers' verbal consent. The data were evaluated in the SPSS package program and $p < 0.05$ was considered significant.

Results: 284 people were included in this study. Of them, 60.9% were male; 85.9% were married; 53.5% were high school graduates. Among participants, 119 (41.9%) were between the ages of 34-41, 70 (24.6%) . When the occupational distribution was examined it was found that, of the participants 63.0% were workers, 15.5% were housewives. 82% of the participants were living in urban areas. 70.4% were active smokers whereas 2.1% quitted cigarette. 74.3% of the respondents said they had information about e-cigarettes, of them 65.4% obtained this information from friends; only 1.8% said they had never heard of e-cigarettes. However, when information regarding e-cigarette was examined, 70.6% said that e-cigarette was a nicotine delivery system, 64.9% said that it was a device for evaporating nicotine, 48.8% said that different additives could be breathed, 23.3% said that different tastes could be breathed, 41.2% said that there was no burning process in e-cigarette, 78.7% said e-cigarettes did not contain carbon monoxide, and 82.9% did not know that e-cigarette was not covered by Food and Drug Legislation. 21.8% of them said that they tried e-cigarettes out of curiosity or with the intention to quit or reduce the amount of traditional smoking. 20.4% of the participants were planning to use e-cigarettes in the future. 40.3% believed that e-cigarette was less harmful than traditional cigarette, 50.9% believed that it was cheaper, 49.3% believed that there was no addictive

Table 1. Opinions and Suggestions of Electronic Cigarette Regulation by Participants

Opinions and suggestions	n	%
Only available with prescription	80	28.2
Nicotine should be banned	36	12.7
Tastes should be banned	26	9.2
Prohibition of selling to young people (<18 years)	98	34.5
Use in public places should be prohibited	43	15.1
Must be licensed as medicinal products	37	13.0
It should only be sold in pharmacies	34	12.0
Product diversity in the market should be limited	32	11.3
Ads should be banned	48	16.9
Warning should be added that the use is harmful	69	24.3
No idea	44	15.5

feature in e-cigarettes and 46.0% predicted that it could help to reduce the number of cigarettes they consumed. Smokers, individuals with higher education levels and men had higher information levels about e-cigarettes and the difference was statistically significant ($p < 0.000$, $p < 0.000$, $p < 0.000$).

Conclusion: Despite 74.3% of the participants stating that they know of e-cigarettes, most of the questions regarding awareness about e-cigarettes were not answered accurately.

Keywords: E-cigarette, cigarette, awareness

[Abstract:0548] PS-216 [Accepted:Poster Presentation] [COPD]

The Effect of Chronic Obstructive Lung Disease (COPD) Treatment on Nitric Oxide (NO) and Asymmetric Dimethyl Arginine (ADMA) Levels

Kübra Tanboğa¹, Cahit Bilgin², Mehmet Akdoğan¹, Asuman Devenci Özkan³

¹Department of Medical Biochemistry, Sakarya University School of Medicine, Sakarya, Turkey

²Department of Chest Disease, Sakarya University School of Medicine, Sakarya, Turkey

³Department of Medical Biology, Sakarya University School of Medicine, Sakarya, Turkey

Objectives: Asymmetric dimethylarginine (ADMA) and nitric oxide (NO) show reciprocal mechanisms of action, and the balance between these molecules contributes to tight regulation of airway tone and function. We aimed to determine changes in serum ADMA, NO levels, changes in pulmonary function tests (PFT), hemogram and total IgE levels of chronic obstructive pulmonary disease (COPD) treatment.

Methods: We included 30 male/female patients (40-60 years) diagnosed with COPD according to GOLD according to GOLD and 30 volunteer male/female control group without any known disease of similar age group. Global initiative (GOLD) for chronic obstructive pulmonary disease was treated according to the 2017 guidelines. Blood samples for ADMA, NO and Total IgE were obtained from the patients and control groups before and after treatment in the study. Respiratory Function Tests, CAT questionnaire, plasma NO, ADMA Total IgE, Hemogram, and levels of COPD were measured. There was no statistically significant difference ($p < 0.05$) between groups with COPD before treatment compared with group with ADMA levels higher than control group ($p < 0.05$). Pre-treatment and post-treatment NO levels in COPD patients were significantly lower than the control group ($p < 0.001$), and the difference between pre-treatment and post-treatment NO levels was not significant ($p > 0.05$). There was statistically significant difference between control group and total IgE concentrations before and after treatment ($p < 0.001$). There was no significant difference between pretreatment and posttreatment total IgE levels ($p > 0.05$).

Results: There was a significant difference between hsCRP concentrations in the control group and before and after treatment groups ($p < 0.001$), but there was no significant difference between pretreatment and post hsCRP levels ($p > 0.05$). Before and after treatment COPD had a significant negative correlation between serum ADMA and NO levels.

Conclusion: In COPD, ADMA levels are high, NO levels are low, and both show a strong correlation with the airflow limitation level. ADMA appears to be a potential new indicator of COPD prognosis and may be a new therapeutic target in the treatment of COPD.

Keywords: Asymmetric dimethyl arginine (adma), nitric oxide (no), chronic obstructive lung disease (copd), respiratory function tests (rft)

[Abstract:0550] SS-006 [Accepted:Oral Presentation] [Asthma and Allergy]

The Effect of Weight Loss Under Dietitian Supervision on Asthma Control and on Quality of Life in Obese Adult Patients with Asthma: A Randomized Controlled Study

Zeynep Çelebi Sozener¹, Ümüþ Özbey², Serap Balaban², Aslı Uçar², Dilşad Mungan¹, Zeynep Mısırlıgil¹

¹Department of Chest Diseases, Division of Immunology and Allergy, Ankara University School of Medicine, Ankara, Turkey

²Department of Nutrition and Dietetics, Ankara University, Faculty of Health Sciences, Ankara, Turkey

Objectives: Although the relationship between obesity and asthma has not been clearly elucidated, mechanical effects on the lungs, immune/inflammatory response and hormonal changes are considered to be possible factors. Increased fat tissue leads to systemic and local inflammation and promotes airway sensitivity and asthma symptoms in asthmatic individuals. In this case, reduction in fat tissue in obese asthmatic individuals is expected to improve asthma symptoms. In this study, based on the above information, it was aimed to observe the effect of dietary weight loss and changes in the intake of macro-micro nutrients on asthma characteristics, asthma control and the quality of life in obese asthmatic individuals.

Methods: Obese (BMI>30) individuals who were at the ages ranging from 20 to 65 years and who were admitted to the AUMF allergy polyclinic between January and May 2017 with the diagnosis of uncontrolled asthma were randomly assigned to a 10-week dietary group (n=29) or to control group (n=26). Pulmonary function tests, ACT, AQLQ, and anthropometric measurements were performed in all individuals, and 1-day food consumption was recorded at the beginning and at the end of the study. Inaccurate eating habits have been identified according to the nutrition consumption records of the individuals. A weekly phone call was made during 10 weeks, as long as the study continued, in order to correct these mistakes and increase the motivation of the individuals. Dietary habit of the individuals in the control group was not intervened; however, all measurements were repeated at the end of the study.

Results: In the study population the majority of which was composed of women (93% of the dietary group, 100% of the control group) and in which the mean age was 50.4±10.1 years, there was no difference in terms of gender, age, body composition, asthma characteristics, educational status, smoking and the presence of comorbid diseases in the beginning. At the end of ten weeks, significant weight loss in those going on diet compared to the control group [median (IQR) ; respectively -5.2kg (4.5) , -0.1 kg (1.3)], a recovery in ACT [median, (IQR); respectively 2 (2) , 0 (1.7)], and an increase in the AQLQ score [mean±SD; respectively 0.2±0.1, -0.02±0.5] were observed (p<0.001). While the average caloric intake decreased in the dietary group, it was found that there was an increase in the control group [median (IQR) , -309.4 (257) kcal, 129.6 kcal (283.7)], respectively] (p=0.001). There was a significant increase in dietary group in all pulmonary function test parameters (except for % PEF) (p<0.05).

Conclusion: An improvement was seen in asthma with weight loss in obese asthmatic patients both clinically and functionally. However, further studies are needed to reveal the mechanism through which the body mass changes affect the progress of asthma.

Keywords: Asthma, obesity, diet, AQLQ, anthropometric measurement

[Abstract:0554] EPS-007 [Accepted: E-Poster] [Clinic Problems - Others]

Differential Diagnosis of Chronic Dyspnea: Swyer-James Syndrome

Fuat Aytekin, Pınar Yıldız Gülhan, Mehtap Oktay, Merve Erçelik

Department of Chest Diseases, Düzce University School of Medicine, Düzce, Turkey

Introduction: Swyer James (Macleod) Syndrome is a rare disease characterized by unilateral hyperlucent lung, volume loss and smaller hilar shadowing on the affected side. It is thought to develop secondary to viral bronchiolitis and pneumoniae that were undergone in childhood. It can be confused with pulmonary embolism, other diseases that cause perfusion defects and some airway diseases that cause effort dyspnea. We aimed to present our patient who was admitted to various external centers with the complaint of post-infectious dyspnea on exertion that increased for the last one year.

Case Presentation: A 22-year-old male patient was admitted to the emergency service with the complaints of shortness of breath, chest pain, and weakness. He said that he had dyspnea on exertion for the past year. He had a smoking history of 5 packs/year and was still an active smoker. He was a university student at nursing department. He did not have any history of pulmonary infections in childhood. His blood values were normal, and the vital findings were stable. Posterior anterior (PA) chest X-ray of the patient revealed a decrease in the vascular structures of the left lung, and a hyperlucent appearance. The

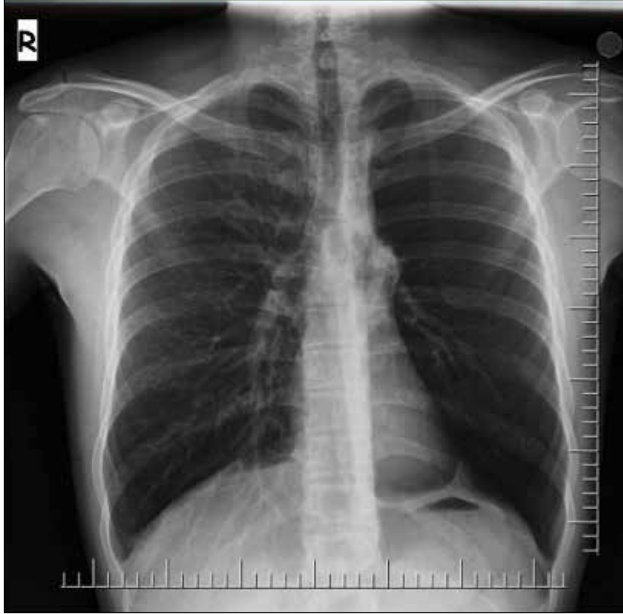

Figure 1.

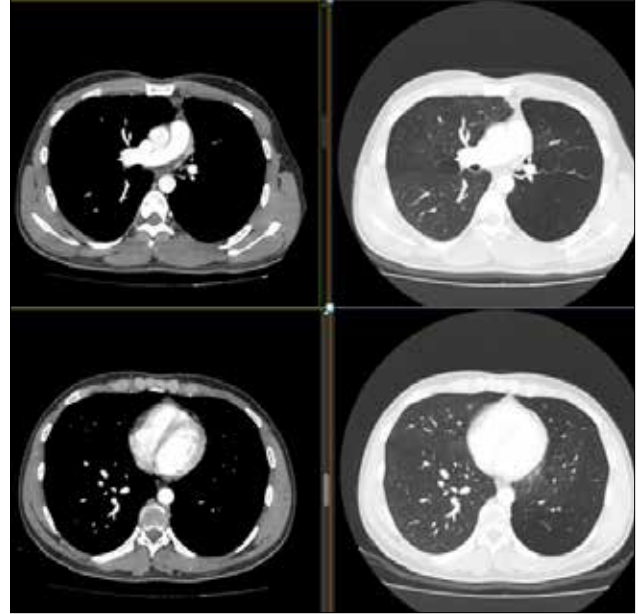


Figure 2.

patient's respiratory function tests were normal. Pulmonary angiography was performed with the prediagnosis of pulmonary embolism in the patient in whom PA chest X-ray showed a reduction in unilateral vascular structures and who had chest pain and dyspnea. In thorax CT angiography; the left main pulmonary artery and branches had a hypoplastic appearance in comparison to the right side; in addition, the right upper lobe artery could not be monitored in the distal side and observed as a stump in the proximal side, and the left basal segment bronchi were observed to be excessively narrow. In the left lung, an increase in lucency compatible with the ventilation increase was observed. The patient was diagnosed with Swyer James syndrome clinically and radiologically.

Conclusion: Swyer-James (Macleod) syndrome should be considered in the differential diagnosis of patients with unilateral hyperlucency in PA chest X-ray, recurrent pulmonary infection and dyspnea.

Keywords: Swyer, James, syndrome

[Abstract:0556] SS-097 [Accepted:Oral Presentation] [Thoracic Surgery]

Long Term Survival and Prognostic Factors of Completion Pneumonectomy for Non Small Cell Lung Cancer

Celal Buğra Sezen, Celalettin İbrahim Kocatürk, Salih Bilen, Cem Emrah Kalafat, Cemal Aker, Kemal Akpınar

Department of Thoracic Surgery, Yedikule Training and Research Hospital for Chest Diseases and Thoracic Surgery, İstanbul, Turkey

Objectives: Complementary pneumonectomy is the removal of residual lung tissue after the first surgical resection. The increase in the frequency of detection of lung cancer, the prolongation of survival time, the follow up of patients with multidisciplinary team increased the incidence of metacon cancer and the frequency of complementary pneumonectomy. Our aim was to identify factors that affect operative mortality and morbidity and long-term survival after completion pneumonectomy.

Methods: The study's ethical committee approval was obtained for the study (version:1115/2011-KAEK-50) . The data of the patients who were operated for NSCLC between January 2000 and December 2015 were reviewed retrospectively from the data set prepared prospectively. CP was performed to 44 (0.86%) of 5086 patients with NSCLC. Post-operative mortality was considered to be the death of the patient during the hospitalization or in the first 30 days. Morbidity was evaluated as com-

plications (respiratory failure, mechanical ventilator requirement, acute renal failure, bronchopleural fistula, empyema, arrhythmia, and wound infections requiring revision) during the first 30 days after surgery. The pathologic staging of the patients was made according to the 8th stage.

Results: 32 non-small cell lung cancer patients, 31 males (96.9%) and 1 female (3.1%) were included in the study. Complications were observed in 15 patients (46.9%) after CP. The most common complication was atrial fibrillation in

Table 3. Characteristics of Completion Pneumonectomies and Histopathological Evaluation

Variables	n	%
Completion Types		
Standard Pneumonectomy	24	75
Sleeve Pneumonectomy	4	12.5
Extended Pneumonectomy	4	12.5
Surgery Side		
Right	19	59.4
Left	13	40.6
Stage (8th)		
Ta1	3	9.4
Ta2	3	9.4
Ta3	9	28.1
Tb	3	9.4
Tc	3	9.4
Td	10	31.3
Te	3	9.4
Tf	3	9.4

Figure 1. Characteristics of Completion Pneumonectomies and Histopathological Evaluation

Table 4. Evaluation of the Factors Affecting the Complication

Variables	Complication (No) n (%)	Complication (Yes) = (%)	p-value
Gender			
Male	16 (94.1)	15 (50)	1
Female	1 (5.9)	0 (0)	
Smoke Habit (Pack/Year)	22 ±20.5	36 ±24.8	0.004
Comorbidity			
Cardiac Problems (Arrhythmia/CF/HT)	4 (23.5)	12 (60)	0.002
CHF	0	2 (13.3)	0.212
DM	5 (29.4)	5 (16.7)	1
PVD*	2 (11.8)	2 (13.3)	1
Operation Side			
Right	9 (52.9)	10 (66.7)	0.436
Left	6 (47.1)	5 (33.3)	
Second Operation Resection Type			
Standard PM**	14 (84.7)	10 (66.7)	0.441
Sleeve PM	2 (11.8)	2 (13.3)	
Extended PM	1 (5.9)	1 (6.7)	
Adjuvant Treatment After Initial Resection			
No	6 (35.3)	5 (33)	0.297
Yes	11 (64.7)	6 (40)	

PVD: Pericardial Vasculi Disease; PM: Pneumonectomy; HT: Hypertension; CF: Cardiac failure

Figure 2. Evaluation of the Factors Affecting the Complication

Table 3. Kaplan Meier Survival Analysis

Variables	2 Year Survival (%)	5 Year Survival (%)	10 Year Survival (%)	Median Survival (month)	95% Confidence Interval	p Value
Histopathology						
Adenocarcinoma	60.0	38.3	24.2	69.0(17.4)	36.9-95.6	0.871
Squamous cell carcinoma	37.8	25.7	24.8	68.0(16.2)	48.5-92.8	
Tumor Diameter						
<7cm	74.8	50.8	38.8	68.0(17.1)	46.1-89.8	0.183
≥7cm	50	50	0	11.0(13.8)	0-49.5	
N Stage						
N ₀ -N ₁	75.8	53.5	35.0	67.0(16.0)	47.2-86.2	0.034
N ₂	0	0	0	8.0(6.5)	0-40.8	
Adjuvant Therapy (After second operation)						
No	55.3	33.3	25	53.0(12.5)	3.94-100	0.050
Yes	54.7	38.8	32.5	68.0(16.4)	48.5-88.1	
Time Interval between primary surgery and recurrence of cancer						
<2 Year	48.7	37.1		73.0(15.0)	41.64-102.8	0.268
2-4 Year	88	50.8		67.4(16.4)	47.14-88.8	
≥4 Year	70	52.5		62.7(17.5)	46.5-108.8	

Figure 3. Kaplan Meier Survival Analysis

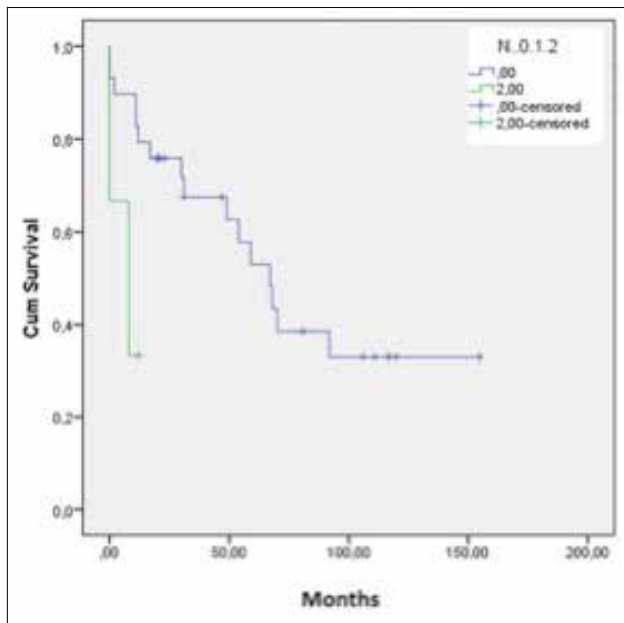


Figure 1. Kaplan Meier Survival Analysis of Lymph Node Status

10 patients (31.3%) . Non-invasive mechanical ventilatory requirements due to respiratory failure were found in 5 patients (15.6%) , pneumonia 6 (18.8%) , bronchopleural fistula 5 (15.6%) , renal failure 2 (6.3%) and wound infection 1 (3.1%) required for revision. Median hospitalization time after CP was 11.4±8.4 (range: 2-36) days. Postoperative mortality was 9.4% (n:4) . Overall survival was 67±10.3 months (50.3% at 5 years, 31.2% at 10 year) . Major factors affecting survival were adjuvant therapy and N2 lymph node status.

Conclusion: The point to keep in mind regarding completion pneumonectomy is that it can be administered to patients with sufficient pulmonary capacity and those who can tolerate the operation. The cases should be planned by taking into consideration particularly age and the risk to be taken. In summary, completion pneumonectomy involves an acceptable mortality rate with 9.4% and a high morbidity rate with 40.6%. Therefore, it should be attempted only in experienced thoracic surgery clinics that can provide a post-operative intensive care service.

Keywords: Completion pneumonectomy, prognostic factors, lung cancer, synchronous lung cancer, metachronous lung cancer

[Abstract:0559] EPS-218 [Accepted: E-Poster] [Thoracic Surgery]

A Case of Rare Bronchogenic Cyst with Atypical Occurrence

Cem Emrah Kalafat, Celal Buğra Sezen, Salih Bilen, Cemal Aker, Halide Nur Urer, Celalettin İbrahim Kocatürk

Department Of Thoracic Surgery, Yedikule Training and Education Hospital for Chest Diseases and Thoracic Surgery, İstanbul, Turkey

Introduction: The bronchogenic cysts first described by Meyer in 1859 are originated from primitive foregut. If this development is at an early stage, the cyst is located close to mediastinum, trachea, carina or main bronchi. If these lesions are formed in the late period, will be located peripheral. Surgical excision is recommended because of the malignancy potential, even if it is asymptomatic. We present a bronchogenic cyst arising from the 9th costavertebral area, which was very rarely located and first described in english literature.

Case Presentation: A 16-year-old male patient was administrated to hospital with car accident. Was foun a lesion in insidentalaly in thorax computerise tomography. The lesion was 27×17 mm diameter, smooth shape in costavertebral area without any neural spinal canal involvement (Figure 1) . Patients went through operation with preliminary diagnosis of posterior mediastinal tumor. Video asistant thoracoscopic surgery with single 4 cm incision approched. At the exploration, smooth shape, cycstic lesion was found at the the left 9th costavertebral area, without any connection with the spinal cannal. The lesion was excised en bloc (Figure 2) . Postoperative pathology of the patient was reported as bronchogenic cyst.

Conclusion: The recommended approach for the diagnosis and treatment of posterior mediastinal lesions is the surgery. It should be kept in mind that these lesions, which are usually neurogenic origin, may rarely presented as a bronchogenic cysts.

Keywords: Bronchogenic cyst, rare tumor, video assisted thoracoscopic surgery, first case

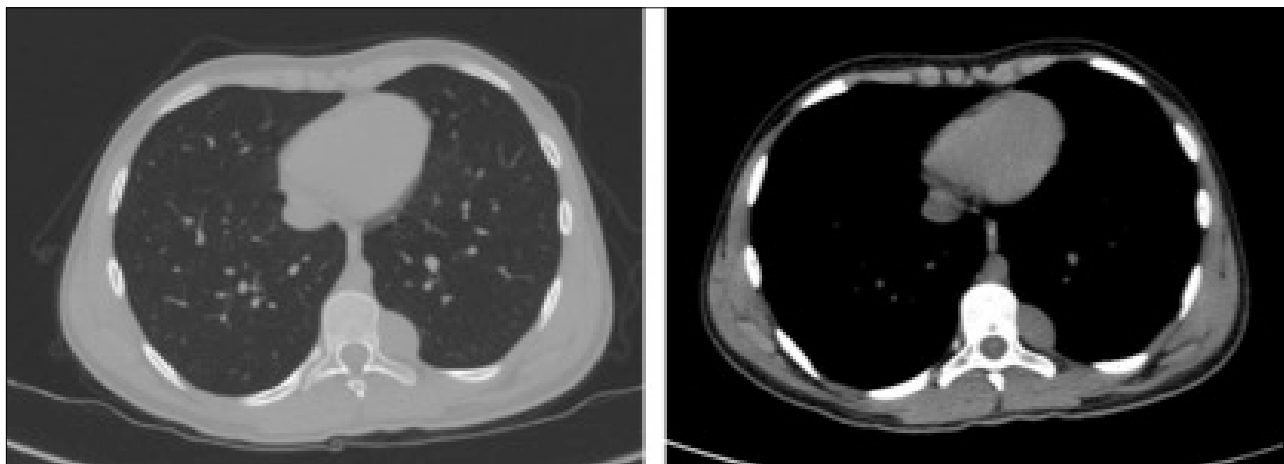


Figure 1. Thorax Ct: 27 × 17 mm lesion in 9th costavertebral area

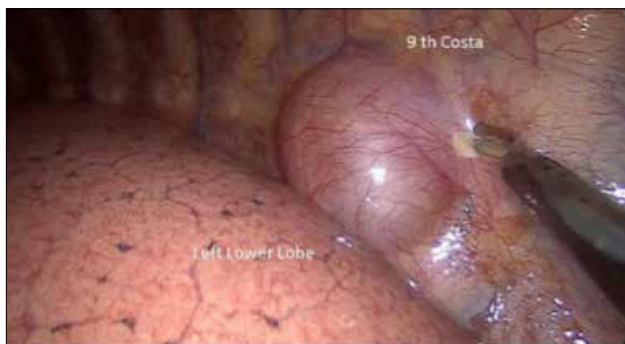

Figure 2. Peri-operativa image of the lesion

[Abstract:0566] EPS-154 [Accepted: E-Poster] [Respiratory Infections]

A Patient with Nocardia, Candidiasis and Aspergillosis Infection Who is Liked Cavitory Tuberculosis

Merve Örün Zengin, Lale Sertçelik, Ipek Erdem, Melis Okşaşoğlu, Armağan Fatma Hazar

Health Sciences University, İstanbul Süreyyapaşa Training and Research Hospital for Chest Diseases and Thoracic Surgery, İstanbul, Turkey

A 51 years old male patient with ankylosing spondylitis was applied to our hospital with the complaints of cough, sputum, chills and fever for 2 mo. AFB was detected as positive on sputum examination so he was admitted to tuberculosis clinic and started o TB treatment with HRZE (6.11.2017). His biochemical parameters and hemogram were within normal limits.

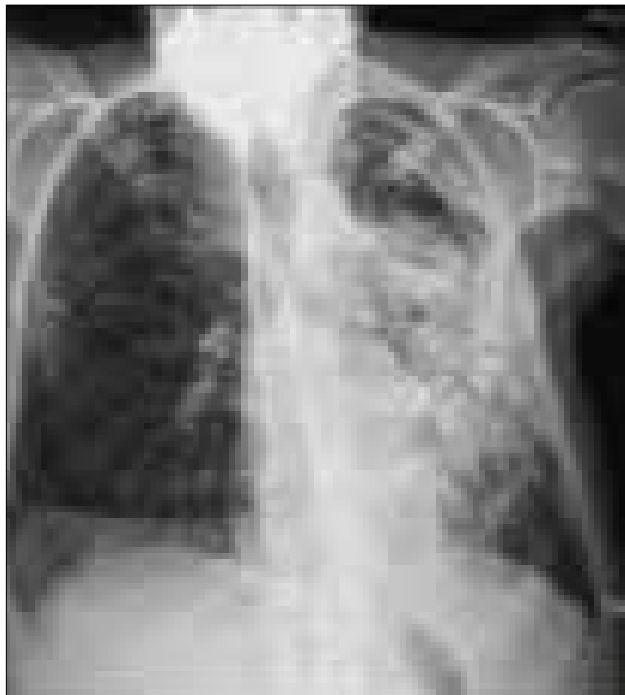

Figure 1. Chest XR

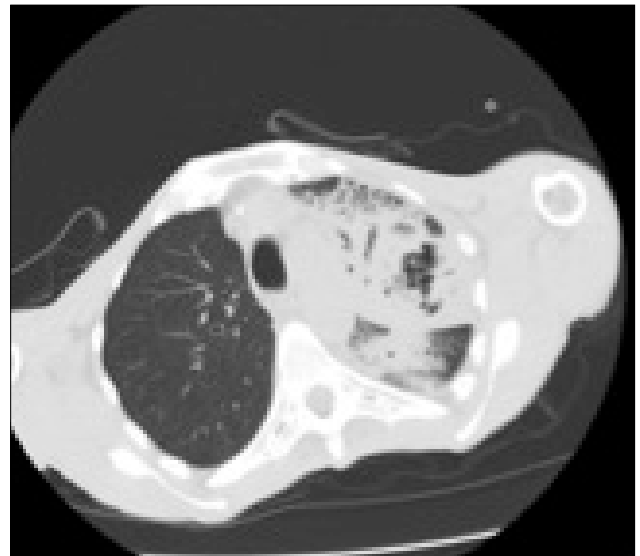

Figure 3. CT Scan

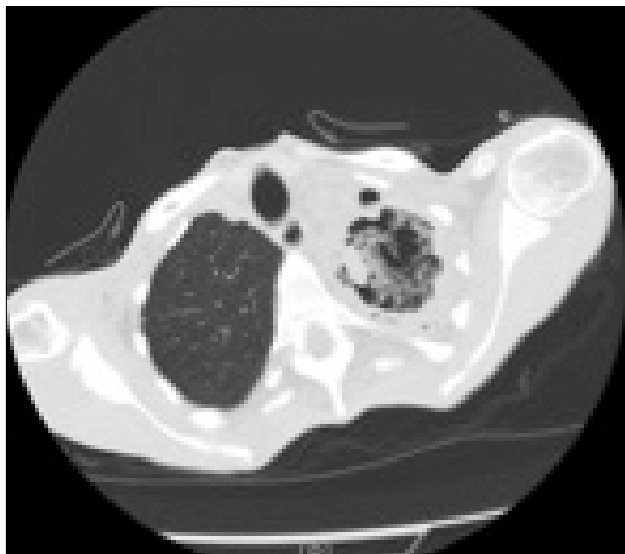


Figure 2. CT Scan

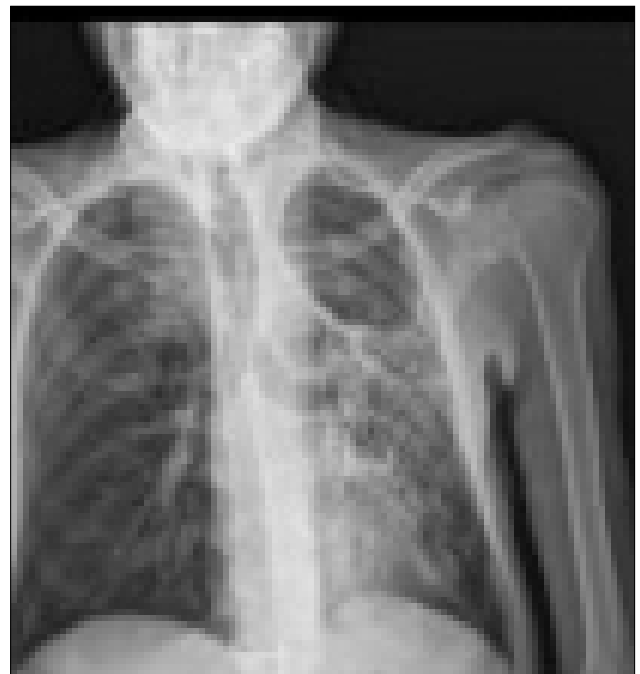

Figure 4. After Treatment Chest XR

After one week of treatment, progression in chest X-R was detected. At this point, the case was thought to be an infection other than tuberculosis. Subsequently acid fast bacilli in sputum was found to be negative for three times. So the patient was transferred to non-TB chest clinic. Since the patient was seriously hypoxic, he was transferred to level II-ICU. At the first day of ICU: his biochemical and hemogram analysis were as follows: wbc: 40.200 Hgb: 9.8 PH: 394.00 BUN: 23 Crea: 0.45 Na: 130 K: 3.5 AST: 30 ALT: 7.

On chest X-R, there was irregular opacity involved all lung areas predominantly upper lobes. FOB was performed at 15.11.2017; left bronchial sistem was covered lwith purulent ecretions, hyperemia. There wasa Iso a fungal planque like lesion on left upper lobe mucosa. His anti bigram was changed as meropenem plus linezolid plus voriconazole.

His anti-TB treatment was stopped, sputum culture examination for nocardia was required. At 15.11. 2017 *Nocardia* was detected on sputum examination. Also *Candida* spp. was detected on bronchial lavage culture. Voriconazole was stopped, anidulofungin was added to treatment regimen. Since galactomannan level on blood examination was found o be >6; probability of *Candida-Aspergillus* coexistence was thought.

Fiberoptic bronchoscopic examination was performed again. Left lower lobe anterior segment was seen as closed with white necrotic material. *Candida* sp. was bronchial lavage culture. It was decided ocontinue treatment with voricenazole. At the 23rd day of ICU treatment, there was no need for vasopressor treatment any more.

Patient was transferred toc hest clinic with the diagnosis of pulmonary nocardiosis and invasive pulmonary aspergillosis.

Imiperem plus trimetoprim- sulformetaxazole treatment for 28 days.TMP-SMP treatment was planned to continue for 6 mo, voriconazole treatment was planned to continue for 6-12 mo. The complaints of patient and radiological findings were seriously regressed on polyclinic admissions.

Keywords: *Aspergillosis, Candida, Nocardia, tuberculosis*

[Abstract:0567] SS-042 [Accepted:Oral Presentation] [Asthma and Allergy]

Evaluation of Influenza and Pneumococcal Vaccination In Patients with Asthma or with COPD

Şule Gündoğdu, Bilun Gemicioğlu, Serdar Erturan

Department of Pulmonary Diseases, İstanbul University Cerrahpaşa School of Medicine, İstanbul, Turkey

Objectives: Adult vaccination is very important for the prevention of infectious diseases. We aimed to compare vaccination frequency and vaccination attitudes of patients with asthma or with Chronic Obstructive Pulmonary Disease (COPD) .

Methods: The study included consecutive 103 asthma and 92 COPD patients who applied to the outpatient clinic of pulmonary diseases department between 1st. November to 31th December 2017. Questionnaires including sociodemographic data, vaccination information and attitudes about vaccinations were applied.

Results: The mean age of the patients was 55.8±15.7 years and 53.8% (n:105) were female. Frequency of influenza and pneumococcal vaccines of patients was presented in Table 1. In addition, patients were divided two groups by age (≥65 years and <65 years) and their vaccination frequency was presented in Table 2. It was determined that 82.3% of the patients learned the vaccination from their physician. There was no physician's recommendation for influenza vaccination in 38.3% of the patients (45.3% of the asthma patients, 29.4% of the COPD patients) . When both groups of 65 years of age and older were questioned

Table 1. Frequency of influenza and pneumococcal vaccine in patients with asthma and COPD (*p≤0.05)

	Influenza vaccine	Pneumococcal vaccine
Asthma (n:103)	17.5%	9.7%
COPD (n:92)	29.3*%	21.7*%

Table 2. Frequency of influenza and pneumococcal vaccine in patient with ≥65 years asthma and ≥65 years COPD (p>0.05)

	Influenza vaccine	Pneumococcal vaccine
≥65 years asthma patients (n:23)	30.4%	26.1%
≥65 years COPD patients (n:41)	31.7%	24.4%

that they did not cause pneumococcal vaccination, 58.3% of the patients were not found to have a physician's recommendation.

Conclusion: The frequency of influenza and pneumococcal vaccination was low in both groups. When the reasons for not having the vaccine were examined, it was determined that the absence of the physician's proposal is the most important problem.

Keywords: Asthma, COPD, influenza vaccine, pneumococcal vaccine

[Abstract:0569] PS-021 [Accepted:Poster Presentation] [Clinical Problems - Diffuse Parenchymal Lung Disease]

Pulmonary Manifestation of Primary Sjörger's Syndrome

Kerem Ensarioğlu, Bahar Kurt

Department of Pulmonary Medicine, School of Health Sciences, Dışkapı Yıldırım Beyazıt Training and Research Hospital, Pulmonary Medicine Clinic, Ankara, Turkey

Primary Sjörger's Syndrome (SS) is an autoimmune disease with characteristic oral and ocular dryness without any underlying rheumatologic disease. As present in two patients in this case report, SS can cause extraglandular organ manifestations in addition to its routine glandular involvement with interstitial fibrosis being the most commonly seen pulmonary manifestation of primary SS.

First case, 69 years old N.G came to polyclinic with dyspnea. Upon further investigation her medical history showed that she was evaluated with Thorax Computer tomography (Thorax-CT) after a traffic accident in 2007, in which interstitial changes were found. She was further evaluated with pulmonary function test (PFT), results being in favor of restrictive pattern (Forced Expiratory Volume (FEV1) : %79, Forced Vital Capacity (FVC) : %71, FEV1/FVC: %92).

In rheumatologic evaluation, C-reactive Protein was found elevated and Anti-Extractable Nuclear Antigens were found positive. Due to no rheumatologic disease present oral and ocular dryness as well as changes in Thorax-BT in favor of interstitial lung disease, patient was diagnosed with Primary Sjörger's Syndrome and was given a regime of glucocorticoid, azathioprine and hydroxychloroquine. Upon admission to ward, dyspnea was evident and resting O₂ saturation was found %92, with basal fine rales present bilaterally. Anti-fibrotic treatment was not given due to presence of Sjörger's.

Second case is F.Y, female 64-year-old patient who admitted to emergency ward with dyspnea. Respiratory acidosis was observed along with bilaterally hilar originated and peripherally advancing reticular densities upon admission. Physical examination was in favor of interstitial disease, with bilateral fine rales presence up to middle zones, desaturation with an average value of %75. In her 2006 Thorax-BT, ground glass presence and interlobular septal thickening was seen. Anti-double stranded DNA was found positive, while the remaining rheumatologic markers were negative. Due to oral and

Table 1. Case 1 PFT Results

Tarih	FEV1	FVC	Oran
13.05.2008	71	71	92
19.06.2008	73	72	86
07.10.2008	87	81	90
07.11.2008	88	78	94
30.12.2008	76	70	92
03.03.2009	107	102	88
05.10.2009	83	76	91
18.11.2009	87	82	115
25.01.2010	62	68	100
10.06.2010	95	91	77
16.01.2012	65	56	127
19.03.2012	77	74	113
14.06.2012	71	60	121
23.07.2012	80	80	100
07.01.2013	86	80	89
16.04.2013	93	84	92
13.11.2013	86	77	92
09.01.2014	86	78	90
06.11.2014	76	55	140
10.07.2015	85	79	88
16.12.2015	76	55	140
28.12.2015	64	49	94
11.01.2016	81	76	95
11.12.2017	54	51	112
19.12.2017	92	86	88

Pulmonary function test (PFT) results of Case 1 during her follow-up.

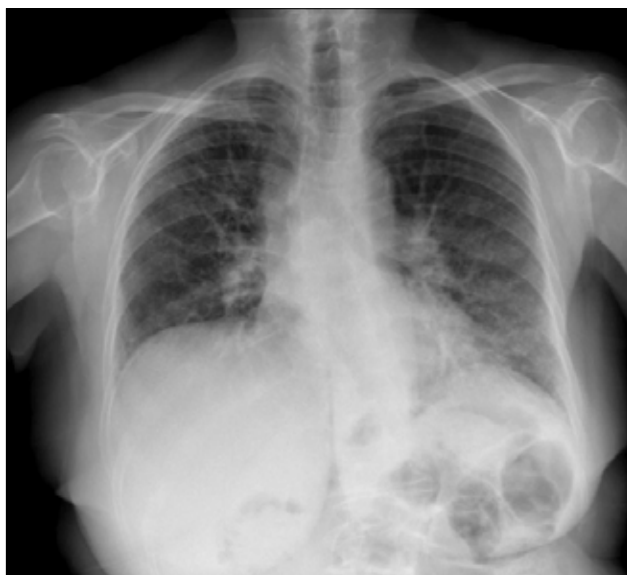

Figure 1. Case 1 Chest Radiograph

Patient's posteroanterior chest radiograph upon admission.

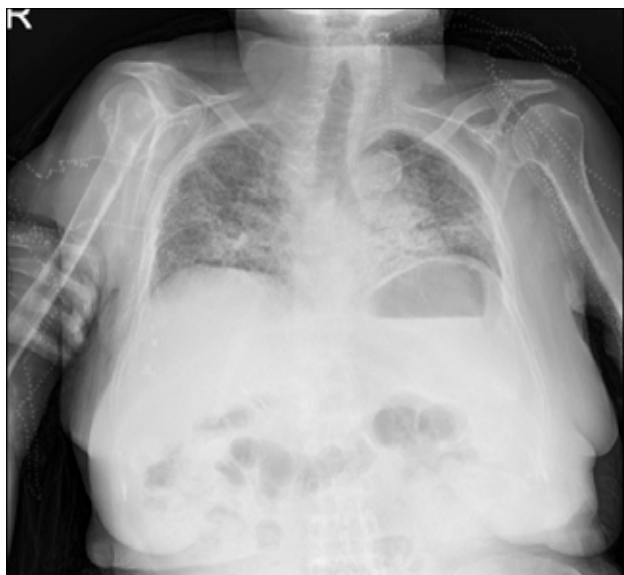

Figure 2. Case 2 Chest Radiograph

Patient's posteroanterior chest radiograph upon admission.

ocular dryness, she was diagnosed with Sjörge'n's, for which a treatment of azathioprine, glucocorticoid and hydroxychloroquine was given with azathioprine being removed due to elevated liver enzymes in the past seven years. Progression was evident in Thorax-BT taken at admission to the ward compared to 2006's images. Pulmonary arterial pressure was found 45 mmHg, her PFT was in favor of restrictive pattern (FVC %37, FEV1 %41, FEV1/FVC %91). DLCO and Six Minutes Walk Test could not be done due to patient's condition. Schimmer test was found normal, while buccal biopsy revealed lymphocytic infiltration.

Anti-fibrotic treatment was not given to both patients due to presence of Sjörge'n's.

Keywords: Lung, fibrosis, interstitial, primary, sjörge'n's

[Abstract:0574] SS-060 [Accepted:Oral Presentation] [Environmental and Occupational Lung Diseases]

Evaluation of the Cases Diagnosed with Occupational Asthma in İstanbul Occupational Diseases Hospital

Bahar Tüzün¹, Özkan Kaan Karadağ¹, Fatma Eren², Duygu Acar Karagül², Zeki Kılıçaslan³

¹Istanbul Occupational Diseases Hospital, İstanbul, Turkey

²Department of Occupational Diseases, İstanbul University İstanbul School of Medicine, İstanbul, Turkey

³Department of Chest diseases, İstanbul University İstanbul School of Medicine, İstanbul, Turkey

Objectives: Occupational asthma is a disease characterized by variable airway restriction and/or hypersensitivity and/or inflammation, which are caused by the reasons or circumstances attributed only to a specific/special working environment, not to non-work reasons. Occupational asthma prevalence has been reported at a rate of 9-25% in studies conducted in different business lines and it is one of the most common occupational diseases. The demographic, occupational and clinical characteristics of occupational asthma patients diagnosed in an occupational disease hospital have been presented.

Methods: This is a descriptive study in which 17 cases who were diagnosed with occupational asthma in İstanbul Occupational Diseases Hospital between January 2014-December 2017 were evaluated. After the occupational histories, symptoms, smoking histories, reversible respiratory function test, and allergy test results were evaluated in all cases, non-specific bronchial provocation test was performed in those for whom it was thought necessary, and they were followed up with PEF meter, considering whether they are working or not.

Results: Four of the 17 patients at the ages ranging from 23 to 51 and with a mean age of 39.00 ± 7.32 years were women. Four of the cases were working in the production of car parts, 3 cases were welders, 2 cases were working in a chemistry factory, 2 cases were working in a factory of chewing gum and confectionery, 1 case was making pitta in a restaurant, 1 case was working in an aluminum factory, 1 case was working in shoe production, 1 case was a cleaning personnel, 1 case was working in transformer production, and 1 case was working in cable production. Exposure durations to sensitizing agent were between 1.5 years and 20 years with an average of 6.06 ± 5.38 years. When the duration of symptom obtained with anamnesis information is taken into account, the sensitization duration is between 6 months and 12 years, and the average is 2.37 ± 3.08 years. Assessment of pulmonary function test in eight cases was obstructive, and 2 cases were mixed type. Pulmonary function test was normal in 7 cases during admission. The reversibility test performed with a short-acting bronchodilator was found to be positive in 10 cases, except for a case that was incompatible. Prick test that was performed with

Table 1. Occupational diseases cases

Age	Gender	Occupation	Exposure	Smoking (p/y)	Duration of employment (year)	Duration of symptoms (year)	RFT	RFT with reversibility	Allergy test	BPT	PEF (%)
40	F	Manufacture of automobile pieces	Thinner, adhesive	None	3	2	Mixed type	Negative	Negative	Positive	>20
42	F	Manufacture of automobile pieces	metal, plastic, cardboard dust	12	6	0,25	Obstructive	Negative	Positive	Positive	
45	F	Manufacture of automobile pieces	plastic, chemical	None	2	1	Obstructive	Pozitive	Negative		27
30	M	Manufacture of automobile pieces	Thinner, adhesive	1	3	2	Mixed type	Negative	Positive	Positive	41
23	M	welder	Welding smoke	2	2	1.5	Obstructive	Positive	Negative		23
40	M	welder	Welding smoke	1	3	2.5	Normal	Positive	Negative	Positive	68
35	M	welder	Welding smoke	None	10	8	Normal	Positive	Negative		35
45	v	Chemical factory	Adhesive, chemical	Gave up	3	2.5	Normal	Non-cooperative	Negative	Positive	15
35	M	Chemical factory	Dye dust, chemical	3	4	3	Normal	Positive	Negative	Positive	
32	M	Restaurant	Wood smoke, flour powder	None	10	9	Obstructive	Pozitive	Negative		
30	M	Chewing gum factory	Food coloring and flavor dye		7	1	Obstructive	Positive	Positive		
38	v	Chewing gum factory	Food coloring and flavor dye		3	2,5	Normal	Pozitive	Pozitive		> 29
41	F	Aluminium factory	Metal dust	None	2,5	1	Normal	Negative	Positive	Positive	
43	M	Cable manufacture	Dye dust, chemic	25	6	1,5	Obstructive	Positive	Positive	66	
47	M	Shoe making	Adhesive, chemical	None	20	8	Obstructive	Negative	Positive		
51	M	Cleaning staff	Chemical	None	1.5	1	Normal	Negative	Negative	Positive	
46	M	Transformer manufacture	Coal dust, chemical	3	17	16	Obstructive	Positive	Negative		

common respiratory allergens was positive in 7 cases. Sensitivity to nonspecific agent was detected in 8 cases in whom bronchial provocation test was performed. PEF variability in 8 of 9 patients in whom PEF meter measurement was able to be performed was found to be over 20%.

Conclusion: The wide age range expected for asthma disease caused by occupational factors and the application status from various professions were found in our study, as well. The duration of sensitization varying according to many factors was found in a very wide range in our study, and the long duration of 3.7 years on average which passed between the onset of the symptom and the diagnosis, and during which the patients continued to be exposed to the sensitizing agent was noteworthy.

Keywords: Occupational asthma, duration of exposure, allergy test

[Abstract:0577] PS-256 [Accepted:Poster Presentation] [Environmental and Occupational Lung Diseases]

A Patient with Organic Phosphat Inhalation

Melis Okşaşoğlu, İpek Erdem, Lale Sertçelik, Merve Örün Zengin, Armağan Fatma Hazar

Health Sciences University İstanbul Sureyyapasa Chest Diseases and Thoracic Surgery Training and Research Hospital, İstanbul, Turkey

Organic phosphate is used frequently in fertilization in agriculture. As a result of inadequate use of appropriate protection methods, organic phosphate intoxication can be seen by inhalation or absorption by the skin. Our patient was admitted to our hospital with dyspnea and deep hypoxia developed at the same day after fertilization. On the basis of our case, we aimed to put attention to importance of history of the patients and the safeguard measures during fertilization. 52 year-old female patient was admitted to our chest clinic with shortness of breath and fever. Her complaints were started after the use of fertilizer on hazelnut trees 5-6 days ago. She had diabetes mellitus and hypertension for 3 years. On her physical examination: TA: 100/70 mmHg, pulse: 85/mm fever: 36.2°C, bpm: 17 O₂ sat: 91 (fiO₂: 45%). On chest auscultation: bilateral crackles lab.

Findings: wbc 5700 Hgb: 12.9 Htc: 39 Neut: 4.86 pH: 7.38 CRP: 37 D-dimer: 4.93 PCO₂:37 sat: 96 HCO₃: 28

Chest XR: Consolidations on bilateral lower zones.

CT findings: consolidations with air bronchograms on right upper lobe and bilateral lower lobes.

Pulmonary function test: FEV1/FVC: 94% DLCO: 50%.

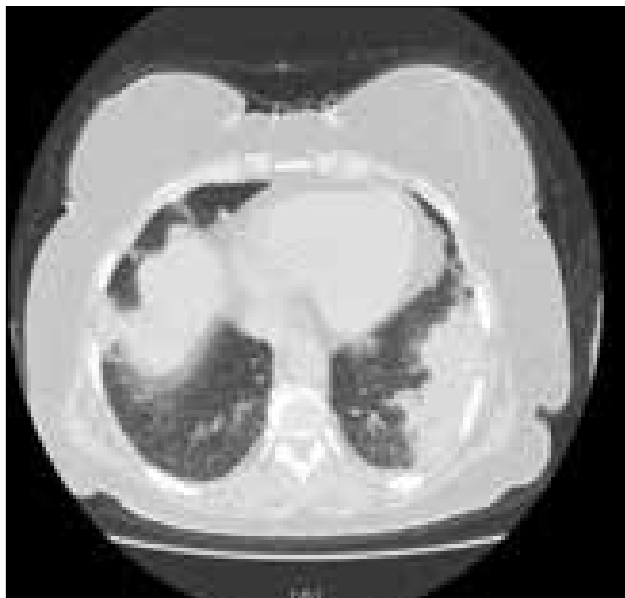


Figure 1. CT Scan

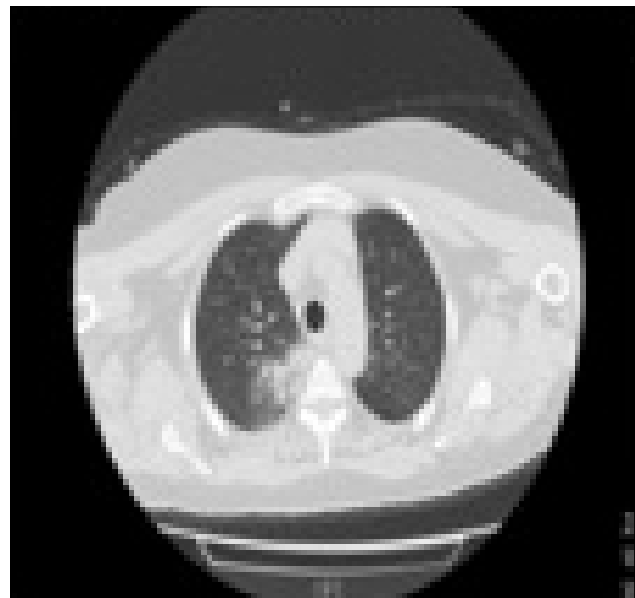


Figure 2. CT Scan

The patient was followed up with 4-5 L/min nasal O₂. Ampirically; Ampicillin-sulbactam 4x1 g, clarithromycin 2x500mg, metil prednisone 1x40mg, furosemide 1x20mg treatment was started. Blood culture was normal flora. Ingradients of fertilizer was searched and phosphate poisoning was considered. The toxicology centre was consulted and methemoglobin value in arterial blood gases was searched. Since its value was found under 20, nasal oxygen was adequate for the patient. On the follow up hypoxemia was deepened. There was no trombus formation on lower extremity venous doppler ultrasonography examination. Cardiology consultation was normal. Chest CT angiography was normal. Since her chest x-R findings were progressed and CRP level in the blood increased 2X, patient was transferred to ICU. After 3 day, she was retransferred to our clinic with the treatment of piperacilin-tazobactam 4x4, 5g, metil prednisolone1x1 20 mg iv. On clinic follow up, metilprednisolone dose is lowered to 80 mg/day and gradually decreased. Her oxygen saturation was about 92% without oxygen. After 20 days of discharge her general condition was improved. Chest X- R findings were seriously regressed.

Keywords: Organic phosphat, respiratory distress,poison

[Abstract:0579] PS-023 [Accepted:Poster Presentation] [Clinical Problems - Diffuse Parenchymal Lung Disease]

Antifibrotic Treatment in Idiopathic Pulmonary Fibrosis: Real-Life Experience

Fatma Tokgöz Akyıl¹, Tülin Sevim², Reyhan Yıldız², İpek Özmen², Meltem Çoban Ağca², Soner Umut Küver², Tülay Törün²

¹Department of Pulmonology, Çanakkale State Hospital, Çanakkale, Turkey

²Department of Pulmonology, University Health Sciences İstanbul Süreyyapaşa Training and Research Hospital for Chest Diseases and Thoracic Surgery, İstanbul, Turkey

Objectives: Antifibrotic treatment in idiopathic pulmonary fibrosis (IPF) have shown efficacy and safety, however, real life clinical experience is limited. In present study, antifibrotic treatment results in patients with IPF is reported.

Methods: The present study is a retrospective, single centre study designed in a training hospital. Thirty-three patients who were initiated antifibrotic treatment with a pattern of usual interstitial pneumonia either histopathologically or radiologically and who were diagnosed as IPF were evaluated. Demographics, side effects, treatment efficacy and tolerability were investigated.

Results: Of all the 33 patients, 22 (67%) were male and the mean age was 66±10 (35-87) years old. The most common presenting symptoms were unproductive cough and shortness of breath on exertion with an avarage duration of 21.5 (4-66) months. Physical examination revealed velcro rales in 94% (n=31) and finger clubbing in 48% (n=16) . Two patients were siblings and 3 patients had doubtful family history. Nine patients were diagnosed histopathologically. The mean forced vital capacity (FVC) was 69% and carbon monoxide diffusing capacity (DLCO) was 51%. All patients were initiated antifibrotic treatment (nintedanib in 2 patients and pirfenidone in 31 patients) along with pulmonary rehabilitation in 7 and long-term oxygen treatment in 5. The mean follow-up duration was 20.8±6.1 (1-27) months.

Conclusion: Antifibrotic treatment was well-tolerated in 60% (n=19) with no side effects. A total number of 19 side-effects were recorded in the other 14 patients. The most common side effects were gastrointestinal-related (n=6, 18%) and skin-related (n=4, 12%) and the earliest was in the seventh day whereas the latest side effect was recorded in ninth month. Treatment was discontinued in 4 patients (12%) and 1 patient stopped treatment at the end of third month considering no clinical effect. Twenty-four patient, who had continued treatment at least 6 month, all but 2 patients had reported clinical efficacy, none of the patients except 1 had more than 15% decrease in FVC and DLCO. Clinical experience with antifibrotic treatment in IPF is generally similar to randomised controlled trials. Close monitoring is necessary for treatment tolerability and efficacy.

Keywords: Idiopathic pulmonary fibrosis, nintedanib, pirfenidone

[Abstract:0580] PS-315 [Accepted:Poster Presentation] [Lung Transplantation]

Kaposi's Sarcoma and Lung Involvement After Lung Transplantation; A Difficult Case and Its Management

Sinan Türkkan, Mahmut Subaşı, Fatmanur Çelik Başaran, Alkın Yazıcıoğlu, Mehmet Furkan Şahin, Ahmet Güngör, Erdal Yekeler

Health Sciences University, Turkey High Specialization Education and Research Hospital, Department of Chest Surgery and Lung Transplantation, Ankara, Turkey

Introduction: We have presented the case of Kaposi's sarcoma (KS), which shows a rapid progression in a short time after lung transplantation (LT).

Case Presentation: Bilateral LT was performed in a 58-year-old male patient with the diagnosis of COPD. Following basiliximab induction, triple immunosuppressive therapy consisting of Tacrolimus + mycophenolate mofetil (MMF) + Prednisolone

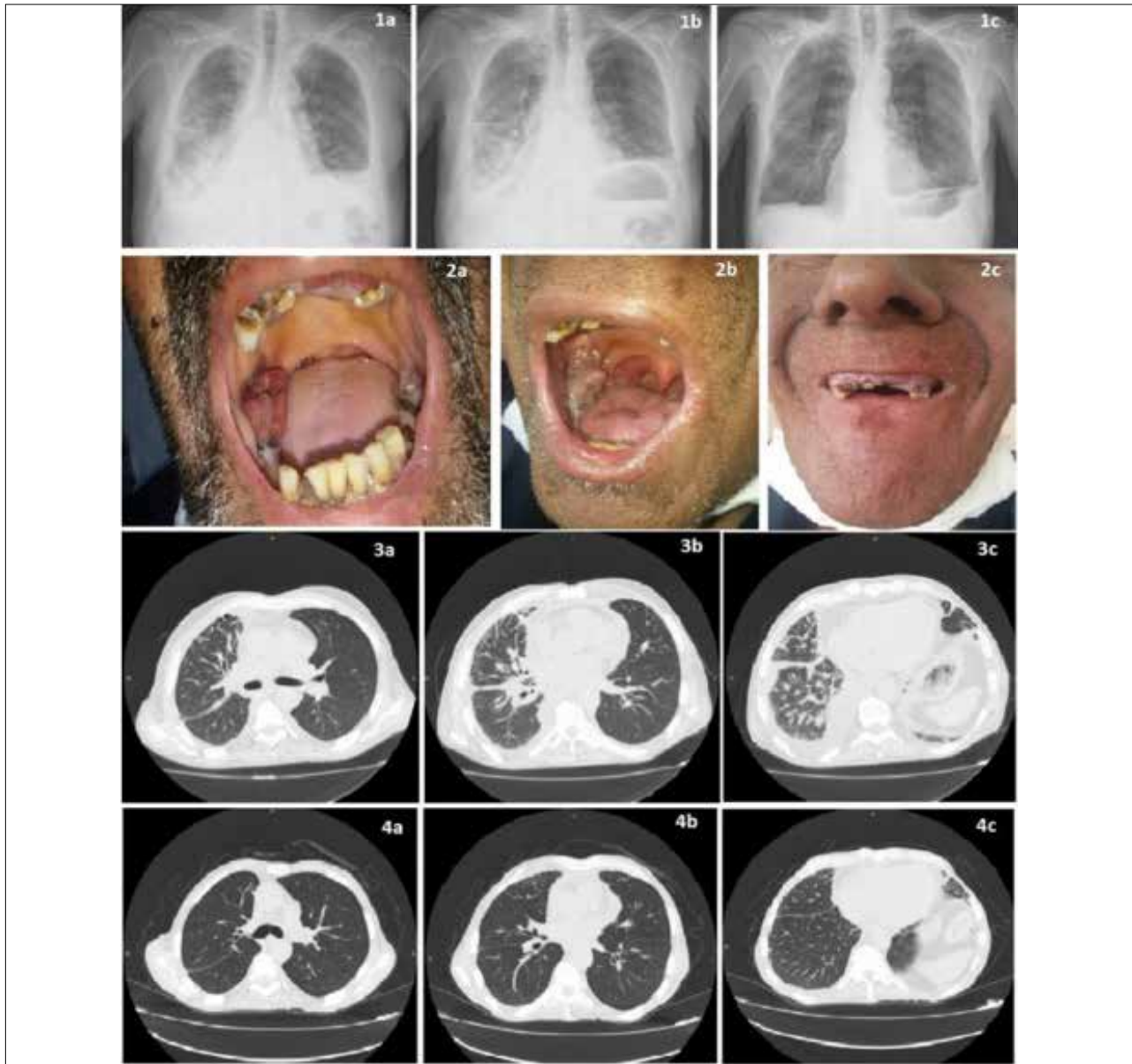


Figure 1. 1a) Pre-CT direct radiography image; 1b) Direct radiography image after two sessions of CT; 1c) Direct radiography image after 5 sessions of CT; 2a) Pre-Ct intraoral lesions 2b, 2c) Sizes of regressed intraoral lesions after 4 sessions of CT 3a,3b,3c) CT image before CT 4a,4b,4c) improved CT images after 5 sessions of CT

was started. For 3 months, the patient was given prophylactic valganciclovir and inhaled amphotericin B, and was discharged on the 33rd day. In post-operative 8th month, HHV-8 (+) KS diagnosis was made with skin biopsy that was taken following antiviral treatment due to a 1×1 cm red-purple maculopapular lesion under the left breast. After PET-CT, endoscopy, colonoscopy and systemic evaluation, distant organ involvement was not detected, and then surgical excision was performed. HHV-8 DNA (+) was detected in the blood. The dose of tacrolimus and prednisolone was reduced; after MMF was discontinued, the patient was started to be followed up. He was hospitalized with the symptoms of shortness of breath, bilateral pleural effusion and peribronchovascular edema in CT in the 9th month, and transbronchial biopsy was performed. During bronchoscopy, red-purple 1-1.5 cm lesions were also seen in the mouth and biopsy was taken. Transbronchial and mucosal biopsies were reported as KS. Because of the rapid progress, chemotherapy consisting of Doxorubicin+Bleomycin+Vincristine was initiated in the patient and tacrolimus treatment was replaced with everolimus. He was discharged in the 2nd week after CT. After 4 cycles of CT, intraoral and pulmonary lesions improved significantly. Weight loss, increase in the pigmentation of the skin, hair loss, neutropenia, increase in creatinine and peripheral neuropathy were observed after CT. The follow-up of the patient, who is still in good health without recurrence in the 7th month after the diagnosis and in the 15th month after transplantation, is continuing.

Conclusion: Opportunistic infections and malignancies caused by high-dose immunosuppression after LT in comparison to the other solid organ transplants are among the significant causes of morbidity and mortality. KS, which involves the skin and mucosa in immunosuppressed patients, is a tumor associated with HHV-8 and has been related with the reactivation of the virus due to immunosuppression. While it can be seen at a rate of 6% after kidney transplantations, it is at a level of case reports after LT. Therefore, there are patient-based experiences in the management of the disease when it occurs after lung transplantation. Reduction of immunosuppressive treatment and the initiation of mTOR inhibitors are the first step and are sufficient in most cases. Surgical excision, CT and RT are other treatment modalities. CT should be started without delay in patients having progression with decreased immunosuppression. A rapid clinical response was obtained from CT (doxorubicin+bleomycin+vincristine) in the patient with rapid progression, and the patient who was NYHA Stage-4 due to pulmonary findings was discharged within 2 weeks. To the best of our knowledge, there are data in the literature on the use of doxorubicin in KS after lung transplantation, but there is no data related to combined CT. After LT, skin malignancies and lymphoproliferative disease are the most common. Subsequent lesions in LT cases should be considered suspicious, prompt diagnosis should be made and effective treatment options should be applied as soon as possible.

Keywords: Lung transplantation, HHV-8, Kaposi's Sarcoma

[Abstract:0582] EPS-031 [Accepted: E-Poster] [Clinical Problems - Diffuse Parenchymal Lung Disease]

Histiocytosis X due to Two Patients

İpek Erdem, Lale Sertçelik, Armağan Fatma Hazar

Health Sciences University, İstanbul Süreyyapaşa Training and Research Hospital for Chest Diseases and Thoracic Surgery, İstanbul, Turkey

Introduction: Histiocytosis X is an interstitial lung disease known to be related with smoking. Smoking history is important for diagnosis. Histologically CD1a positive staining of biopsy material is diagnostic. History of the patient and typical radiology can put the diagnosis without biopsy. The only known treatment is quitting smoking. Transplantation should be evaluated in appropriate cases.

Case 1: 56 years old male patient working as accountant had 60 p. years of smoking history. He was exsmoker for 7 years. He was admitted to our hospital with dyspnea and hemoptysis complaints. He was using varfarin because of atrial fibrillation. Hemoptysis was thought to be because of high blood level of INR. So varfarin treatment was stopped. Rivoroksaban treatment was started instead. Thoracal CT findings revealed cystic lesions bilaterally and non-homogenous opacity in left lower lobe which was regressed with antibiotic treatment. Fiberoptic bronchoscopy was performed. Bronchoalveolar lavage (BAL) findings were within normal limits. Cytologic examinations of bronchial lavage were normal. Acid resistant bacilli were negative in direct examination and culture of bronchial lavage. Bronchial lavage culture was normal flora elements. There was no endobronchial lesion in FOB. In pulmonary function tests: FVC: 37%, FEV 1: 37%. Cardiology consultation was performed: ejection fraction was found to be 30%. After radiology consultation, his CT findings were evaluated as typical for Histrocytosis X with no need for further evaluation.

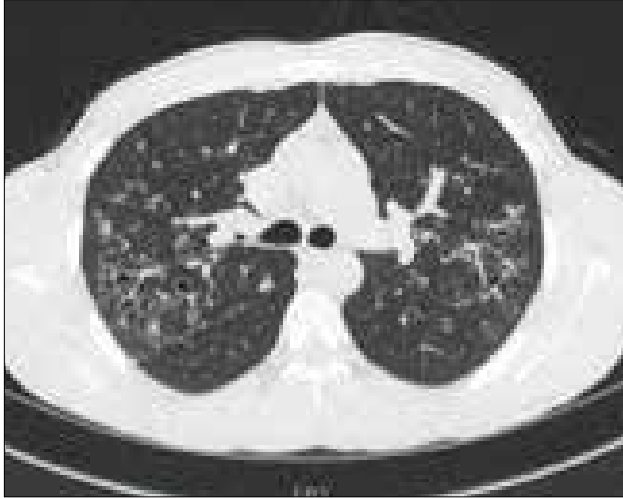


Figure 1. Case 1 HRCT

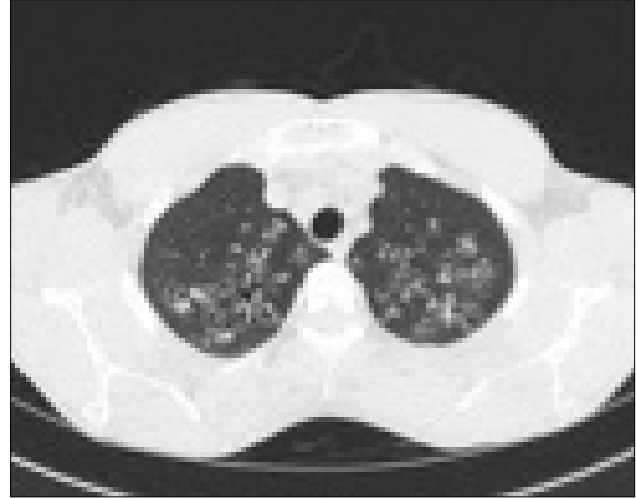


Figure 2. Case 1 HRCT

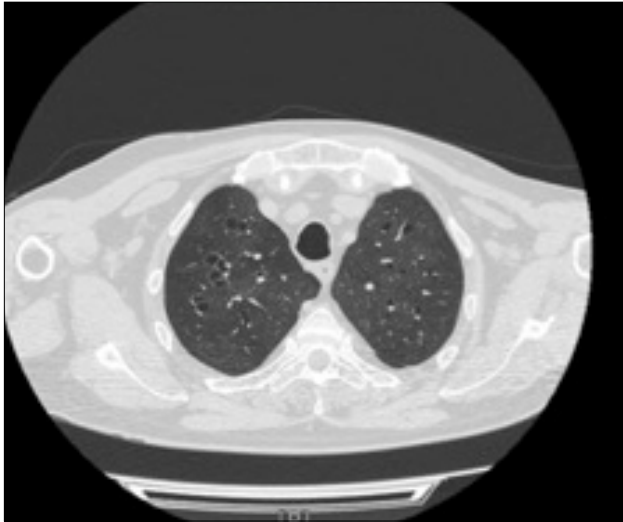


Figure 3. Case 2 HRCT

Case 2: 23 years old male patient working as bulding worker. He had 9 package years of cigarette smoking and he was an active smoker. He was admitted to our hospital with dysprea and cough complaints. His HRCT findings revealed cystic lesions typical for hystrocytosis X. FOB was performed. Endobronchial system was normal. BAL findings were also normal. ARB was negative in bronchial lavage examination. Culture was also negative for ARB. Bronchial lavage cytology was revealed no abnormality. Bronchial lavage culture was normal flora elements. In pulmonary function tests: FVC: 62%, FEV 1: 64% Both of our case were warned about cigarette smoking and are still under our clinical followup.

Conclusion: As a result; we should think about the diagnosis of Histiocytosis X for the cases with cigarette smoking and cytic lesions on CT evaluation.

Keywords: Cigarette, histiositozis x, cystic pulmonary disease

[Abstract:0583] PS-314 [Accepted:Poster Presentation] [Lung Transplantation]

Post-Transplant Lymphoproliferative Disease after Lung Transplantation

Sinan Türkkkan, Fatmanur Çelik Başaran, Mahmut Subaşı, Alkın Yazıcıoğlu, Mehmet Furkan Şahin, Ahmet Güngör, Erdal Yekeler

Department of Thoracic Surgery and Lung Transplantation, Health Sciences University, Turkey High Specializaiton Training and Research Hospital, Ankara, Turkey

Introduction: Post-Transplant Lymphoproliferative Disease (PTLD) is caused by the re-activation of latent EBV (Ebstein-Barr Virus) infection due to immunosuppression following solid organ transplantation (SOT) . We presented a PTLD case that was incidentally detected in our asymptomatic Lung Transplantation (LT) patient.

Case Presentation: Right single LT was performed in a 30-year-old male patient with the diagnosis of Silicosis. Following basiliximab induction, a triple immunosuppression consisting of Tacrolimus+mycophenolate mofetil (MMF)+Prednisolone was initiated. The patient who needed ECMO support due to primary graft dysfunction (PGD) in the post-op period was discharged on the 61st day. The symptoms of the patient who was admitted to the clinic several times with diarrhea, nausea

and vomiting attacks recovered with the cessation of immunosuppressive treatment and with symptomatic treatment; no microbiological factors were detected. Two nodular lesions were observed in the right upper lobe in CT taken for routine control in the 12th month. No rejection was detected in the transbronchial biopsy, but the nodule was not diagnostic in terms of its nature. Hyperplasia similar to the infectious mononucleosis (IMN), which is among the early PTLD lesions, was reported in the transthoracic biopsy. EBER (EBV encoded RNA) (+) and HHV-8 (-) were detected in pathological samples. Concurrently, EBV PCR (-) and EBNA (Ebstein-Barr Nuclear Antigen) (+) were found in the blood. The patient with no other involvements in PET-CT and cranial examinations was considered suitable for the follow-up with immunosuppression modification in the 13th month. The dose of tacrolimus and prednisolone was reduced and Everolimus was added to the treatment;

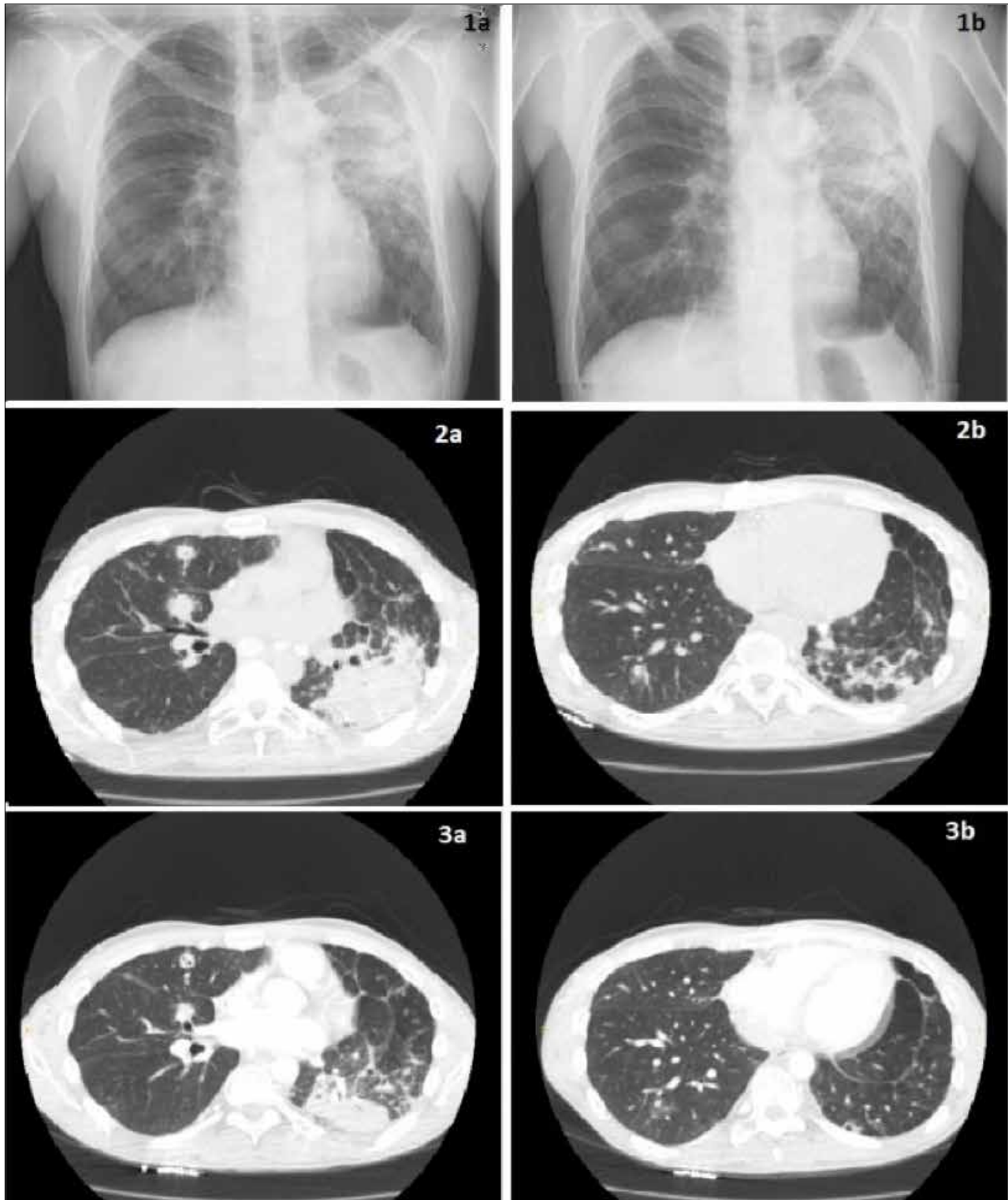


Figure 1. 1a) Direct graph at diagnosis 1b) Direct graph 3 months after diagnosis 2a,2b) CT at diagnosis 3a,3b) a decrease of 2-5 mm in sizes of lesions in CT 3 months after diagnosis

MMF was discontinued. It was observed that the nodule diameters decreased in control CT in the 15th month. The follow-up of the patient continues in the 4th month after the diagnosis and in the 16th month after LT.

Conclusion: PTLD is caused by the malignant transformation of lymphocytes resulting from EBV reactivation with the effect of immunosuppression. Post-transplant lymphomas are called as PTLD and can be seen in a wide range of pathologic types between EMN-like hyperplasia and Malignant Non-Hodgkin's Lymphoma. The frequency of immunosuppression administered at the highest dose is between 5-15% after LT among solid organ transplantations. It is responsible for 50% of the malignancies seen in the first year after LT. While the PTLD seen in the first year is usually limited to the thorax, those seen after 1 year may be abdominal or pelvic involvements. The main symptoms are fever, sweating, loss of appetite and weight-loss, though it changes depending on the area of involvement. The diagnosis is pathologic and the prevalence should be determined with PET and cranial MRI. EBV-DNA PCR and CMV PCR are used to determine viral load in patients. Discontinuation of MMF and azathioprine in early thoracic cases and the reduction of cyclosporine and tacrolimus may be sufficient for treatment. In some cases, resection, RT, CT (CHOP and Rituximab) or their combination may be required. Those which are seen early in the postoperative period have better prognosis. Although survival has been reported to be 1-3 years, publications indicate that there is no difference in LT in terms of survival when compared with other cases. The fact that the case was detected in early stage, limited to the thorax and without symptoms reveals once again the importance of intermittent routine CT control and follow-up of the therapeutic dose of immunosuppressive drug level.

Keywords: Lung transplantation, EBER, EBNA, EBV, malignancy, PTLD

[Abstract:0585] SS-011 [Accepted:Oral Presentation] [Clinical Problems - Diffuse Parenchymal Lung Disease]

Do CD4, CD8 and CD103 T Lymphocytes in Mediastinal Lymph Node Specimens in Sarcoidosis Have Diagnostic Value?

Soner Umut Kuver¹, Fatma Tokgöz Akyıl², Selahattin Öztaş¹, Baran Gündoğuş¹, Meltem Çoban Ağca¹, Tülin Sevim¹, Nurcan Çetin³

¹Department of Pulmonology, Health Sciences University İstanbul Süreyyapaşa Training and Research Hospital for Chest Diseases and Thoracic Surgery, İstanbul, Turkey

²Department of Pulmonology, Çanakkale State Hospital, Çanakkale, Turkey

³Clinical Biochemistry, Düzen Biochemistry Laboratories, İstanbul, Turkey

Objectives: The aim of this study was to investigate the diagnostic value of CD4+, CD8+, and CD103+ lymphocyte subgroups as adjunct markers for sarcoidosis by using flow cytometric analyses of lymph node samples.

Methods: The study was a single-center, prospective cohort study. Between January and September 2017, patients with differential diagnoses of sarcoidosis and non-sarcoidosis based on endobronchial ultrasound were included in the study. Different lymphocyte subsets were counted and compared.

Results: The final diagnoses based on clinical and histopathological findings were sarcoidosis in 31 (67%) out of 46 patients and non-sarcoidosis in 15 (33%) patients. Cell numbers and lymphocyte ratios were similar in both patient groups while CD4+ T lymphocyte rates were higher in sarcoidosis patients ($p=0.017$). CD8+ T lymphocyte percentages and CD4/CD8 ratios were similar between the two groups ($p>0.05$). In sarcoidosis patients, CD103+CD4+ and CD103+CD8+ lymphocyte percentages were lower ($p=0.008$ and $p=0.048$, respectively). The CD103+CD4+/CD4+ ratio was lower in sarcoidosis patients ($p=0.014$).

Conclusion: Cytological examination of lymph node material provided important clues to the differential sarcoidosis diagnosis. Although the number of CD4+ lymphocyte cells in sarcoidosis patients was higher than in non-sarcoidosis patients, the contribution of the CD4/CD8 ratio to the diagnosis is limited. Low CD103+CD4+ and CD103+CD8+ T lymphocytes were found to be predictors of sarcoidosis.

Keywords: CD103, endobronchial ultrasound, sarcoidosis

[Abstract:0586] EPS-078 [Accepted: E-Poster] [Lung and Pleura Malignancies]

Closed Pleura Needle Biopsy Results Our Patients

Gonca Öcal¹, Maung Thura Tun¹, Züleyha Bingöl¹, Dilek Yılmazbayhan², Mustafa Erelel¹, Turhan Ece¹, Esen Kıyan¹, Gülfer Okumuş¹, Zeki Kılıçaslan¹

¹Department of Pulmonary Medicine, İstanbul University İstanbul School of Medicine, İstanbul, Turkey

²Department of Pathology, İstanbul University İstanbul School of Medicine, İstanbul, Turkey

Objectives: Closed pleura needle biopsy (C-PNB) is a diagnostic method which is cheap and can be performed easily in bedside without anesthesia to the patients with pleural effusion. The diagnostic skill of C-PNB is generally reported as 40-50% in literature. However, this diagnostic method has been less applied for the last few years. In this study, we evaluated the results of C-PNB which were performed in our clinic for the last 5 years.

Methods: The pleural biopsies performed at İstanbul School of Medicine, Department of Pulmonary Medicine between 2013 and 2018 were reviewed.

Results: Totally 33 patients were performed C-PNB in 5 years. Exudative pleura effusion was present in all cases. All patients underwent C-PNB with ultrasonography by Abrams needle using local anesthesia. When we evaluated the pathological results, 16 (48.5%) patients had specific diagnosis. Eight patients (24%) with necrotizing granulomatous inflammation, 1 patient with non-necrotizing granulomatous inflammation were detected. Totally 7 patients (21%) were diagnosed with malignancy (3 adenocarcinoma, 1 epitheloid type mesothelioma, 1 renal cell tumor metastasis, 1 lung carcinoma, 1 breast carcinoma metastasis). The procedure was non-diagnostic in 17 patients (51%). Complication was seen in 1 patient who had pneumothorax and tube thoracostomy was applied to the patient.

Conclusion: The place of C-PNB should be preserved in cases of tuberculous pleurisy. Beside this, the useability of C-PNB which is less invasive procedure than surgery should not be forgotten in cases of malignancy with extensive pleura involvement.

Keywords: Malign effusion, pleura biopsy, tuberculous pleurisy

[Abstract:0587] EPS-033 [Accepted: E-Poster] [Clinical Problems - Diffuse Parenchymal Lung Disease]

Evaluation of The Side Effects of Antifibrinolytic Treatment in UIP Cases in The Center of Süreyyapaşa Chest Diseases and Chest Surgery Hospital

Armağan Fatma Hazar, Hatice Türker, Ayşem Aşkın Öztin, Sibel Boğa, Murat Kavas, Lale Sertçelik, İpek Erdem, Baran Gündoğmuş, Sümeyye Alpaşlanbekir, Özlem Soğukpınar

Health Sciences University, İstanbul Süreyyapaşa Training and Research Hospital for Chest Diseases and Thoracic Surgery, İstanbul, Turkey

Objectives: Diffuse Interstitial Fibrosis is an entity that develops over years after the onset and leads to respiratory insufficiency at the end. It is characterised by dyspnea, shortened walking distance, inability to perform daily activities even inside the home, hypoxia, sometimes hypercopia. This disorder affects the daily life of patients making life difficult. Today, there is no accurate treatment available for UIP. Bronchodilators, antifibrinolytic agents and lung transplantation are the treatment modalities considered for these cases. Antifibrinolytic agents (pirfenidone and nintedanib) are thought to stabilize the disease. We aimed to share the side effects of antifibrinolytic agents used in our center.

Methods: 20 of our patients were male and 8 were female. 24 of them were started pirfenidone while 3 were nintedanib. The patient with longest use was at 2 years follow up.

Results: Side effects were seen in 7 of our patients. All of them were using pirfenidone. Excluding one of them (who had a relatively tolerable side effect) treatment was stopped. In one of these patients; nintedanib treatment was started. Side effects

were hypertension crisis in 2 patients, serious photosensitivity in 1 patient (though the use of sunprotective cream) , acute attack of chronic obstructive pulmonary disease in 1 patient, general malaise and excessive fatigue in 2 patients, maculopapular rash and diarrhea in 1 patient. All these complaints were regressed after the termination of medication and restarted after retreatment with the same agent. Treatment was not terminated in the patient who had photosensitivity side effect. 21 patients were still under antifibrinolytic treatment and followed up in our centre.

Conclusion: Finally; Antifibrinolytic treatment is seem to be an alternative before lung transplantation in IPF cases. Patients who are eligible for treatment should be carefully monitored for side effects of the drugs.

Keywords: UIP, antifibrinolytic treatment, side effects

[Abstract:0589] EPS-155 [Accepted: E-Poster] [Respiratory Infections]

Hydatid Cyst Mimicking Lung Carcinoma

Yıldız Atlı¹, Burcu Yalçın¹, Atilla Can²

¹Department of Chest Diseases, Konya Training and Research Hospital, Konya, Turkey

²Department of Thoracic Surgery, Konya Training and Research Hospital, Konya, Turkey

Introduction: Hydatid cyst is a parasitic disease created by the larvae of *Echinococcus granulosus*. The lungs are the second most commonly involved organ after the liver. Hydatid cyst disease still poses a major problem in endemic areas. Of the cases, 30-50% are asymptomatic and incidentally diagnosed radiologically. The hydatid cyst of the lung may appear similar

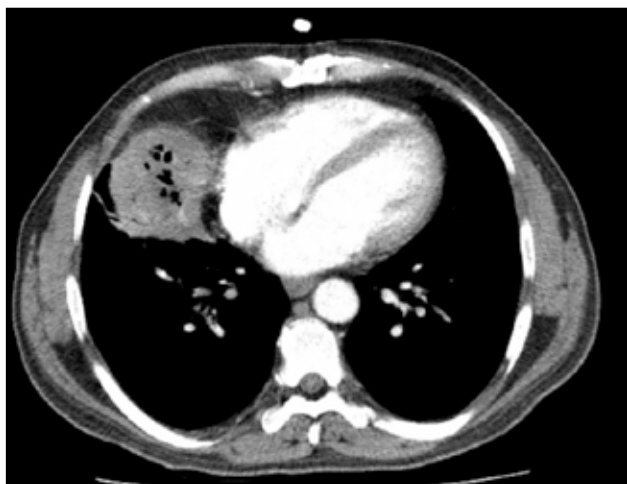

Figure 1. Thorax CT

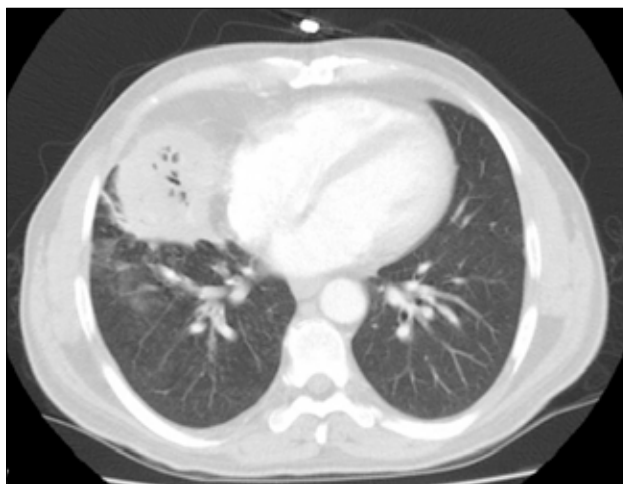

Figure 3. Thorax CT

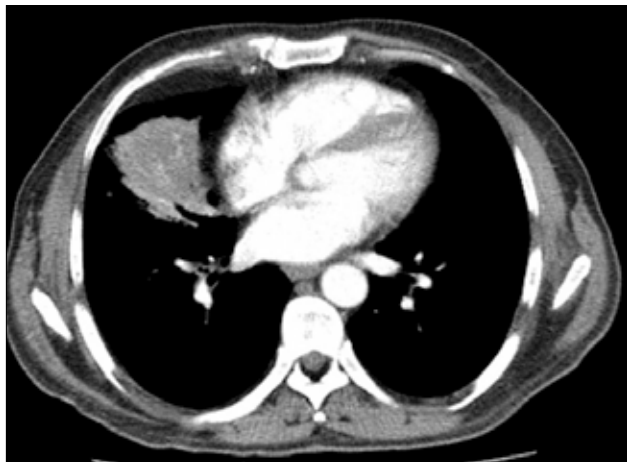

Figure 2. Thorax CT

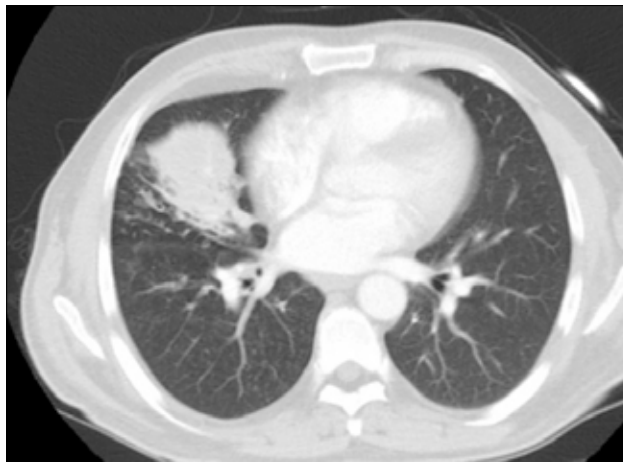

Figure 4. Thorax CT

to malignant diseases such as lung cancer as well as infectious benign diseases such as tuberculosis. Ruptured hydatid cysts may exhibit different radiological findings. Radiologically, it should be known that the hydatid cyst of the lung may mimic many lung pathologies, malignancies being in the first place. Even though clinical and radiological findings suggest lung cancer in countries like ours in which hydatid cyst, a parasitic disease, is common, complicated or ruptured hydatid cysts should always be considered in differential diagnosis. Therefore, we aimed to present a case interpreted as lung cancer in the thoracic computerized tomography (CT) and PET CT, however, diagnosed as the ruptured hydatid cyst of the lung.

Case Presentation: Our case is a 55-year-old male. He was admitted to an external clinic with the complaints of chronic cough, expectorating. He was referred to our hospital with the prediagnosis of lung cancer. Nothing relevant was detected in his past medical history or family history. His physical examination was normal. Leukocyte count was 11.4 cells/ μ L, crp was 3 mg/dL. The thoracic CT obtained in the external clinic due to non-regressing radiological pathologies despite antibiotic treatment revealed irregular a non-homogeneous increased density with irregular contours in the posterior segment of the lower lobe of the right lung. The report of the CT was written again upon consulting with the radiology department. A mass lesion with a lobulated contour measuring 7x8 cm in size and which was in favor of hydatid cyst was detected in the dome of the right lobe of the liver and an invasion was noted in the right diaphragm. Cystotomy and capitonnage were performed by the thoracic surgery and general surgery departments.

Conclusion: It should be kept in mind that the hydatid cyst of the lung may mimic many lung pathologies, malignancies being in the first place, and should be considered in differential diagnosis, especially in endemic regions.

Keywords: Hydatid cyst, lung cancer, thorax CT

[Abstract:0592] PS-029 [Accepted:Poster Presentation] [Clinical Problems - Diffuse Parenchymal Lung Disease]

Progesterone Induced Acute Eosinophilic Pneumonia

Biray Harbiyeli, Bahar Ulubaş

Department of Chest Diseases, Mersin University School of Medicine, Mersin, Turkey

Drug-induced pulmonary disease can emerge secondary to the direct toxic effect of the substance itself or due to drug triggered inflammatory reaction. We report the case of a 35-year-old female who was admitted to our emergency service complaining of sudden shortness of breath and dry cough. The treatment administered for infertility (Progesterone 100 mg/day, intramuscular) was stopped 3 days before the event. There was no other chronic disease or smoking in her medical history. Vital signs: temperature 36,8°C, pulse rate 125/min, arterial blood pressure 120/88 mmHg, respiratory rate 22/min. Physical examination was normal except bilateral pulmonary rales. Oxygen saturation on room air was 86%. Laboratory tests revealed leukocytosis (WBC: 19330/ μ L), eosinophilia (22%) and elevated C-reactive protein level (103 mg/L). Bilateral infiltrations were detected on chest X-ray. Consequently, thoracic computed tomography scan was performed, revealing predominantly peripheral-subpleural, symmetrical focal frosted glass like consolidations, more pronounced in the lower lobes and bilateral minimal pleural effusions. Echocardiography findings were normal. Progesterone related acute eosinophilic pneumonia was considered primarily in the preliminary diagnosis. Bronchoalveolar lavage was not performed because of hypoxia, tachycardia and poor general condition of the patient. The patient was unable to expectorate, so eosinophil count could not be measured in sputum. Atypical cells were not detected in the peripheral blood smear. We initiated intravenous methylprednisolone at a dose of 100 mg/day and rapid clinical improvement was observed immediately. Number of eosinophils was normal in the blood tests on the 3rd day after treatment. Bilateral infiltrations completely disappeared on chest X-ray. The oxygen saturation on room air increased to 97-99%. Methylprednisolone therapy

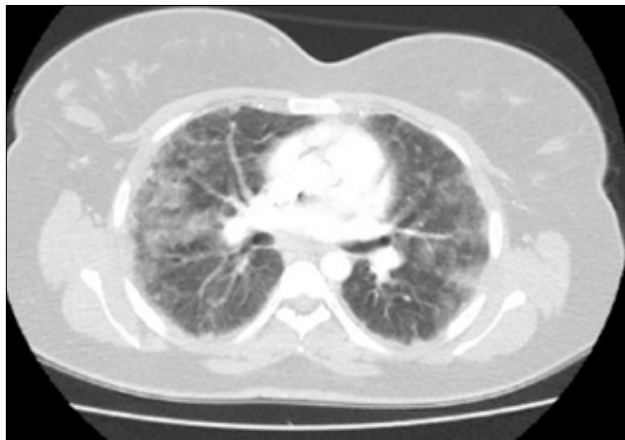


Figure 1. Thoracic Computed Tomography Image of the Case
Thoracic computed tomography scan revealed predominantly peripheral – subpleural, symmetrical focal frosted glass like consolidations.

was continued with decreasing doses. FVC was 2.05 lt 75%, FEV1 was 1.85 lt 90% and FEV1/FVC 90% after 7 days of treatment. Also chest X-ray and blood tests were normal. Oral treatment was administered after seven days of intravenous methylprednisolone therapy and the patient discharged.

Rapid response to systemic steroid therapy may be observed in cases with drug induced eosinophilic pneumonia.

Keywords: Acute eosinophilic pneumonia, methylprednisolone, progesterone

[Abstract:0593] PS-174 [Accepted:Poster Presentation] [Tuberculosis]

The Knowledge and Attitudes of Hospital Staff about Tuberculosis

Serap Argun Barış, Ersin Alkılınç, Elif Karasal, Haşim Boyacı, İllknur Başığit

Department of Pulmonary Disease, Kocaeli University School of Medicine, Kocaeli, Turkey

Objectives: Despite prevention strategies, tuberculosis is still a common disease in our country and people are prejudiced in this regard because of its contagious nature. The aim of this study is to evaluate the knowledge level and attitudes of the individuals working in our hospital about tuberculosis.

Methods: A questionnaire including questions evaluating information and attitudes about tuberculosis was applied to all voluntary individuals who work in Kocaeli University School of Medicine Hospital.

Results: There were 81 (63.3%) female and 47 (36.7%) male, totally 128 individuals were included. It was well known that tuberculosis is a treatable disease that affects lungs and extra-pulmonary organs, transmitted by droplet infection and its notification is mandatory. However, 51.6% of the cases reported that the contagiousness decreased with the treatment. In addition, approximately 37% of the cases thought that tuberculosis could be transmitted through contact or blood. The most common source of information about tuberculosis was physician informing (72.7%) and hospital education (68%) . There was no difference between genders regarding of knowledge level about tuberculosis. Approximately 60% of participants who has a level of education below high school were stated that tuberculosis may be transmitted by contacting with tuberculosis patients and/or by using the same objects used by patients. The percentage of hospital education about tuberculosis in these participants was significantly low (47.6% vs. 72%, $p=0.03$) . When we classify participants as health-care workers (research assistant, nurse, trainee) and non-medical staff (secretary, staff, administrative staff) ; tuberculosis complaints were found to be better known among health professionals. Approximately 55% of non-medical staff stated that tuberculosis may be transmitted by contacting patients with tuberculosis and/or by using the same objects used by patients, tuberculosis transmission routes are not well known. After contact with patients with tuberculosis, it was found that non-medical staff have more concern about the possibility of transmission of the disease to themselves and/or their family members ($p=0.006$, $p=0.001$) , need for wearing a mask ($p=0.006$), need for referral to a pulmonologist ($p=0.001$) and necessity of using preventive medication ($p=0.001$) .

Conclusion: Tuberculosis is still an important public health problem in our country. There is prejudice about tuberculosis even among health-care workers who are expected to have information about the disease. Continuing education among hospital staff is important to ensure that these patients are not excluded from society.

Keywords: Attitude, hospital staff, knowledge, transmission, tuberculosis

[Abstract:0595] EPS-239 [Accepted: E-Poster] [Thoracic Surgery]

A Rare Case of Lung Tumor: Sclerosing Pneumocytoma

Anıl Gökçe¹, Merve Şatır¹, Aynur Baş¹, Anar Süleymanov¹, Ali Çelik¹, İsmail Cüneyt Kurul¹, Leyla Memiş²

¹Department of Thoracic Surgery, Gazi University School of Medicine, Ankara, Turkey

²Department of Pathology, Gazi University School of Medicine, Ankara, Turkey

Sclerosing pneumocytoma (SP) is a rare tumor of pulmonary parenchyma that is accepted as benign and was first described in 1956 by Liebow and Hubbell as 'sclerosing hemangioma'. This tumor is often asymptomatic, is detected incidentally and much more common in women. It is a solitary, peripheral and well-circumscribed nodule in the radiological image. Lymph node metastasis is quite rare. It is defined by WHO as "a tumor of pneumocyte origin, containing solid, papillary, sclerotic and haemorrhagic areas".

Our case is a 12-year-old child; about 6 months ago, he was operated due to a lesion that developed in the lip region, and the diagnosis was made as malignant melanoma. After a 3-mm nodule was seen in the left lung in thorax tomography taken during the controls, the patient was referred to our department, and wedge resection was performed. He was discharged on the postoperative third day without any complications.

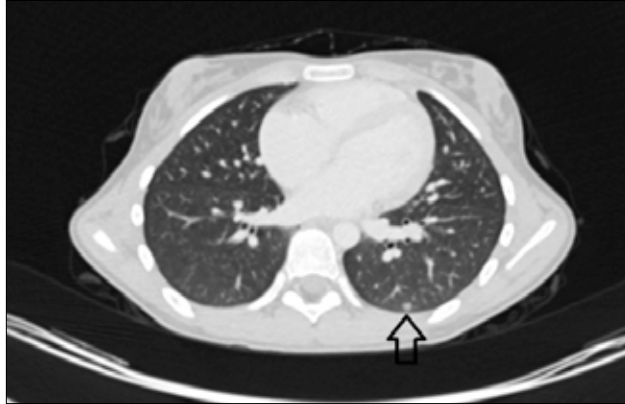


Figure 1.

The pathological result of the material taken was reported as sclerosing pneumocytoma. Of the patients, 80% are asymptomatic, as in our case. Hemoptysis, cough and chest pain are the most common symptoms. It is usually found in the form of a well-circumscribed nodule located in the lower lobes. It is mostly peripherally localized. They are seen as a mass lesion which is well-circumscribed, and which shows homogeneous or heterogeneous contrast enhancement in CT. They are macroscopically well-circumscribed and non-capsular tumors. The treatment is surgical. While segmentectomy, "wedge" resection and lobectomy are recommended, lymph node dissection is still not recommended. Its prognosis is good, and recurrence is not observed.

Keywords: Sclerosing, pneumocytoma, rare

[Abstract:0597] EPS-147 [Accepted: E-Poster] [Respiratory Infections]

Fungal Infection in Immune-Competent Patients

Neslihan Köse, Dilek Ernam, Ülkü Aka Aktürk, Özlem Makbule Akbay, Erhan Oğur

Department of Chest Diseases, Süreyyapaşa Chest Diseases And Chest Surgery Training and Research Hospital, İstanbul, Turkey

Introduction: Coccidioimikosis is a systemic infection caused by *coccidioides immitis*. It is the cause of outbreaks resulted by earthquakes, storms and outdoor hobbies (poultry farming) where contact with soil increases. Direct human-to-human transmission is not usually seen. Clinical pictures that appear with influenza-like findings ranging from acute pulmonary infection to chronic pulmonary infection can be observed. Main symptoms are fever, chest pain, fatigue, and coughing, myogenic pain and weight loss. In the first few days of the symptomatic period, erythematous in the chest, arm and leg regions and maculopapular rash can be seen. In order for diagnosis, sputum, bronchoalveolar lavage fluid (BALF), tissue biopsies and blood samples might be taken. Observing reproduction in fungal culture is definitive diagnosis. Although this disease can heal spontaneously, it can also turn into a situation that affects several systems among immunosuppressed patients.

Case Presentation: A 26-year-old male patient presents to the hospital complaining of sudden onset of cold-chill, fatigue, fever reaching a high of 40°C. The patient expresses that during the high fever, rash in extremities is observed. Chest X-ray shows bilateral asymmetric consolidation and nonspecific-antibiotic treatment is given for the preliminary diagnosis of pneumonia. Computed tomography (CT) reveals bilateral asymmetric consolidations with spicules with rounded apophysis that is accompanied by ground glass densities and without air bronchograms. The hospital requires "Positron Emission Tomography (PET-CT)" for the preliminary diagnosis of lung metastases. The general condition of the patient presenting himself to our clinic was determined as moderate with the fever of 36.5°C and 95% room air saturation. Respiratory sounds were detected as normal. In his history, it was learned that the patient used to work as a religious leader (imam), was not on any medical treatment, had no other illnesses, was living in a village and engaged in poultry farming. His chest X-ray revealed increased infiltration. His complete blood count showed that leukocyte was 6600, hemoglobin was 14.2, and platelet was 218,000. In

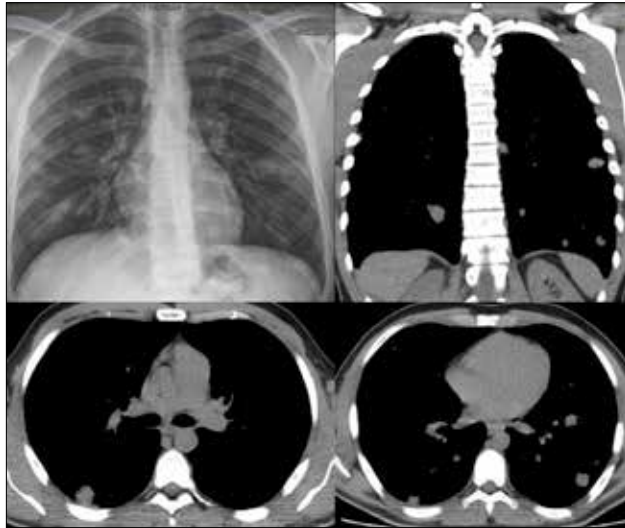


Figure 1. Lung radiography and thoracic CT images at admission

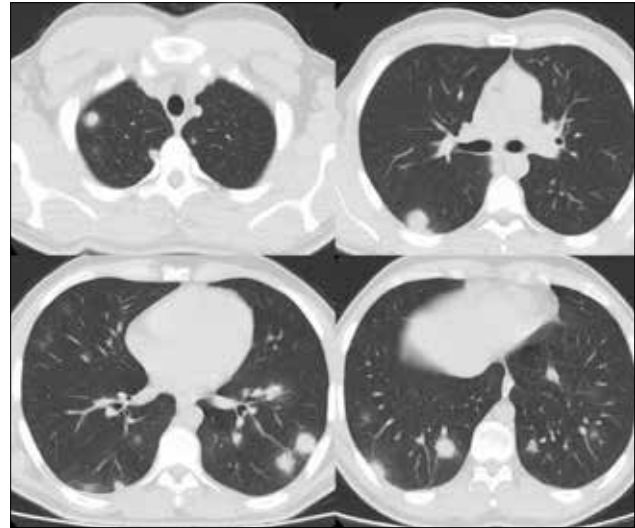


Figure 2. Thoracic CT images at admission

Table 1. Fungal infection according to host

HEALTHY HOST	HEALTHY HOST WITH IMMUNE INSUFFICIENCY	HOST WITH IMMUNE INSUFFICIENCY
<i>Histoplasma capsulatum</i>	<i>Aspergillus</i> spp.	<i>Candida</i> spp.
<i>Blastomyces dermatitidis</i>	<i>Cryptococcus neoformans</i>	Zygomycetes
<i>Coccidioides immitis</i>	<i>Sporothrix schenckii</i>	<i>Trichosporon</i> spp.
<i>Paracoccidioides brasiliensis</i>	<i>Penicillium marneffeii</i>	<i>Fusarium</i> spp.
	<i>Geotrichum</i> spp.	<i>Penicillium</i> spp.
		<i>Hansenula</i> spp.
		<i>Mucor, Rhizopus and Absidia</i> genera (mucormycosis)
		<i>Pseudoallescheria boydii</i>
		<i>Pneumocystis jirovecii</i>

his biochemistry parameters ALP, ALT, GGT, LDH values were high, CRP was 49 and sedimentation was 30. PSA, B-HCG, AFP, ELISA values were negative. Bronchoscopy and bronchoalveolar lavage (BAL) were performed. There was no endobronchial lesion on the bronchoscope and all lobes and segments were clearly visible. Lavage ARB and galactomannan were negative. In the BAL fluid; 310 total cells, 28.1% live cells, 35% lymphocytes, 20% neutrophils, 43% macrophages, 2% eosinophils, CD4/CD8: 2.56% were detected. In the fungal culture performed during BAL fluid, reproduction consistent with *Coccidioides* was detected. Due to an acute onset of the clinical picture, poultry farming history and radiology and culture results, his lung lesions were determined as fungal infection and voriconazole treatment was started. In his control chest X-ray, regression was observed in the infiltrations and it was detected that the consolidations completely disappeared in the control thorax CT that was performed 2 months later. It was learned that another friend of his who was also engaged in poultry farming presented himself to a hospital with similar complaints and was followed up in the intensive care unit due to accompanying comorbidity.

Conclusion: It is important to keep in mind that fungal infections may occur in patients without immunosuppression because of the increased incidence of fungal infection. Detailed anamnesis and systematic approach should be considered prior to advanced noninvasive and invasive examinations.

Keywords: Coccidioides, fungal infection, contact with soil

[Abstract:0598] EPS-098 [Accepted: E-Poster] [Lung and Pleura Malignancies]

Rarely Cause of Ptosis: Central Horner Syndrome

Önder Öztürk¹, Hatice Çelik¹, Merve Pınar¹, Sema Bircan², Neslihan Merd³, Ahmet Akkaya¹

¹Department of Chest Diseases, Süleyman Demirel University School of Medicine, Isparta, Turkey

²Department of Pathology, Süleyman Demirel University School of Medicine, Isparta, Turkey

³Department of Radiology, Süleyman Demirel University School of Medicine, Isparta, Turkey

Intorduction: Horner syndrome is characterized by miosis, ptosis, facial anhidrosis and enopthalmus and is caused by a lesion along the oculosympathetic pathway starting from hypothalamus and ending in the eye. The most common preganglionic Horner syndrome is caused by the pathology of the lung apex. But central Horner syndrome is a very rare condition. We wanted to present our case in the context of the literature because of being an interesting case that originates from the right pulmonary hilar region and leads to rare central Horner syndrome.

Case Presentation: A 78-year-old male patient without a previously known chronic disease referred to our clinic with complaints of cough, purulent sputum production, progressive effort dyspnea and hemoptysis for the last 2 weeks. He had crepitan ralles at the base of right lung and unilateral ptosis. He had no smoking history. At laboratory; CRP: 4 mg/L, NE: %82.2, WBC: 9300 were found. At PA chest film; a heterogeneous increased density was observed at the right lower zone and confined to the oblique fissure (Figure 1) . At thorax CT; a hypodense lesion filling the azygous esophageal cavity and pushing the right pulmonry artery, pulmonary vein structures to supreior and obliterating right pulmonary artery, right lower bronchus totally was observed. There is a well-defined nodular appearance in the right middle lobe of the lung and irregularly contoured soft tissue mass invading the chest wall on the same side with mediastinal LAPs (Figure 2) . A vegetative mass obliterating the proximal portion of the right bronchus intermedius in the FOB examination. Eye and neurology consultation was requested with the reason of complaints of

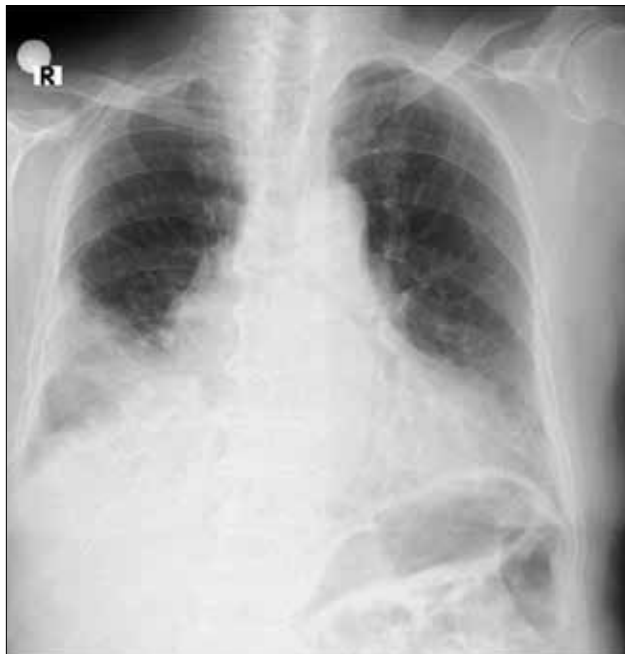

Figure 1. PA chest film;a heterogeneous increased density was observed at the right lower zone and confined to the oblique fissure.

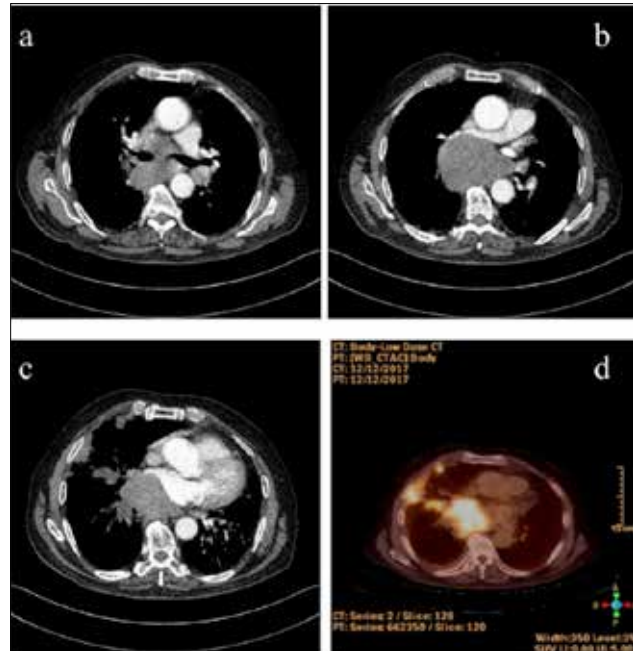


Figure 2. a-d. Thorax CT:a hypodense lesion filling the azygous esophageal cavity and pushing the right pulmonry artery, pulmonary vein structures to supreior and obliterating right pulmonary artery, right lower bronchus totally was observed. There is a well-defined nodular appearance in the right middle lobe of the lung and irregularly contoured soft tissue mass invading the chest wall on the same side. 2d: PET/CT view of the lesions.

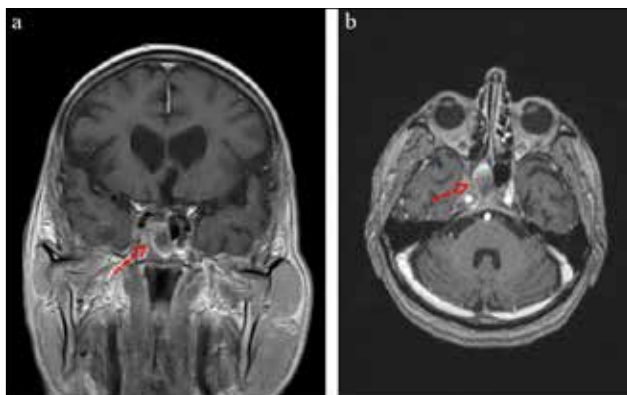


Figure 3. a, b. Cranial MR:revealed a hypointense mass lesion starting from the right petrous apex and obliterating the cavernous sinus totally, moving to left cavernous sinus and right orbital apex, infiltrating the 3rd, 4th, 5th, 6th cranial nerves.

droopy right eyelid for 2 months. Cranial MR revealed a hypointense mass lesion starting from the right petrous apex and obliterating the cavernous sinus totally, moving to left cavernous sinus and right orbital apex, infiltrating the 3rd, 4th, 5th, 6th cranial nerves (Figure 3) . Histopathological evaluation of the received biopsies was reported as small cell lung carcinoma. The patient, classified as an extensive stage, was directed to medical oncology and radiation oncology.

Conclusion: We want to share our case because of being educational with different location and histopathological type and having the first sign of ptosis. Horner's syndrome can be caused by malignant cervical or mediastinal mass lesions as well as by treatable benign causes. If there is any suspicion detailed follow-up studies might be life saving by early diagnosis and planning appropriate treatment.

Keywords: Horner syndrome, ptosis, lung cancer

[Abstract:0599] PS-218 [Accepted:Poster Presentation] [COPD]

Knowledge Level of Pharmacists and Pharmacy Staff in the Use of Inhaler Devices

Nevhiz Gündoğdu¹, Mete Sergen³, Umut Örs³, Metin Öztep³, Dicle Habeş³, Caner Akufuk³, Ahmet Avcı³, Büşra Kırmacı³, Fatma Nur Karakan³, Nazlı Neval Binici³, Oğuzhan Yener³, Ezgi Nur Korkmaz³, Halil İbrahim Ertem³, Osman Ildız³, Pınar Günel Karadeniz⁴, Zeynep Özlem Soran²

¹Department of Chest Diseases, Sanko University School of Medicine, Gaziantep, Turkey

²Heart and Vascular Institute, University of Pittsburgh, Pittsburgh, USA

³3rd Grade Student, Sanko University School of Medicine, Gaziantep, Turkey

⁴Department of Biostatistics, Sanko University School of Medicine, Gaziantep, Turkey

Objectives: There are approximately 300 million asthmatic patients worldwide and incidence of chronic obstructive pulmonary disease (COPD) is 15-20% in adults over 40 years. The proper use of inhaler devices has an important role in the effective treatment of asthma and COPD. In our country, the use of patient devices is often learned from pharmacists and pharmacy staff. Our aim was to evaluate the skills of pharmacist and pharmacy staff in Gaziantep.

Methods: 214 pharmacy staffs from various regions in Gaziantep were reached in February-May 2017, but 139 were admitted to participate in the study. The knowledge level of pharmacist and pharmacy staff about commonly used discus, inhaler capsules, turbuhaler, metered dose inhaler and elliptical devices were measured using the face to face survey method. The device applications step by step were evaluated via questionnaire forms prepared by us to work under the guideline of the "Inhaler Handling Guidelines for Aerosol Therapy Devices Guidebook 2nd Edition". Approval of the ethics committee required for the study was taken from SANKO University Clinical Research Ethics Committee. The data were evaluated using the "SPSS Statistics 23" program.

Results: The average age of participants was 30.84±10.02,33 persons were pharmacists, 37% were university graduates. Participants stated that they knew to use 97% discus, and 49% elliptical devices, the most easily described device was the inhaler capsule (39%) and the most difficult described device was the turbuhaler (33%) . 79 percent of participants were telling each patient how to use the device.Participants indicated that the most difficult age group to describe the use of the device was patients over 65. Of the participants, 122 participants from who said they knew about the use of discus and explained the use of discus, only 8 people; 112 participants from who said they knew about the use of turbuhaler and explained the use of turbuhaler, only 5 people; 95 participants from who said they knew about the use of inhaler capsule and explained the use of inhaler capsule, only 5 people; 96 participants from who said they knew about the use of metered dose inhaler and explained the use of metered dose inhaler, only 5 people; 32 participants from who said they knew about the use of ellipta and explained the use of ellipta, only 2 people described the whole of the steps.

Conclusion: The results of our study; pharmacists and pharmacy staffs; Although they know how to use inhaler devices except ellipta but they can't fully perform all the steps in practice. These results highlight the need for pharmacy staff to be trained in the use of inhaler devices

Keywords: Inhaler devices, education, pharmacy staff

[Abstract:0601] SS-046 [Accepted:Oral Presentation] [Sleep-related Disorders]

Obstructive Sleep Apnea Increases the Risk of Hemoptysis

Meral Uyar¹, Nazan Bayram², Selim Kervancıoğlu³

¹Sanko University, Department of Pulmonary Diseases, Gaziantep, Turkey

²Department of Pulmonary Diseases, Gaziantep University School of Medicine, Gaziantep, Turkey

³Department of Radiology, Gaziantep University School of Medicine, Gaziantep, Turkey

Objectives: Repeated respiratory events and hypoxia lead to endothelial damage and inflammation. Studies have shown that obstructive sleep apnea (OSA) may stimulate a state of hypercoagulability. In this study, we aimed to evaluate whether obstructive sleep apnea syndrome has a role in the etiology of haemoptysis.

Methods: Patients older than 18 years who underwent bronchial artery embolization for hemoptysis between 2009 and 2015 were included. Patients willing to participate in the study were interviewed in 2016 to evaluate the history and quantity of hemoptysis, relationship with sleep, sleep quality, probability of sleep apnea (Pittsburgh Sleep Quality Index, Berlin Sleep Questionnaire, STOP and STOP-BANG Questionnaires) .

Results: Fifty-three patients with hemoptysis who underwent embolization and 58 healthy, age and sex matched subjects were included in the study. The mean age of patients and control subjects was 46.94±14.36 years and 41.97±12 years, respectively (p>0.05) . The rate of massive hemoptysis was 67.6% (n=23) in males and 73.7% (n=14) in females (p=0.646) . No relationship was found between the timing of hemoptysis and sleep. High OSA risk was found in 24.5% (n=13) of hemoptysis cases and this rate was 8.6% in controls (n=5) (p=0.023) . When the cases were grouped according to the amount of hemoptysis, high OSA risk was 29.7% (n=11) in patients with massive hemoptysis, 12.5% (n=2) in non-massive hemoptysis and 8.6% (n=5) in the control group (p=0.022) . High OSA risk was found in 4 (44.4%) of 9 cases with idiopathic hemoptysis and in 20.5% (n=9) of those with a known underlying cause for hemoptysis (p=0.127) . Embolization procedure had to be repeated in 7 of 53 patients due to the recurrence of hemoptysis. High OSA risk was detected in 57.1% (n=4) of these patients and 19.6% (n=9) in the remaining patients (p=0.031) .

Conclusion: We found that high OSA risk was common in hemoptysis patients. OSA may be a causative factor in idiopathic hemoptysis. Unrecognized and untreated OSA may be effective in treatment failure in hemoptysis. This is the first study in the literature to investigate the relationship between hemoptysis and OSA. Our findings showed the necessity of evaluating OSA risk in hemoptysis patients. Endothelial dysfunction, increased vascular pressures, changes in the coagulation mechanism, intrathoracic pressure changes could be underlying processes in OSA associated with hemoptysis.

Keywords: Sleep apnea, hemoptysis, embolisation

[Abstract:0603] EPS-043 [Accepted: E-Poster] [Clinical Problems - Pulmonary Vascular Diseases]

Is Symptomatic Follow up Important after Acute Pulmonary Embolism?

Elif Şahutoğlu¹, Esin Tuncay², Esin Yentürk², Zehra Dilek Kanmaz², Gülfidan Aras², Firdevs Atabey²

¹Şanlıurfa Training and Research Hospital, Şanlıurfa, Turkey

²Yedikule Chest Disease and Chest Surgery Training and Research Hospital, İstanbul, Turkey

Objectives: The incidence of chronic thromboembolic pulmonary hypertension (CTEPH) following acute pulmonary embolism was investigated.

Methods: Patients who had persistent symptoms after at least 3 months of anticoagulation following acute pulmonary embolism were included. Patients with malignancy, groups 1, 2, 3 or 5 pulmonary hypertension, >80 years old or without symptoms (chest pain, exercise intolerance, dyspnea) of pulmonary hypertension were excluded. Patients with systolic pulmonary artery pressure of >40 mmHg after at least 3 months of effective anticoagulation and normal pulmonary capillary wedge pressure (PCWP) were diagnosed with CTEPH. Findings consistent with pulmonary embolism on pulmonary CT angiography and/or VQ scan at least 3 months following of at least 3 months of effective anticoagulation were considered as recurrent pulmonary embolism

Results: Mean age and follow up duration of the 30 eligible (F/M 17/13) patients out of 140 were 55.8 ± 11.4 years and 39.4 ± 21.5 months, respectively. The most common symptoms were dyspnea (90%), exercise intolerance (83%) and chest pain (53%). Mean SPAP was 28.7 ± 4.9 mmHg. VQ scan was normal in 12/29 (41%), low-probability in 7/29 (24%), intermediate-probability in 4/29 (13%), and high-probability in 6/29 (20%) patients. D-dimer was above cut-off in 2/25 patients. One patient (3.3%) (F, 66) was diagnosed with CTEPH (with SPAP of 40 mmHg). She had acute pulmonary embolism 21 months ago and the current VQ scan revealed intermediate-probability for PE and the Lupus anticoagulant test was positive. Vasoreactivity test was negative and thrombosis was not detected within the pulmonary arteries on right heart catheterization. Riociguat was prescribed because thromboendarterectomy was not considered suitable. Recurrent pulmonary embolism was seen in 30% of the patients (n=9, 5/4 F/M) and mean age was 59.6 ± 10.3 years. The diagnosis was made via VQ scan in 6 and CT pulmonary angiography in 3 patients. Mean SPAP was below 40 mmHg. In search for the etiology, heterozygote mutation in factor V Leiden was found in 2, protein S deficiency in 1, hyperhomocysteinemia in 1 and mutation in MTHFR gene in 1 patients.

Conclusion: New onset of symptoms in patients after or under treatment should be evaluated for recurrent PE or CTEPH and D-dimer, echocardiography (right heart catheterization in cases with PHT), CT angiography and/or VQ scan will help to reduce delayed detection and misdiagnosis. The only definitive treatment for CTEPH is thromboendarterectomy, therefore referral of the patients to experienced centers for surgical assessment is of critical importance.

Keywords: CTEPH, pulmonary embolism, pulmonary hypertension

Table 1. Baseline characteristics of the cohort

	All patients
Age (year)	55.8 ± 11.4
Gender (F/M)	17/13
Number of comorbidities (n, %)	
None	12/30 (40%)
1 comorbidity	4/30 (13.3%)
≥2 comorbidities	4/30 (13.3%)
Risk factors for VTE (n, %)	
Surgery	5/30 (16.6%)
Immobility	7/30 (23.3%)
Malignancy	1/30 (3.3%)
Hypercoagulability	5/30 (16.6%)
Deep vein thrombosis (n, %)	6/24 (25%)
Treatment for PE	
Warfarin	26/30 (86.6%)
LMWH	3/30 (10%)
NOAC	1/30 (3.3%)
Duration of anticoagulant treatment (month)	7.7 ± 5.1
VTE, venous thromboembolism; PE, pulmonary embolism; LMWH, low molecular weight heparin; NOAC, non-vitamin K oral anticoagulant.	

Table 2. Assessment of symptoms, cardiac and pulmonary status on the last visits

	All patients (n=30)
Symptoms	
Dyspnea (n, %)	27/30 (90%)
Chest pain (n, %)	16/30 (53.3%)
Exercise intolerance (n, %)	25/30 (83.3%)
Echocardiography	
SPAB (mmHg)	28.7 ± 4.9
TAPSE (mm)	22.2 ± 4.0
Tricuspid regurgitation	
Minimal	23/30 (76%)
Mild	7/30 (23%)
LV-EF (%)	58.6 ± 4.3
V/Q scintigraphy	
Normal	12/29 (41%)
Low-probability	7/29 (24%)
Intermediate-probability	4/29 (13%)
High-probability	6/29 (20%)
6-MWT	
Walked distance (m)	421.7 ± 90.2

[Abstract:0604] PS-150 [Accepted:Poster Presentation] [Clinic Problems - Others]

Fat Embolism

Şaban Melih Şimşek, Deniz Kızılırmak, Pınar Çelik, Yavuz Havlucu, Tuğba Göktaş

Department of Chest Diseases, Celal Bayar University School of Medicine, Manisa, Turkey

Introduction: Fat embolism was first detected in 1862 by Zenker during an autopsy. Clinically, fat embolism syndrome was first described by VonBergmann in 1873. Fat embolism is seen in every patient who experienced a long bone fracture. However, in small number of cases, fat embolism develops accompanied with lung and cranial involvement and skin lesions within 24-72 hours. Clinically, loss of brain and lung function, petechial rash of skin are observed. Diagnosis is difficult, but imaging methods facilitate to diagnose. In high-risk patients, early follow-up of oxygen saturation (SpO₂) leads to early diagnosis.

Case Presentation: A 22-year-old male patient who had a femur fracture due to a car accident presented himself to us after an orthopedic clinic follow-up because of low level of SpO₂. During his physical examination, his respiratory sounds were normal, no skin lesions were present but isolated warts were observed in the conjunctiva. His chest X-ray and computed tomography (CT) was normal. SpO₂ in room air was %78 but fat embolism was detected in his cranial CT and MR upon observing a tendency to sleep. Upon the detection of multiple lesions in the form of cotton waste on his follow-up chest X-rays, bilateral infiltrations compatible with fat embolism were detected on his second CT. 40 mg of intravenous Prednol, oxygen support, SpO₂ and chest X-ray were recommended. On the third day of treatment, regression was observed on his control graphs. Hypoxia was not observed on room air arterial blood gas.

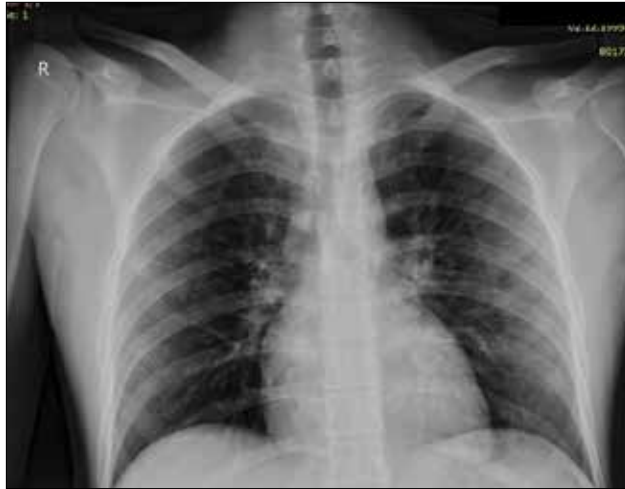

Figure 1. Lung radiography. 3rd day of treatment

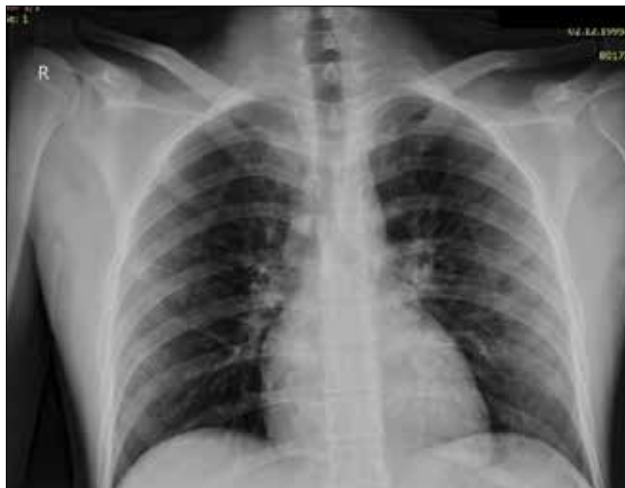

Figure 2. Lung radiography. Hospitalization

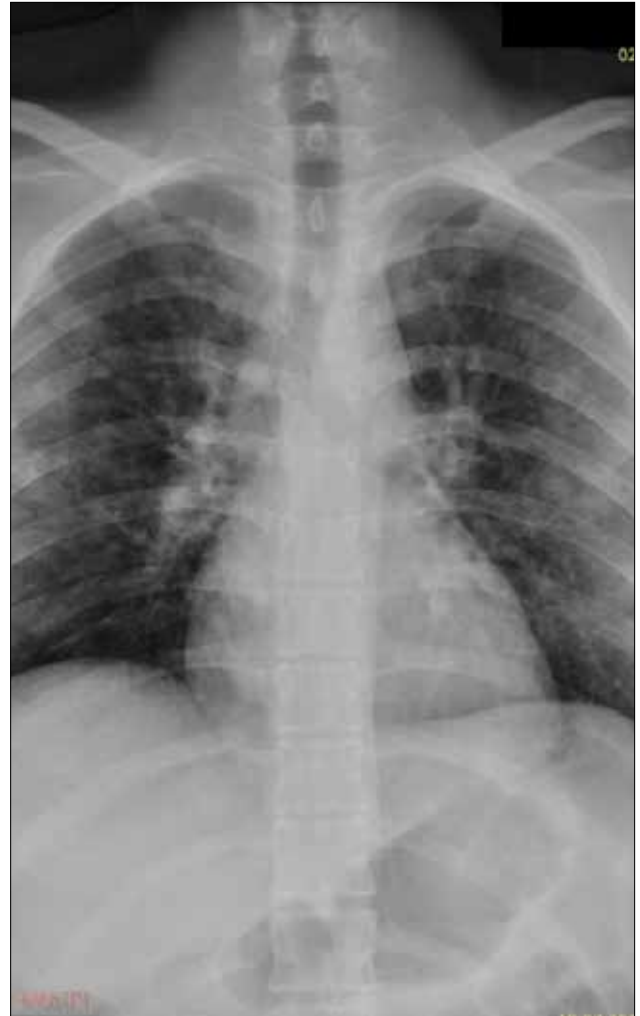

Figure 3. Lung radiography 2. Control radiography after respiratory symptoms

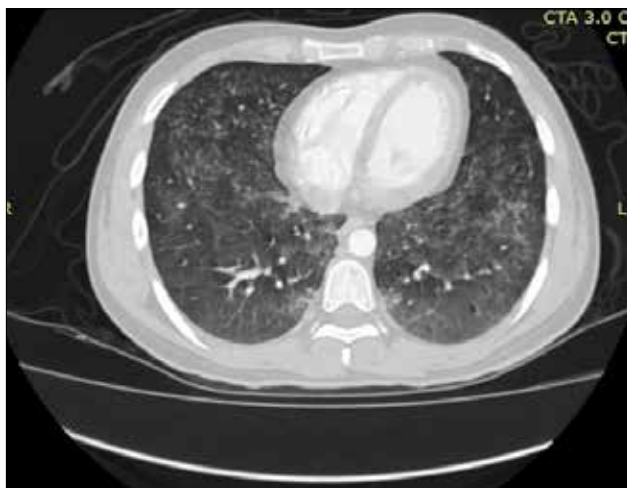

Figure 4. Thoracic CT

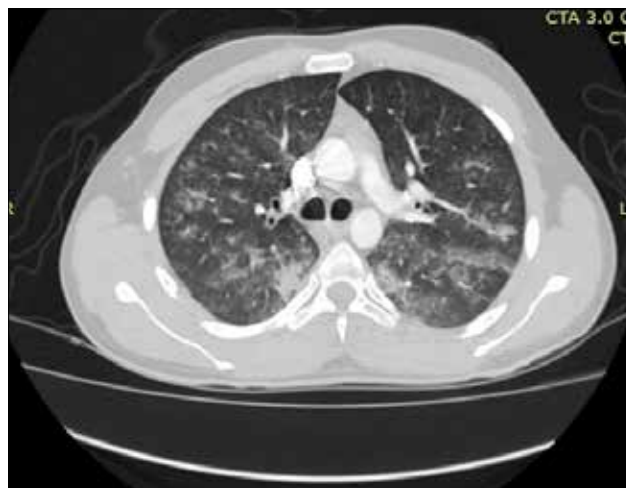

Figure 5. Thoracic CT

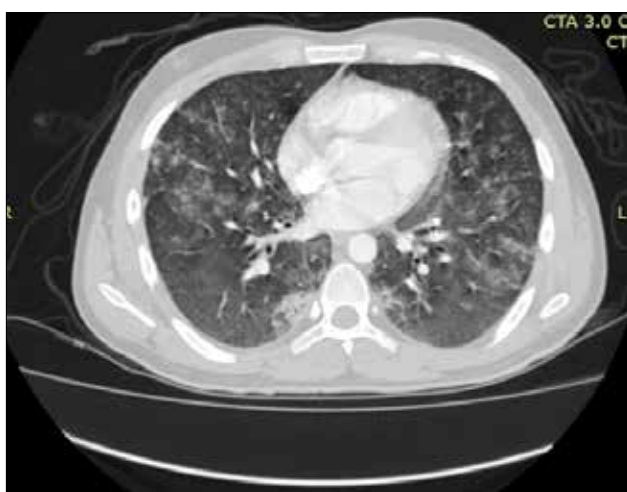

Figure 6. Thoracic CT

Conclusion: The most significant difference of fat embolism is that it causes systemic embolisms since the embolism passes into the pulmonary vein through pulmonic capillary bed. While in 75% of the patients experience dyspnea, tachypnea and venous symptoms, respiratory failure may develop in 10% of the cases. In 86% of the patients, some neurological findings such as confusion, seizures, brain edema and coma may occur. In 20-50 % of the cases within the 24th-72nd hours skin lesions in the form of non-palpable warts may appear and disappear at the end of the first week. As a result, it should be noted that in high risk patients fat embolism can be diagnosed at an early stage by clinical examination support, saturation follow-up and radiological findings.

Keywords: Fat, embolism, trauma, desaturation

[Abstract:0610] SS-130 [Accepted:Oral Presentation] [Pulmonary Rehabilitation and Chronic Care]

Comparison of Cardiopulmonary Exercise Test Parameters, Pulmonary Function and Quality of Life in Patients with Non-Small Cell Lung Cancer and Healthy Subjects

Zeynep Pelin Dündar¹, Meral Boşnak Güçlü², Aydın Çiltaş³, Mustafa Benekli⁴

¹Department of Physiotherapy and Rehabilitation, Necmettin Erbakan University Faculty of Health Sciences, Konya, Turkey

²Department of Physiotherapy and Rehabilitation, Gazi University Faculty of Health Sciences, Ankara, Turkey

³Department of Oncology, Gazi University School of Medicine Hospital, Ankara, Turkey

⁴Private Clinic, Çukurambar, Ankara, Turkey

Objectives: Many patients with non-small lung cancer (NSCLC) are deconditioned with poor physical fitness. Remission therapy administered in non-small cell lung cancer patients has negative effects on maximal exercise capacity, respiratory function and quality of life. Cardiopulmonary exercise testing (CPET) is the gold standard evaluation method of exercise capacity. However, there is a few study investigated maximal exercise capacity using CPET in patients with non-small lung cancer and compared with healthy subjects. The aim of this study was to compare cardiopulmonary exercise test parameters, pulmonary functions and quality of life patients with NSCLC and healthy subjects.

Methods: Eighteen curative intent treatment for NSCLC patients (63.61±5.65 y, 2F/16M) and 16 healthy subjects (59.93±6.69 y, 2F/14M) were compared. Demographics were recorded. Peak oxygen uptake (VO_2), carbon dioxide output (VCO_2), minute ventilation (VE), respiratory exchange ratio (RER), metabolic equivalent (MET), anaerobic threshold ($ATVO_2$), heart rate (HR), heart rate reserve (HRR) and oxygen pulse (O2HR) measured during cardiopulmonary exercise testing. Pulmonary functions were measured using spirometry and quality of life were evaluated using FACT-L (Functional Assessment of Cancer Therapy-Lung) questionnaire.

Results: Demographics were similar in groups ($p>0.05$). Peak- VO_2 ($p<0.001$), VCO_2 ($p<0.001$), VE ($p<0.001$), RER ($p=0.017$), MET ($p<0.001$), $ATVO_2$ ($p<0.001$), HR ($p=0.001$), HRR ($p<0.001$) and O2HR ($p<0.001$) were statistically significantly decreased measured at max CPET. Pulmonary function parameters FEV1 ($p<0.001$), FVC ($p<0.001$), PEF ($p=0.002$) and FEF 25.75% ($p=0.002$) were significantly lower and FACT-L questionnaire physical ($p<0.001$), social/family ($p=0.043$), emotional ($p=0.063$), functional wellbeing subscale scores ($p=0.009$) and total score ($p<0.001$) were higher in patients with NSCLC compared with healthy subjects. Fourteen (77.7%) lung cancer patients' peak VO_2 values were below 80% expected. Eleven (61.1%) lung cancer patients had obstructive type, 7 (38.8%) had restrictive type respiratory function abnormality.

Conclusion: Survived non-small lung cancer patients have impaired maximal exercise capacity, both obstructive and restrictive type of pulmonary function abnormalities and quality of life. Both pulmonary and cardiac parameters are adversely affected. Cardiopulmonary rehabilitation is essential for NSCLC to optimize exercise capacity, lung function and quality of life.

Keywords: Non-small cell lung cancer, cardiopulmonary exercise test, pulmonary function, quality of life

[Abstract:0612] PS-094 [Accepted:Poster Presentation] [Pulmonary Rehabilitation and Chronic Care]

Relationship Between Gait Speed and Peripheral Muscle Strength, Rectus Femoris Muscle Cross-Sectional Area and Exercise Capacity in Patients with Pulmonary Hypertension

Buse Özcan Kahraman¹, İsmail Özsoy¹, Agah Baran², Serap Acar¹, Ebru Özpelit³, Bahri Akdeniz³, Can Sevinç⁴, Ali Balcı², Sema Savcı¹

¹School of Physical Therapy and Rehabilitation, Dokuz Eylül University School of Medicine, İzmir, Turkey

²Department of Radiology, Dokuz Eylül University School of Medicine, İzmir, Turkey

³Department of Cardiology, Dokuz Eylül University School of Medicine, İzmir, Turkey

⁴Department of Chest Diseases, Dokuz Eylül University School of Medicine, İzmir, Turkey

Objectives: Pulmonary hypertension (PH) is a rare disorder characterized by dyspnea, increased fatigue, decreased muscle strength and reduced exercise capacity. The gait speed has been reported as a sign of disability in the elderly, need for health care and survival. It is also referred to as a sign of exercise performance in the elderly and is associated with other well-known performance measures such as the 6 Minute Walk Test (6MWT) distance. It has been reported that gait speed reflects not only pulmonary effect but also general well being and systemic effects of disease severity in Chronic Obstructive Pulmonary Disease. However, there are not enough studies about the factors related to gait speed in PH patients. Our aim therefore was to investigate the relationship between gait speed, peripheral muscle strength, cross-sectional area of rectus femoris, and exercise capacity in patients with PH.

Methods: Eighteen participants with PH diagnosis were included. The gait speed results calculated from the 4m gait speed were used to evaluate the gait speed. A hand-held dynamometer was used to assess muscle strength of the knee extensor. Superficial ultrasonography was used to measure rectus femoris muscle cross-sectional. Exercise capacity was assessed by the 6 Minute Walk Test.

Results: The median age of the patients were 45.5 years (Interquartile range: 25.75-58.25). There was found a statistically significant moderate to high level of correlation between gait speed and knee extensor muscle strength, rectus femoris muscle cross-sectional area and exercise capacity ($p<0.05$).

Conclusion: Its simple to apply and the relation of knee extensor muscle strength, rectus femoris muscle cross-sectional area and exercise capacity suggests that gait speed may be an evaluation method that can reflect physical performance in PH patients.

Keywords: Gait speed, peripheral muscle strength, rectus femoris muscle cross-sectional area

[Abstract:0615] PS-172 [Accepted:Poster Presentation] [Tuberculosis]

The Dynamics of Tuberculosis Incidence Rate in Belarus and Nearby Countries

Halina Baradzina, Anastasia Vankovich, Elena Romaschenko

Belarusian State Medical University, Minsk, Belarus

Objectives: Republic of Belarus achieved significant results in reducing tuberculosis incidence rate. Analysis of tuberculosis incidence dynamics in Belarus in comparison with the neighboring countries of the European Region of WHO is important for a right mark of the situation with tuberculosis. All the states are supervised by a single WHO Center, therefore, they use uniform approaches to the implementation of international strategies to combat tuberculosis. The aim was to evaluate tuberculosis incidence rate dynamics in Belarus by comparison with Russia, Ukraine, Poland, Lithuania, Latvia, Estonia and Kazakhstan.

Methods: Analysis of the Belarus statistical data and WHO data about tuberculosis incidence for 2000-2015 years was conducted. European Region of WHO unites also the countries of the former Soviet Union. Among the analyzed states besides countries-geographical neighbors of Belarus, Estonia was included (to analyze the situation in all the Baltic countries) and Kazakhstan (as the largest post-Soviet country after the Russian Federation) .

Results: Tuberculosis incidence in analyzable region varies from 91 in Ukraine till 18 per 100.000 populations in Estonia. Tuberculosis incidence in Ukraine, Kazakhstan and Russia is significantly higher than in other countries. The highest incidence rate was registered in Kazakhstan in 2004 (202 per 100.000 populations) , but in 2015 morbidity index in Kazakhstan became less than in Ukraine (89 and 91 per 100,000 populations) . World tuberculosis incidence peak, which was in 2004 year, practically coincided with maximum indexes in Kazakhstan, Russia and the Ukraine. In other countries tuberculosis morbidity peak was overcome earlier. The leaders in the rate of this indicator declining from 2000 till 2015 are Estonia (-4.69 % in a year) , Latvia (-4.43%) and Kazakhstan (-3.31%) . The level of MDR-TB is varies from 0.9% in Poland to 67.3% in Belarus and 56.2% in Kazakhstan in 2015. The amount of MDR-TB cases stabilized with a decreasing tendency since 2014. HIV-TB level in the analyzable countries varies in 12.6 times. HIV-TB level in Poland is only at 1.9% TB patients. This problem is the most actual in Latvia (24%) and Ukraine (22%) . Russia and Estonia have same HIV-TB level (10 %) .

Conclusion: The incidence of tuberculosis and the rate of decline of this indicator vary significantly in the analyzed region. The leaders are Kazakhstan, Latvia and Estonia. Significant MDR-TB dissemination is a global problem of the region especially for Belarus and Kazakhstan. HIV-TB proportion is growing in all countries of region, but the highest level is in Latvia and Ukraine.

Keywords: Tuberculosis, incidence, HIV-TB, drug-resistant tuberculosis.

[Abstract:0619] PS-217 [Accepted:Poster Presentation] [COPD]

Correctable Errors in COPD and Asthmatic Patients While Using Inhaler Medication: Analysis of 509 Patients

Birsen Ocaklı¹, İpek Özmen¹, Eylem Acartürk Tunçay¹, Sinem Güngör¹, Zafer Ali Sak², Nurgül Yer¹, Nalan Adıgüzel¹, Zuhâl Karakurt¹, Peri Meram Arbak³

¹Health Sciences University İstanbul Süreyyapaşa Chest Diseases and Thoracic Surgery Training and Research Hospital, İstanbul, Turkey

²Department of Chest Diseases, Harran University School of Medicine, Şanlıurfa, Turkey

³Department of Chest Diseases, Düzce University School of Medicine, Düzce, Turkey

Objectives: Inhaler therapy is the cornerstone of COPD and asthma therapy, effectiveness of treatment depends on the device and the patient's ability to use the inhaler. In GINA/GOLD guidelines, it is recommended to evaluate inhaler training before prescribing a new device. We aimed to investigate the frequency of corrected misapplication in COPD and asthma patients by determining the common inhalation technique mistakes.

Methods: A hospital-based cross-sectional, observational study was done in chest diseases department of university hospital with COPD and asthma patients who participated in control and used an inhaler at least one month were included. The socio-demographic information was collected.

The ability to use inhalation devices was assessed by requiring a technician to demonstrate the patient inhaler technique with metered dose inhalers and dry powder inhalers with placebo. Technician was filled inhaler chart, prepared by Thoracic Society Asthma Guideline. The inhaler mistakes of COPD and asthma patients were compared.

Results: 509 patients included in the study, 181 were asthma (36.6%) and 328 were COPD (64.4%) . 140 (77%) of asthmatic and 114 (34.8%) of COPD were female ($p<0.0001$) . The ages of asthma and COPD were 56.0 ± 14.5 , 64.6 ± 10.3 , respectively ($p<0.0001$) . The disease duration was similar (9.2 ± 9.5 , 9.5 ± 7.7 years) . Inhaler use duration in asthma and COPD was 7.0 ± 7.6 , 8.0 ± 6.6 years, respectively. The inhaler characteristics of the patients are summarized in Table 1. In asthmatics keeping the head in the right position while using ÖDİ® was significantly more frequent than COPD ($p<0.007$) . Asthmatics using Aerolizer® are significantly more likely than COPD to press keys and were found to be unable to hold their breathes for 10 seconds ($p<0.0005$, $p<0.012$, respectively) . Asthmatics were significant inability to keep the Turbohaler® in upright position compared to COPD ($p<0.029$) . Diskus® practice errors were similar in both groups. COPD and asthma patients were more likely to have a sustained ÖDİ®'s and head vertically, increased ability to hold the turbohaler vertically ($p<0.0001$, $p<0.0001$, $p<0.005$, respectively) . As the duration of inhaler use was prolonged, the superiority of head vertical while using ÖDİ and Turbohaler® vertically was increased ($p<0.006$, $p<0.012$, respectively) .

Conclusion: In this study, mistakes were reported at different stages of using inhalers in COPD and asthma. The usage skills of inhaler was improved by the longer duration of disease. In patients using inhalers, the use of inhaler devices shouldn't be considered adequate, inhaler technique training should include continuity rather than a session at the beginning. Inhaler technique checks should be performed at each controls.

Keywords: Asthma, COPD, education of patients, inhaler devices, misuse

Table 1. The inhaler devices characteristics of the patients

	COPD, N=328	Asthma, N=181	p
The Inhaler device type	N (%)	N (%)	p
Turbohaler®	34 (10.4)	43 (23.8)	<0.001
Diskhaler®	78 (23.8)	75 (41.4)	<0.001
Ölçülü Doz İnhaler®	273 (83.2)	140 (77.3)	0.07
Aerolizer®-ve Handihaler®	249 (75.9)	69 (38.1)	<0.001
Nebulizer	111 (33.8)	32 (17.7)	<0.001

[Abstract:0623] SS-134 [Accepted:Oral Presentation] [Respiratory Failure and Intensive Care]

Factors Affecting Success of High Flow Oxygen Therapy in Acute Hypoxemic Respiratory Failure

Emel Eryüksel, Hüseyin Arıkan, Umut Sabri Kasapoğlu, Erdem Yalçınkaya, Ayşen Erer, Şehnaz Olgun Yıldızeli, Sait Karakurt

Department of Pulmonary and Critical Care Medicine, Marmara University School of Medicine, İstanbul, Turkey

Objectives: Oxygen therapy is the first-line treatment of acute hypoxemic respiratory failure. In patients where low-flow oxygen systems are not sufficient; high flow nasal cannula (HFNC) , which can deliver 100% humidified and heated oxygen at flow rates up to the nostril up to 60 L/min, has been widely used. The aim of this study is to investigate the factors affecting the success of HFNC treatment in adult patients with acute hypoxemic respiratory failure.

Methods: The study was designed to be prospective and observational. Between January 2017 and 2018, medical records of cases with acute hypoxemic respiratory failure supported by HFNC treatment in the intensive care unit were evaluated. Treatment success is defined as avoidance of intubation. Serial changes in respiratory parameters after HFNC treatment and baseline characteristics of patients were measured and recorded.

Results: HFNC was applied to 37 cases of hypoxemic respiratory failure. The median age of the cases with 29 (78.4) male and 8 (21.6) female was 61 (19-85) years. Indications of HFNC are according to the order of frequency; 18 (48.6) had immunosuppressive pneumonia; 10 (27) had pneumonia, 6 (16.2) had interstitial lung disease, and 3 (8.1) had pulmonary embolism. HFNC success was 51.4% with 19 cases. The mortality of those who failed HFNC was found to be significantly higher than the mortality of the successful ones. (94% vs. 28.8%, respectively, $p<0.001$) of the cases; the mean initial SOFA score was 7.08 ± 3.09 , the mean APACHE II score was 20.4 ± 6.3 ; median PaO₂/FiO₂ 146 (55-320), mean respiratory rate 30.1 ± 6.8 , mean heart rate 105.6 ± 20 , mean MAP 88.1 ± 16.04 . PaO₂, PaO₂/FiO₂ and lactate medians were statistically significantly different between the successful and unsuccessful groups when compared to the HFNC success status individually [88 (50-160) vs 70.5 (50-132) $p=0.04$; 174 (76-320) vs 102 (55-160) $p=0.02$; 1.5 (0.7-5) vs 2.3 (0.6-6.9) $p=0.02$]. The SOFA score and the APACHE II score were found to be statistically significantly different between the successful and the unsuccessful groups compared to the HFNC success status individually (5.95 ± 3.04 versus 8.28 ± 2.74 , $p=0.02$; 17 ± 4.8 vs 24 ± 5.9 $p<0.001$ respectively).

Conclusion: As a result; HFNC has a high mortality rate in unsuccessful cases. For this reason, knowing the factors contributing to the prediction of failed events may contribute to reducing mortality.

Keywords: High flow oxygen, hypoxemic respiratory failure, success

[Abstract:0625] PS-121 [Accepted:Poster Presentation] [Clinical Problems - Pulmonary Vascular Diseases]

Unilateral Pulmonary Arterial Agenesis Diagnosed at Adult: Case Report

Sertaç Arslan¹, Özlem Erçen Diken¹, Yusuf Karavelioğlu², Ayşe Yılmaz¹, Meral Gülhan¹

¹Department of Pulmonary Medicine, Hitit University School of Medicine, Çorum, Turkey

²Department of Cardiology, Hitit University School of Medicine, Çorum, Turkey

Introduction: Unilateral pulmonary arterial agenesis (PAA) is a rare congenital cardiovascular abnormality. Approximately 350 cases were reported between 1868-2010. Incidence has been increased recently due to development at diagnostic methods and computerized tomography (CT). Although it is a congenital abnormality, the diagnosis may be delayed until adulthood. In a systematic review between 1990-2016, only 65 adult cases were reported. We aimed to present a PAA patient diagnosed at our clinic for the first time.

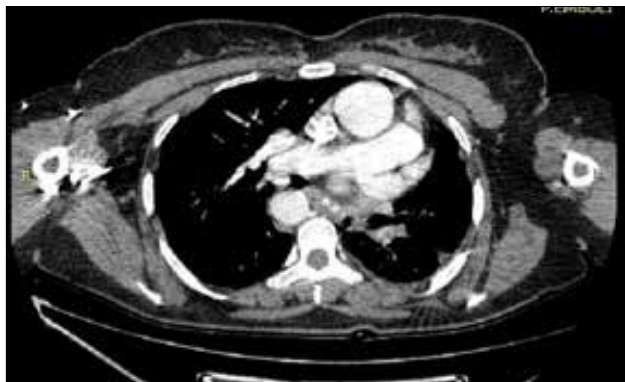

Figure 1. Left pulmonary artery can not be seen at CT angiography, aorta is placed at paravertebral position

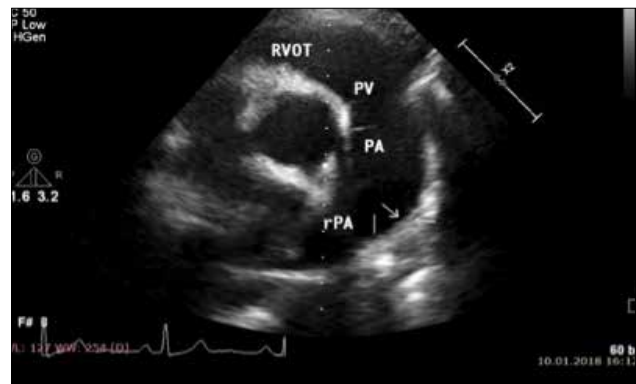


Figure 2. No left pulmonary artery seen at echocardiography

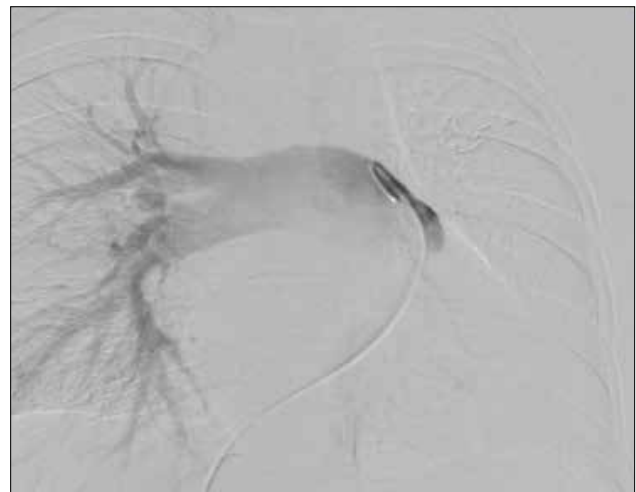

Figure 3. Left pulmonary artery can not be seen

Case Presentation: 49 year-old female, admitted with dyspnea; hospitalized for further examination with suspicious pulmonary emboli. CT angiography findings supported left PAA (Figure 1) . To confirm the diagnosis, echocardiography and pulmonary angiography; and to rule out pulmonary arterial hypertension (PAH) , right heart catheterization were performed. After the procedure, left PAA was verified (Figure 2, 3) , PAH wasn't found. Left lung hypoplasia and bronchiectasis were accompanied. Clinical improvement was obtained by nonspecific treatment, patient immunized against bacterial infection. Surgical intervention was not thought because she didn't have active bleeding and recurrent infections. Patient was taken into follow-up for hemoptysis and PAH.

Conclusion: Differential diagnosis of PAA with chronic pulmonary emboli, Swyer-James-McLeod Syndrome, lobar atelectasis and postlobectomy is important; as it is rarely seen etiologic factor for exercise dyspnea and hemoptysis. There is no any specific treatment. Medical treatment against PAH and surgical treatment for recurrent pulmonary infections and hemoptysis are treatment options. Bronchial arterial embolization can be an option for hemoptysis if patient isn't suitable for surgery.

Keywords: Pulmonary arterial agenesis, congenital abnormality, vascular abnormality

[Abstract:0627] PS-193 [Accepted:Poster Presentation] [Pediatric Pulmonary Diseases]

Complicated Community Acquired Pneumonia in Childhood: Our Annual Data

Gökçen Dilşa Tuğcu¹, Beste Özsezen¹, Betül Pehlivan³, İrem Alkan³, Güzin Cinel²

¹Department of Pediatric Chest Diseases, Hacettepe University School of Medicine, İhsan Doğramacı Children's Hospital, Ankara, Turkey

²Department of Pediatrics Chest Diseases, Ankara Child Health and Diseases, Hematology and Oncology Hospital, Ankara, Turkey

³Ankara Child Health and Diseases, Hematology Oncology Training and Research Hospital, Ankara, Turkey

Objectives: Although community-acquired pneumonia (CAP) has been declining in children in recent years, the frequency of complicated community-acquired pneumonia (CCAP) has been increasing steadily. Why and how patients diagnosed with CAP develops CCAP still remains a current research topic. Thus, new approaches related to the diagnosis and treatment of CCAP are becoming important.

Methods: Demographic characteristics, anamnesis, laboratory findings, imaging results and treatment responses were recorded from the file records of 113 patients who were hospitalized due to CAP and CCAP in our pediatric services in 2017. When pleural effusion empyema developed in patients diagnosed with CCAP, thoracentesis and/or chest tube insertion, pleural fluid test results, microbiology results, additional surgical intervention need and length of hospitalization were investigated.

Results: 60 of our patients (53%) were female and 53 (47%) were male and the average age was 2 years and 10 months (1 month-17 years 6 months) . 15 patients (13%) who had been previously diagnosed with asthma/wheezy children were being followed up. 15 patients (13.7%) had been previously diagnosed with CAP. At the time of admission, 107 (94.7%) patients had coughing complaints, 92 (81.4%) had fever, and the average duration was 3 days. 43 patients (38.1%) had been previously on oral antibiotics. In their chest X-rays, 23 (20.4%) patients had atelectasis, 108 (95.6%) had consolidation, 16 (14.2%) had pleural effusion. 36 (31.8%) patients were diagnosed with CCAP and of these patients, 16 (44.4%) had developed pleural effusion, 8 (22.2%) had developed empyema, 4 (11.1%) had had necrotizing pneumonia, 1 (14.2%) had developed ling abscess, 1 (14.2%) patient had experienced broncho pleural fistula, 6 (16,6%) had developed pneumothorax. 16 (14,2) patients required a monitoring in the pediatric intensive care unit, 15 (41,6) patients required thoracic computed tomography due to CCAP. 56 (49,6%) patients received oxygen via nasal cannulae and 18 (15,9%) received oxygen via high frequency nasal cannulae. 13 (11.5%) patients were followed by noninvasive mechanical ventilation and 2 (1.8%) were followed by invasive mechanical ventilation. Of the 70 patients whose blood cultures were taken, it was detected that 6 (8,5%) were found have reproduction (p.aeruginosa = 1, staph strains=2, streptococ strains=3) . Twenty-two (19.5%) patients required respiratory viral panel DNA PCR and 12 (18.3%) of them had a positive results (influenza A=2, coronavirus=1, RSV=6, adenovirus=3) . M. tuberculosis was detected in none of our patients, via immunologic tests 3 (2.7%) patients were diagnosed with selective IgA deficiency and 1 (0.9%) patient were diagnosed with infant transient hypogammaglobulinemia. Of the 24 (21,2 %) patients

who had developed pleural effusion and empyema, thoracentesis was performed in 10 (41.6%) patients, 12 (50%) were implanted chest tubes, and 2 patients were followed-up without a surgical intervention since their thoracic USG was below 10 mm. of the 12 patients who were implanted chest tubes, 4 (25%) of them received Tissue plasminogen activator (TPA) treatment due to effusion containing septa. 1 (4,1%) patient had a surgical intervention due to bronchopleural fistula. The mean duration of hospitalization for our patients was 12 days (12.3 ± 3.7). It was recorded that patients who were diagnosed with CCAP were hospitalized for longer periods (22.3 ± 4.3 , $p > 0.001$) compared to patients diagnosed with CAP. It was also recorded that previous antibiotics use, presence and duration of fever was not associated with CCAP diagnosis ($p > 0.001$). During admission, between CAP and CCAP no difference in CRP, white blood cell count, age and gender were detected.

Conclusion: New approaches in the diagnosis and treatment of CAP and the identification of etiology remains an important research topic nowadays. With the help of future prospective studies, causes of CCAP can be detected and preventive new treatments can be developed.

Keywords: Community-acquired pneumonia, complicated community-acquired pneumonia, pleural effusion, empyema

[Abstract:0629] PS-158 [Accepted:Poster Presentation] [Clinic Problems - Others]

Evaluation of the Chest Diseases Consultations That Are Requested from Surgical Branches

Pelin Duru Çetinkaya, Ferhat Çetinkaya

Çukurova Dr. Aşkim Tüfekçi Hospital, Adana, Turkey

Objectives: We wanted to evaluate what is done with the preoperative, postoperative, diagnostic, therapeutic purposed consultations which do not have standard evaluation method despite the pulmonologists constantly confront them.

Methods: 778 pulmonology consultations that were requested between the dates of 01.12.2017 - 31.12.2017 were analyzed in terms of the "medical units", and the files from the surgical services were checked additionally. The reasons (preoperative-postoperative) that the consultations are requested and the way that they were evaluated (the examinations that were requested and suggested treatments) were examined retrospectively. Acquired data were analyzed stastically at SPSS.

Results: Of the 787 pulmonolgy consultations that were requested in a month; 598 were from emergency service, 142 were from inpatient (services), 47 were from intensive care unit. 89 of 142 inmate consultations were requested from surgical branches (Figure 1, 2). There are no clinic of obstetrics and gynecology-pediatrics clinic in our hospital. We analyzed the consultations that were requested from surgical branches retrospectively; 62 files were acquired. Average age of the matures that the

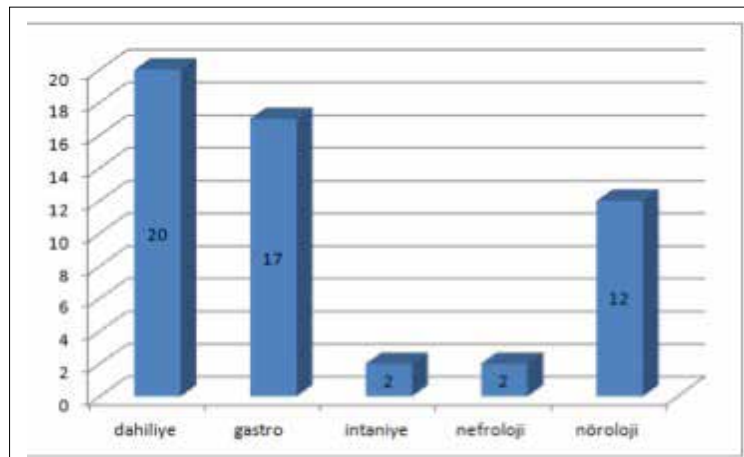


Figure 1. Distribution of required consultations from internal branches

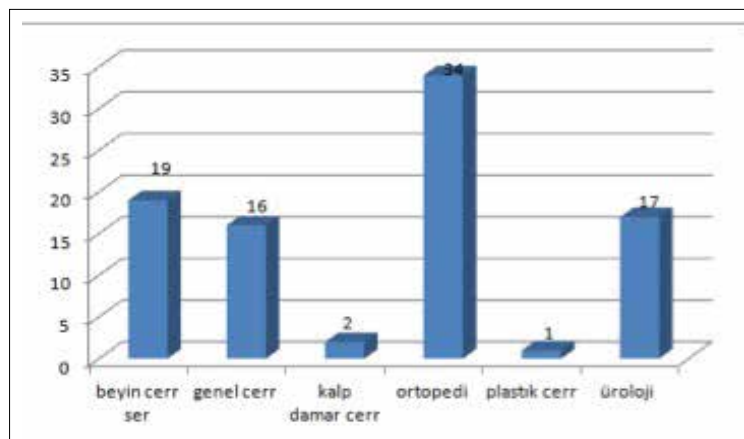


Figure 2. Distribution of required consultations from surgical branches

consultations were requested for was 64.20 ± 17.23 (24-91). 64.5% (40) of the matures were male and 35.5% (22) were female. In 33.9% (21) of the pulmonology consultation requisition papers the reason for request was not specified. 83.9% (52) of the consultations were preoperative and 14.5% (9) were postoperative. PA graphy for all of the 62 matures was requested. Respiratipon function test was requested for 38,7% of the cases that the consultation was required. 35.5% (22) of the cases are smokers. 54.8% (34) of the cases have no symptoms. In responses; for 37.1% (23) of the cases treatment was suggested. No risks were indicated for 46.15% (24) of the cases in preoperative consultations. Among the ones that risks were indicated maximum rate was 15.8% that can be defined as low-risk. 50 of the 52 cases that had been evaluated preoperatively had the operation and only in 4 of the cases complications developed.

Conclusion: In this study it was deduced that %83.9 of the consultations that are requested from surgical branches are preoperative, in 33.9% of the cases that consultations were requested the reason of the requisition was not specified and in 54.8% cases there were no symptoms. When there is no need for advanced pulmonary examination in the cases that are detailedly physical inspection and the ones that pathology was not detected, PA pulmonary graphy was requested for all the 52 cases that consultation was requested preoperatively. In 46.5% of the cases no risks were indicated. Unfortunately, we could not find any standards for requisiton and responding of the consultations.

Keywords: Chest diseases, consultation, surgical branches

[Abstract:0632] SS-061 [Accepted:Oral Presentation] [Experimental Investigations]

Effects of Timokinone on Gene Level in Lung Cancer and Comparison with Cisplatin

Sedat İlhan¹, Demet Kahraman¹, Onur Bayrakçı², Hasan Bayram³, Ahmet Ferudun Işık¹

¹Cell Culture Laboratory, Gaziantep University School of Medicine, Gaziantep, Turkey

²Ersin Arslan Research and Application Hospital, Gaziantep, Turkey

³Translational Medical Research Center, Koç University, İstanbul, Turkey

Objectives: Many of the effects of *Nigella sativa* (black cumin) components such as antioxidants, antioxidants and antitumoral agents have been demonstrated in studies of thymoquinone, a bioactive component. In our study, the effects of effective doses of thymokinone on gene levels on lung cancer cell lines were investigated.

Methods: In Gaziantep University Cell Culture Laboratory; A549 (adenocarcinomic human alveolar basal epithelial cells), BEAS 2B (normal human bronchial epithelial cells) and HTB 54 (human lung carcinoma-Cal-1) were propagated in appropriate culture media. Previous studies have been exposed to doses of thymoquinone (100 μ M) and cis-platine (200 μ M) as determined. The cells collected at the end of the 4th hour and were analyzed using the RT-PCR method for EGFR (epidermal growth factor receptor), K-RAS, p53 (tumor protein 53) and c-Myc genes.

Results: In the A549 cell line, cisplatin significantly increased expression of the genes which K-RAS ($p=0.0087$) and EGFR ($p=0.00130$); thymoquinone significantly reduced expression of the p53 gene ($p=0.0022$). For BEAS 2B, p53 gene expression was significantly increased in the presence of thymoquinone ($p=0.0022$). Finally, expression of K-RAS ($p=0.0152$) p53 ($p=0.0022$) and EGFR ($p=0.0022$) genes was decreased in the presence of thymoquinone for HTB 54.

Conclusion: Based on the PCR results obtained, it was seen that each cell line reacted differently to cis-platine and thymoquinone. However, when compared to cis-platin, basically, it can be said that thymoquinone has a higher anticancerogenic effect at a lower dose.

Keywords: Cell line, cisplatin, lung cancer, polymerase chain reaction, thymoquinone

[Abstract:0636] EPS-032 [Accepted: E-Poster] [Clinical Problems - Diffuse Parenchymal Lung Disease]

Langerhans Cell Histiocytosis: Case Report

Görkem Baydoğan Türkan¹, Özge Aydın Güçlü², Ezgi Demirdöğen Çetinoğlu¹, Ahmet Ursavaş¹, Mehmet Karadağ¹

¹Department of Pulmonary Diseases, Uludağ University School of Medicine, Bursa, Turkey

²Gürsu Cüneyt Yıldız Hospital, Bursa, Turkey

Introduction: Langerhans cell histiocytosis (LCH) is a rare disorder caused by monoclonal Langerhans cells proliferation in bone, skin, lung, lymph nodes, liver, spleen, nervous or hematopoietic system. Aetiology is unknown but occurs predominantly in young smokers, with an incidence peak at 20-40 yrs of age. In adults, pulmonary involvement with Langerhans' cell histiocytosis usually occurs as a single-system disease and is characterised by focal Langerhans' cell granulomas infiltrating and destroying distal bronchioles. We aim to present this case to discuss clinical, pathological and radiological features of LCH.

Case Presentation: Fifteen months prior to this presentation, a 50-year-old man developed polyuria, polydipsia, and nocturia. A diagnosis of central diabetes insipidus (DI) was confirmed. He complained of dizziness, right aural fullness, a right post-auricular mass one year later. Acoustic canal magnetic resonance imaging (MRI) showed that the mass at the right mastoid cellular, measuring 3x1.9x2.6 cm. Neurosurgery team operated and pathological diagnosis was 'eosinophilic granuloma'. Postoperative follow-up without treatment was proposed. Three years after surgery, a lump on the back of the skull and a well-defined, painfull, 3x2 cm measuring mass on right scapular bone was found. Excisional biopsy of the scapular bone was performed, which revealed 'eosinophilic granuloma'. He was admitted to our pulmonary clinic for further evaluation and treatment. He had been smoking 20 cigarettes day for 4 years and he was working at textile sector. The physical examination was normal. The chest radiography showed bilateral symmetrical reticulo-micronodular infiltration predominantly involving the upper zones. On the thoracic computed tomography (CT)

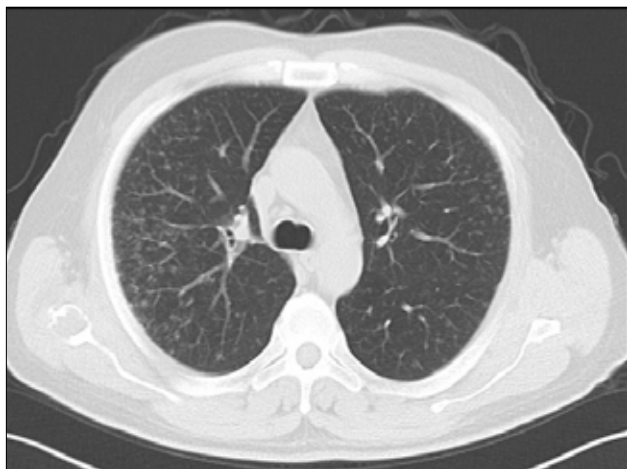

Figure 1.

combines small than 1 cm, poorly limited nodules, and thick and thin-walled cysts predominantly in the upper and middle lung fields. The lesions are focal and are separated by apparently normal parenchyma, and they affect both the peripheral parts of the lung fields (Figure 1). We evaluated CD1a-negative cells in bronchoalveolar lavage samples. Based on the clinical presentation of the lesions and positive microscopic examinations a final diagnosis of eosinophilic granuloma type of LCH was made.

Conclusion: Although some of the steps in the disease process that leads to pulmonary Langerhans' cell histiocytosis are beginning to come to light, further work is needed to explain the different aspects of the Langerhans' cell granuloma. A key goal is determination of the mechanisms involved according to the location and clinical expression of the disease.

Keywords: Langerhans cell histiocytosis, eosinophilic granuloma, diabetes insipidus

[Abstract:0638] PS-093 [Accepted:Poster Presentation] [Pulmonary Rehabilitation and Chronic Care]

Comparison of Balance Ability of Healthy Individuals with Asthmatic Patients

Ayşenur Yılmaz¹, Süleyman Gürsoy¹, Orçin Telli Atalay¹, Harun Taşkın¹, Ali Yalman¹, Binnaz Fatma Evyapan²

¹Pamukkale University School of Physical Therapy and Rehabilitation, Denizli, Turkey

²Department of Chest Diseases, Pamukkale University School of Medicine, Denizli, Turkey

Objectives: Previous studies have shown that structural defect and deformities develop in the chest wall due to decreased thoracic mobility in asthmatic patients. The biomechanics of the thoracic cage may affect the body's global mechanics. This situation may cause balance disorder. Therefore, the aim of the study was to compare the balance capabilities of healthy individuals with asthma.

Methods: The study included 49 volunteer subjects who had asthma (Study group) diagnosis according to GINA with 18-50 ages range and 51 healthy volunteer subjects (Control group). Socio-demographic characteristics of subjects were recorded. Static balance and dynamic balance were assessed with SportKat Kinesthetic Ability Trainer (SPORKAT550). Mann-Whitney u was used for data comparison.

Results: The average BMI (Body mass index) score of study group, with a mean age of 35.3±10.3 years, had 26.88±4.29 kg/m² and control group, With a mean age of 36.17±8.47 years, had 24.33±3.39 kg/m² of BMI score. Both the SPORKAT 550 static total balance and dynamic total balance scores were significantly difference between two groups (p<0.05).

Conclusion: As a result of this study it was seen that the static and dynamic balance of asthmatic individuals was deteriorated. We think that balance, one of the most important determinants of daily living activities, should be evaluated in obstructive diseases such as asthma and added balance and postural exercises in pulmonary rehabilitation programs.

Keywords: Asthma, balance, SportKAT 550

[Abstract:0641] SS-064 [Accepted:Oral Presentation] [Experimental Investigations]

Effect of Novel Synthesized Hypoxia Induced Factor (HIF) Inhibitors on Apoptosis and HIF-1 α Expression in A549 Cells

Demet Taşdemir Kahraman¹, Sedat İlhan¹, Eyüp Başaran², Yasemin Saygıdeğer Kont⁴, Ayşegül İyidoğan², Tuğba Taşkın Tok², E. Elçin Oruç Emre², Hasan Bayram³

¹Cell Culture Laboratory, Gaziantep University School of Medicine, Gaziantep, Turkey

²Department of Chemistry, Gaziantep University, Gaziantep, Turkey

³Research Center for Translational Medicine, Koç University, Istanbul, Turkey

⁴Çukurova University School of Medicine, Adana Turkey

Objectives: An effective chemotherapeutic agent has yet to be found in the treatment of lung cancer or the prevention of its metastases. Hypoxia inducible factor 1 alpha (HIF-1 α), which is a transcription factor being sensitive to hypoxia, plays an important role in the initiation of angiogenesis and metastasis by providing transcription of numerous genes. In our previous studies, we demonstrated that our novel synthesized compounds decreased cell viability of broncho-alveolar carcinoma cell line (A549) under hypoxic conditions (İlhan et al. TTD Kongresi 2017: SS 058). In this study, we aimed to investigate the effects of novel synthesized HIF-1 α inhibitors on cell apoptosis in hypoxic conditions, and the underlying mechanisms.

Methods: Hypoxic conditions were provided by incubation in an anaerobic chamber with 1% O₂, 5% CO₂, and 94% N₂ gas mixture. The dose (75 μ M) that was effective on cell viability of the compounds (4S, 6R, 6S, 7R) synthesized for apoptosis and gene level studies was selected. As positive controls, 2-Methoxy-estradiol (2ME2) and FG4592 were used. Apoptosis of cells was evaluated by flow cytometry, whereas mRNA expression for HIF-1 α , VEGFR, GLUT1 mRNA was measured using RT-PCR

Results: As cell apoptosis was assessed, 6R compound (39%) significantly increased the early apoptosis of A549 cells, as compared to negative control cells treated with DMSO (18.2%, p<0.01), and positive controls 2ME2 (13.4%, p<0.01), FG4592 (0.01). Although other compounds including 4S (10.4%) and 6S (9.2%) did not change the cell apoptosis, 7R (25.6%, P<0.05) significantly induced apoptosis comparing to positive controls; 2ME2 and FG4592. Similarly, 6S (HIF-1 α , p<0.05; GLUT1, p<0.01; VEGFR, P<0.05) 6R (HIF-1 α , p<0.05; VEGFR, p<0.001), and 7R (HIF-1 α , p<0.05; GLUT1, p<0.01) significantly enhanced the expression of mRNA levels of the studied proteins as compared to the negative control group, while 4S did not affect the mRNA expression.

Conclusion: These findings suggest that the novel compounds, which we synthesised, in particular 6R, can induce A549 cell apoptosis in vitro by a mechanism, which involves in suppression of HIF-1 α , GLUT1 and VEGFR gene expression.

Funding: This study was funded by TUBITAK (project no: 114Z960)

Keywords: Hypoxia inducible factor 1 alpha (HIF-1 α), lung cancer, cell culture

[Abstract:0643] PS-176 [Accepted:Poster Presentation] [Tuberculosis]

Coexistence of Metastatic Peripheral Nerve Sheath Tumor and Pulmonary Tuberculosis

Özge Aydın Güçlü¹, Görkem Baydoğan Türkan², Ezgi Demirdöğen Çetinoğlu², Ahmet Ursavaş², Mehmet Karadağ²

¹Gürsu Cüneyt Yıldız Hospital, Bursa, Turkey

²Department of Pulmonary Diseases, Uludağ University School of Medicine, Bursa, Turkey

Introduction: Malignant peripheral nerve sheath tumors (MPNST) are uncommon, biologically aggressive soft tissue sarcomas of neural origin that pose tremendous challenges to effective therapy. In 50% of cases, they occur in the context of neurofibromatosis type I, characterized by loss of function mutations to the tumor suppressor neurofibromin; the remainder arise sporadically or following radiation therapy. We aimed to present a case of lung metastasis followed by peripheral nerve sheath tumor and presenting with tuberculosis.

Case Presentation: A 29-year-old man presented with a 4-year history of a mass within his neck. This mass had increased in size in the year prior to presentation. He is a nonsmoker, with no significant past medical history. On examination, the lesion was a firm, nonmobile, exhibited distinct borders, measuring 10×10×8 cm (Figure 1). No other lesions were identified, and examination of her neck and supraclavicular lymph nodes was unremarkable. An excisional biopsy of the neck was performed, which revealed “peripheral nerve sheath tumor”. Neurosurgery was performed in 2014 and postoperative follow-up without treatment was proposed. The patient who applied to the external center for dry cough was found to have multiple, well-defined, nodular lesions on the thoracic computed tomography (CT) (Figure 2). Laboratory testing results were unremarkable. Bronchoscopic examination of the tracheobronchial tree was normal. Due to positive result for acid-fast colouration of the bronchial lavage fluid, the patient received quadruple therapy with isoniazid, rifampicin, ethambutol and pyrazinamide. A positive culture for *M. tuberculosis* has been obtained. Transthoracic biopsy performed because of persistence of nodular lesions in both lungs and resulted as “peripheral nerve sheath tumor”. Medical oncology planned to start chemotherapy.

Conclusion: We have presented a case of lung tuberculosis which also incidentally found for further evaluation for metastatic pulmonary nodules. MPNSTs are a rare variety of soft tissue sarcoma of ectomesenchymal origin, with an incidence of one per million per year. A total of 9% of patients present with disease-positive lymph nodes, in 28%, distant metastases (primarily lung) occur. After receiving the diagnosis of the biopsy, a chest x-ray and if necessary a chest CT should be performed to evaluate for pulmonary metastases. Nearly one third of patients presented with metastases or developed distant metastases, mainly in the lung.

Keywords: Malignant peripheral nerve sheath tumors, lung metastasis, tuberculosis

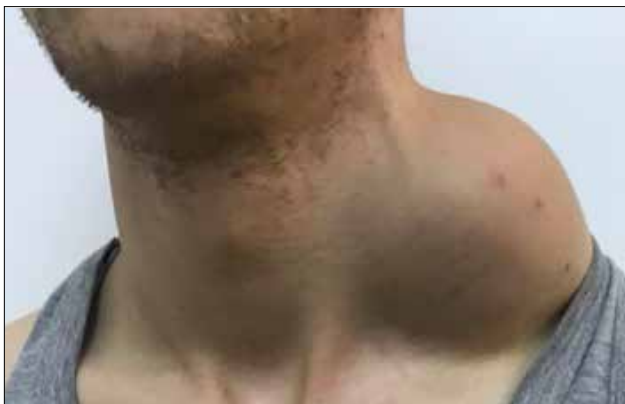

Figure 1.

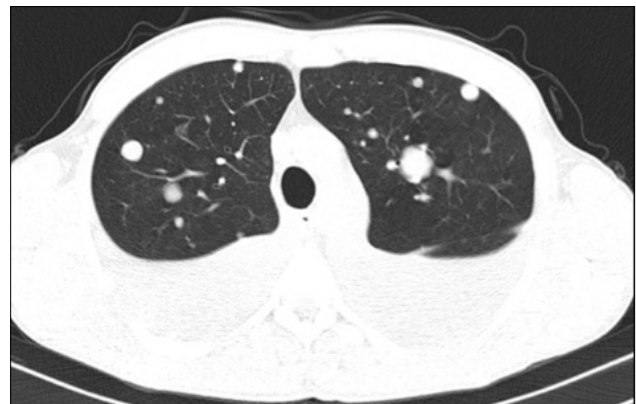

Figure 2.

[Abstract:0647] EPS-215 [Accepted: E-Poster] [Thoracic Surgery]

A Rare Intrathoracic Mass: Accessory Liver Lobe

Salih Bilen, Celal Buğra Sezen, Neslihan Akanil Fener, Celalettin İbrahim Kocatürk

Health Sciences University Yedikule Chest Diseases and Chest Surgery Hospital, İstanbul, Turkey

Abnormal location of liver tissue is usually observed in abdominal organs such as gallbladder, spleen, adrenal glands, pancreas. However, intrathoracic liver tissue is really rare to be observed. Although the reason may be congenital, it may also develop after a trauma or a surgical intervention. Since they are usually asymptomatic, they are detected incidentally. In this article, we evaluated our rarely seen accessory liver lobe (ALL) case within the context of literature.

Keywords: Accessory liver, intrathoracic mass, supradiaphragmatic lesion, thoracoscopy

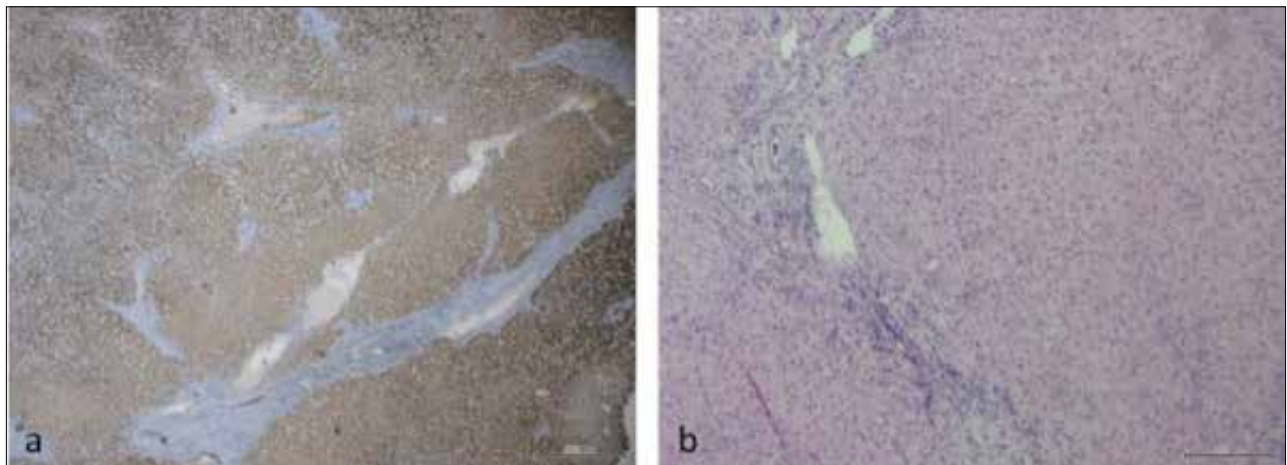


Figure 1. Pathology image. Positive reaction with x40 hepar and x200 he liver tissue including central vein, portal area and lobular structure

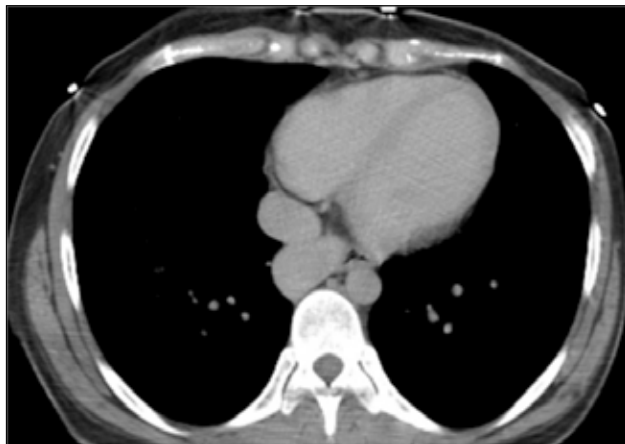

Figure 2. Thoracic CT image

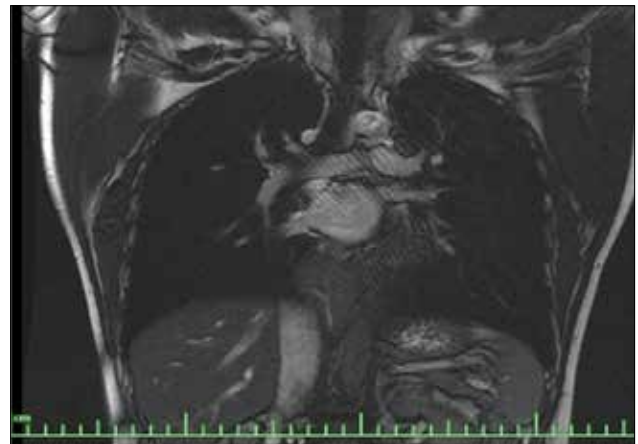


Figure 3. Thoracic MR image

[Abstract:0651] SS-027 [Accepted: Oral Presentation] [Pulmonary Rehabilitation and Chronic Care]

Physical Fitness, Pulmonary Function and Exercise Capacity in Children with Primary Ciliary Dyskinesia and Healthy Subjects

Hazal Sonbahar Ulu¹, Deniz İnal İnce¹, İlker Yatar², Cemile Bozdemir Özel¹, Aslıhan Çakmak¹, Naciye Vardar Yağlı¹, Melda Sağlam¹, Haluk Tekerlek¹, Ebru Çalık Kutucu¹, Hülya Arıkan¹, Hayriye Uğur Özcelik³

¹Department of Physiotherapy and Rehabilitation, Hacettepe University School of Health Sciences, Ankara, Turkey

²Department of Physiotherapy and Rehabilitation, East Mediterranean University School of Health Sciences, Famagusta, Cyprus

³Department of Pediatric Chest Diseases, Hacettepe University School of Medicine, Ankara, Turkey

Objectives: Primary ciliary dyskinesia (PCD) is a rare disease characterized by dysfunction in moving cilia. There is a lack of study related to physical fitness, pulmonary function and exercise capacity in PCD. The aim of this study was to compare physical fitness, pulmonary function and exercise capacity in children with PCD and healthy subjects.

Methods: Twenty children with PCD (12.7±3.8 years; 9F, 11M) and 20 healthy subjects (13.8±4.5 years; 9F, 11 M) participated in the study. Pulmonary function test results were recorded and respiratory muscle strength (maximal inspiratory and expiratory pressure, MIP and MEP respectively) were measured using hand held mouth pressure measurement device. Exercise capacity was evaluated using incremental shuttle walk test (ISWT). Physical fitness was assessed using Munich Physical Fitness Test (PFT).

Results: The FEV1, FEF25-75%, MIP, MEP, Munich PFT's speed, strength, power, flexibility and coordination parameters and ISWT distance were significantly impaired in children with PCD than those of healthy subjects (p<0.05).

Conclusion: Munich PFT's speed, strength, power, flexibility and coordination parameters, pulmonary function and exercise capacity were affected by the illness. These findings should be considered in future studies investigating the effectiveness of pulmonary rehabilitation in PCD.

Keywords: Primary ciliary dyskinesia, pulmonary function, physical fitness, exercise capacity

[Abstract:0654] SS-053 [Accepted:Oral Presentation] [Thoracic Surgery]

Clinical Study: Resection in Lung Cancer Thoracic Wall Invasions

Funda Cansun Yakut, Bengisu Arabacı, Şeyda Örs Kaya, Ozan Usluer

Department of Chest Surgery, Health Sciences University, Dr. Suat Seren Chest Diseases and Thoracic Surgery Training and Research Hospital, İzmir, Turkey

Objectives: Resection of thoracic wall can be performed due to several reasons such as primary or metastatic thoracic wall tumors, breast and cancer invasions, radiation necrosis, congenital defects, traumas, sternotomy or wound site infection after a thoracotomy.

Methods: In our clinic, we evaluated the characteristics of 91 cases who had been operated due to thoracic wall invasion of lung cancer between 2006-2017.

Results: Of the 91 patients, 72 were male (65.52%) and 19 were female (34.48%) and 13 had received neoadjuvant chemotherapy treatment. Surgical treatment was performed on 51 (56,04%) patients with tumors located in the right lung and 40 patients (43,95%) with tumors located in the left lung and most common histopathologically observed diagnosis was recorded as squamous cell lung carcinoma (54,6%). Of the studied cases, 21,84% (total 24 patients) were evaluated as stage 3 a-b and stage 4. Of the patients who had different resection types, 18.2% (20 patients) had single rib, 20.02% (22 patients) had double rib, 31.85% (35 patients) had triple rib, and remaining 14 patients (12%, 74) had quadric rib resection.

Conclusion: Direct invasions of lung cancer are one of the most common indications of thoracic wall resections. Curative resection prolongs survival at a significant level. Resection of the thoracic wall aims curative treatment and it can rarely be applied on ulcer lesions or on inoperable cases for pain palliation.

Keywords: Lung cancer, thoracic surgery, thoracic wall, cancer, resection

[Abstract:0655] PS-014 [Accepted:Poster Presentation] [Clinical Problems - Diffuse Parenchymal Lung Disease]

Coexistence of Nonspecific Interstitial Pneumonia and Celiac Disease: Case Report

Serdar Berk¹, Şule Karadayı², Abdulkerim Yılmaz³, Cesur GümüŖ⁴, Şahande Elagöz⁵, Hatice Özer⁵, Zehra Seyfikli¹

¹Department of Chest Diseases, Cumhuriyet University School of Medicine, Sivas, Turkey

²Department of Thoracic Surgery, Cumhuriyet University School of Medicine, Sivas, Turkey

³Department of Gastroenterology, Cumhuriyet University School of Medicine, Sivas, Turkey

⁴Department of Radiology, Cumhuriyet University School of Medicine, Sivas, Turkey

⁵Department of Pathology, Cumhuriyet University School of Medicine, Sivas, Turkey

Introduction: Nonspecific intestinal pneumonia (NSIP); is an idiopathic interstitial pneumonitis that causes shortness of breath, cough, and fever in middle-aged women and men. Histopathologically, there is no diagnostic feature of UIP, AIP, DIP and COP. Etiology is not fully known. It is often associated with connective tissue diseases and other systemic diseases. Radiographic features of the disease are lower lobe predominant process with patchy areas of ground-glass opacity and varying degrees of reticular abnormality and consolidation. Celiac disease is defined as intolerance that is genetically susceptible to autoimmune mechanisms against gluten and similar proteins in cereals such as wheat, barley, and oats. It is a proximal small bowel disease. The disease can be seen at any age. As it may be asymptomatic, or present with recurrent abdominal pain, diarrhea, impaired liver function and malabsorptions. It has been reported that celiac disease and some interstitial lung diseases may be seen together. Especially, coexistence of hypersensitivity pneumonias and celiac disease have been shown in various case reports (7). In this case report, the coexistence of Celiac disease and NSIP is presented which we have not seen in the literature before.

Case Presentation: A 48-year-old male farmer was admitted to the hospital with a history of non-productive cough and exertional dyspnea for 3 months. The patient had no previously diagnosed chronic disease and no history of smoking. His son's was pigeon exposure but he was not contact with the pigeons. No abnormal findings were found on the physical examinations except for the inspiratory fine crackles. Complete blood count and biochemical tests results were normal and the sedimentation rate was 36 mm/h. Chest radiograph and thoracic HRCT revealed bilateral diffuse reticular and ground-glass opacities, numerous small air cysts in the lower lobes of the lungs and sequel fibrotic changes, mosaic attenuation in both upper lobes (Figure 1, 2). There was no hypoxemia in arterial blood gas analysis. In pulmonary function tests, FVC: 108%, FEV1: 109%, FEV1/FVC: 83, DLCO: 46%. Abnormal findings were not found in connective tissue markers and rheumatological evaluation. Video-assisted Thoracoscopic Surgery (VATS)

Lung Biopsy was performed to the patients. Pathological evaluation revealed NSIP. Endoscopic biopsy revealed gastric and mucosal inflammation, with intraepithelial lymphocytosis, crypt hyperplasia and villous atrophy (compatible with Celiac disease). The patient was followed up with corticosteroid treatment.

Keywords: Celiac diseases, nonspecific intestinal pneumonia, interstitial lung diseases

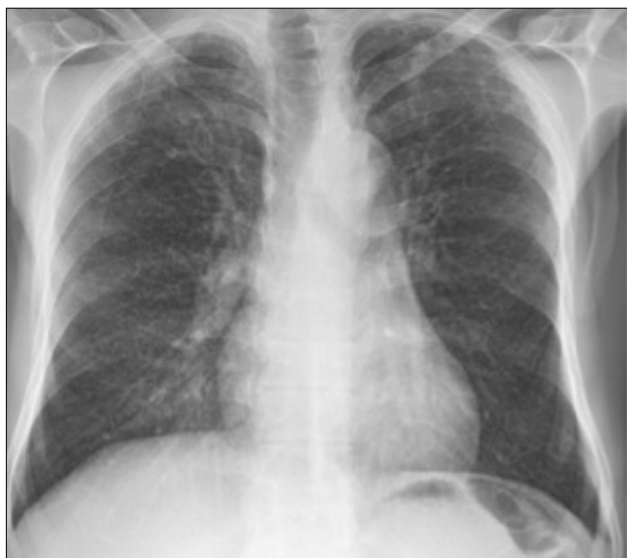

Figure 1. Chest X-ray on admission showed bilateral diffuse reticular opacities and sequel fibrotic changes in the upper zones

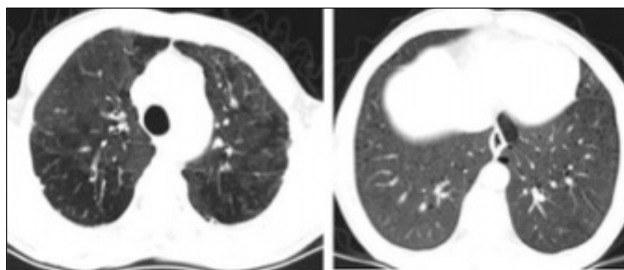


Figure 2. Thoracic HRCT image with mosaic attenuation areas, subpleural fibrosis in the upper lobes and ground-glass opacities, numerous small air cysts in the lower lobes

[Abstract:0658] PS-084 [Accepted:Poster Presentation] [Pulmonary Rehabilitation and Chronic Care]

The Relationship Between Reaction Time, Exercise Tolerance and Balance in Children with Bronchiectasis

Jan Dik¹, Melda Sağlam¹, Naciye Vardar Yağlı¹, Cemile Bozdemir Özel¹, Ebru Çalık Kütükcü¹, Deniz İnal İnce¹, Hazal Sonbahar Ulu¹, Aslıhan Çakmak¹, Haluk Tekerlek¹, Hülya Arıkan¹, Sanem Eşref², Deniz Doğru Ersöz²

¹Department of Physiotherapy and Rehabilitation, Hacettepe University School of Health Sciences, Ankara, Turkey

²Department of Pediatric Pulmonology, Hacettepe University School of Medicine, İhsan Dogramaci Children's Hospital, Ankara, Turkey

Objectives: Reaction time is a feature that determines the duration of the first muscular reaction or movement initiation of a person against the stimulus. A good reaction time allows us to be agile and effective in responding to stimuli and situations. In this study, it was aimed to investigate the relationship between reaction time, exercise capacity and balance in children with bronchiectasis.

Methods: Seventeen patients with bronchiectasis between 6 and 18 years were included in the study. Pulmonary function test parameters were determined using spirometry. "Fitlight Trainer (TM) " was used to evaluate the reaction time and the time to act. During this test, 6 led lights placed at a specific point on the wall are turned on in random order. The patient was asked to turn off a total of 29 led lights as quickly as possible. Total and average scores were determined in seconds. Exercise capacity was assessed by the incremental shuttle walking test (ISWT). Functional reach test was performed in balance evaluation

Results: Patients participating in the study had mild to moderate obstruction (mean FEV1: 89.57±22.04%). The mean duration of reaction time was significantly correlated with ISWT distance (r=-0.601, p=0.014), dyspnea perception after exercise test (r=0.621, p=0.01) and functional reach test distance (r=-0.525, p=0.037).

Conclusions: Increased reaction time is associated with decreased exercise capacity, increased dyspnea perception during exercise, and impaired balance in children with bronchiectasis. The reaction time may provide an input for exercise programs aimed at improving the performance of patients with bronchiectasis.

Keywords: Bronchiectasis, reaction time, exercise tolerance

[Abstract:0659] PS-267 [Accepted:Poster Presentation] [Sleep-related Disorders]

A Novel Mouthpiece Device Design for the Treatment of Obstructive Sleep Apnea

Sefa Zülfikar¹, Ceyda Erel Kırıçoğlu², Alp Dinçer², Albert Güveniş¹, Özgür Kocatürk¹

¹Institute of Biomedical Engineering, Boğaziçi University, İstanbul, Turkey

²Acıbadem University, İstanbul, Turkey

Objectives: Continuous positive airway pressure (CPAP) devices are considered as the first line therapy for obstructive sleep apnea syndrome (OSAS). However, there is an increasing tendency to use oral appliance as an alternative treatment due to poor patient compliance of CPAP devices. The most commonly used techniques to evaluate the efficacy of the novel oral appliances in the treatment of OSAS are magnetic resonance image segmentation of upper airway structures and polysomnographic variables. This study aims to evaluate the efficacy of a novel mouthpiece device on patients with OSAS by the comparison of oropharyngeal volume and polysomnographic variables with and without the device. The proposed mouthpiece device design increases intraluminal pressure by using patients' own breath while reshaping the lower jaw and tongue position.

Methods: Each patient underwent magnetic resonance imaging (MRI) of the upper airway during wakefulness at baseline and with the novel mouthpiece device. Since the proposed novel mouthpiece device design allows patient to breathe orally, the oropharyngeal volume change has been evaluated instead of the velopharyngeal volume. The oropharyngeal volumes of the participants have been reconstructed as 3D models from the acquired MRI images. Afterwards, each patient attended the sleep laboratory (Kozyatağı Acıbadem Hospital, İstanbul, Turkey) on two nights with and without the novel mouthpiece device for full diagnostic polysomnography.

Results: The results (current n=12) show that the use of proposed device enlarged the oropharynx volume 27% on average while reducing the apnea hypopnea index by 44% on average. On the other hand, the polysomnographic variables have been significantly improved by the use of novel mouthpiece device. The oxygen desaturation index reduced 27.5% on average. Lowest oxygen saturation values improved 4.2% on average.

Conclusion: The clinical results show that the proposed mouthpiece design offers a promising alternative oral appliance for OSAS patients.

Keywords: Sleep apnea, mouthpiece, oral appliance, treatment, sleep disorder, polysomnography

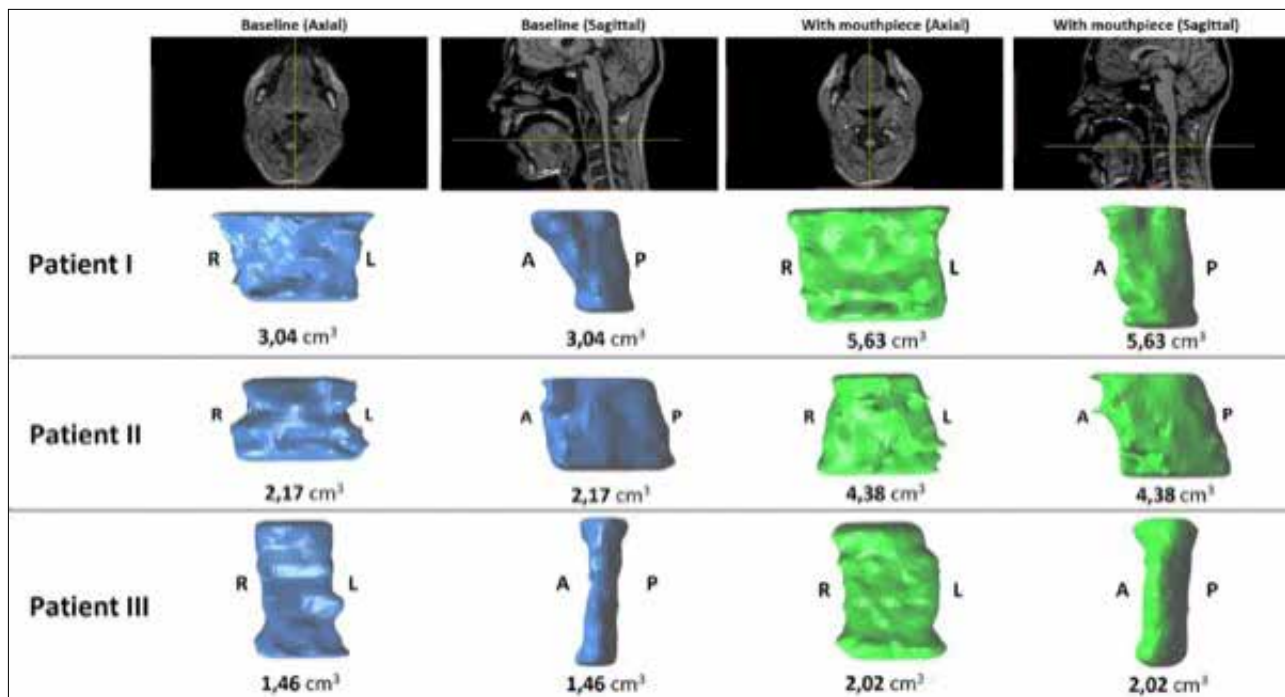


Figure 1. Comparison of the oropharyngeal volumes which is segmented from the images acquired by Magnetic Resonance Imaging

Table 1. Polysomnography results

Severity	Status	MILD (n: 4)			MODERATE (n: 3)			SEVERE (n: 5)		
		Diagnose	Treatment	% Change	Diagnose	Treatment	% Change	Diagnose	Treatment	% Change
	Total Sleep Time (min)	317,0	314,4	-0,8%	414,7	303,8	-26,5%	308,7	297,1	-3,8%
	Sleep Efficiency (%)	88,3%	91,3%	3,4%	91,3%	86,2%	-5,5%	79,8%	81,5%	2,1%
	Respiratory Disturbance Index (events/h)	10,0	3,9	-60,9%	20,3	11,1	-44,8%	50,1	39,3	-21,9%
	Oxygen Desaturation Index (events/h)	4,8	2,8	-41,0%	8,9	4,3	-51,9%	34,1	35,2	3,2%
	REM RDI	23,9	11,4	-52,3%	6,0	11,0	81,8%	37,5	39,3	4,8%
	NREM RDI	8,2	2,8	-66,4%	30,8	10,3	-66,7%	52,3	39,7	-24,1%
	Supine RDI	16,0	5,7	-64,1%	59,0	19,6	-66,7%	69,9	47,5	-32,0%
	Non-Supine RDI	16,0	8,2	-49,1%	7,0	6,7	-4,7%	60,0	41,7	-30,5%
	Mean Oxygen Saturation	95,5%	95,8%	0,3%	96,4%	95,7%	-0,7%	93,5%	93,8%	0,3%
	Lowest Oxygen Saturation	87,8%	89,3%	1,7%	80,0%	89,7%	4,2%	78,8%	81,2%	5,6%
	T90 (min)	1,0	0,4	-64,4%	2,1	0,6	-71,8%	18,0	11,2	-37,5%
	Oropharyngeal Volume (cm³)	3,1	4,3	39,0%	4,3	5,2	20,8%	2,5	3,0	20,2%

[Abstract:0660] PS-306 [Accepted:Poster Presentation] [Respiratory Infections]

Eoziofilic Pnemonia Resulted from Suboxone Utilization

Hatice Çetindoğan, Nesrin Öcal, Ergün Uçar, Cantürk Taşçı

Department of Chest diseases, Gülhane Training and Research Hospital, Ankara, Turkey

Introduction: Eosinophilic lung diseases is a large group of diseases accompanied with increased blood or tissue eosinophilia. In addition to idiopathic forms, infectious agents, some systemic diseases, and eosinophilic pneumonia caused by various drugs are also evaluated within this disease group. Suboxone is an opioid-derived drug consisting of buprenorphine and naloxone combination and is used in the treatment of heroin dependence and thus, is addictive and purchased with red prescription. A limited number of data is available in the literature on peroxycarbonylation of Suboxone.

Case Presentation: In the thorax HRCT of a 30-year-old man with a history of ongoing cough for the last week, back and chest pain, mild fever, fatigue and shortness of breath, it was revealed that diffuse pneumonic infiltration areas accompanied with ground glass areas in the left lower lobe were present. In laboratory tests, while WBC was 14.960 (Neutrophil 77.6%) and CRP was 174, other laboratory values were measured within normal limits. In physical examination, sub-febrile fever and mild coarseness of respiratory sounds were present. The patient started receiving treatment with the diagnosis of pneumonia. HRCT was performed during his control. In the second HRCT, it was observed that previous infiltrations disappeared, but in right middle lobe and lower lobe of the lung, newly developed infiltration areas accompanied with about 1x2 cm in diameter subcranial and the lower paratracheal adenopathy areas were seen. There were no significant changes in laboratory and clinical findings. Therefore, the patient underwent diagnostic EBUS and FOB procedures. TBIA was performed in mediastinal adenopathy areas and from the infiltrated parenchymal area TBB was performed. Approximately 20 days later, his new chest X-ray revealed a newly developed pleural effusion and perforated eosinophilia. In the pleural fluid tests, it was found that the pleural fluid was exudative and in the cell count WBC was 11.71 and eosinophil was 69,3% (eosinophil: 8,04). During this process, it was observed that mediastinal lymph node samples in the pathology results were found to be normal tissue and TBB was reported as inflammation results including eosinophils. During the last visit of the patient, his complete blood count and peripheral spread tests revealed peripheraleosinophils. Tests were deepened in terms of Pulmureosinophilis endomorphs. No parasites were detected in the stool. In this context, the anamnesis of the patient who had declared that he used to be a heroin addict got deepened and it was learned that he applied to AMATEM (Alcohol/ Substance Addiction Research and Treatment Center) because of his heroin addiction and he had been using suboxone for 2 years. As a result of all the tests and the acquired rheumatology, hematology, immunology, infectious diseases and neurology consultations, the patient was initiated on methylprednisolone at a dose of 0.5 mg/kg/day based on the diagnosis of eosinophilic pulmonary

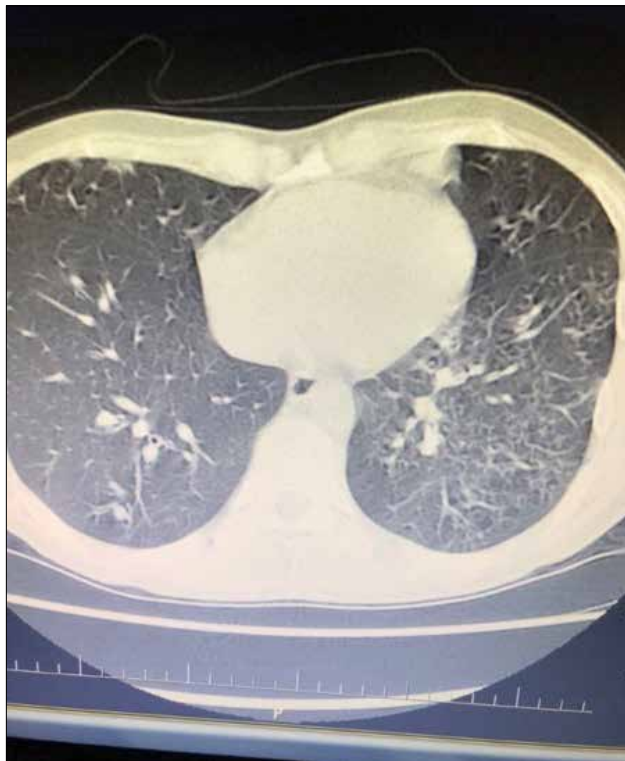

Figure 1. HRCT at admission. Admission to the clinic for pneumonia

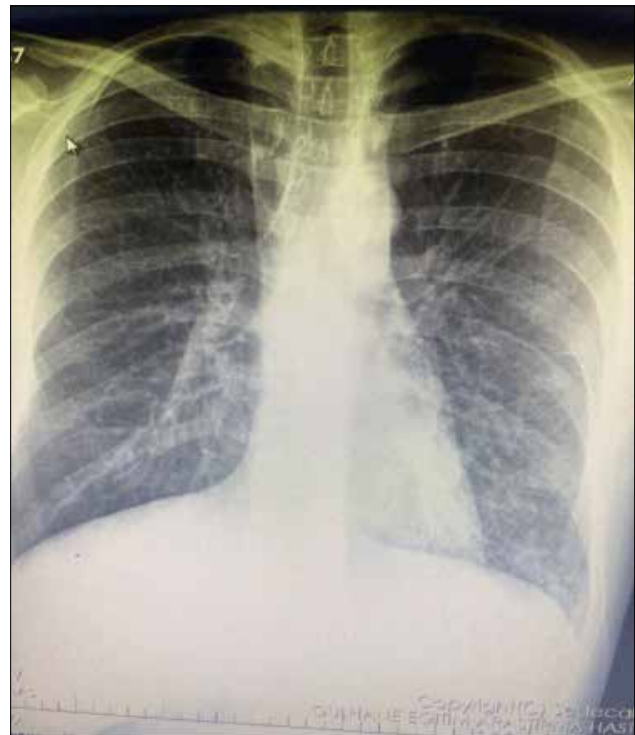

Figure 2. Chest radiography after methylprednisolone. Control after diagnosis and treatment

disease resulted from medication. It was observed that the peripheric eosinophilia disappeared and the pleural effusion decreased significantly after 15 days of treatment.

Conclusion: It was reported that the etiologic cause of the diagnosis of eosinophilic pulmonary disease was the use of suboxone after a detailed anemnesis. This case is the first eosinophilic pulmonary disease case in the literature that was resulted from the use of suboxone.

Keywords: Eosinophilic pneumonia, pleural effusions, suboxone.

[Abstract:0663] PS-027 [Accepted:Poster Presentation] [Clinical Problems - Diffuse Parenchymal Lung Disease]

Occasion of Oxaliplatin Toxicity

Özlem Ataoğlu¹, Merve Erçelik¹, Pınar Yıldız Gülhan¹, Onur Eşbah²

¹Department of Pulmonary Diseases, Düzce University School of Medicine, Düzce, Turkey

²Department of Internal Medicine, Düzce University School of Medicine, Düzce, Turkey

Introduction: Pulmonary toxicity due to cancer drugs is common. These drugs can cause a wide variety of syndromes including pneumonitis/fibrosis, noncardiogenic pulmonary edema and hypersensitive pulmonary disorders. Oxaliplatin is a third generation platinum analogue; an effective chemotherapeutic and highly preferred in oncology, used in gastric, pancreatic and colorectal cancers. We presented this case because lung toxicity due to oxaliplatin is rare.

Case Presentation: 40 years old female patient admitted to emergency with dyspnea. The patient diagnosed with colorectal cancer for five months and two weeks ago she has had third chemotherapy cure with oxaliplatin/capecitabine. The patient had no cough and sputum. On chest X-ray there was heterogeneity in left upper and middle zone (Figure 1). The fingertip oxygen saturation in room air was %70. Thorax computerized tomography showed that ground glass densities at left upper anterior lobe, lingula and lower superior lobe. In posterobasals linear density thickening with pleural extensions which were prominent on the left were observed (Figure 2). There is no clinical findings and laboratory results for infection. The patient has been considered pulmonary toxicity due to drugs after exclusion of infection. The patient hospitalized and 1mg/kg methylprednisolone therapy was started. On the 6th day of hospitalization, which completely regressed in dyspnea and recovered the hypoxemia in the arterial blood gas and the heterogeneity disappeared in the X-ray graphy (Figure 1) of patient steroid treatment (will have completed 1 month) regulated and discharged.

Conclusion: Chemotherapeutic agents like oxaliplatin can cause pulmonary diseases. Drug toxicity should be considered in chemotherapeutic treatment patient with acute dyspnea.

Keywords: Colorectal cancer, oxaliplatin, toxicity

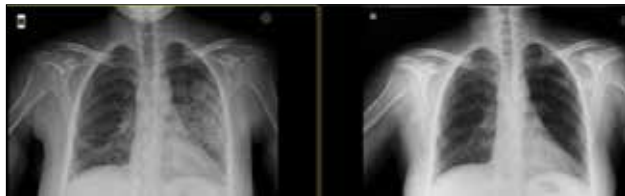


Figure 1.

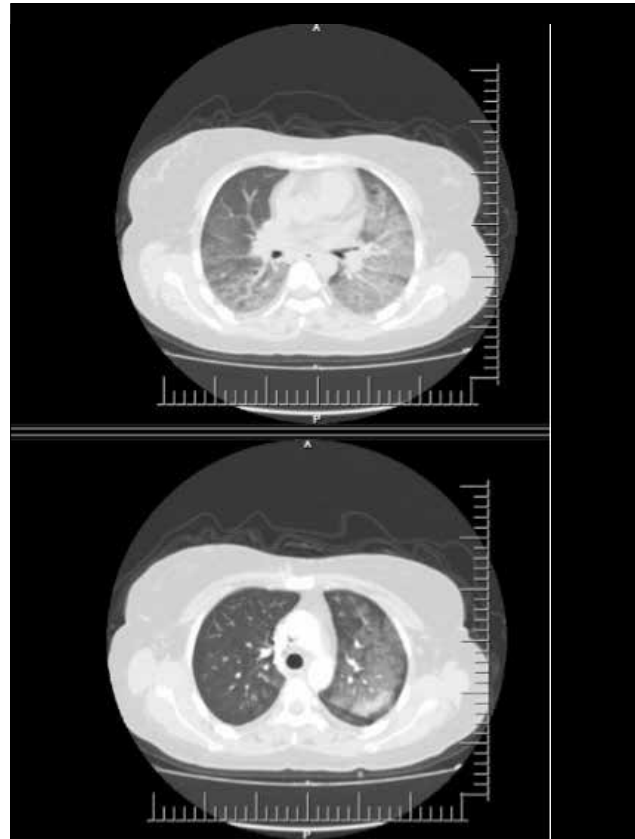

Figure 2.

[Abstract:0665] SS-044 [Accepted:Oral Presentation] [Sleep-related Disorders]

Evaluation of Left Ventricular Functions in Obstructive Sleep Apnea Syndrome (OSAS) Patients without Cardiac Co-Morbidity

Burcu Oktay Arslan¹, Hikmet Fırat², Ramazan Akdemir³

¹Health Sciences University, Dr.suat Seren Chest Diseases and Thoracic Surgery Training and Research Hospital, İzmir, Turkey

²Health Sciences University, Dışkapı Yıldırım Beyazıt Training and Research Hospital, Ankara, Turkey

³Department of Cardiology, Sakarya University School of Medicine, Sakarya, Turkey

Objectives: It is suggested that obstructive sleep apnea syndrome (OSAS) may affect myocardial functions without a significant cardiac disease and hypertension. In this study, we aimed to evaluate left ventricular functions in OSAS patients who were excluded from hypertension and cardiac co-morbidities.

Methods: Forty patients with OSAS pre-diagnosis who presented themselves to our sleep laboratory were included in the study. The patients didn't have a cardiac disease history and risk factors. Furthermore, the coronary artery disease was excluded with myocardial infarction scintigraphy and the patients were diagnosed with OSAS after polysomnographic (PSG) tests. Sixteen patients with no cardiac disease history and risk factors and who were excluded from OSAS diagnosis by PSG tests constituted the control group. Two-dimensional transthoracic echocardiographic examination was performed on all patients. Routine biochemical examinations were performed. Between the patient and control groups, the differences in terms of echocardiographic parameters and the relationship between sleep parameters and echocardiographic results were evaluated.

Results: 56 cases (16 females, 40 males) were included in the study. There was no significant difference between the patient and control groups regarding age, gender, tobacco use, body mass index (BMI) ($p > 0.05$). When echocardiographic (ECG) parameters were evaluated, it was reported that LVIDD (Left Ventricular Internal Dimension In Diastole) ($p = 0.01$), left atrium diameter (LAD) ($p = 0.008$), aortic diameter (AD) ($p = 0.006$) and stroke volume (SV) ($p = 0.03$) were higher in OSAS patient group compared to control group. In the correlation analysis test, no correlation was reported among AHI and LVIDD, LAD, SV and AD ($p > 0.05$). However, a weak but significant correlation was found between desaturation period in sleep below 90% with LVIDD ($p: 0.02$, $r: 0.347$) and SV ($p: 0.01$, $r: 0.376$).

Conclusion: In patients with OSAS, left ventricular diastolic functions can be affected without hypertension and coronary artery disease. Diastolic dysfunction appears to be related to the duration of hypoxic sleep. Patients diagnosed with diastolic dysfunction using ECO but with no additional cardiac problems should be evaluated for OSAS.

Keywords: Obstructive apnea, diastolic dysfunction, echo

[Abstract:0667] PS-305 [Accepted:Poster Presentation] [Pulmonary Pathology]

Sclerosing Pneumocytoma: An Extremely Rare Case

Yurdanur Süllü¹, Yasemin Büyükkarabacak², Seda Koç¹

¹Department of Pathology, Ondokuz Mayıs University School of Medicine, Samsun, Turkey

²Department of Thoracic Surgery, Ondokuz Mayıs University School of Medicine, Samsun, Turkey

Introduction: Sclerosing pneumocytoma is a rare tumor initially described by Liebow and Hubbel. It is seen in middle-aged women. It is a benign tumor that grows slowly and expansively. However, in a small number of cases metastasis has been reported. The differential diagnosis includes inflammatory pseudotumor, clear cell tumor, metastatic carcinoma and epithelioid hemangioendothelioma. We present a case of sclerosing pneumocytoma due to its rarity.

Case Presentation: Surgery was planned because of a slight increase in the lesion size in the control CT of a seventy-one-year-old female patient who had a 23x22 mm nodular lesion in the right lung mid-lobe PET CT during a year-long knee oper-

ation. Lobectomy was performed after the intraoperative evaluation resulted in low-grade adenocarcinoma suspicion. On the macroscopic examination of the right lung middle lobectomy material, a solid mass, 25x22x21 mm in size, separated from the lung parenchyma by smooth boundary was observed. On the microscopic examination, a tumor with solid and papillary hemorrhagic and sclerotic areas was observed. The cells covering the papillary structures on the surface were pronounced nucleolus, cuboidal shaped cells. Stromal cells were epithelioid-like, oval round nucleus eosinophilic, some with transparent cytoplasm. Superficial cells were stained positive with pancytokeratin and cytokeratin 7, whereas stromal cells stained negative with pancytokeratin and cytokeratin 7. EMA and TTF1 were positive in both cell types. More predominant staining was observed in stromal cells with estrogen and progesterone receptors. Ki 67 index was evaluated as 1%. No staining with SMA, S-100, thyroglobin and PAX 8 was observed.

Conclusion: Sclerosing pneumocystitis is a rare tumor and should be kept in mind in differential diagnosis especially in female patients.

Keywords: Sclerosing pnemocytoma, sclerosing hemangioma, TTF1

[Abstract:0668] SS-122 [Accepted:Oral Presentation] [Lung and Pleura Malignancies]

Relationship between Prognosis and Preoperative PET/CT FDG Involvement (SUVmax) in Operated Lung Cancer Patients

Aydan Mertoğlu¹, Ahmet Üçvet², Sami Deniz¹, Günseli Balcı¹, Kenan Can Ceylan¹, Nimet Aksel¹, Özgür Batum¹, Emel Tellioglu¹, Hakan Koparal³, Ali Kadri Çırak¹, Soner Gürsoy², Ufuk Yılmaz¹, Berna Kömürçüoğlu¹

¹Department of Chest diseases, Health Sciences University, İzmir Dr. Suat Seren Chest Diseases and Surgery Training and Research hospital, İzmir, Turkey

²Department of Chest surgery, Health Sciences University, İzmir Dr. Suat Seren Chest Diseases and Surgery Education and Research Hospital, İzmir, Turkey

³Department of Nuclear Medicine, Health Sciences University, İzmir Dr. Suat Seren Chest Diseases and Surgery Training and Research Hospital, İzmir, Turkey

Objectives: The aim of this study is to investigate the relationship between survival and preoperative PET/CT FDG involvement (SUVmax) in operated lung cancer patients.

Methods: We retrospectively reviewed pre-operative FDG-PET / CT performed cases who had been operated due to lung cancer between January 2011 and December 2011 in our hospital. Cases who had been operated due to recurrence/ metastasis, who had been diagnosed with Small Cell Lung Cancer (SCLC) and Carcinoid tumors, who had been performed segmentectomy/wedge, who were receiving neoadjuvant therapy, patients with pathologic stage 4 and cases with unspecified PET positive lesions were excluded from the study. Patients' demographic data, type of operation, location, pathologic stage, histologic type of tumor, surgical margin positivity, N status, tumor size and SUV max value of the primary mass were recorded and statistical analysis were carried out.

Results: A total of 104 (97 male, 7 female) patients were included in the study. The average age was 62.02±8.73, the primary tumor SUV max.average was 14.29±7.35, average tumor size was 4.02±2.08, and the follow-up duration was 58.26±25.24. PET SUV max value ≤ 10=27 cases, between 10-20=57 cases, and > 20=27 cases were detected. There was no significant difference in the survival time of the 3 groups who were divided according to their PET SUV max values (p=0.600). ROC analysis was carried out and Cox regression analysis was performed according to the value showing the best sensitivity and specificity (7.2). No effect of PET SUV max on length of life (p=0.24) was reported.

Conclusion: In patients with localized early stage NSCLC, the risk of recurrence and distant metastasis after surgery is high. The researches have shown that the high SUV max, MTV and TLG values of the cases in PET/CT were positively correlated with local recurrence and mortality rates. In our study, in operated NSCLC patients the difference between primary mass average SUVmax value and the prognosis was not reported as statistically significant.

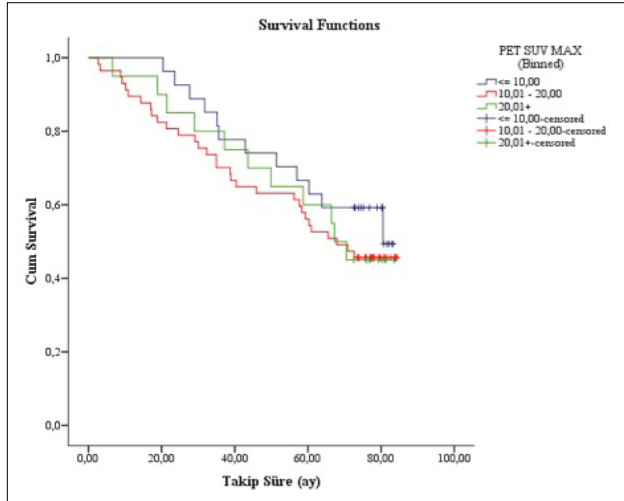


Figure 1. Kaplan-Meier Curve. 3 group analysis according to PET SUVmax (p=0.60)

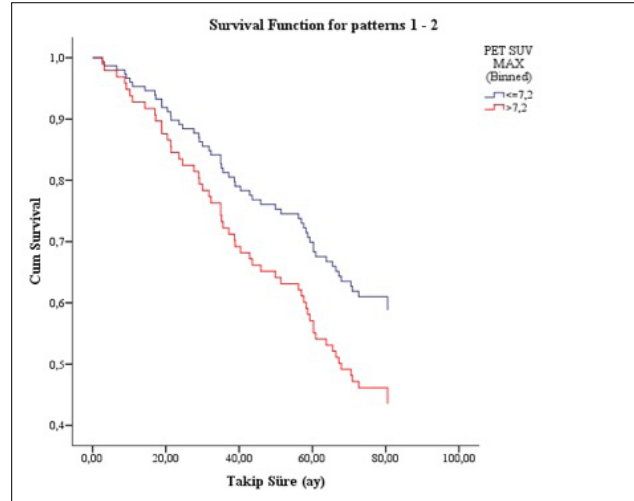


Figure 2. Cox regression analysis. Effect of PET SUVmax on lifetime (p=0.24)

[Abstract:0669] EPS-208 [Accepted: E-Poster] [Thoracic Surgery]

Congenital Esophageal Duplication Cyst: A Rare Cause of Dysphagia in Adults

Mehmet Oğuzhan Özyurtkan¹, Gökhan Çakıroğlu², Gökhan Çipe³, Esin Oğul⁴, Arif Acar⁵

¹Department of Thoracic Surgery, Medicana International İstanbul Hospital, İstanbul, Turkey

²Department of Pathology, Medicana International İstanbul Hospital, İstanbul, Turkey

³Department of General Surgery, Medicana International İstanbul Hospital, İstanbul, Turkey

⁴Department of Pulmonology, Medicana International İstanbul Hospital, İstanbul, Turkey

⁵Department of Gastroenterology, Medicana International İstanbul Hospital, İstanbul, Turkey

Esophageal duplication cyst accounts for 10-15% of all congenital duplication cysts involving the GI tract. Majority of these cysts are diagnosed in childhood. They are very rare in adulthood and are mostly asymptomatic when present. A 36 year-old male patient presented with progressive dysphagia for the last 4 to 5 months. Endoscopic investigation revealed a 4x2cm lesion at the distal esophagus to the Z line, which was protruding to the lumen with a normal mucosal layer. Chest BT and MRI investigations demonstrated that the lesion was originating from esophagus and cystic in nature. The patient underwent total cyst excision via minithoracotomy. The lesion was found to originate from the esophageal wall, between the muscle layers. The postoperative course of the patient was uneventful. He was discharged on the 5th postoperative days. Histological examination showed boundless smooth muscle cells with a collagenous stroma within the cyst wall. The internal surface

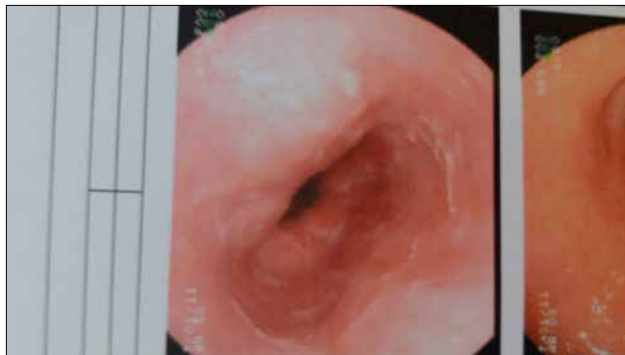

Figure 1. Endoscopic view of the lesion

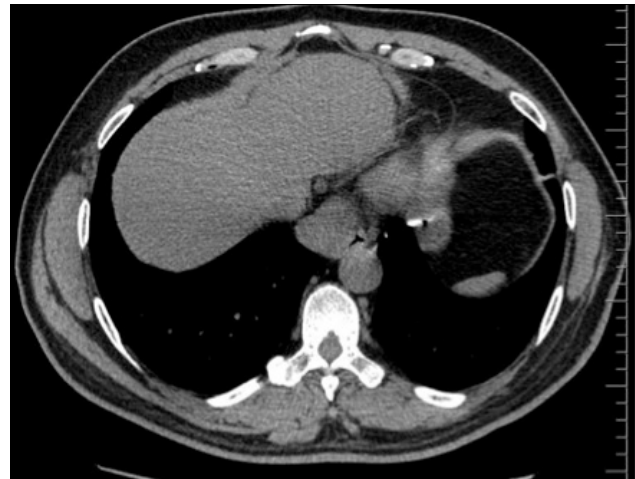

Figure 2. Chest CT demonstrating the lesion

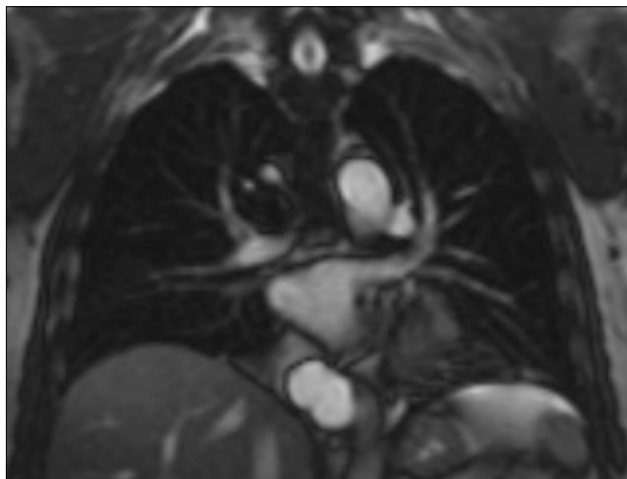


Figure 3. MRI view of the lesion

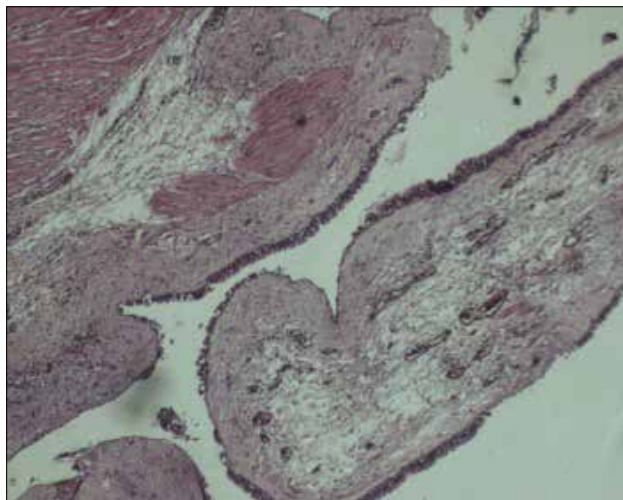


Figure 4. Pathological view of the lesion demonstrating ciliated epithelium and layers of esophageal muscles

was lined with a ciliated epithelium. Based on these data, a final diagnosis of a foregut duplication cyst was established.

The patient had no dysphagia and other problems during the follow-up of 1 year. Esophageal duplication cysts are rare and mostly asymptomatic in adults. But they can cause dysphagia, back pain, infection and can cause malignant transformation. Differential diagnosis include other cystic diseases such as bronchogenic cyst, hydatid cyst and neurogenic cyst. Treatment is complete surgical excision.

Keywords: Esophagus, dysphagia, duplication cysts

[Abstract:0670] EPS-047 [Accepted: E-Poster] [COPD]

Can Chitotriosidase Levels in COPD Patients be a Biomarker Leading to Clinical Worsening?

Selvi Aşker¹, Tijen Tanyalçın²

¹Department of Chest diseases, Van Yüzüncü Yıl University, Van, Turkey

²Tanyalçın Medical Laboratory Selective Screening and Metabolism Unit, İzmir, Turkey

Objectives: Although there is no chitin in human body, interestingly there are chitinase enzymes such as chitotriosidase which can break chitin down. Although the physiological function of chitotriosidase is not yet known, recent findings indicate that it interferes with the mechanisms related to the immune response and inflammatory process and also plays a role in host defense against chitin-containing pathogens. The main source of increased serum chitotriosidase activity is activated macrophages. Tumor necrosis factor- α (TNF- α), lipopolysaccharide, prolactin, macrophages; granulocyte-macrophage colony-stimulating factor (GM-CSF) stimulate the release of both macrophages and chitotriosidase. Chitotriosidase activity is elevated in the diseases in which activated macrophages and neutrophils play a role in pathogenesis. Chitin is an important component of insects, fungi and house dust mites. The presence of chitin breaking enzyme "chitotriosidase" in patients with COPD attacks may suggest such triggers that trigger inflammation.

Methods: Blood chitotriosidase levels were studied in 20 patients with severe type 2 respiratory insufficiency who were admitted to the department of chest diseases due to COPD attacks.

Results: Of the patients, chitotriosidase levels were detected above the limit superior of 44 nmol/mL/h in 12 patients (60%) (59,62 \pm 53,196 SD). The chitotriosidase level in 4 patients was above 100 nmol/mL/h. A positive correlation was reported between chitotriosidase levels and number of attacks in a year, number of hospitalization, partial CO₂ value, duration of illness, length of hospital stay and C-reactive protein (p<0.005).

Conclusion: Serum chitotriosidase activity may be a useful indicator of macrophage/phagocyte activation. Considering the limitations, 8% of the Turkish society suffer from chitotriosidase deficiency. It can be considered as a useful biochemical parameter in treatment activities monitoring and diagnosis of diseases in which mycophageal/phagocyte activation

is involved in the pathogenesis or the investigation of disease mechanisms. It is known that pulmonary fibrosis develops in mice with excess lung chitinase activity. It has been shown that patients with interstitial lung disease associated with pulmonary fibrosis due to telomer dysfunction have excessive amounts of chitin polymers in the airways. In lung diseases characterized by epithelial cell dysfunction such as COPD, chitin cleansing may worsen the fibrogenic pathways. Chitotri-oxidase may contribute to lung remodeling by contributing to lung fibroblasts. Chitotrioxidase may be a new biomarker for the survival of COPD patients.

Keywords: Chitotrioxidase, COPD, Lung

[Abstract:0671] PS-095 [Accepted:Poster Presentation] [Pulmonary Rehabilitation and Chronic Care]

The Comparison of Quadriceps Muscle Strength, Functional Tests and Quality of Life in Asthmatic Children and Adolescents with Low and High Grip Strength

İsmail Özsoy¹, Aylin Tanrıverdi¹, Buse Özcan Kahraman¹, Serap Acar¹, Nazenin Hande Sezgin¹, Karya Polat¹, Aslı Papurcu¹, Gizem Atakul², Nevin Uzuner², Suna Asilsoy², Özkan Kahraman², Sema Savcı¹

¹School of Physical Therapy and Rehabilitation, Dokuz Eylül University, İzmir, Turkey

²Department of Child Health and Diseases, Dokuz Eylül University, İzmir, Turkey

Objectives: Grip strength is used as an indicator of general muscle strength. It has been shown that grip strength can be affected by asthma. There are no studies comparing quadriceps muscle strength, functional tests and quality of life in asthmatic patients with low and high grip strength. Therefore, the aim of our study is to compare quadriceps muscle strength, functional tests and quality of life in asthmatic children and adolescents with low and high grip strength.

Methods: The study included 44 asthmatic children and adolescents aged between 8 and 16 years, who were admitted to Dokuz Eylül University Hospital Children's Health and Diseases Department. Participants' demographic and clinical information was recorded. Pulmonary functions were assessed with spirometer. The grip and quadriceps muscle strength were assessed. Functional tests which are Six Minute Walking Test (6MWT) and Timed Up and Go (TUG) are performed. The quality of life was questioned by the Pediatric Asthma Quality of Life questionnaire. Asthmatic children and adolescents were divided into two groups according to the percentage of their grip strength (below 80% low grip strength and above 80% high grip strength). The Mann Whitney U Test was used to compare between the groups.

Results: Demographic information (age, sex, body mass index) of the two groups were similar ($p>0.05$). The median value of the asthma control test result for both groups was 25. There was no difference in corticosteroid use between groups ($p>0.05$). Pulmonary function parameters were similar between the two groups ($p>0.05$). Quadriceps muscle strength and percentage of the group with low grip strength is significantly lower than the group with high grip strength ($p=0.02$, $p=0.03$, respectively).

In the group with low grip strength, the 6MWT distance and percentage were significantly lower ($p=0.002$, $p=0.01$) while the completion time of TUG test was significantly longer ($p<0.001$). The quality of life was lower the group with low grip strength than the group with high grip strength ($p=0.03$).

Table 1. Participants' demographic and clinical characteristics

	Group with Low Grip Strength (n=22)	Group with High Grip Strength (n= 22)	p
Age (years)	11.00 (9.00-14.00)	11.50 (10.00-14.25)	0.462
Gender (Girl/Boy)	9/13	5/17	0.195*
BMI (kg/m ²)	20.50 (17.75-23.50)	21.00 (16.75-23.25)	0.663
Asthma Control Test (0-25)	25 (21-25)	25 (25-25)	0.082

BMI: Body Mass Index; Mann Whitney U Test; * Chi square test

Conclusion: Our study showed that quadriceps muscle strength, functional test results, and quality of life are lower in well-controlled asthmatic children and adolescents with low grip strength. In addition, the grip strength test is relatively inexpensive, easy to apply and a short time measurement. Thus grip strength in asthmatic children and adolescents can be used as a marker of quadriceps muscle strength, functional tests and quality of life in clinical practice.

Keywords: Asthma, children and adolescent, grip strength

[Abstract:0672] PS-116 [Accepted:Poster Presentation] [Pulmonary Rehabilitation and Chronic Care]

The Relationship Between Physical Fitness and Respiratory Muscle Function in Healthy Subjects

Sena Teber, Beyza Nur Karadüz, Melda Sağlam, Naciye Vardar Yağlı, Ebru Çalık Kütükçü, Deniz İnal İnce, Hülya Arıkan

Department of Physiotherapy and Rehabilitation, Hacettepe University School of Health Sciences, Ankara, Turkey

Objectives: Health-related physical fitness includes, cardiorespiratory fitness, body composition, muscular fitness, balance and elasticity parameters. The level of physical fitness, which is an important marker for the lifestyle and health profiles of individuals; it may predict the risk of future chronic diseases. Respiratory muscle performance provides prospective information about the respiratory functions of individuals. For this reason, respiratory muscle performance is an important indicator in terms of affecting physical fitness. The aim of the present study was to examine the relationship between physical fitness parameters and respiratory muscle performance in healthy subjects.

Methods: Thirty subjects' (17F, 13M; mean age was 22.7 ± 1.72 years) demographic and physical characteristics were recorded. Respiratory muscle strength (RMS) was measured by mouth pressure device (maximal inspiratory pressure-MIP, maximal expiratory pressure-MEP) and respiratory muscle endurance (RME) was measured by respiratory muscle endurance test at constant threshold load (60% of MIP). Cardiorespiratory fitness using three-minute step test, muscular fitness using vertical jump test, trunk flexibility using flexion test, and balance using time up and go test (TUG) were evaluated. The body composition of individuals was determined by body mass index (BMI).

Results: According to analysis, there was a strong significant relationship between RME and three minute-step test ($r=0.673$; $p=0.01$). While RMS (MIP and MEP both) showed moderate correlation with BMI ($p<0.01$) and vertical jump test ($p<0.01$), it showed weak correlation with TUG ($p<0.04$). There was no significant relationship between RME and BMI, TUG and flexibility ($p>0.05$).

Conclusion: In the result of the current study, muscle strength and muscle endurance were positively correlated with cardiorespiratory fitness and muscular fitness. These findings highlight that it is important to develop respiratory functions as well as health-related physical fitness parameters in the prevention of chronic diseases.

Keywords: Cardiorespiratory fitness, physical fitness, respiratory muscles

[Abstract:0673] PS-057 [Accepted:Poster Presentation] [Lung and Pleura Malignancies]

Is Stereotactic Body Radiotherapy An Alternative to Surgery in Early Stage Non Small Cell Lung Cancer

Gökhan Yaprak, Naciye Işık, Bedriye Doğan Akaslan

Department of Radiation Oncology, University of Health Sciences Kartal Dr. Lütfi Kırdar Training and Research Hospital, İstanbul, Turkey

Objectives: This study aimed to determine local control and overall survival of patients with medically inoperable early-stage non-small cell lung cancer treated with stereotactic ablative radiotherapy.

Methods: A total of 52 patients [7 (13%) females and 45 (87%) males] with medically inoperable early-stage non-small cell lung cancer and who were treated with stereotactic ablative body radiotherapy (SBRT) by a Cyber Knife robotic radiotherapy machine between 2009 and 2017 were evaluated retrospectively. Depending on tumor size and location, median 45 Gy (30-60 Gy) radiotherapy has been delivered in median 3 fractions (3- 5 fractions) to PTV. As regards the tumor-tracking system, X-Sight lung tracking system was used in 43 (83%) patients, gold fiducials in 4 (8%) patients, and X-Sight spine tracking system in 5 (9%) patients.

Results: The median age of patients was 66.5 (54-86) years. The Karnofsky performance score of 41 (79%) and 11 (21%) patients were 80-100 % and 60-80%, respectively. Tumor was staged as cT1 in 39 (75%) patients and cT2 in 13 (25%) patients. Histopathological distribution of 43 cases diagnosed histologically was as follows; 12 adenocarcinoma, 20 squamous cell carcinoma, and 11 non-small cell lung cancer with no subtyping 9 cases with no tissue diagnosis had radiologically and metabolically progressed mass which could not undergo biopsy. Median follow up was found to be 23 months (10-84 months). Median survival time was 38 months and 1-3-5 year survival rates were respectively 94%-53%- 33.6%. Locoregional recurrence occurred in 8 (15%) patients and recurrence was only local in 4 (8%) patients, while it was only regional in 3 (6%) patients. During follow up, local and distant recurrence was detected in 27 (52%) cases and median progression free survival was found to be 12 months. Grade 3 toxicity was observed in only one patient; no grade 4-5 toxicity was observed.

Conclusion: A high local control rate with no major toxicity was obtained by stereotactic ablative body radiotherapy in the patients with medically inoperable early-stage non-small cell lung cancer. In the near future, SBRT may be an alternative that has growing evidence to support comparable outcomes in selected stage I patients.

Keywords: Stereotactic body radiotherapy, surgery, non-small cell lung cancer

[Abstract:0679] EPS-150 [Accepted: E-Poster] [Respiratory Infections]

A Case of Nephrotic Syndrome with Pneumocystis Jiroveci Infection

Merve Erçelik¹, Gül Akın², Kürşad Öneç², Fuat Aytekin¹, Özlem Ataoğlu¹, Mehmet Fatih Elverişli¹

¹Department of Pulmonary Diseases, Düzce University School of Medicine, Düzce, Turkey

²Department of Internal Medicine, Düzce University School of Medicine, Düzce, Turkey

We were consulted because a desaturation developed in a 26-year-old male patient who was admitted to the nephrology department due to hypervolemic hyponatremia. He has been diagnosed with collapsing glomerulonephritis in 2016. In his application he was using cyclosporine and prednisolone. Cyclosporine was stopped due to cyclosporin toxicity which causes hyperpotasemia and hypertension progression of renal dysfunction. In the respiratory system examination, bilateral subscapular area breathing sounds were found to be decreased. Postero-anterior chest X-ray (PA AC) left cardiophrenic sinus was blunted. In the blood gas, PO₂ was found to be 53 mmHg and the Alveola-arterial gradient was found to be increased to 52.75. Diuretic therapy was given considering that it was secondary to hypervolemia. The patient was receiving fluconazole and ampicillin-sulbactam treatment for the cause of oral candidiasis. When cervical lymphadenopathy infection was considered, metronidazole was added to the antibiotherapy. The antibiotherapy of the patient with febrile height was changed to piperacillin-tazobactam (3x2.25gr), trimethoprim-sulfamethoxazole (TMP-SMZ) (2x800mg), acyclovir (1x800mg). High Resolution Computerized Tomography was performed, when re-consultation was taken on because of deepening hypoxemia, due to PA AC heterogeneous opacity increase of bilateral perihilar, more intense on the right; Bilateral pulmonary alveolar frosted glass densities and consolidation areas, bilateral hemorrhagic pleural effusion and

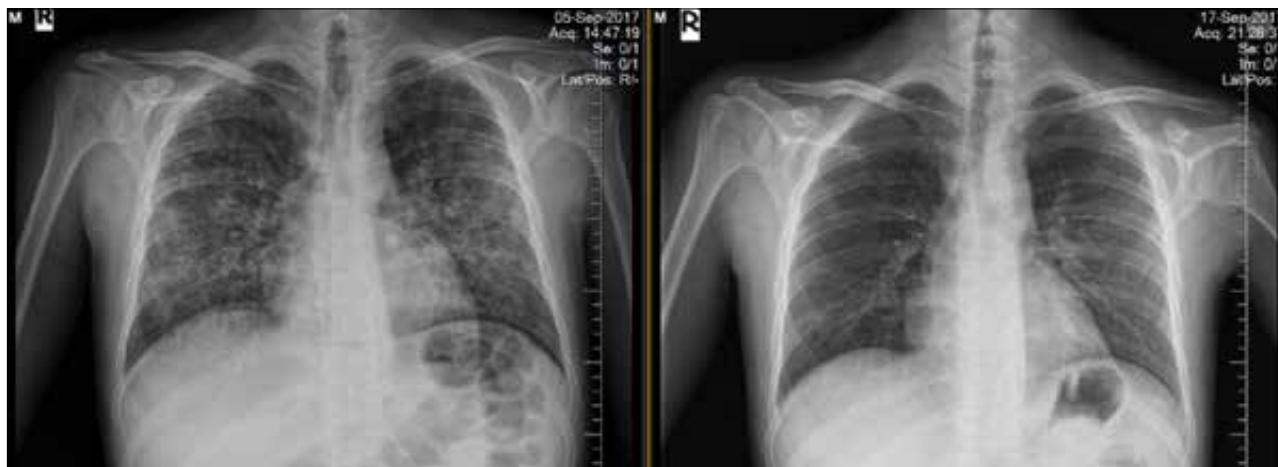

Figure 1. Pre and Post Treatment PA AC

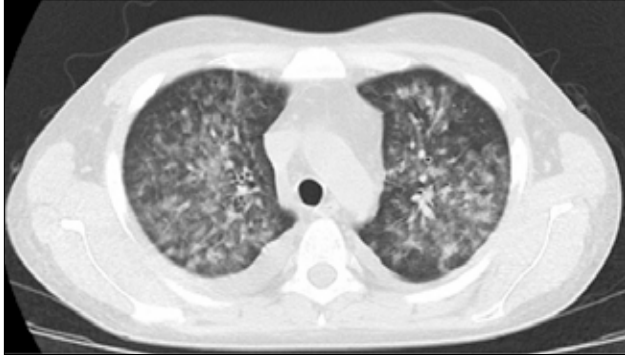


Figure 2. HRCT

widespread free circulation within the abdomen were observed. *Pneumocystis jiroveci* (PCP) infection was suspected in these findings. Flexible bronchoscopy was performed on the patient. PCP was detected in lavage culture. In there cytology were degenerate reactive bronchial epithelia, foamy macrophages, crescent microorganisms on the foamy-fibril floor in some foci between the lymphocytes. The patient underwent a TMP-SMZ (3x7.5 mg/kg) dose. As a result of antibiotics for 7 days, patients without hypoxemia in room air were discharged. TMP-SMZ treatment was completed in 14 days.

Keywords: *Pneumocystis jiroveci*, collapsing glomerulonephritis, nephrotic syndrome

[Abstract:0680] EPS-199 [Accepted: E-Poster] [Thoracic Surgery]

Congenital Cystic Adenomatoid Malformation in An Adult: A Rare Case

Mehmet Oğuzhan Özyurtkan¹, Gökhan Çakıroğlu², Zeliha Arslan Ulukan³, Uğur Temel⁴

¹Department of Thoracic Surgery, Medicana International İstanbul Hospital, İstanbul, Turkey

²Department of Pathology, Medicana International İstanbul Hospital, İstanbul, Turkey

³Department of Pulmonology, Medicana International İstanbul Hospital, İstanbul

⁴Department of Thoracic Surgery, Şişli Hamidiye Etfal Training and Research Hospital, İstanbul, Turkey

The incidence of congenital cystic adenomatoid malformation (CCAM) is 1/25000-35000, and mostl of the cases are diagnosed in the childhood period. A 42-year-old male patient presented with progressive dyspnea. He underwent tube thoracostomy 19 years ago due to righth pneumothorax. The pulmonary function test demontrated a lower FEV1 value. There was a hyperaeration on the right apical areas on the chest X-ray. Chest CT scan demonstrated multiple bullae of several diameters on the right upper lobe, as well as a nodular lesion. PET-CT demonstrated that the SUV-max value of the nodular lesion was 0.9. Right upper lobectomy was planned with a presumed diagnosis of bullous lung disease. The patient underwent right upper lobectomy and middle lobe wedge resection via thoracotomy. He developed prolonged air leak, and was discharged on postoperative day 9 with a Heimlich valve. The valve was taken out 5 days later. The pathological examination revealed multicystic lesions with part solid and necrotic areas. The cysts were lined with pseudostratified columnar epithelium ve were surrounded by fibromuscular tissue. The diagnosis was CCAM type 1. The nodular lesion was diagnosed as hamartoma. Dyspnea resolved and pulmonary function test results increased on the postoperative period of 5 months. The patient had no further complaints. Nearly 90% of the CCAM cases are diagnosed during the first years of life. They are very rare in the adult patients. The treatment is the complet surgical excision.

Keywords: Cystic malformation, lung, bullous disease

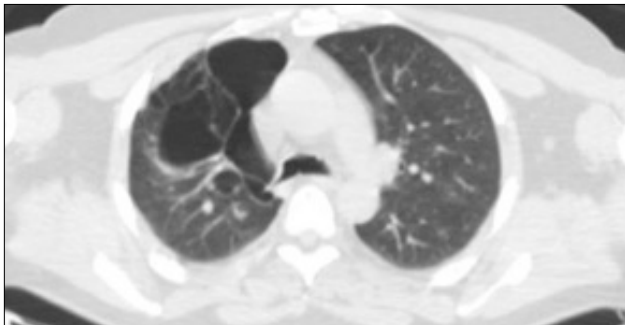


Figure 1. Chest CT demonstrating bullous lesion on the right upper lobe

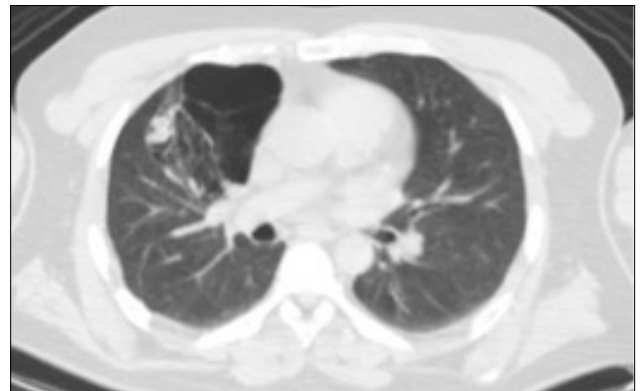


Figure 2. Nodular lesion close to the bullous lesion on chest CT

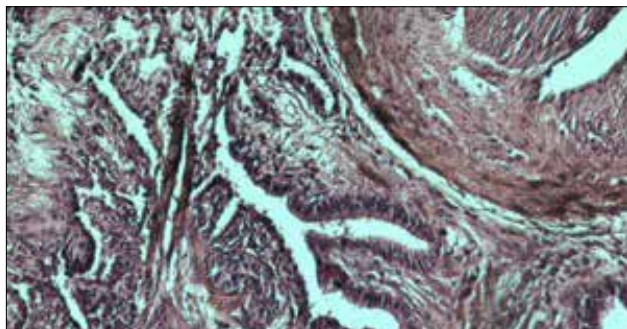


Figure 3. Pathological view of the cystic lesions and hamartoma

[Abstract:0682] SS-080 [Accepted:Oral Presentation] [Lung Transplantation]

Cases who Experienced Immunosuppressive Drug Replacement after Lung Transplantation

Sinan Türkkkan, Fatmanur Çelik Başaran, Mahmut Subaşı, Alkın Yazıcıoğlu, Mehmet Furkan Şahin, Ahmet Güngör, Erdal Yekeler

Health Sciences University, Turkey High Specialization Education and Research Hospital, Department of Chest surgery and Lung Transplantation, Ankara, Turkey

Objectives: Due to high dose of immunosuppressives used in lung transplantation (LT), opportunistic infections, malignancies, nephrotoxic and hematologic side effects are frequently encountered. We presented the results of our patients who experienced drug replacement due to various clinical conditions.

Methods: By retrospectively analyzing the data of LT patients, the FEV 1 level of creatinine after the immunosuppressive drug replacement was evaluated in terms of infection and malignancy.

Results: 42 Lung transplants were conducted between March 2013 and January 2018 in our institution. Of the patients, 8 (19%) patients were performed immunosuppressive replacement. In all cases, the average age was 45.9. The average follow-up period of the patients who underwent replacement was 4.1 months (1-10). In one patient, everolimus was added to the current treatment due to chronic rejection (CLAD), tacrolimus x everolimus replacement was performed in 1 patient due to frequent CMV infection, and in 2 patients due to creatinine increase. In 4 patients, MMF was discontinued and tacrolimus x everolimus replacement was performed due to malignancy. Since medication replacement was conducted in the last 2 months in 4 patients, data could not be evaluated. A patient who was started on everolimus treatment due to high creatinine level improved, but due to subsequent treatment for MAC and CMV infection, a slight elevation repeated. In the same patient, thrombocytopenia was observed that required everolimus linked replacement due to interaction with clarithromycin treatment given for MAC. In another patient who was started on everolimus instead of tacrolimus due to creatinine elevation, since therapeutic everolimus dose could not be reached due to non-healing oral aphtha, tacrolimus and everolimus doses were reduced and used together, and creatinine values were improved as desired. As a result of the control of the patient whom we performed drug replacement on due to PTLH, the size of the lesions decreased. Lesions improved in the patient diagnosed with CS.

Conclusion: Rejection rates after an LT are higher compared to other SOT, so immunosuppression level is high. Today, immunosuppressive therapy, which is accepted in lung transplantation, is followed by induction, and is usually continued with triple therapy consisting of Tacrolimus+MMF+Prednisolon. However, treatment with drugs such as tacrolimus and MMF, which specifically suppress cellular immunity, also allows for opportunistic infections and malignancies. Another side effect of tacrolimus that may affect the clinic is the elevation of creatinine. We are trying to minimize the side effects and rejection risk by modifying immunosuppressive treatment in various ways in cases of side effects and situations like CLAD, which is the most common late mortality cause of lung transplant. Examples include the removal of tacrolimus and MMF in the treatment of malignancy and the replacement of everolimus, in case of creatinine increase the use of everolimus in place of tacrolimus, or the use of lower doses of both drugs, the introduction of everolimus into the treatment in CLAD, cessation or reduction of certain immunosuppressive agents in recurrent or severe infections. By performing some timely medication replacements in our clinic, we believe we prevented the side effects' showing progression in patients.

Keywords: Lung transplant, infection, immunosuppressive treatment, malignancy, side effect

Table 1. Data of patients whose drugs were changed

Patient	Age (year)	Duration of follow-up after transplantation (month)	Time of drug change (month)	Changed drug	Duration of follow up after switching drug	FEV1 before and after change	CRE befor and after	Rejection	Infection	Diagnosis	Reason for change
Ş.S	37	46	36	Everolimus was added	10	1,81L/44-1, 26/31	1-0,8	CLAD progression	-	IPF+CLAD	CLAD
D.Y	61	27	26	Tak x Eve changei	1			-	-	COPD	Frequent CMV infection
H.H.S	52	24	18	Tak x Eve change	6	3,11 L/ 92%- 2,85L %86	1,7-1,2	-	-	COPD	Increased CRE
S.A	29	16	14	Tak x Eve change, cessation of MMF	2	1,80 L/ 47%- 1,82L/ %47	0,9-0,7	-	-	Silicosis	Development of malignancy (PTLH)
Z.Y	58	14	9	Tak x Eve change, cessation of MMF	5	1,80 L/ %56- 2,14 L/ %67	1,89-2,02 (received CT)	-	-	COPD	Development of malignancy (Kaposi's Sarcoma, KS)
K.U	51	9	4	Tak x Eve change	5	2,61 L/ %66- 2,51L/ %63	2,33- 2,20	-	For once, CMV inf, +MAC inf.	IPF	Increased Cre
Sv.A	44	7	5	Tak x Eve change, cessation of MMF	2	1,53/ %58- 1,75/ %67	0,7-0,8	-	-	IPF	Malignancy; adenoca in eksplant material
H.Ş	57	4	2	Tak x Eve change, cessation of MMF	2	2,37/ %63- 2,72/ %71	0,8-0,7	-	-	COPD	Malignancy; adenosquamous ca in eksplant material

[Abstract:0684] PS-089 [Accepted:Poster Presentation] [Pulmonary Rehabilitation and Chronic Care]

Investigation of Pulmonary Functions, Dyspnea, Peripheral Muscle Strength, Respiratory Muscle Strength and Endurance in Patients with Newly Diagnosed Hematologic Malignancy

Zeliha Çelik¹, Meral Boşnak Güçlü¹, Zübeyde Nur Özkurt²

¹Department of Physical Therapy and Rehabilitation, Gazi University School of Health Sciences, Ankara, Turkey

²Department of Hematology, Gazi University School of Medicine, Ankara, Turkey

Objectives: Assessment of disease-related symptoms in newly diagnosed hematologic malignant patients is important for the prognosis and treatment of the disease. In literature, side effects of treatments were investigated, but no study evaluated pulmonary functions, dyspnea, peripheral muscle strength, respiratory muscle strength and endurance in patients with newly diagnosed hematologic malignancies. The purpose of this study was to evaluate pulmonary functions, dyspnea, peripheral muscle strength, respiratory muscle strength and endurance in patients with newly diagnosed hematologic malignancy.

Methods: Twenty-three newly diagnosed hematologic malignant patients (40.87±12.32 years, 10M, 13F) and 20 healthy controls (36.05±12.27 years, 7M, 13F) were included. Pulmonary functions using spirometry, dyspnea using Modified Medical Research Council (MMRC) dyspnea scale, peripheral (upper and lower extremity) muscle strength using dynamometer, respiratory muscle strength using mouth pressure device and endurance using incremental threshold loading test (PowerBreath®) were evaluated.

Results: Patients' measured and percent predicted MIP ($p=0.016$, $p=0.006$), MEP ($p=0.012$, $p=0.009$), PEF ($p=0.015$, $p=0.012$); respiratory muscle endurance pressure* time ($p=0.043$) values were statistically significant lower compared with healthy controls ($p<0.05$). Patients' dyspnea scores ($p=0,053$) were statistically significant higher compared with healthy controls ($p<0.05$). Measured and percent predicted FVC, FEV1, FEV1/FVC, FEF25-75, shoulder flexors and abductors, knee extensors, hand grip strength were similar in groups ($p>0.05$).

Conclusion: Although pulmonary functions and peripheral muscle strength are preserved, inspiratory and expiratory muscle strength, respiratory muscle endurance are impaired in patients with newly diagnosed hematologic malignancies. Reduction in PEF may be associated with decreased expiratory muscle strength. Before medical treatment, patients should be included to pulmonary rehabilitation programs.

Keywords: Dyspnea, muscle strength, pulmonary functions, respiratory muscles

[Abstract:0686] EPS-111 [Accepted: E-Poster] [Lung and Pleura Malignancies]

Extranodal Marginal-Zone Lymphoma

Neslihan Fener¹, Gülşah Günlüoğlu²

¹Department of Pathology, Health Sciences University Yedikule Chest Diseases and Thoracic Surgery Training and Research Hospital, İstanbul, Turkey

² Department of Chest Diseases, Health Sciences University Yedikule Chest Diseases and Thoracic Surgery Training and Research Hospital, İstanbul, Turkey

A 59-year-old male patient presented himself to the chest diseases polyclinic with the complaints of cough and back pain. He smoked 30 packets/year, has been an ex-smoker for 10 years. No significant information was present in his and family history. Upon detecting pathology on his chest X-ray, thoracic tomography was required and 40x36 mm consolidation in the right lung upper lobe anterior segment and in the fissure junction subpleural in left upper lobe anterior segment and focal consolidations with similar features in the right lung upper lobe superior segment were observed. Fiberoptic bronchoscopy was performed, upon failing to achieve regression with antibiotic therapy in terms of possible malignancy. Endobronchial lesion was not observed. A transbronchial biopsy from the right upper lobe anterior segment was inadequate for the diagnosis. Fine needle aspiration biopsy was performed on the lesion twice under the guideline of computerized tomography. Both were negative for malignancy. VATS-wedge biopsy was performed from lesions on the right upper and lower lobes for diagnostic purposes with the decision of the council. In the pathologic evaluation of both biopsy materials; lymphoidinfiltration was observed, showing a nodular growth pattern that clears the lung parenchyma. The cells forming the infiltration are with fine granular chromatin having a narrow and clear cytoplasm. All of these cells had positive reaction with CD20, negative with CD5, and positive with BCL2. The findings were consistent with *extranodal marginal-zone* lymphoma. The case was presented since it is a reminiscent of the fact that lymphoma should be taken as a differential diagnosis of cancer in lesions that constitute an underlying mass effect, and it is rarely observed.

Keywords: Lung, mass, lymphoma

[Abstract:0692] PS-085 [Accepted:Poster Presentation] [Pulmonary Rehabilitation and Chronic Care]

The Effect of Nutritional Support on Pulmonary Rehabilitation Outcomes in COPD Patients with Low Body Mass Index

İlknur Naz¹, Hulya Sahin²

¹Department of Physiotherapy and Rehabilitation, İzmir Katip Celebi University Faculty of Health Sciences, İzmir, Turkey

²Health Sciences University, Dr. Suat Seren Chest Diseases and Surgery Training and Research Hospital, İzmir, Turkey

Objectives: Malnutrition, commonly occurs in COPD patients, is associated with functional impairment and mortality. Although nutritional support, one of the components of pulmonary rehabilitation (PR), has been shown to have positive effects on these patients, the results are controversial and the level of evidence of efficacy is inadequate. The aim of our study is to

examine the effect of protein-rich nutritional support combined with the exercise program on PR gains in COPD patients with low body mass index (BMI).

Methods: Twenty-five COPD patients with a BMI of 21.0 kg/m² or less were included in the study. Exercise program consisting of respiratory, aerobic and strengthening exercises were applied to all the patients for 8 weeks for a total of 16 sessions. Protein-rich nutritional support was provided addition to the exercise program in the study group (n=12). Patients who didn't accept nutritional support despite indication were identified as the control group (n=13). Pulmonary function test, arterial blood gas, 6-minute walk distance (6MWD), MMRC Dyspnea Scale, St.George and SF-36 Quality of Life and Hospital Anxiety and Depression Questionnaire results were recorded before and after PR.

Results: The median age of patients was 64 (57-70) years, disease duration; 5 (3-8) years, BMI; 20 (19-21) kg/m², and cigarette consumption; 50 (40-68) p* year. The disease duration, cigarette consumption, distribution of COPD stage, and hospital admissions in the last year were similar between groups (p>0.05). Patients in the study group had a higher number of emergency referrals in the last year (p=0.029). Pulmonary function test, arterial blood gas, 6-MWD, dyspnea, quality of life, anxiety and depression scores were similar between groups before PR (p>0.05). Significant improvements were noted in the 6-MWD, dyspnea, anxiety, disease specific and health related quality of life parameters for both groups after PR (p<0.05). When comparing the post-PR gains of groups, the improvement in dyspnea and symptom score of disease-specific quality of life were significantly more in the study group (p=0.047, p=0.004, respectively).

Conclusion: When the protein-rich nutritional support administered in addition to the exercise program, it did not result in any change in gains of pulmonary function test, arterial blood gas or 6-MWD, but it increases the improvement in dyspnea and symptom burden in COPD patients with low BMI. Our work supports the idea that nutritional support will have positive effects on the outcome of the PR program. There is a need for longer term studies with more cases involving body composition and diet information of patients.

Keywords: COPD, nutritional support, pulmonary rehabilitation

[Abstract:0698] EPS-028 [Accepted: E-Poster] [Clinical Problems - Diffuse Parenchymal Lung Disease]

Pulmonary Alveolar Proteinosis: Case Report

Günseli Balcı, Aydan Mertoğlu, Ali Korkmaz, İpek Ünsal, Emel Telliöğlü

Health Sciences University, Dr. Suat Seren Chest Diseases and Chest Surgery Training and Research Hospital, İstanbul, Turkey

Pulmonary alveolar proteinosis is a rare disease characterized by the accumulation of lipoproteinous material in the alveoli. A thirty seven-year-old woman was admitted to our hospital with complaints of dyspnea and cough. Bilateral diffuse infiltration was seen on chest X-ray. In high-resolution computerized tomography (HRCT), interlobular septal thickening with increased densities in the form of ground glass, and patchy infiltrations which tended to coalesce mostly in the central and upper lobes in both lungs. The patient underwent wedge resection with video assisted thoracoscopic surgery (VATS) for diagnosis. Accumulation of proteinaceous material staining with histochemical PAS staining was observed in the alveolar spaces of the left upper and lower lobe wedge resection materials. The pathology result was reported as "Pulmonary Alveolar Proteinosis (PAP)". Patients presenting with complaints of dyspnea should also be considered for PAP in the differential diagnosis, which is a rare disease in the presence of bilateral infiltration.

Keywords: Pulmonary alveolar proteinosis, dyspnea, VATS

[Abstract:0699] PS-246 [Accepted:Poster Presentation] [Environmental and Occupational Lung Diseases]

Evaluation of Occupational and Environmental Exposure Status in Malign Pleural Mesothelioma Patients Diagnosed at the Hospital of Dokuz Eylül University Medical Faculty

Erçin Alsancak, Gökçen Ömeroğlu Şimşek, Arif Hikmet Çımrın

Department of Chest Diseases, Dokuz Eylül University School of Medicine, İzmir, Turkey

Objectives: Malignant pleural mesothelioma (MPM) is a tumor originating from the serous surfaces of the pleura, peritoneum and pericardium. Many studies have shown a relationship between MPM and asbestos exposure. Asbestos has been banned in recent times and is involved in a variety of industrial products. In our country, it is found in nature and causes lifetime exposures.

Methods: In our study, 38 patients who were diagnosed in DEUTF Chest Diseases Polyclinic in the last 10 years and diagnosed as malignant mesothelioma were searched by their contact numbers and were questioned about their environmental and occupational exposures. 1 out of 38 patients were alive and interviewed, and 32 of the remaining 37 patients were reached.

Results: In the obtained data, the incidence of MPM was 58/42% with male/female ratio, the mean age was 60 and the smoking rate was 55%. The histologic type of MPM diagnosis was mostly epithelioid type, and in 8 cases both peritoneal and pleural involvement were observed. Environmental exposure was detected in 58% of cases and 13% had occupational exposure. 63% had a story of residence in the house and 84% had a story in the village.

Conclusion: As a result, environmental exposure is still the most important cause of MPM in our country and it is inevitable that social precautions must be taken in this respect. It seems that the environmental and occupational exposures caused by low socio-economic levels rather than the effect of the industry and should be avoided.

Keywords: Asbestos, environment, occupation

[Abstract:0700] PS-042 [Accepted:Poster Presentation] [Lung and Pleura Malignancies]

Video Assisted Thoracoscopic Surgery for Rare Mediastinal Mass: Ectopic Thyroid

Kenan Can Ceylan¹, Güntuğ Batıhan¹, Özgür Batum², Ali Galip Yener³

¹Department of Thoracic Surgery, Health Sciences University Dr. Suat Seren Chest Diseases and Surgery Training and Research Hospital, İzmir, Turkey

²Department of Chest Diseases, Health Sciences University Dr. Suat Seren Chest Diseases and Surgery Training and Research Hospital, İzmir, Turkey

³Department of Pathology, Health Sciences University Dr. Suat Seren Chest Diseases and Surgery Training and Research Hospital, İzmir, Turkey

Introduction: Mediastinal ectopic thyroid tissue is very rare but important differential diagnosis when investigating mediastinal lesions and should be considered even if scintigraphy is negative in the right clinical context. Most patients are asymptomatic and euthyroid with positive signals on scintigraphy. Here, we report a rare case of ectopic thyroid tissue present as right paratracheal mediastinal mass.

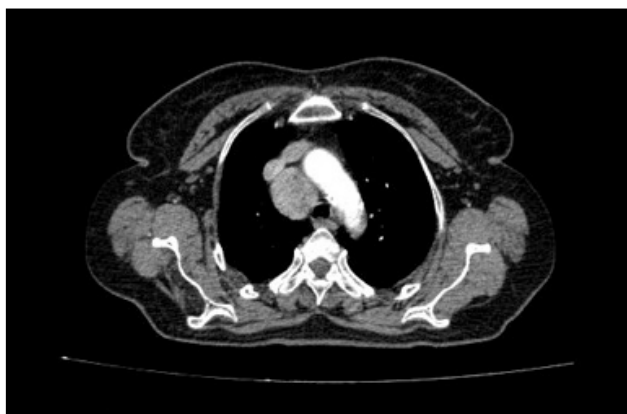

Figure 1. Right paratracheal mass

Case Presentation: A 70-year-old woman directed our hospital because of incidentally detected right paratracheal mass. Chest X-ray suggested possible pleural thickening prompting computerised tomography of the chest which showed an incidental 2.5 cmx3.4 cm mass indenting the right lateral tracheal wall and no pleural thickening. Endobronchial ultrasound guided fine needle aspiration (EBUS-TBNA) performed two times but could not be diagnosed. Based on malignancy suspicious and in order to diagnose surgical excision was scheduled.

Video assisted thoracoscopic surgery performed. The excised tumour was retrieved intact and histopathological specimen was consistent with the normal thyroid tissue. The drainage tube was removed after 48 hours and the patient was discharged. There wasn't any problem in clinical follow up.

Conclusion: It is important to make a histopathological verification for mediastinal masses in order to make a differential diagnosis. Surgical excision is the best way to rule out malignancy suspicious and to relieve symptoms in symptomatic cases. We report rare case of video assisted thoracoscopic excision of ectopic thyroid tissue present as right paratracheal mediastinal mass.

Keywords: Ectopic thyroid, vats, mediastinal mass

[Abstract:0701] SS-079 [Accepted:Oral Presentation] [Lung Transplantation]

High CA 19-9, CA 125 and CEA in Cases with Idiopathic Pulmonary Fibrosis

Fatmanur Çelik Başaran, Sinan Türkkan, Mahmut Subaşı, Alkın Yazıcıoğlu, Furkan Şahin, Ahmet Güngör, Erdal Yekeler

Department of Chest Surgery and Lung Transplantation, Health Sciences University, Turkey High Specialization Training and Research Hospital, Ankara, Turkey

Objectives: Carbohydrate Antigens (CA 19-9 and CA 125) and Carcinoembryonic Antigen (CEA) are tumor markers used in the diagnosis and treatment of gastrointestinal system and gynecological malignancies. In the literature, there are studies reporting that they are released from normal respiratory and GI epithelium and there are new studies on the possibility of elevations in benign lung diseases such as tuberculosis, bronchiectasis, idiopathic pulmonary fibrosis (IPF), asbestosis and asthma. We evaluated IPF cases that had been referred to our clinic for lung transplant with elevated tumor markers but showing no malignancy. We presented that in some benign conditions such as IPF, elevated tumor markers are possible and these markers may be a leading marker for the surveillance of patients.

Methods: 613 terminal stage chronic lung disease cases who were evaluated for lung transplant between March 2013 and January 2018 (COPD, IPF, bronchiectasis, LAM, IPAH, cystic fibrosis and sarcoidosis) were studied retrospectively. Ninety-nine IPF cases were included in the study. Serum CEA, CA 19-9 and CA 125 levels were measured by ECLIA method. In terms of malignancy, all patients received USG, total abdominal CT, endoscopy, colonoscopy and PET-CT examinations and gynecological/urological examinations were performed when required. Mortality rates of 0 to 3 months, 3 to 6 months, and 6 to 12 months were analyzed in terms of tumor markers and mortality rates.

Results: Ninety-nine cases of IPF were evaluated. 61 of the cases had high level of CEA (61.6%), 38 were detected with high level of CA 19-9 (38.3%) and 37 cases with high CA 125 (37.3%). While all tumor markers of the seven IPF cases were normal, at least 1 elevated tumor marker was present in 92 IPF cases. In 4 cases that we evaluated as ataxia, CA19-9 >1900ng/ml was found to be very high, about 55 times of the normal value. No malignancy was detected in any patient. In long-term follow-up, 42 cases died. Of these patients, 16 died in the first 3 months; 10 within 3-6 months; 8 within 6-12 months; 8 patients died after 1 year. 4 cases with CA19-9 > 1900 ng/ml died in the first 3 months. In only 2 of 42 cases, all tumor markers were normal and the surveillance of these cases was longer than 1 year. Early mortality was found to be higher in cases with high CA 19-9 levels, and it was seen that the surveillance was longer when CA 19-9 levels were lower. This difference was not observed in CEA and CA 125 markers. Upon the evaluation of 42 cases, the exitus time and blood levels of average tumor markers are shown in Table 1.

Conclusion: We presented this study with the aim of emphasizing that other than malignant diseases tumor markers may also be elevated especially in terminal stage and ataxia IPF patients and in these patients as the level of tumor markers are increased, the surveillance is shorter and can be related to poor prognosis. Being the transplant center, we know that the early stage IPF patients' being in the organ waiting list increases the chances of receiving the transplant. These markers, especially CA-19-9 during the evaluation can be helpful in the estimation of 3,6, and 12 month -mortalities of the patients and poor prognosis and therefore in determining the correct timing to be on the organ transplant waiting list ; we may also be able to guide the 3-and 6-month mortality of patients and the timing of the estimation of poor prognosis and hence the time taken to be on the organ transplant waiting list.

Keywords: Idiopathic pulmonary fibrosis, tumor markers, CA 19-9

Table 1. Mean levels of tumor markers according to patients survivals

Tumor marker / Survey	0-3 month (16 patients)	3-6 month (10 patients)	6-12 month (8 patients)	>12 month (8 patients)
CEA (0-3,8ng/mL)	10.24	10.96	34.7	4.43
CA-19-9 (0-27 U/mL)	519	208	112	31.6
CA-125 (0-35 U/mL)	82.12	204	44.7	16.3

[Abstract:0702] EPS-022 [Accepted: E-Poster] [Clinical Problems - Diffuse Parenchymal Lung Disease]

Eosinophilic Pneumonia Case with Atypical Radiological Mutual

Emine Güzey, Süleyman Savaş Hacıevliyagil, Murat Yağcısoy, Gazi Gülbaş, Arzu Nakış Güven, Mehmet Burak Öztürk

Department of Chest Disease, İnönü University School of Medicine, Malatya, Turkey

Introduction: Eosinophilic lung disease is characterized by eosinophilic infiltration in peripheral blood and bronchoalveolar lavage (BAL) and the lung tissue. Peripheral infiltrates that are generally bad restricted and may be consolidated at the appearance of ice glass in the chest X-ray is seen in all the patients. Negative appearance of pulmonary edema is classical pattern. We wanted to present a eosinophilic lung disease with atypical radiological.

Case Presentation: A 48-year-old male with asthma referred to the external center for cough and fever complaints. There has been complaints of shortness of breath in the last 1 year. There have been complaints of minimal hemoptysis 2 times before. The patient's tomography was directed to our center with the examination of the etiology of pneumonia not responding to nonspecific treatment. There was uniformly limited consolidation of 4x4 cm in the left lung baseline. In the follow-up, cavitary lesion (Figure 1, 2) with left lower lobe posterior air fluid level (Figure 1, 2), neutrophil dominance at baseline in full blood count, and eosinophilia (9%) in follow-up. Fiberoptic bronchoscopy left bottom lob carbon blunt, lateral segmently departure

available. Pathology reported as suspected for malignance. Segmentectomy was performed. Pathology, reproduced as characterized pneumonia results with increased eosinophiles which show organization findings. 32 mg/day prednisolon has started with eosinophilic pneumonia diagnosis. Lesions are regressed patient is like 2 months following (Figure 3).

Conclusion: As a result; loss of the eosinophilic lung disease with laboratory findings and clinic in atopic radiology appearance. Bronchoscopic inspections must be considered prior to identifiable identification and formulable complications.

Keywords: Eosinophilia, cavity, surgery

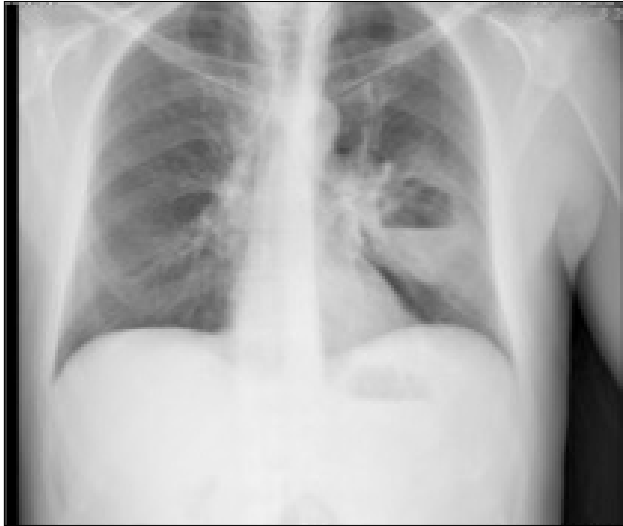

Figure 1. Chest X-ray at admission

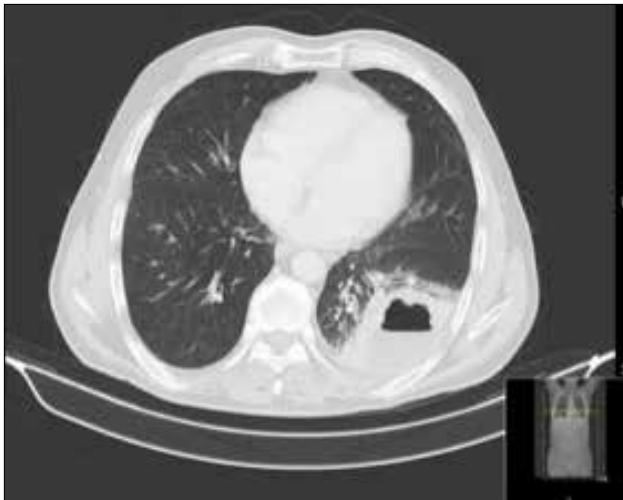


Figure 2. CT at admission

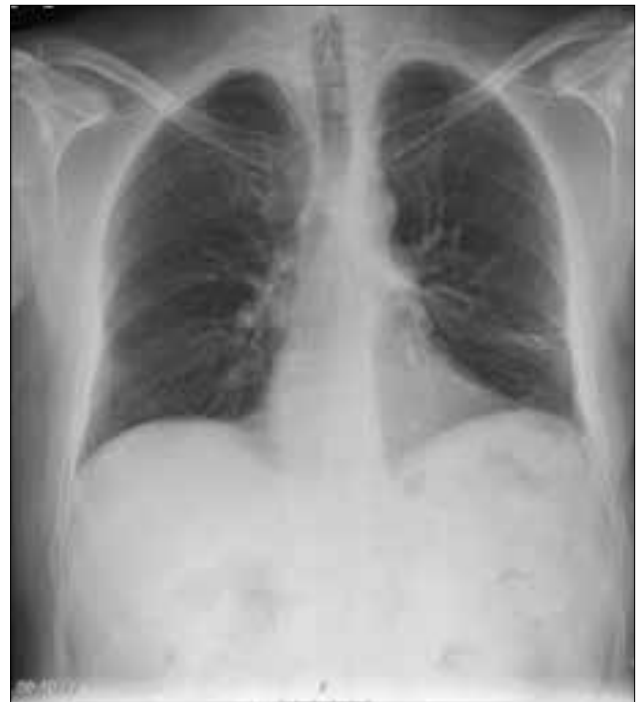

Figure 3. Chest X-ray after admission

[Abstract:0706] EPS-228 [Accepted: E-Poster] [Thoracic Surgery]

Superior Vena Cava Syndrome Caused by a Right Apical Giant Bulla: A Rare Case

Güntuğ Batihan, Yunus Türk, Ozan Usluer, Şeyda Örs Kaya

Department of Chest Diseases and Thoracic Surgery, Health Sciences University, Dr. Suat Seren Chest Diseases and Surgery Training and Research Hospital, İzmir, Turkey

Introduction: Superior vena cava syndrome (SVCS) is a group of symptoms caused by obstruction of superior vena cava. The characteristic physical findings of SVCS include venous distention of the neck and chest wall, facial edema, upper-extremity edema, mental changes, plethora, cyanosis, papill edema, stupor, and even coma. More than 80% of cases of SVCS are caused by malignant tumors especially small-cell bronchogenic carcinomas. Nonmalignant conditions like; mediastinal fibrosis, aortic aneurysm, benign mediastinal tumors, infections can also cause SVCS. We present a rare case of SVC syndrome caused by a tense bulla. To our knowledge, only one case has been reported previously.

Case Presentation: A 29-year-old man admitted our clinic with 3 month history of non-productive cough and dispnea that aggravated with lying down. Facial plethora was seen in physical examination. Chest radiography revealed giant right apikal bulla formation. Computed tomography revealed tense bullae cause superior vena cava compression.

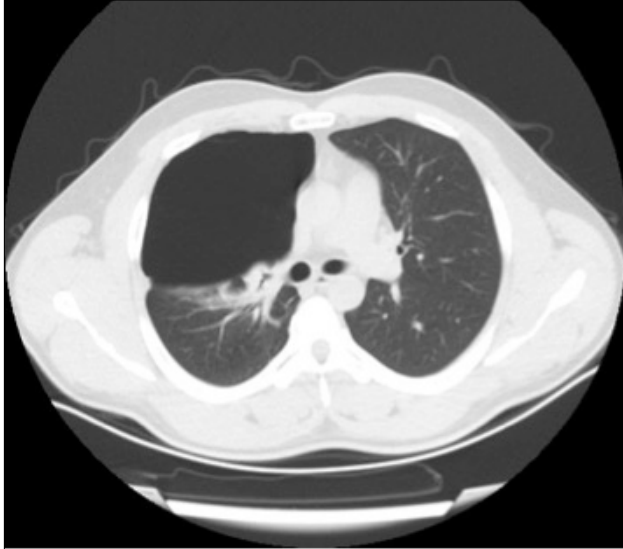


Figure 1. Right apical giant bullae compressing superior vena cava

Video-assisted thoracoscopic surgery bullectomy was performed via two port without any complication. After surgery patient's facial plethore and cough disappeared. Chest tube was terminated at post-operative day 4.

Conclusion: Superior vena cava (SVC) syndrome is a group of symptoms caused by obstruction of superior vena cava. More than 80% of cases of SVCS are caused by malignant mediastinal tumors. In this report, we have presented a rare case of SVC syndrome caused by a tense bulla. Generally, as a bulla expands, the visceral pleura stretches and the residual lung is compressed. However, in this case, severe pleural adhesion prevented the bulla from expanding and compressing the surrounding lung, forcing the bulla to compress the chest wall and the mediastinum, including the SVC, and thus causing SVC syndrome. In patients with right apical tense bullae, SVC syndrome should be considered especially if clinical symptoms caused by SVC compression present.

Keywords: Giant bullae, VCSS, VATS

[Abstract:0710] EPS-038 [Accepted: E-Poster] [Clinical Problems - Pulmonary Vascular Diseases]

Massive Pulmonary Thromboembolism Occurred after Pulse Corticosteroid Therapy in a Patient with Pemphigus Vulgaris

Ayşe Baççioğlu, Dilek Eraslan, Ayşe Füsün Kalpaklıoğlu

Department of Pulmonary and Allergic Diseases, Kırıkkale University School of Medicine, Kırıkkale, Turkey

Venous thromboembolism (VTE) has been reported to be a significant cause of death in patients with pemphigus vulgaris (PV) which is an autoimmune disease of skin. PV is treated with immunosuppressive agents such as oral corticosteroids (OC) that may increase PE risk, by increasing platelet counts, decreasing renal clearance, occurrence of hypervolemia, stasis, and endothelial dysfunction. Here, a case with PV who developed massive PTE during high dose OC treatment was presented.

A 42-year-old female patient with pemphigus vulgaris (PV) had been under treatment with azathioprine for 2 years. However, OC was indicated for uncontrolled PV disease, and she started to use OC 1mg/kg/day methylprednisolone. The OC dose was gradually tapered to 16 mg/day in 6 months. Although lesions of PV were healed, she complained about progressive exercise dyspnoea during the last month of OC treatment. The patient was then admitted to emergency with syncope. Physical examination revealed hypotension, tachycardia, tachypnea, pulse oxygen saturation (O₂ sat) 39%, unconscious, wheezing, and cushingoid body. Thorax computed tomography (CT) angiography was reported as VTE in bilateral main pulmonary arteries, and infarct areas in both parenchyma. Low extremity colour doppler ultrasonography showed VTE in the right femoral and popliteal venous. Serum d-dimer was 31µg/mL (upper limit 0.5µg/mL). Systolic pulmonary arterial pressure (SPAP) was 41 mmHg in echocardiography (ECO). Thrombolytic (tenecteplase 100 mg) was administered to the patient in the initial hours of her admission, and there after her cardiovascular vital findings returned to normal limits. She was discharged with low molecular-weight-heparin (LMWH), and after one month of treatment, SPAP was under 25mmHg, O₂ sat 96%, serum d-dimer and ECO were also normal. VTE risk factors were negative including genetic thrombophilia screening tests. Treatment with azathioprine, and CS was discontinued, and PV was treated with topical drugs. VTE in pulmonary, and low extremity were completely resolved after 6 months of oral anti-coagulation therapy with warfarin.

VTE risk factors in this patient was suggested as PV, and its treatment's complications, including OC. Patients with PV treated with OCs may be at an increased risk of PE which requires VTE assessment, and thrombo-prophylaxis.

Keywords: Pulmonary thromboembolism, pemphigus vulgaris, corticosteroid

[Abstract:0711] PS-167 [Accepted:Poster Presentation] [Tuberculosis]

Mortality from Tuberculosis in Belarus and Other Countries of the European Region of WHO

Halina Baradzina, Anastasia Vankovich Vankovich, Elena Romaschenko

Belarusian State Medical University, Minsk, Belarus

Objectives: Development and introduction of international and national programs to struggle with tuberculosis in Belarus leded to significant success in mortality reducing. The aim of study was analysis of mortality's dynamics from tuberculosis and evaluation of the contribution to this indicator of HIV-associated tuberculosis (HIV-TB) in Belarus, Russia, Ukraine, Poland, Lithuania, Latvia, Estonia and Kazakhstan.

Methods: The WHO statistical data of tuberculosis mortality in some countries of European region, which unites also the countries of the former Soviet Union during 1994-2015, and National Belarusian statistical data were used.

Results: At the end of the 20th century, the difference in mortality rates between countries was very high, but nowadays it has become more similar. In general in all countries observed a positive dynamics, but not always reducing mortality was smooth. Mortality rate in Belarus (4.0 per 100 000 in 2015 as compared by 12.1 per 100.000 populations in 2005) is less than in Russia, Kazakhstan, Lithuania and Ukraine. The highest mortality during 1994-2000 was observed in Kazakhstan (data on Ukraine till 2000 year are absent). Since 1997 index increased and peaked rapidly (38.4 per 100.000 populations), then it started to decline at a rapid rate (3.98% per year). In other countries for the exception of Poland, this indicator reached the maximum in 2005 (later than in average in the world (2002)). Poland demonstrates a consistently low mortality rate (1.4-2.9 per 100 000). The start position of Latvia was worse then in Lithuania, but since 2002 mortality index became lower than in Lithuania, in which mortality changed insignificantly (from 11 to 7.9 per 100 000 populations) during the explored period. Estonia (5.5 % per year) and Latvia (5.14%) are the leaders in the rate of a mortality reduction.

The proportion of HIV-TB in 2015 ranged from 1.9% in Poland up to 24% and 22% in Latvia and Ukraine. The level of HIV-TB in Ukraine and Latvia is almost identically, but mortality from HIV-TB in Latvia to 3.36 times lower.

Conclusion: The average value of TB mortality in the analyzed countries is 6.13 per 100 000 populations. TB mortality rate is the highest in Kazakhstan, Lithuania and Ukraine. Kazakhstan, Latvia and Estonia are the leader to rate of indicator reduction. The powerful contribution to the mortality from tuberculosis is made by HIV-TB. A big difference of mortality from HIV-TB in Ukraine and Latvia demonstrates priority of HIV-TB patient's treatment organization.

Keywords: Tuberculosis, HIV-TB, mortality

[Abstract:0715] SS-059 [Accepted:Oral Presentation] [Environmental and Occupational Lung Diseases]

Impact of Heating with Natural Gas on Emergency Admissions due to Upper and Lower Respiratory Tract Diseases in Children in the Province of Düzce

Pınar Yıldız Gülhan, Ege Güleç Balbay, Ali Nihat Annakkaya, Öner Abidin Balbay, Peri Meram Arbak

Department of Chest Diseases, Düzce University School of Medicine, Düzce, Turkey

Objectives: The use of natural gas for heating purposes causes less air pollution than solid fuels. Preventing air pollution decreases hospital admissions due to respiratory infections in children. Examining the impact of using more clean fuel for heating purpose on hospital admissions with upper and lower respiratory tract diseases in children retrospectively.

Methods: The records of the patients admitted to the pediatric emergency service of Düzce University Hospital with the diagnosis of respiratory tract disease between 2014 and 2017 were examined (n=41078). During the same period, air monitoring measurements of the national air quality network were recorded (PM10, SO₂, air temperature).

Results: Four-year disease distribution, acute upper respiratory tract infection (URTI) 39.3%, tonsillitis 19.5%, acute lower respiratory tract infections (LRTI) 10.4%, pharyngitis 8.2%, bronchiolitis 5.3%, pneumonia 4.2%, asthma 3.1%. Between 2014-2017, the mean PM10 was observed to decrease (2014: 114.4, 2017:79, p<0.0001), rate of natural gas usage (2014: 52.9%, 2017: 64.2%) increased, rates of stove usage (2014: 47%-2017: 35.7%,) decreased, annual mean air temperature values (2014:13.9-2017:16.7, p<0.0001) increased significantly (Figure 1).A significant decrease was observed in the admissions due to LRTI (from 5.1% to 4.2%), URTI (from 65.7% to 54.9%), bronchitis (from 5.9% to 0.8%), pneumonia (from 3.6% to 1.5%), asthma (from 5.3% to 2.4%) in the fall season between 2014-2017. A downward tendency was noted in the admissions due to LRTI (from 10.4% to 9.1%), URTI (from 55% to 41.5%), bronchitis (from 1.9% to 1.3%), pneumonia (from 3.3% to 3.1%), asthma (from 3.3% to 2.1%) in the winter season. A significant decline was observed in the admissions due to LRTI (from 6.1% to 5.4%), URTI (from 58.2% to 42.2%), pneumonia (from 4.2% to 2.2%), asthma (from 4% to 2%) in the child age group of 2-5 years between 2014-2017. A significant decrease was noted in the admissions due to LRTI (from 3.5% to 3.9%), URTI (from 63.1% to 45.4%), pneumonia (from 2.5% to 2.2%), asthma (from 5% to 4.1%) in the child age group of 6-11 years. When all pediatric emergency admissions between 2014 and 2017 were examined, the number of those diagnosed with respiratory tract disease reduced while the number of general pediatric emergency admissions increased (Figure 2).

Conclusion: The use of more clean fuels for heating purposes was observed to decrease the incidence of acute LRTI and URTI significantly. The use of clean fuel should be encouraged since preventing childhood infections would protect from the chronic lung diseases that may occur during adulthood.

Keywords: Child, clean fuel, natural gas, PM10

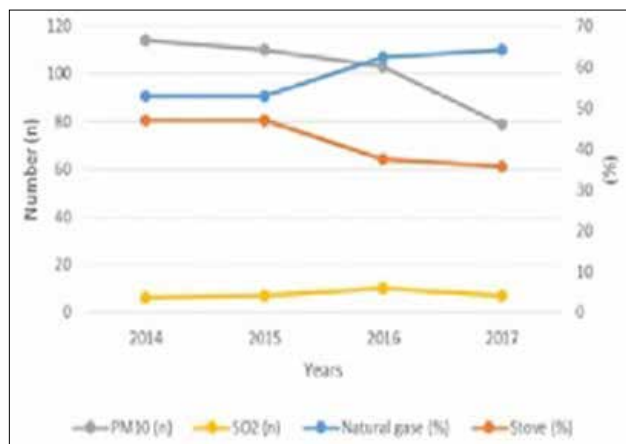


Figure 1. Natural gas, stove usage rate by years and PM10, SO₂ level

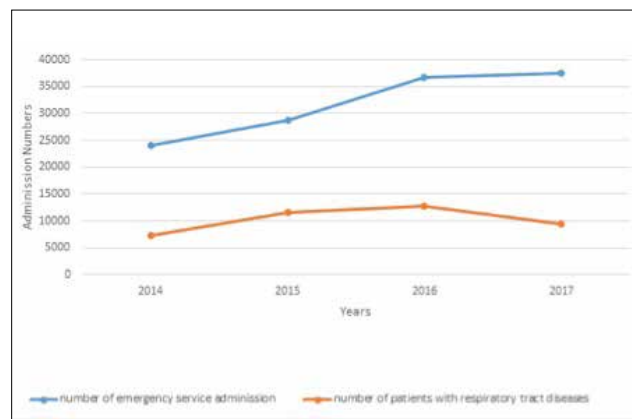


Figure 2. Number of pediatric emergency department admissions and respiratory disease patients by years

[Abstract:0720] EPS-280 [Accepted: E-Poster] [Thoracic Surgery]

A Rare Lung Tumor: Sclerosing Hemangioma

Suzan Temiz, Gönül Gülmez, Oğuzhan Turan, Ömer Önal, Ömer Faruk Demir

Department of Chest Surgery, Erciyes University School of Medicine, Kayseri, Turkey

Introduction: Sclerosing hemangioma of the lung which is frequently detected incidentally is usually a rare benign tumor that is more commonly seen among women between the ages of 30 and 50 years in the form of solitary pulmonary nodule. Since vascular structures are in the forefront and it is considered vascular related, it was named as sclerosing hemangioma. However, afterwards it was accepted that it is a very low-grade malignancy originating from the primitive respiratory epithelium. It is mostly peripheral. In the computed tomography (CT) of the thorax, they are observed as well-defined, homogeneous or heterogeneous mass lesion with contrast enhancement. 80% of the patients are asymptomatic. Hemoptysis, cough and chest pain are the most common complaints.

Case Presentation: A 50-year-old woman was admitted to the chest diseases department with the complaint of occasional chest pain. She was referred to our institution by another health institution upon her thoracic CT that showed a well-defined mass of 22x18 mm in the left lower lung lobe anterobasal segment and was directed to our institution for further examination (Figure 1). Her PET-CT, the lesion was assessed as a primary malignancy and there was no distant organ metastasis. The patient

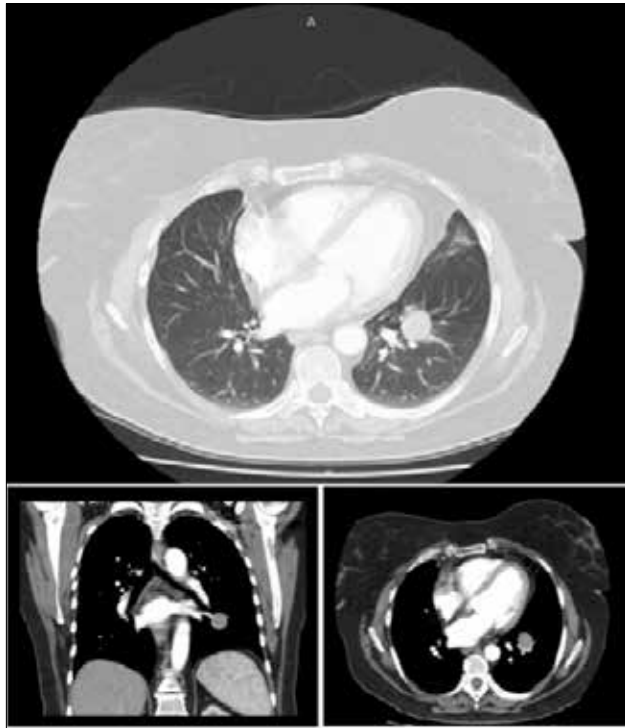


Figure 1. 22x18 mm mass in the anterobasal segment of the left lower lobe, in the neighborhood of basal segment artery in CT

was operated because brain CT did not show any pathology and the location of the lesion was not suitable for transthoracic and bronchoscopic biopsy. During the surgery; the lesion adjacent to the basal segment artery and which was in the the left lower lobe anteromedio-basal was totally excised by enucleation. As a result of the “frozen examination” performed during the operation, it was observed that “Neoplastic lesion is more epithelial in appearance. Mesenchymal lesions could not be excluded, mitosis was not seen. It was reported that for a definite diagnosis paraffin blocks are recommended”. The ultimate pathology of the patient was sclerosing pneumocytoma. After discharge, the patient was directed to oncology and our polyclinic for follow-ups.

Conclusion: Benign tumors of the lung are very diverse, but rare. Although pulmonary sclerosing hemangiomas are considered as benign tumors, their metastases or recurrences have been reported in regional lymph nodes. Pulmonary sclerosis hemangiomas may include four different histological patterns; papillary, solid, hemorrhagic, and sclerotic. Sclerosis hemangiomas (pneumocytoma) is considered to have epithelial, endothelial, histiocytic, or mesothelial origin. For this reason, Sclerosis hemangiomas may be confused with malignant and benign tumors of the lung. Many are diagnosed with randomly performed radiographs. The case is presented because it is rarely seen among benign lung diseases and imitates malignancy.

Keywords: Lung, malignancy, sclerosis hemangiomas

[Abstract:0723] SS-030 [Accepted: Oral Presentation] [Pulmonary Rehabilitation and Chronic Care]

Comparison of Exercise Capacity, Hemodynamic Responses, Dyspnea, Pulmonary Function and Risk Scores in Patients Underwent Coronary Artery Bypass Graft Surgery with and without Diabetes Mellitus

Selin Bayram¹, Burcu Camcıoğlu¹, Zeynep Pelin DüNDAR³, Hanım Eda Göktaş¹, Dilek Erer², Erkan Iriz², Gürsel Levent Oktar², Meral Boşnak Güçlü¹

¹Department of Physiotherapy and Rehabilitation, Gazi University School of Health Sciences, Ankara, Turkey

²Department of Cardiovascular Surgery, Gazi University School of Medicine, Ankara, Turkey

³Department of Physiotherapy and Rehabilitation, Necmettin Erbakan University School of Health Sciences, Konya, Turkey

Objectives: Exercise capacity is an important predictor of long-term prognosis after coronary artery bypass graft surgery (CABG). The acceleration of atherosclerosis and impaired chronotropic response in individuals with diabetes mellitus (DM) reduces exercise capacity. There are limited studies investigated cardiopulmonary manifestations in patients underwent CABG surgery with and without DM. The aim of the study was to compare functional exercise capacity, hemodynamic responses, dyspnea, pulmonary function and pulmonary risk scores in patients underwent CABG surgery with/without DM and healthy individuals.

Methods: Twenty six patients underwent CABG surgery (63.5±6.5 years, 6F/20M, grafts (n) : 2.7±0.9, intubation duration: 15.9±4.9 h) with DM and 43 patients (60.3±9.9 years, 4F/39M, grafts (n) : 2.9±0.7, intubation duration: 15.3±7.0 h) without DM and 24 healthy individuals (58.4±6.3 years, 4F/20M) were compared. Demographic and clinical characteristics were recorded. Pulmonary risk score scale were used to evaluate pulmonary risk. Functional exercise capacity using six-minute walk test (6MWT), dyspnea and fatigue using modified Borg scale and pulmonary function using spirometry were assessed. Hemodynamic responses; heart rate (HR), oxygen saturation (SpO₂), breathing frequency (BF) and blood pressure (BP) were measured before, during and after 6MWT.

Results: Demographic characteristics were similar between groups (p>0.05). FEV₁ (L,%), FVC (L,%), PEF (L,%), 6MWT distance and %6MWT decreased similarly in patients with and without DM compared with healthy individuals (p≤0.001). Resting HR, BF, dyspnea, general fatigue increased and SpO₂ decreased similarly in patients with and without DM compared with healthy individuals (p<0.001). After 6MWT, patients have significantly higher dyspnea (p=0.003), general fatigue, quadriceps femoris (QF) fatigue and lower systolic blood pressure compared with healthy individuals (p<0.001). Heart rate recovery at 1 minute after 6MWT was significantly lower in patient compared with healthy individuals (p<0.001). Patients with DM have significantly higher glucose levels (p=0.006), pulmonary risk scores (p<0.001), resting QF fatigue (p=0.01) and lower 6MWT distance (p=0.005) and %6MWT (p=0.001) compared with non-DM patients. Activity dyspnea and hemodynamic responses measured before, during and after 6MWT were similar in DM and non-DM patients (p>0.05).

Conclusion: Patients underwent CABG surgery with and without DM have impaired pulmonary function, functional exercise capacity and hemodynamic responses to exercises. Patients with DM undergoing CABG surgery have advanced decreased functional exercise capacity; increased muscle fatigue and pulmonary risk scores. Comprehensive pulmonary rehabilitation assessment, risk factor analysis and pulmonary rehabilitation interventions should be performed before and after coronary artery bypass surgery in patients with and without DM.

Keywords: Coronary artery bypass graft surgery, diabetes mellitus, exercise capacity, pulmonary risk score

[Abstract:0726] SS-012 [Accepted:Oral Presentation] [Clinical Problems - Diffuse Parenchymal Lung Disease]

The Influence of Body Mass Index on Survival in Patients with IPF

Burcu Uysaler, Aysu Sinem Koç, Nesrin Moğulkoç Bishop

Department of Chest Diseases, Ege University School of Medicine, İzmir, Turkey

Objectives: It has been reported that a high body mass index (BMI) is associated with better survival in patients with idiopathic pulmonary fibrosis (IPF), similar to the beneficial impact seen in COPD and chronic respiratory insufficiency. We aimed to find out whether body mass index influences survival of patients with idiopathic pulmonary fibrosis.

Methods: We examined the relationship between BMI and survival in our cohort of patients with IPF. These patients were first seen in our interstitial lung disease clinic between May 2008 and January 2018. All had a diagnosis of IPF based on clinical assessment and high resolution CT scan; one third underwent a surgical lung biopsy. Height and body weight were ascertained at the first consultation. Survival analysis was performed using SPSS version 16.

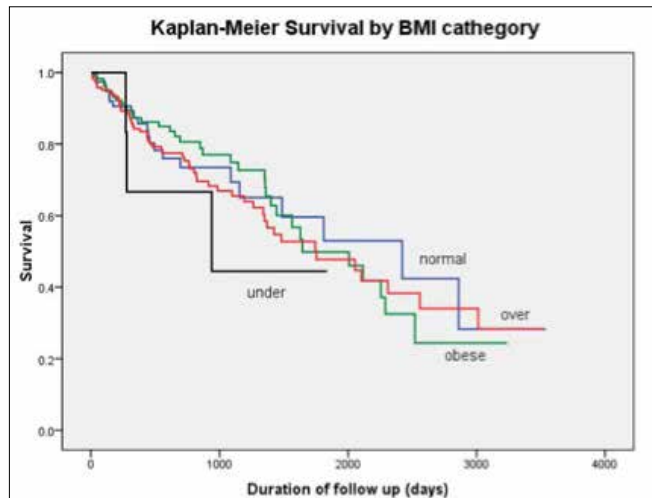


Figure 1. Kaplan-Meier Survival by BMI category

Results: We had data on 367 patients. The median age at first consultation was 66 years (range 39 to 97). There were 272 men and 95 women. At presentation, 6 were underweight (BMI<18.5), 79 were of normal weight (BMI 18.5 to 25), 165 were overweight (BMI 25 to 30) and 117 were obese (BMI>30). On Kaplan-Meier survival analysis, there was no significant difference in survival between these categories ($p=0.75$).

Conclusion: The differences between the groups did not reach clinical significance. The graph suggests that being underweight is an adverse prognostic factor, but the number of such patients was very small. It also suggests that obesity may be marginally beneficial for the first four years but not thereafter.

Keywords: Body mass index, idiopathic pulmonary fibrosis, survival

[Abstract:0728] PS-289 [Accepted:Poster Presentation] [Respiratory Failure and Intensive Care]

Risk Factors for Mortality in Patients with Idiopathic Pulmonary Fibrosis Followed at Intensive Care Unit due to Acute Respiratory Failure

Burcu Uysaler, Pervin Korkmaz Ekren, Feza Bacakoğlu, Nesrin Moğulkoç Bishop

Department of Chest Diseases, Ege University School of Medicine, İzmir, Turkey

Objectives: Rapid progression and respiratory failure may be seen in patients with idiopathic pulmonary fibrosis (IPF). The effect of invasive (IMV) and noninvasive (NIV) mechanical ventilation is not clearly known in patients developing acute respiratory failure. The aim of this study is to determine mortality rates and to evaluate the risk factors for mortality in IPF patients with acute respiratory failure.

Methods: The patients hospitalized in the Respiratory Intensive Care Unit (ICU), Chest Diseases Department of Ege University were evaluated retrospectively between May 2002 and November 2017.

Results: During the study period, 65 patients with interstitial lung disease were followed up at the ICU. 44 of them [22 male, median age 69 years (IQR: 60-82)] had IPF and respiratory failure. The median age at the time of diagnosis of IPF was 62 years, and the patients were hospitalized in the ICU at an average of 36 months after the date of diagnosis. The most common causes of respiratory failure were pneumonia (26 patients, 11 of them with community acquired pneumonia) and exacerbation of IPF (7 patients). Treatment of respiratory failure comprised only oxygen supplement (9.1%), only NIV (34%), only IMV (11.4%), or a combination of NIV and IMV (45.5%). The overall mortality rate was 61.4% and average length of hospitalization was 10.5 (IQR: 4-17) days. The mortality rate was 53.3% for patients treated with only NIV, compared to 60.0% for patients treated with only IMV. The highest mortality rate was 93.3% in patients who were treated firstly with NIV, then required IMV due to failure of NIV. Leukocyte and neutrophil, CRP and LDH value at admission were higher in the group that died than among survivors ($p=0.004$, $p=0.009$, $p=0.005$, $p=0.026$, respectively). However, albumin level and PaO₂/FiO₂ ratio were lower in the group that succumbed ($p=0.002$, $p=0.003$). Age was not found a risk factor for mortality. Patients treated with IMV because of acute respiratory failure had higher mortality ratio ($p=0.031$).

Conclusion: Mortality rates rise with an increasing need for ventilatory support in patients with IPF suffering acute respiratory failure. Prospective study with large numbers cases is needed to detect the favourable patient group that benefits from NIV or IMV support.

Keywords: Acute respiratory failure, idiopathic pulmonary fibrosis, mortality, risk factors

[Abstract:0729] PS-302 [Accepted:Poster Presentation] [Pulmonary Pathology]

Rarely Seen Spontaneous Mediastinal Hematomas

¹Department of Radiology, Van Yüzüncü Yıl University, Van, Turkey

²Department of Radiology, Van District Training and Research Hospital, Van, Turkey

³Department of Radiology, Batman State Hospital, Van, Turkey

Objectives: Due to the presence of numerous and various organs and tissues in the mediastinum, a wide variety of neoplastic masses, cystic lesions and infectious diseases may occur. The most common symptoms are chest pain, cough, and shortness of breath. It has been reported that 54-57% of mediastinal lesions are anterior located, 9.5-20% is midline and 26-33.4% is posterior mediastinal located. Mediastinal hematomas are usually secondary to thoracic trauma or ruptured aortic aneurysm, and non-traumatic mediastinal hematomas are rare. Anticoagulant treatment is one of the risk factors for mediastinal hematomas. Mediastinal bleeding is not common and it is difficult to recognize the hematoma radiologically. In this study, we aimed to present our patient who presented to our clinic with chest pain complaint and whose spontaneous mediastinal hematoma which was mimicking the mass was incidentally detected by computerized tomography (CT).

Methods: A 75-year-old male patient was referred to our thoracic surgery polyclinic with a complaint of chest pain. The patient without a history of trauma and anticoagulant drug use was performed a contrast-enhanced thoracic CT examination.

Results: In contrast-enhanced thoracic CT, about a 5 cm in diameter well-defined with soft tissue density lesion was observed. The lesion was in the right paratracheal area applying pressure on vena cava and narrowed the trachea slightly from the right side. Effusion concomitant within the right pleural space and contaminations in adjacent fat planes were noted. FDG involvement was not detected on PET-CT images that was performed for hematoma-mass differentiation. Because the patient had no history of trauma and anticoagulant medication use, he was primarily thought to be hematoma. The control film taken a week later showed a significant regression of lesion (3 cm).

Conclusion: Spontaneous-traumatic hemorrhage is rare. The causes of spontaneous-traumatic hemorrhage can be hemorrhage disorders, coagulation anomalies, hemodialysis, and the use of anticoagulants. Recognition of mediastinal hematoma may prevent unnecessary interventions. In the diagnosis stage, the sudden expansion of the mediastinum in relation to the chest pain and in the follow-up stage spontaneous regression of the situation is significant. Hematoma should be kept in mind in soft tissue lesions of middle mediastinum.

Keywords: Mediastinum, hematoma, tomography

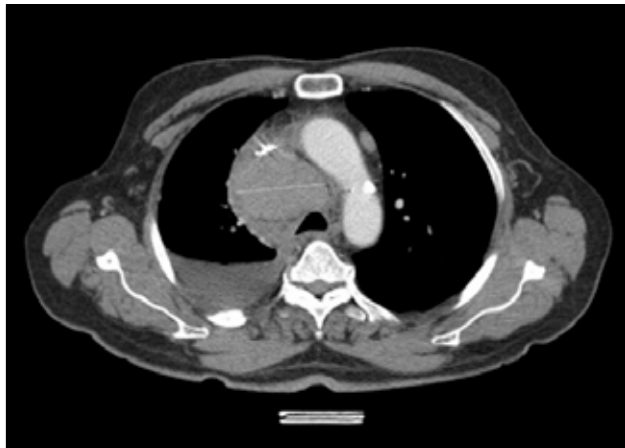

Figure 1. Heterogeneity and effusion in the middle mediastinum with surrounding fatty plane

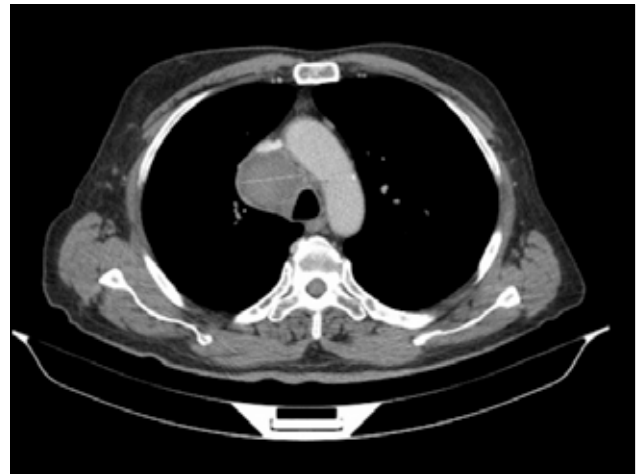

Figure 2. Regression in hematoma in control graph

[Abstract:0731] PS-200 [Accepted:Poster Presentation] [Pediatric Pulmonary Diseases]

Giant Mediastinal Lymphoma in Pediatric Patient

¹Department of Radiology, Van Yüzüncü Yıl University, Van, Turkey

²Department of Radiology, Van District Training and Research Hospital, Van, Turkey

³Department of Radiology, Batman State Hospital, Van, Turkey

Introduction: Less than 20% of patients with mediastinal tumors are in the pediatric age group. 44% of pediatric mediastinal tumors are anterior mediastinal and approximately 80% are malignant. Mostly lymphoma, teratoma and other germ cell tumors, thymoma and cystic hygroma are observed. 50-85% of pediatric cases are symptomatic. Invasive malignant tumors especially in children under two years of age may cause serious respiratory distress and cardiovascular collapses due to the intense pressure on the heart and lungs.

Case Presentation: Our case is a 5-year- 8-month old boy. He was presented to our clinic with the complaint of shortness of breath. No pulmonary sounds were heard during his physical examination. His chest graphy revealed a mass image covering the lungs. Contrast-enhanced thoracic computed tomography showed a soft-tissue lesion approximately 13x8 cm in size that filled the anterior mediastinum and going through superior mediastinum applying significant pressure to the lung in the right, with central necrotic-cystic areas, surrounding the vascular structures and compressing the heart. The result of a through cut biopsy was reported as 'Precursor T-cell lymphoblastic lymphoma' pathology.

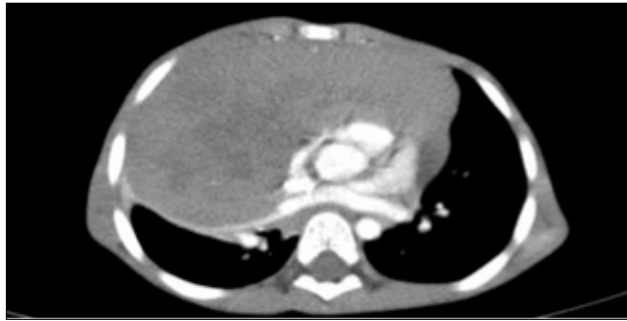

Figure 1. Giant massive image in Anterior mediastinum

Conclusion: Mediastinal lymphoma usually occurs as a symptom of systemic disease, and rarely is the site of primary involvement in mediastinal disease. Lymphoma should be considered primarily in giant mediastinal masses in childhood.

Keywords: Computerized tomography, mediaestinum, lymphoma

[Abstract:0733] EPS-061 [Accepted: E-Poster] [Diagnostic Methods]

Hitit University Department of Pulmonary Medicine First Year EBUS Experience

Sertaç Arslan¹, Özlem Erçen Diken¹, Güven Güney², Ayşe Yılmaz¹, Meral Gülhan¹

¹Department of Pulmonary Medicine, Hitit University School of Medicine, Çorum, Turkey

²Department of Pathology, Hitit University School of Medicine, Çorum, Turkey

Objectives: Endobronchial ultrasonography (EBUS) is a precious method for sampling mediastinal leisons. We evaluated results of 64 patients who were our first year EBUS patients between 2016 June- 2017 June.

Methods: Patient results were evaluated retrospectively. Sixty-four patients were included. SPSS 21 was used for statistical analysis.

Results: Mean age of patients was 62.4. Forty patients (62.5%) were male, 24 (37.5%) were female. Diagnostic sampling was achieved at 52 patients (81.3%) (97/112 [86.6%] lymph node) (Figure 1). Most frequent sampled lymph node was station 7 (34/39 successful sampling). In the manner of sampling technique, although station 4L can be sampled harder than 4R, successful sampling scores were (8/9 [88.8%]) and (28/33 [84.8%]) respectively. Successfully sampled stations were not different from unsuccessful sampled ones. Within successfully diagnosed group, 26 patients (50%) were malignant -22 (42.3%) of them were lung cancer. Four patients diagnosed small cell lung cancer, 11 patients were squamous cell carcinoma, 6 were adenocarcinoma, 1 patient was non-small cell lung cancer with undetermined subtype. One patient who couldn't be diagnosed by EBUS, was diagnosed leukemia by peripheral lymph node biopsy; and 1 patient was diagnosed neuroendocrine tumor by lobectomy. Six patients needed further diagnostic procedures. Five of them had malignant, 1 had benign diseases as final diagnosis. One patient had tuberculosis, whose pathology resulted as granulomatous disease with caseified necrosis. Seven patients (13.5%) were diagnosed as sarcoidosis (Figure 2).

Conclusion: Diagnostic sensitivity of EBUS for mediastinal involvement of lung cancer in several meta-analyses varies from 88% to 93%. Sensitivity for sarcoidosis varies from 54% to 93%. Our results are compatible with the literature. EBUS is a precious method with high diagnostic results even at clinics with limited experience.

Keywords: Endobronchial ultrasonography, mediastinal lesions, cancer

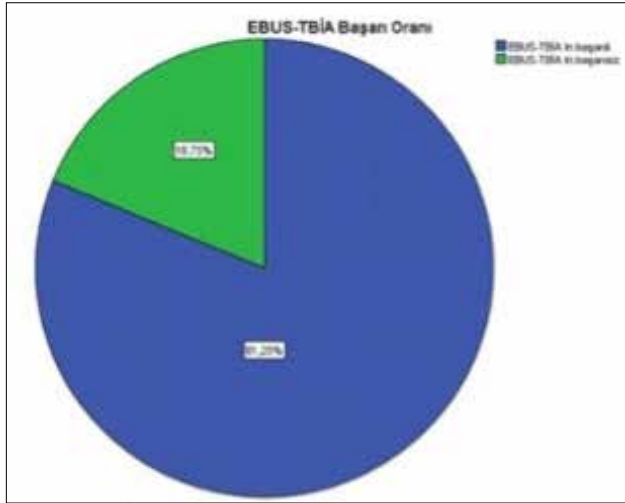


Figure 1. EBUS-TBNA success rate

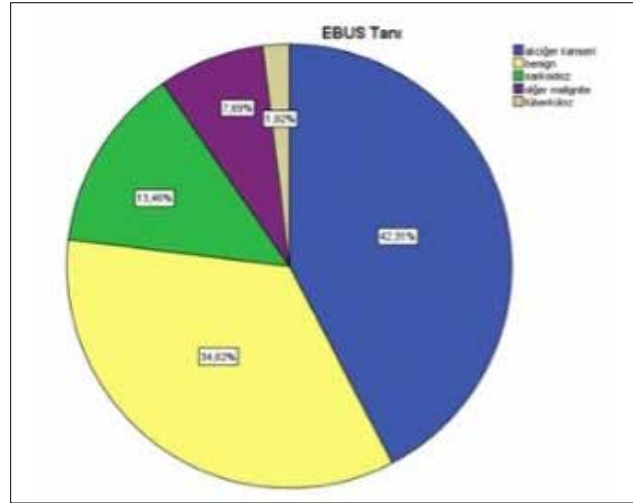


Figure 2. EBUS diagnostic distribution

[Abstract:0734] EPS-261 [Accepted: E-Poster] [Thoracic Surgery]

A Rare Thoracic Wall Resection Indication: Fibromatosis

Gülşen Yılmaz, Erkmén Gülhan, Seray Hazer, Deniz Kaygusuz Tikici, Leyla Nesrin Acar

Department of Chest Surgery, Health Sciences University, Ankara Atatürk Chest Diseases and Chest Surgery Training and Research Hospital, Ankara, Turkey

Thoracic wall tumors can be originated from skin, muscles, fat tissue, nerves and veins, bone and cartilage tissues. Primary malignant tumors of the thoracic wall are rare. When considered together, soft tissue is the major source of primary thoracic wall tumors.

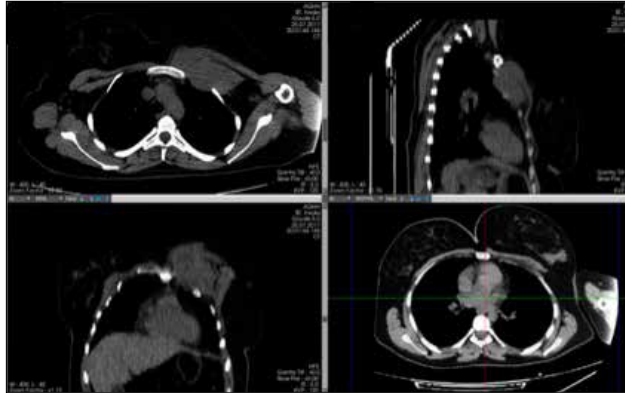


Figure 1. Lesion in left thorax wall in CT

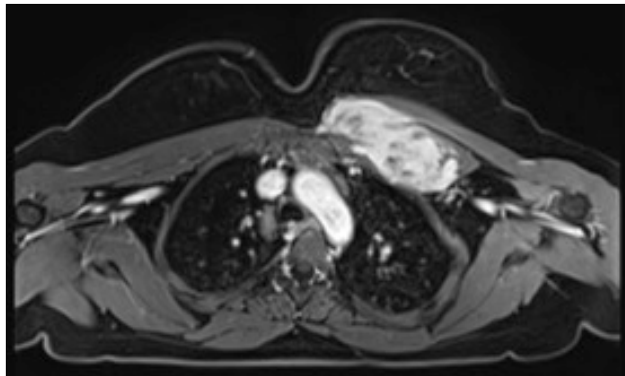


Figure 2. Lesion in left thorax wall in MR

Fibromatosis, one of the primary thoracic wall tumors, is a rare thoracic wall lesion. Although the reasons have not been well-defined, it is thought that factors such as trauma, hormonal disorders, past surgeries, genetic factors and Gardner's syndrome are thought to play a role in the development of the disease. There are two main groups according to their distribution as facial and muscular-aponeurotic tissue. Despite the fact that they are benign lesions, extensive resection is crucial because of the high local recurrence rate. In this case report, a 19 year-old female patient who was operated due to fibromatosis on the thoracic wall and diagnosed with primary thoracic wall tumor was evaluated.

Keywords: Thoracic wall tumors, Fibroblastoma, Soft tissue tumors

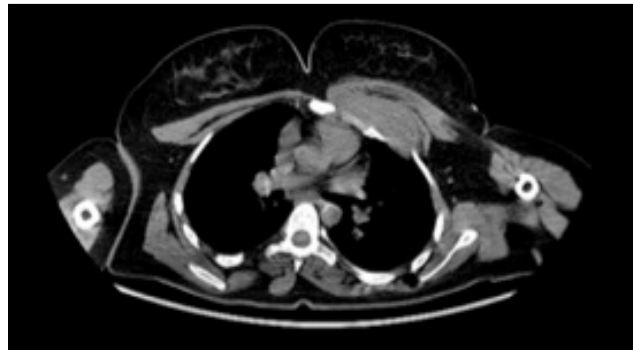


Figure 3. Lesion in the left thorax wall in Positron Emission Tomography- computed tomography (PET-CT)

[Abstract:0739] EPS-203 [Accepted: E-Poster] [Thoracic Surgery]

Interesting Foreign Body Aspiration: Voice Prosthesis

Hüseyin Ulaş Çınar¹, Burçin Çelik², Salih Bilgin³¹Clinic of Thoracic Surgery, Medicana International Hospital, Samsun, Turkey²Department of Thoracic Surgery, Medical Faculty, Ondokuz Mayıs University, Samsun, Turkey³Clinic of Pulmonary Disease, Medicana International Hospital, Samsun, Turkey

Introduction: Foreign body aspirations are still an important health problem today. Airway aspirations can lead to life-threatening complications in the early stages or various lung diseases in the late period. In this study, we attempted to present a localized voice prosthesis aspiration in the left main bronchus, which causes severe respiratory failure in an elderly patient.

Case Presentation: A 83-year-old male patient was admitted to the emergency department with complaints of dyspnea and was followed up in our intensive care unit with an initial diagnosis of pneumonia and massive pleural effusion. Radiological findings of the patient who underwent total laryngectomy because of laryngeal carcinoma two years ago detected a foreign body causing total opacity in the left lung (Figure 1). Fiberoptic bronchoscopy revealed that the patient had aspirated voice prosthesis. By rigid bronchoscopy, the prosthesis was removed from the distal part of the left main bronchus without complication (Figure 2). The clinical findings of the patient were dramatically improved following the removal of foreign body.

Discussion: Life-saving early intervention is crucial, because of the foreign body aspiration can cause complications, even if it is asymptomatic. Bronchoscopy is highly recommended for the definitive diagnosis and treatment of such cases in the presence of clinical suspicion. It should be kept in mind that the patients with laryngectomies can aspiration the voice prostheses in rare cases.

Keywords: Aspiration, voice prosthesis, foreign body

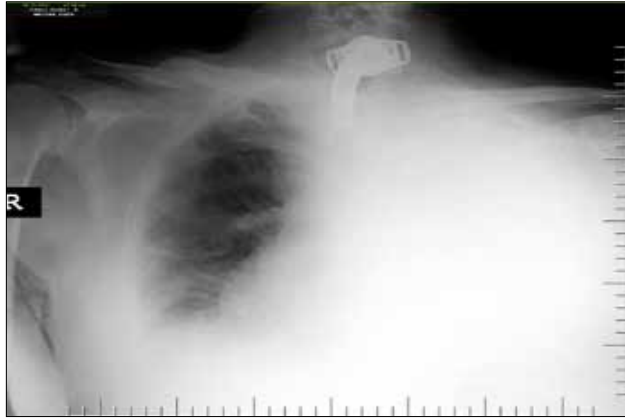

Figure 1. Total opacity in left hemithorax, detected on PA chest X-ray at the time of admission

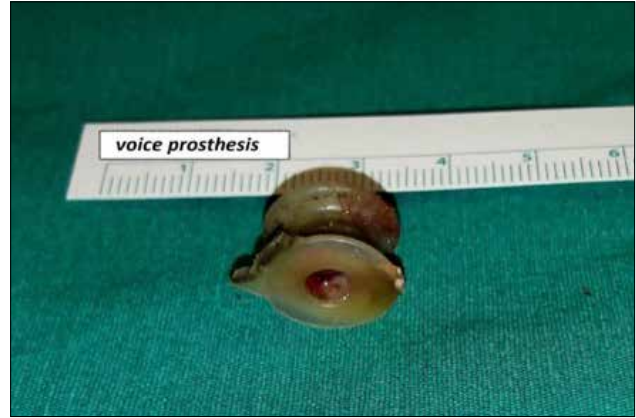

Figure 2. Voice prosthesis removed from left main bronchus by rigid bronchoscopy

[Abstract:0745] PS-307 [Accepted:Poster Presentation] [Respiratory Infections]

Chronic Multidrug Resistant *Burholderia Cepacia* Colonization with Superimposed Influenza A and Fulminant Course in a Patient with Cystic Fibrosis

Ceren Değirmenci¹, Oğuz Karcıoğlu¹, Çağkan İnkaya², Ebru Ortaç Ersoy³, Deniz Doğru Ersöz⁴, Ebru Çelebioğlu¹, Ali Fuat Kalyoncu¹¹Department of Chest Diseases, Hacettepe University School of Medicine, Ankara, Turkey²Department of Infectious Diseases and Clinical Microbiology, Hacettepe University School of Medicine, Ankara, Turkey³Section of Medical Intensive Care Unit, Department of Internal Medicine, Hacettepe University School of Medicine, Ankara, Turkey⁴Division of Pediatric Chest Diseases, Hacettepe University School of Medicine, Ankara, Turkey

Introduction: Chronic *Burkholderia cepacia* complex colonization in cystic fibrosis (CF) is usually associated with poor prognosis. A 22-year-old male patient with CF who had a chronic *B. cepacia* colonization and was complicated with acute influenza virus infection was presented.

Case Presentation: A 22-year-old male patient, with the diagnosis of CF since he was 2 months old, was admitted to emergency department on December 2017 complaining of shortness of breath. He had chronic colonization with *B. cepacia* for one year and had two previous admissions for intravenous antibiotic treatment during the preceeding year. He had been followed by pediatric pulmonology department until he was 16 years old and had regular follow up visits, but for the last 6 years he was noncompliant. On admission he was not febrile, his respiratory rate was 33/min, and had crackles on bilateral upper lung fields. Chest radiograph showed no new infiltrates and was similar compared to previous ones. Sputum cultures were obtained and empirical antibiotics with trimetoprim/sulfametaksazol and meropenem were initiated that were changed to ceftazidime, colistin and amikasin after 8 days because of multidrug resistant *B. cepacia* growth on sputum culture. He received continuous nasal oxygen and intermittent noninvasive mechanical ventilation but had little clinical benefit. On 30th day of admission because his oxygen demand did not improve oseltamivir was added empirically and 1 day later Influenza A virus was shown on nasopharyngeal swab specimen that was not present on admission. After 29 days all antibiotics were stopped because of no benefit. There were new infiltrates on chest X-ray, blood leucocyte count, and CRP levels continued to increase. 400 mg/kg intravenous immunoglobulin treatment was given. In vitro susceptibility test revealed that the bacteria is susceptible to Avibactam that is not currently available on the market in Turkey, and was asked from Ministry of Health. Avibactam and ceftazidime treatment was planned, however patient continued to deteriorate, Influenza A virus was shown repeatedly and he refused intubation. After 4 days of emergency intubation and mechanical ventilation, he died on 45th day of hospitalization.

Conclusion: In this patient, chronic infection with multidrug resistant *B. cepacia* lead to rapid deterioration in pulmonary functions and frequent pulmonary exacerbations during the previous year that was further deteriorated because of superinfection with Influenza A virus.

Keywords: *Burkholderia cepacia*, cystic fibrosis, influenza

[Abstract:0748] EPS-140 [Accepted: E-Poster] [Pulmonary Rehabilitation and Chronic Care]

Is There a Relationship between Skeletal Muscle Functions and Respiratory Muscle Functions?

Beyza Nur Karadüz, Sena Teber, Naciye Vardar Yağlı, Melda Sağlam, Cemile Bozdemir Özel, Hülya Arkan, Ebru Çalık Kütükcü, Deniz İnal İnce

Department of Physiotherapy and Rehabilitation, Faculty of Health Sciences Hacettepe University, Ankara, Turkey

Objectives: In the literature, respiratory muscle strength is related to skeletal muscle strength. However, there was no study investigating the association between respiratory functions and other features of skeletal muscles' such as endurance and flexibility. The purpose of this study to investigate the relationship between skeletal muscle's endurance and flexibility and respiratory muscle strength and endurance.

Methods: Thirty healthy individuals (17 males, 13 females, mean age: 22.7±1.72 years) participated in the study. The flexibility was assessed by measurement of the lateral flexion distance (cm) and the quadriceps muscle endurance was assessed by the Squat-to-stand test. The number of repetitions was recorded. Respiratory muscle strength was determined by measuring maximal inspiratory muscle pressure (MIP) and expiratory muscle pressure (MEP) using a mouth pressure device. Respiratory muscle endurance was measured by sustainable time at 60% of MIP.

Results: The mean of the muscle flexibility were 20.06±3.88 cm, and the mean value of the Squat to stand test was 66.87±15.28. The mean MIP values were as 83.03±23.25 cmH₂O. The mean MEP were as 108.63±30.92 cmH₂O and the mean respiratory muscle endurance was 14878±14503.67 sec × cm H₂O. There was no statistically significant relationship among MIP, flexibility and skeletal muscle endurance (p>0.05). There was a relation between MEP and flexibility (r=0,468, p=0.009). There was a positive and moderate correlation between respiratory muscle endurance and skeletal muscle endurance (r=0.616, p<0.01).

Conclusion: In this study, there is an association with the respiratory muscles endurance and skeletal muscles endurance. This relationship should be investigated with larger samples and patient groups. The effects of the flexibility and muscular endurance training addition to pulmonary rehabilitation program should be examined with further studies.

Keywords: Respiratory muscles, quadriceps muscle, muscle strength

[Abstract:0749] PS-230 [Accepted:Poster Presentation] [Tobacco Control]

The Place and Importance of The Hooked on Nicotine Checklist (HONC) on Quitting Smoking Behaviour

Fatma Çiftci, Sümeyye Ayöz, Zeynep Pınar Önen, Elif Şen

Department of Chest Disease, Ankara University School of Medicine, Ankara, Turkey

Objectives: The disappearance of personal autonomy over smoking is a physical and psychological barrier to smoking cessation. The Hooked on Nicotine Checklist (HONC) is a ten-item screening test designed to evaluate the autonomy of smokers on cigarettes. In this study, it was aimed to investigate the relationship between HONC and smoking behaviors of patients.

Methods: Demographic characteristics (age, sex, marital status, occupation), comorbidities, smoking history (age of onset, number of cigarettes smoked, smoking cessation trials, supportive treatments) were taken from the patients who applied to the unit. The Hooked on Nicotine Checklist (HONC) questionnaire and the Fagerström Nicotine Dependence Test (NDT), both translated into Turkish, were administered with the necessary permission as the HONC Test (Table 1).

Results: 103 (65 E, 39 K) patients with a mean age of 45.6 ± 11.7 who applied to the smoking cessation unit between 2017-2018 were included in the study. The age of onset of cigarette smoking was 16.8 ± 4.9 and smoking amount was 28.02 ± 14.39 packs/year. 76 (73.8%) had previously tried to quit smoking, 63 (61.2%) had no professional support for smoking cessation,

12 (11.7%) patients has previously used drugs to quit smoking. A statistically significant relationship was found between HONC with mean score of 8.5 ± 1.7 and NDT with mean score of 6.1 ± 2.6 ($r=0.438$, $p<0.001$). There was a significant relationship between HONC and NDT with age ($r=0.423$, $r=0.327$), smoking initiation age ($r=0.351$, $r=0.284$) (<0.001), no difference was found between the males and females in HONC and NDT scores ($p=0.09$, $p=0.38$, respectively). There was a significant relationship between the increase in the amount of cigarettes smoked over time and HONC ($r=0.231$, $p=0.02$). There was no significant difference between the education level, marital status and occupational groups in HONC and NDT scores. $p=0.308$, $p=0.390$, having to leave before ($p=0.47$, $p=0.917$), receiving professional support ($p=0.279$, $p=0.643$) ($p=0.202$, $p=0.602$) and duration of discontinuation ($p=0.148$, $p=0.690$) were not significantly correlated with both HONC and NDT.

Conclusion: High HONC scores are correlated with age, intensive smoking during lifetime, a smaller age at initiation of cigarette smoking, an increase in cigarette consumption over time, and a higher level of nicotine addiction. It reflects lifelong cigarette smoking behavior. In patients with high HONC score, appropriate pharmacological treatment should be recommended due to intense smoking, early age of onset, increase in the amount of smoking over time.

Keywords: Fagerström nicotine dependence test, the hooked on nicotine checklist (HONC), smoking cessation behaviour

Table 1.

	YES	NO
1. Have you ever tried to quit smoking, but couldn't?		
2. Do you smoke now because it is really hard to quit?		
3. Have you ever felt like you were addicted to tobacco?		
4. Do you ever have strong cravings to smoke?		
5. Have you ever felt like you really needed a cigarette?		
6. Is it hard to keep from smoking in places where you are not supposed to? 16.25.19.20.14 When you tried to stop smoking... (or, When you haven't used tobacco for a while...)		
7. Did you find it hard to concentrate because you couldn't smoke?		
8. Did you feel more irritable because you couldn't smoke?		
9. Did you feel a strong need or urge to smoke?		
10. Did you feel nervous, restless, or anxious because you couldn't smoke?		
TOTAL SCORE		
The Hooked on Nicotine Checklist (HONC)		

[Abstract:0754] SS-068 [Accepted:Oral Presentation] [Health Policies]

In 2050, Will One of Four Deaths be from Respiratory Diseases?

Sedat Altın, Nurdan Kalkan, Gülşah Günlüoğlu, Demet Turan, Binnaz Zeynep Yıldırım

Health Sciences University Yedikule Chest Diseases and Surgery Research and Training Hospital, İstanbul, Turkey

Objectives: Respiratory system deaths increase more rapidly than population growth and general deaths. For this reason, we aimed to estimate the mortality rate in 2050 by making future projections.

Methods: Using the TUIK death statistics for years 2009-2016, the mortality rates of 2023 and 2050 were calculated by means of time series taking into account the increase or decrease percentages. These proportions were applied to the TUIK population projections and the general and respiratory system expected death figures for the year 2050 were found. The number of deaths expected by increase or decrease percentages by sex and age groups was calculated. The expected rate of crude deaths in 2023 was 7.1, and in 2050 it was 9.7 at 1000.

Results: Respiratory system deaths account for 11.9% of deaths in 2016. Between 2009 and 2016 deaths increased by 42.2% in males and 49.1% in females, respiratory system deaths increased by 79.2% in males and 94.2% in females, compared to 119.5% for females. As can be seen, respiratory system deaths in women were 2.4 times higher than general deaths and 1.9 times more in men. The expected population in 2023 will be 84247088 and the proportion of population over 65 will increase to 10.2% and this rate will be found to be 11.4% for women in TUIK population projections. Using this time series of data, it was estimated that respiratory system deaths would reach 94229% with 15.9% of the total deaths, which would approach 600.000 (593.607) by 2023. In 2050, it is determined that the death rate of respiratory system which will reach to 271,679,24% of 1,130,189 deaths in total will increase to 15.8% in 2023 and 25.8% in 2050 in women. The highest increase in respiratory disease-related mortality rates between 2009 and 2016 was pneumonia-related deaths of 72.4% per annum, followed by chronic lung diseases (COPD, asthma and bronchiectasis) with an annual increase of 7.6% it was estimated that the deaths remained at an annual rate of 4.95%. According to this, in 2023, 52.926 deaths (56.2% of respiratory deaths) and 41.025 (43.5%) deaths due to pneumonia were calculated. By 2050, deaths are expected to reach 208.242 (76.7%) and 63.226 (23.3%), respectively. Also interestingly, it is estimated that respiratory system deaths, which are higher in male deaths from the beginning (male/female mortality rate in 2016 to 1.36), will reverse in 2050 (in 2023 to 1.14 in 2050 to 0.91).

Conclusion: The fact that deaths due to respiratory system diseases, one of the 10 deaths nowadays, is one of the four deaths in 2050 is thoughtful in terms of our expertise. At the very least, this fast-turn should at least focus on policies to reduce speed.

Keywords: Time series method, respiratory system deaths, projection

[Abstract:0755] EPS-219 [Accepted: E-Poster] [Thoracic Surgery]

The Use of Videothoracoscopy for the Diagnosis of Pleurisy of Unclear Etiology

Barat İsak Bayramov, Rafik Behmen Kerimov, İlgar Almas Mustafayev

Research Institute of Lung Diseases, Baku, Azerbaijan

Objectives: The number of patients with pleurisy of unclear etiology is increasing every year. Antibiotic therapy without cytological, microbiological, immunological analysis of pleural fluid often leads to ineffective treatment and worsening of patients Goal. Application videotorakoskopii (WATS) with the acquisition of biopsy materials and their study at the histomorphological level.

Methods: For the period from 2010 to 2016 g. 143 patients were examined: men had 95 cases (66.4%), women -48 (33.6%). The age of patients ranged from 18 years to 60 or more. All these patients underwent videotouracoscopic examination under intubation anesthesia with separate intubation. During the study, materials were taken in the form of pleural effusion, as well as pieces of parietal and visceral pleura from various sites. The material taken was studied histomorphologically and bacteriologically.

Results: According the results of the study, pleurisy of specific (tuberculous) etiology was revealed in 87 patients (60.8%). The diagnosis was confirmed by additional specific methods of investigation. In 23 patients (16.6%), was diagnosed pleurisy of non-specific etiology caused by gram-positive and less frequently gram-negative flora. Pleurisy of tumor etiology was revealed in 33 patients (23%). Exudative pleurisy of traumatic etiology was not included in this study. All patients routinely used WATS research methods under the control of the monitor and selectively sampled the material. This method was used to examine 143 patients.

Conclusion: 143 patients underwent 148 video-sonography studies. Thus, the results of the study showed that WATS is the most effective diagnostic method for examination in effeminate pleurisies, in contrast to other methods.

Keywords: Videotorakoskopii, pleurisy, biopsy materials

[Abstract:0756] EPS-156 [Accepted: E-Poster] [Respiratory Infections]**A Case of Actinomycosis with Pleural Effusion**Demet Polat¹, Eylem Sercan Özgür¹, Erhan Ayan², Mehmet Yıldız³, İsmail Sert¹, Gülden Ersöz⁴¹Department of Chest Disease, Mersin University School of Medicine, Mersin, Turkey²Department of Thoracic Surgery, Mersin University School of Medicine, Mersin, Turkey³Department of Pathology, Mersin University School of Medicine, Mersin, Turkey⁴Department of Clinical Bacteriology and Infectious Diseases, Mersin University School of Medicine, Mersin, Turkey

Pulmonary actinomycosis clinically or radiologically imitates tuberculosis, pulmonary abscess or lung cancer. 53-years-old man was admitted to our hospital with complaint of right chest pain. There was no complaints of fever, cough, shortness of breath, weight loss. He had a history of smoking 40 packs/year. No related features were found in his medical history. On examination, vital signs were normal; patient was well looking, had decreased breathing sounds over right lung bases, and normal cardiovascular and abdominal examination. Laboratory parameters were as follows: leukocyte count: 7.7/mm³, C-reactive protein: 94.5, sedimentation: 49 mm/h. Posteroanterior chest radiograph shows a large area of increased homogeneous density in the right hemithorax (Figure 1). Thorax CT revealed pleural thickening with pleural fluid in right hemithorax (Figure 2). Multiple millimetric nodules were detected in both lung parenchyma. PET/CT is planned due to pleural fluid and multiple pulmonary nodules. Levofloxacin therapy was started. Pet scans shows increased FDG uptake in the pleural thickening area of the right hemithorax uptake (SUV max: 6.5, Late SUVmax=8.2). There was nodular lesion with increased FDG uptake in the left upper lobe of the lung (SUVmax=3.1, late SUVmax=5) (Figure 3). Diagnostic VATS was performed by the chest surgeon. In the pathological examination of the materials, suppurative pneumonia, abscess foci were detected. Suspect 1-2 areas suggesting actinomycosis were detected. The patient was treated with IV penicillin for 1 month. Oral penicillin was started after IV penicillin treatment. At 4th month of treatment, control

Thorax CT revealed that the pleural fluid in the right lung was regressed. We are presenting this case to remind the clinicians that pulmonary actinomycosis should also be considered in the differential diagnosis of pulmonary malignancy.

Keywords: Malignancy, pleural effusion, pulmonary actinomycosis

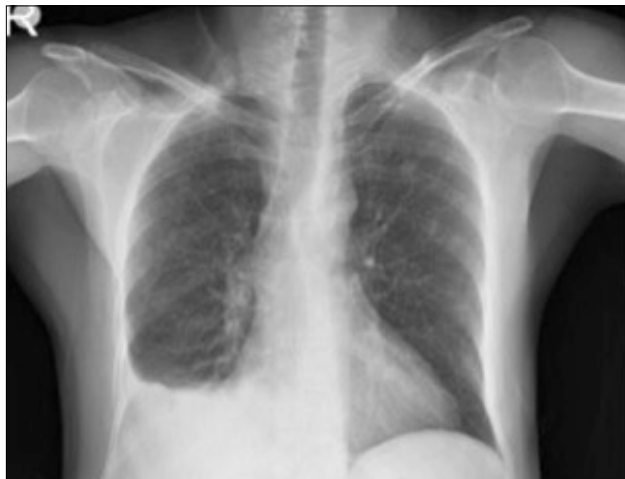

Figure 1. Posteroanterior chest radiograph shows a large area of increased homogeneous density in the right hemithorax

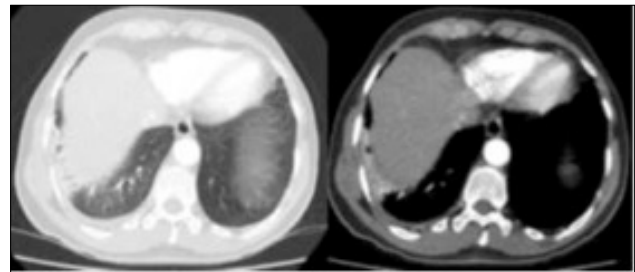


Figure 2. Thorax CT revealed pleural thickening with pleural fluid in right hemithorax

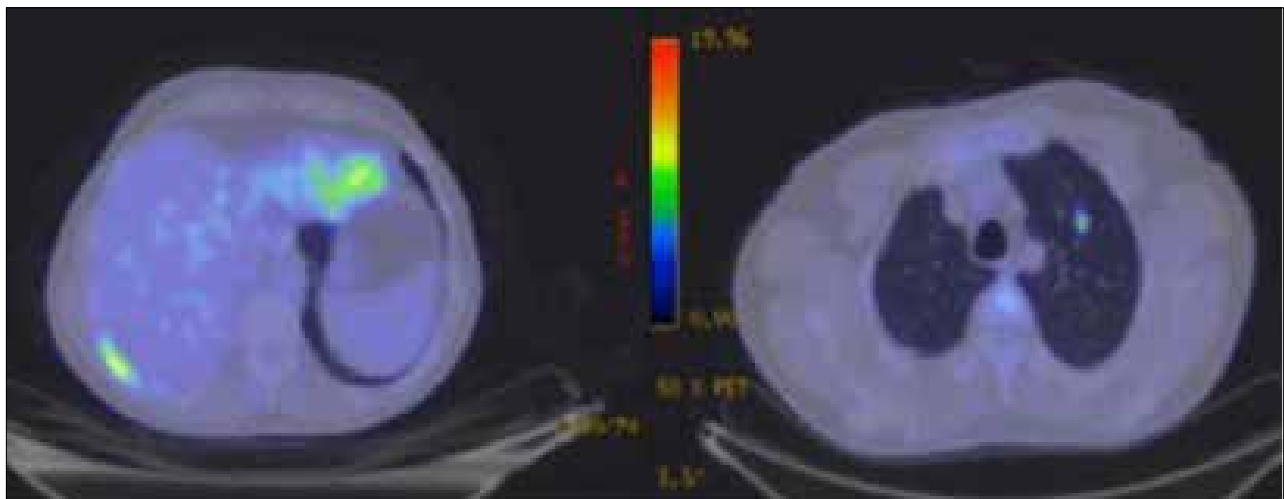


Figure 3. Pet scans shows increased FDG uptake in the pleural thickening area of the right hemithorax uptake (SUV max: 6.5, Late SUVmax=8.2) . There was nodular lesion with increased FDG uptake in the left upper lobe of the lung (SUVmax=3.1, late SUVmax=5)

[Abstract:0758] SS-100 [Accepted:Oral Presentation] [Thoracic Surgery]

The Role of Surgical Treatment in the Control of Chronic Infection For Patients with Non-Cystic Fibrosis Bronchiectasis

Selçuk Gürz¹, Ayşen Taslak Şengül¹, Yasemin Bilgin Büyükkarabacak¹, Burçin Çelik¹, Halil Kolcu¹, Mehmet Gökhan Pirzirenli², Ahmet Başoğlu¹

¹Department of Thoracic Surgery, Ondokuz Mayıs University School of Medicine, Samsun, Turkey

²Ministry of Health Şanlıurfa Training and Research Hospital, Şanlıurfa, Turkey

Objectives: Bronchiectasis is a chronic lung disease characterized by coughing and purulent sputum, recurrent infections, and airway injury leading to severe morbidity and mortality. At the present time, besides treatment of acute infection with antibiotics, surgical treatment option is applied to selected patients with quality of life impairment. In this study, we aimed to evaluate the patients who have been receiving treatment and follow-up for non-cystic fibrosis bronchiectasis in our clinic.

Methods: In this study, 65 cases of non-cystic fibrous bronchiectasis who admitted in Ondokuz Mayıs University, School of Medicine, Thoracic Surgery Clinic between 2007 and 2017 were examined retrospectively in terms of age, gender, symptom, bronchiectasis type, treatment modalities, follow-up period, morbidity and mortality.

Results: From the 65 patients with a mean age of 40±15.8 included, 67.7% (n=44) were female and 32.3% (n=21) were men. Patients were most frequently admitted with complaints of cough sputum (35.4%). The symptoms for 45.1% of the patients started less than 1 year ago, but 27.5% of the patients had complaints from childhood. On the radiological examination, it has been found out that 49.2% (n=32) of the patients had cystic and 36.9% (n=24) of the patients had tubular type bronchiectasis. Surgical treatment was applied to 41.5% (n=27) of the patients. Lobectomy amongs surgical procedures was applied to 82.2% of patients and segmentectomy was applied to 17.8% of patients. Morbidity rate was 14.3% and mortality was seen in 1 patient. 77.7% (n=21) of the surgically treated patients did not have recurrent infection attacks.

Conclusion: Surgical treatment has an important role in non-cystic fibrosis bronchiectasis. In appropriate patients, the anatomic resection of the bronchiectasis zone of the lung is a safe method of improving quality of life and may be applied to control chronic infection.

Keywords: Bronchiectasis, infection, non-cystic fibrosis, surgery

[Abstract:0760] PS-261 [Accepted:Poster Presentation] [Diagnostic Methods]

Could We Use SUVmean Values for Thoracic Typical Carcinoid Tumors?

Cumhur Murat Tulay¹, Feray Aras², Demet Yaldiz³

¹Department of Thoracic Surgery, Manisa Celal Bayar University School of Medicine, Manisa, Turkey

²Department of Nuclear Medicine, Manisa Celal Bayar University School of Medicine, Manisa, Turkey

³Thoracic Surgery Clinic, Dr. Suat Seren Chest Medicine and Thoracic Surgery Hospital, İzmir, Turkey

Objectives: Carcinoids account for less than 1-5 % of all pulmonary malignancies. Pulmonary carcinoids have significantly better prognosis compared to the other pulmonary malignancies. F-18 FDG PET/CT is useful in detecting lung carcinoids, its metastases and recurrence. F-18 FDG uptake value is variable in bronchial carcinoids. We aimed to investigate whether the correlation between Ki-67 index and standard uptake values (SUVmax, SUVmean) in typical lung carcinoid tumors in our study.

Methods: Retrospectively, twenty eight patients with thoracic mass which were diagnosed as typical carcinoid were in this study. F-18 FDG PET/CT was performed to all patients before operation. Patients were operated by thoracic surgery clinic. There were no pathological F-18 FDG uptake in other areas of the whole body. We calculated SUVmax and SUVmean values of lesions that drawn region of interesting area by determining different cut-off value (2.5 and 0.5). We take care to draw only the lesion in the field of interest excluded of atelectatic area.

Results: Twenty-eight patients were included in the study, (13 female and 15 male) the mean age was calculated as 45. All patient's pathologic diagnoses were diagnosed as typical carcinoid. Paranchymal lesion was determined in 8 patients and endobronchial lesion in 20 patients. Mean of Ki-67 index was approximately 3-4% (range 1%-10%). PET/CT scan results were interpreted as positive when the lesion activity was greater then the background mediastinal pool and lung activity. We have not detected post- resection relapse or death in 3 years follow-up period. Spearman correlation test was used for statistical analysis. SUVmean1 and SUVmean2 values were statistically significant when compared with SUVmax1 and SUVmax2 values ($p<0.05$) (Table1).

Conclusions: We considered that in lung carcinoid tumors in addition to mitoses, SUVmean, Ki-67 index might be an important prognostic indicator identifying high risk subsets of patients for whom multimodal therapy may be

considered for management. We want to emphasize significance and necessity of F-18 FDG PET/CT imaging of localized parenchymal and bronchial typical carcinoids. We thought that Ki-67 indexes may be well-matched with SUVmean values. SUVmean values could be use for lung carcinoid tumors. Lower cut-off values could be more compatible with typical carcinoid tumors for diagnosis and prognosis.

Table 1. Mean SUVmax-SUVmean Values

Mean SUVmax (cut-off 2.5)	Mean SUVmax (cut-off 0.5)	Mean SUVmean (cut-off 2.5)	Mean SUVmean (cut-off 0.5)
(2.64 – 11.06)	(2.64 – 11.06)	(2.62 – 4.58)	(1.17 – 4.15)
5.35±2.72	5.35±2.72	3.36±0.76	2.02±0.89

Keywords: FDG PET-BT, karsinoid, torasik kitle

[Abstract:0765] PS-022 [Accepted:Poster Presentation] [Clinical Problems - Diffuse Parenchymal Lung Disease]

Idiopathic Pleuro-parenchymal Fibroelastosis: Due to a Case

Cengizhan Sezgi, Mahşuk Taylan, Hatice Selimoğlu Şen

Department of Chest Diseases, Dicle University School of Medicine, Diyarbakır, Turkey

Introduction: Idiopathic pleuroparenchymal fibroelastosis (IPPFE) is a rare interstitial lung disease with subpleural pulmonary parenchyma and visceral pleura involvement especially in the upper lobes. In the lung parenchyma, excessive collagen and elastic tissue are stored, and the visceral pleura is a homogenous in the form of a thick elastic band. The etiology and pathophysiology of the disease have not been fully understood. It clinically develops fast and has had poor prognosis. There is no effective treatment option other than lung transplantation. A familial predisposition may be seen in the disease. We presented this case because IPPFE is a very rare pulmonary disease and our case had IPPFE in the family history and the disease has a rapid progression.

Case Presentation: Thirty-six year old male patient was examined at a health institution with chest pain and cough complaints four years ago. No significant pathology was detected in the examinations performed. The patient was referred to our hospital for further examination after the increase in his complaints and the addition of the effort dyspnea. No obvious cardiac, vascular or infectious disease was found in the patient. The thoracic computed tomography (CT) performed in December 2014 revealed subpleural irregularities in the upper lobes of both lungs, reticular densities and fibrotic changes in the apical segments. Mild restriction was observed in spirometride but blood gas results were observed within normal limits. The patient had been hospitalized numerous times, but no reason was detected to explain the interstitial lung disease. The patient was admitted to the hospital in November 2017 with the complaint of repeated effort dyspnea and numbness in his legs. The patient was considered as IPPFE because the Thoracic CT showed significant increases of subpleural reticular densities in the upper lobes, fibrotic changes in the apical segments and thickening of the pleura was present. When a detailed anamnesis was taken, it was stated that two of his family members died in a similar way at a young age. The spirometric evaluation revealed that the restriction became evident and was desaturated with effort. In the neurology consultation, polyneuropathy was detected in the patient.

Conclusion: IPPF is a rare form of interstitial pulmonary disease. It is a diagnosis that should be considered in patients with widespread fibrinous in subpleural pulmonary parenchyma and with pleural thickening in the upper lobes. That the disease is seen among young people, IPPFE in the family history and presence of rapid progression will be important in distinguishing it from other diseases.

Keywords: Idiopathic Pleuroparenchymal fibroelastosis, pleural thickening, upper lobe involvement

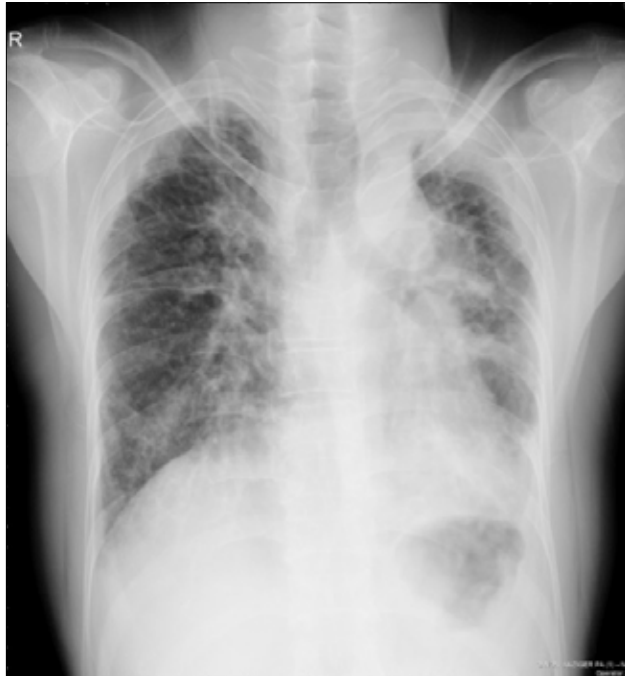

Figure 1. Chest radiography

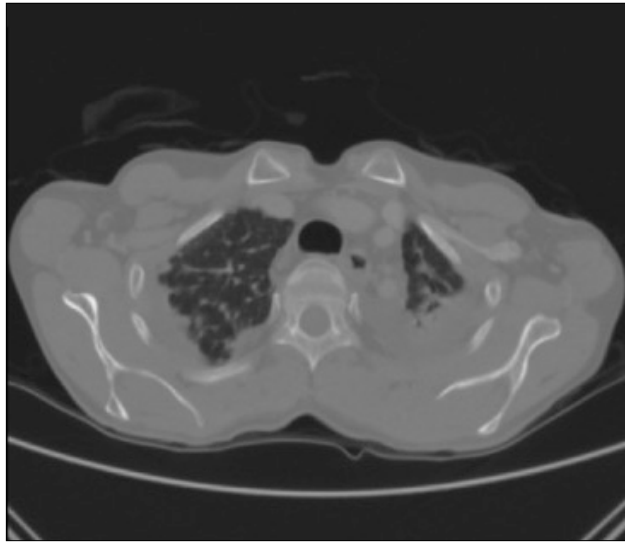


Figure 2. Thoracic CT sections-1

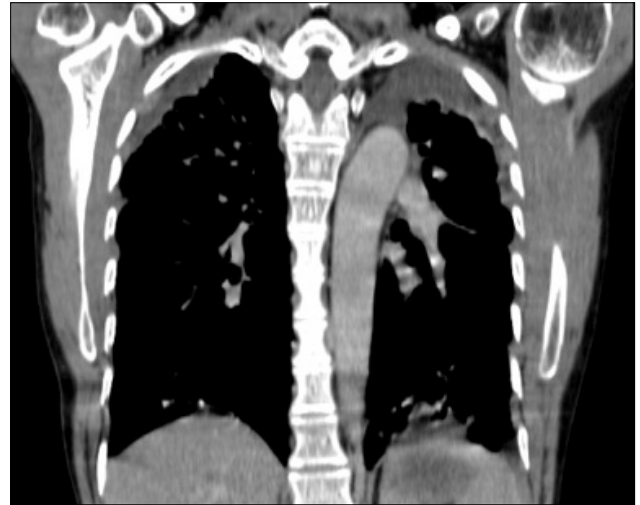


Figure 3. Thoracic CT sections -2

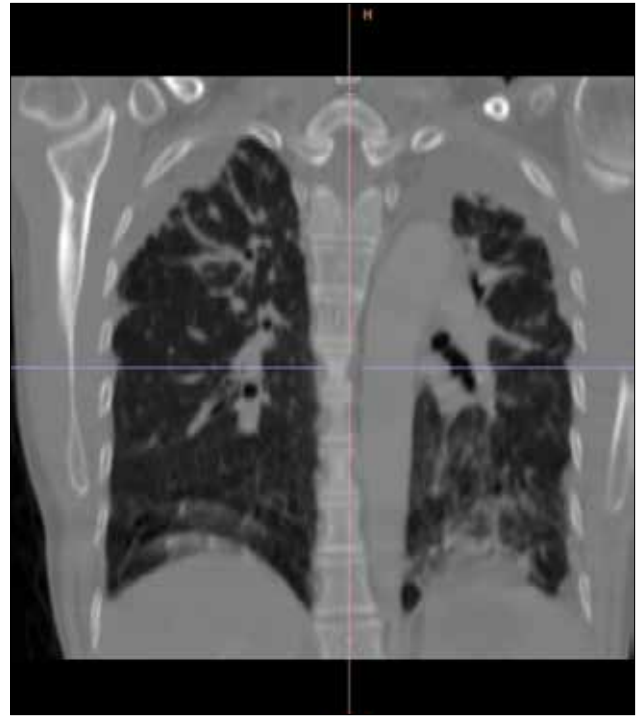


Figure 4. Thoracic CT sections -3

[Abstract:0767] EPS-062 [Accepted: E-Poster] [Diagnostic Methods]

Radiological Methods of Investigation in Differential Diagnosis of Small Bronchial Diseases in Children

Züleyha Zakir Sardarova, İlgar Almas Mustafayev, Giymet Xasay Mursalova

Research Institute of Lung Diseases, Baku, Azerbaijan

Objectives: Among all chronic bronchopulmonary diseases, the greatest difficulties arise in the diagnosis of chronic diseases of small bronchi. In recent decades, computer tomography (CT) is increasingly being used in respiratory medicine, which significantly expands the possibilities for in-depth and detailed study of pathological changes in the bronchopulmonary apparatus of the bronchi, the clinical manifestations of which are bronchial obstruction.

To evaluate the role of CT in differential diagnosis of BMB.

Methods: 139 patients with COB, 103 children with BPD, and 113 children with asthma aged 1 month to 15 years old were under observation. Radiography / computed tomography was used in 88% / 16% of patients with asthma, 94%/77% of children with COB and 100%/58% of patients with BPD, respectively.

Results: Studies were conducted in the acute stage of the disease. Irreversible symptoms (transpulmonary cords, fibrosis areas, pleuropulmonary adhesions) did not occur in any case of asthma, whereas when compared in 12 children with COB and 16 patients with BPD, this symptom took place and was significantly high. In 40 children with BPD and 28 - with COB and in 2-arm BA, hyperinflation was revealed. One of the most common signs in patients with BPD was the presence of atelectasis and distelectase in 35 cases, whereas in COB it was detected in 7 patients. The reinforcement of the interstitial pattern, almost at the same frequency, occurred in all 3 groups and, therefore, was not pathognomonic for any particular nosological form. Bronchiectasis was found in 8 cases with COB, which was a reliable sign for this nosology.

Conclusion: An analysis of the results obtained showed that CT scan has a high diagnostic value, which makes it possible to detect irreversible changes that are characteristic of each nosology that are not determined by X-ray diffraction. This allows us to propose the use of CT in BMB in order to clarify the genesis and severity of the disease in children.

Keywords: Computed tomography, radiography, bronchial asthma, chronic bronchiolitis, bronchopulmonary dysplasia

[Abstract:0768] EPS-174 [Accepted: E-Poster] [Thoracic Surgery]

Is There Any Aggressive Surgery Need to Tumours of Typical Carcinoid?

Hakkı Ulutaş¹, Muhammet Reha Çelik¹, Mehmet Açar¹, İlham Gülçek¹, Emine Şamdancı²

¹Department of Thoracic Surgery, İnönü University School of Medicine, Malatya, Turkey

²Department of Pathology, İnönü University School of Medicine, Malatya, Turkey

Introduction: Carcinoid tumors; are rare seen and originated from bronchial Kuchitzky cells. Carcinoid tumors are malignant tumors and constitute 0.4%-3% of resected lung tumors. Three cases with typical carcinoid tumors treated with bronchoscopic resection were presented.

Case 1: 44-year-old male patient admitted to our clinic with cough and hemoptysis. A computerized thorax tomography; a endotracheal lesion in left lower tracheal area was detected. In fiberoptic bronchoscopy; a bright colored endotracheal lesion occluded near the left main bronchus on the left lower wall of the trachea. Biopsy result reported as typical carcinoid tumor. The lesion undergoing mechanical resection with rigid bronchoscopy was totally excised. Patient without postoperative complication was extubated on day 2. No additional pathology of the typical carcinoid tumor was found in the patient who was followed for 10 years.

Case 2: Forty-three years old a female patient who was admitted to our polyclinic with a complaint of dyspnea and cough. A computerized thorax tomography; endobronchial lesion narrowing the left lower and upper lobe bronchus was detected. In fiberoptic bronchoscopy; a brightly colored, soft vegetative endobronchial lesion was seen on the left main bronchus, narrowing the bronchus of the lower and upper lobes, allowing distraction. Mechanical resection with rigid bronchoscopy resulted in total excision of the lesion 1x1 cm. Uncomplicated patient was discharged on the first day and followed for 3 years without any problems.

Case 3: Fifty-four years old a female patient who was admitted to our polyclinic with a complaint of cough. A computerized thorax tomography; a minimal occlusive endobronchial lesion was found that allowed passage through the right intermediate bronchus to the distractor. In bronchoscopy; A soft, bright-colored endobronchial lesion of 1x0.5 cm distal to the intermediate bronchus was detected. The biopsy result is the patient reported as a typical carcinoid tumor. Mechanical resection was performed with bronchoscopy. Postoperative first day was discharged uncomplicated. The patient has been followed for 6 months.

Although typical carcinoid tumors are malignant tumors, they do not show aggressive course. For this reason, surgical approaches such as tracheal resection, bronchotomy, segmentectomy, sleeve resection, lobectomy, pneumonectomy should not be preferred and minimally invasive surgical methods should be preferred.

Keywords: Typical carcinoid, bronchoscopic, mechanical resection

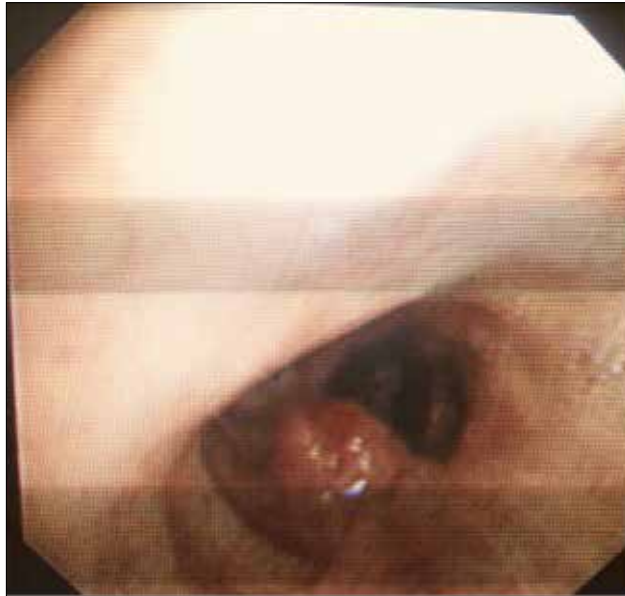


Figure 1. Preoperative bronchoscopic appearance

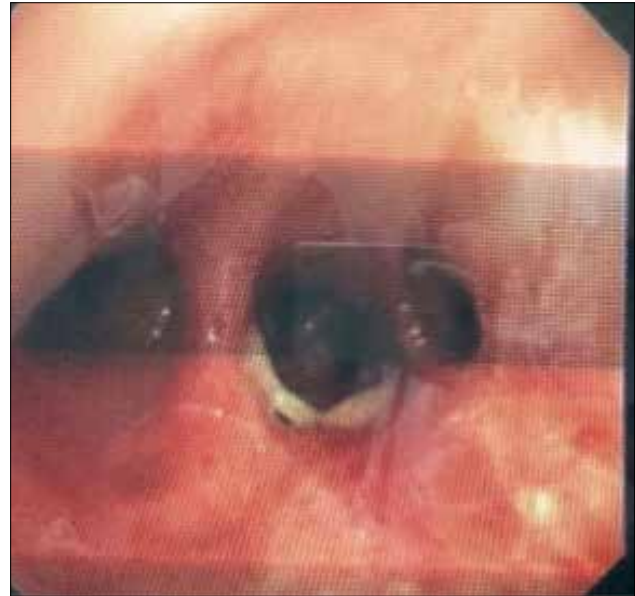


Figure 2. Postoperative 2nd month

[Abstract:0769] EPS-051 [Accepted: E-Poster] [COPD]

Secondary Pneumothorax Cases Mimicking COPD Exacerbation

Yakup Arslan, Cantürk Taşçı

Department of Pulmonary Disease, Health Sciences University Gülhane Training and Research Hospital, Ankara, Turkey

Introduction: Chronic Obstructive Pulmonary Disease (COPD) is a preventable and treatable chronic lung condition characterized by airflow limitation that is usually progressive and is associated with an abnormal inflammatory response in the lungs to noxious particles of gases, primarily caused by cigarette smoking. Exacerbations are heterogeneous events, and the clinical features vary widely. At the differential diagnosis of the exacerbation, pneumothorax, pneumonia and pulmonary embolism must be excluded. Three cases which were diagnosed as secondary pneumothorax while assessing the preliminary diagnosis of COPD exacerbations at the emergency service.

Case 1: 78-year-old man using LABA+ICS+LAMA+long term oxygen with the diagnose of COPD for 18 years was applied to the emergency service suffering from dyspnea. On the left hemithoracic auscultation, the respiratory voices were listened as decreased. The analysis of arterial blood gases were pH:7,98, pCO₂:115 mmhg, pO₂:108 mmhg, HCO₃:26.1 meq/lt (Fio₂ 40%). On the chest x-ray and thoracic tomography, the pneumothorax was seen on the left hemithorax (Figure 1, 2). Non-invasive mechanical ventilator and the chest tube were applied.

Case 2: 54-year-old man using LABA+ICS with the diagnose of COPD for 8 years was applied to the emergency service suffering from unconsciousness. On the right hemithoracic auscultation, the respiratory voices were listened as decreased. The analysis of arterial blood gases were pH:7,16, pCO₂:85 mmhg, pO₂:49,5 mmhg, HCO₃:27,4 meq/lt. On the chest X-ray, the pneumothorax was seen at the right hemithorax. Non-invasive mechanical ventilator and the chest tube were applied.

Case 3: 83 Year old man using LABA+ICS+LAMA+long term oxygen with the diagnose of COPD for 20 years was applied to the emergency service suffering from syncope. On the left hemithoracic auscultation, the respiratory voices were listened as decreased. The analysis of arterial blood gases were pH:7,07, pCO₂:83,8 mmhg, pO₂:46,6 mmhg, HCO₃:23,2 meq/lt. On the chest X-ray, the pneumothorax was seen at the left hemithorax. Invasive mechanical ventilator and the chest tube were applied.

Results: After applying chest tube, invasive/non-invasive mechanical ventilators, and medical treatment, the analysis of patients arterial blood gases analysis were controlled regularly. And the 6th. hour control results were respectively pH:7.26, pCO₂:69.6 mmhg, pO₂:70.8 mmhg, HCO₃:30.5 - pH:7.31-PCO₂:54.7 mmhg-pO₂:74.1 mmhg-HCO₃:26.7-pH:7.26-pCO₂:66.2 mmhg, pO₂:54.6-HCO₃:285.

Conclusion: One of the most frequent reason of secondary pneumothorax which is the prominent emergencies is COPD. This situation is usually happened as mimicking the exacerbations of COPD. It is essential to reduce the mortality by making diagnose and applying the thoracic tube early. We aimed to emphasize the importance of efficient differential diagnose of COPD exacerbations.

Keywords: Secondary pneumothorax, mimicking, copd exacerbation

[Abstract:0773] EPS-108 [Accepted: E-Poster] [Lung and Pleura Malignancies]

Giant Mass at Anterior Mediastinum; Mature Cystic Teratoma

Nazan Beyhan¹, Tuğba Mandal¹, Mehmet Emin Sezgin¹, Firdevs Atabey¹, Esin Yentürk¹, Güven Olgaç², Esin Tuncay¹

¹Department of Chest Diseases, Health Sciences University Yedikule Chest Diseases and Thoracic Surgery Training and Research Hospital, İstanbul, Turkey

²Department of Thoracic Surgery, Health Sciences University Yedikule Chest Diseases and Chest Surgery Training and Research Hospital, İstanbul, Turkey

Introduction: Anterior mediastinal masses are usually thymoma, lymphoma and germ cell tumors. Teratomas are germ cell tumors and may be benign or malignant, with equal frequency in men and women. Benign teratomas are capsular, partially solid, and partially cystic tumors. Besides, they have malignant potential, and may turn into sarcomas or carcinomas. We aim to present a rare case of teratoma which has not any symptoms other than fatigue until it reaches giant dimensions.

Case Presentation: A 26-year-old female patient admitted to our polyclinic with a complaining of fatigue. On the posteroanterior chest X-ray, a well-circumscribed mass of 15x10 cm extending to the pleura and filling 2/3 of both lungs was observed in the hilary region. The results of performed tests were WBC: 10.26 10e3/μL, LDH: 243 iu/L, CRP: 5.4 mg/L; apart from that there was no any other pathology. In tomography of the thorax, a mass of 10x15 cm in diameter was detected in the lobule cystic structure which covers anterior mediastinum. As per the pre-diagnosis of teratoma, thymic lesion; operation was decided to the patient at the surgical council. A cystic lesion 15x11x6 cm in size was excised from the patient who underwent thoracotomy. The patient who hadn't a development of postoperative complication and who had a mature cystic teratoma was discharged on the 7th day. The patient's follow-up to the outpatient clinic is ongoing.

Conclusion: Although benign mediastinal teratomas are rare, they may not cause symptoms until they reach very large sizes. However, being able to obtain complete cure with surgical excision is also good.

Keywords: Germ cell tumor, mature cystic teratoma, anterior mediastinal mass

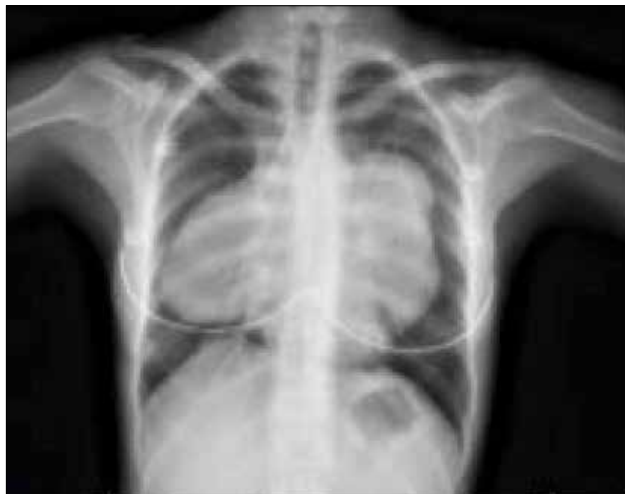

Figure 1. Preoperative chest X-ray

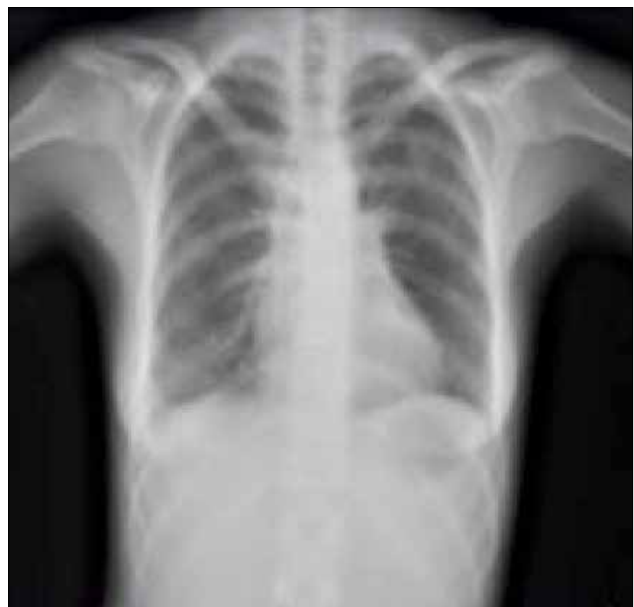

Figure 2. Postoperative chest X-ray

[Abstract:0775] EPS-070 [Accepted: E-Poster] [Diagnostic Methods]

Anisocoria Associated with Salbutamol-Ipratropium Bromide Combination

¹Department of Chest Diseases, Trakya University School of Medicine, Edirne, Turkey

²Department of Chest Diseases, Dörtyol State Hospital, Hatay, Turkey

³Department of Chest Diseases, İskenderun State Hospital, Hatay, Turkey

⁴Department of Anesthesiology and Reanimation, Dörtyol State Hospital, Hatay, Turkey

Medications containing ipratropium-bromide are frequently used as bronchodilators in the practice of chest diseases. A 72-year-old female patient was admitted to the outpatient clinic with complaints of coughing, wheezing, shortness of breath and sputum production.

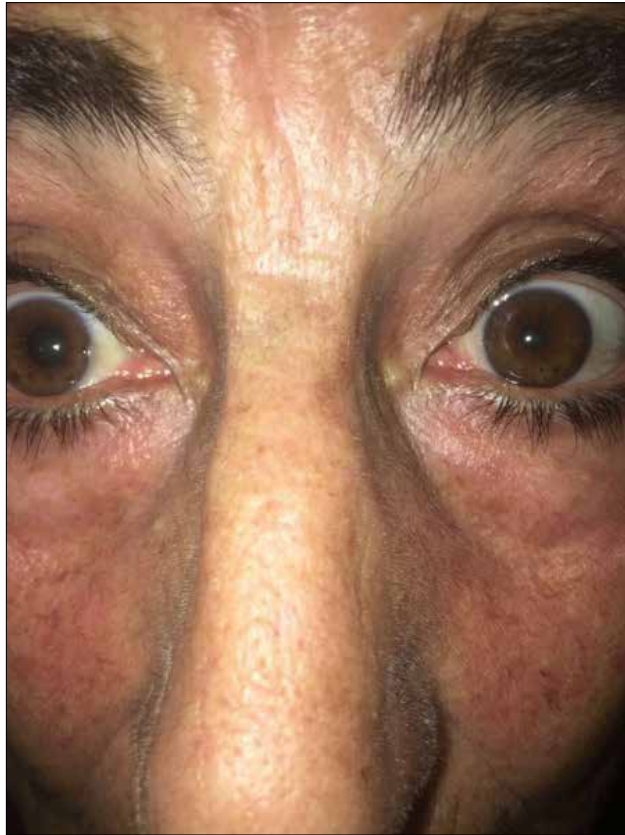

Figure 1.

The patient was hospitalized with the diagnosis of asthma. There was no problem other than asthma in her history. Bilateral diffuse rhonchus was present in the respiratory system examination. Other system examinations were normal. The patient was started on antibiotics, systemic steroids, salbutamol-ipratropium bromide and budesonide (nebulized form). During the treatment, it was detected that the patient developed unilateral mydriasis. In terms of anisochoriology, she was consulted by eye and neurology departments. Since no pathology was detected that can be considered as a reason for anisocoria, she was diagnosed with pharmacological mydriasis. The patient's inhalation treatment was changed to salbutamol by the cessation of salbutamol-ipratropium bromide. Our diagnosis was confirmed when the patient's pupil diameter returned to normal. Our case is a rare anisocoria case associated with salbutamol - ipratropium bromide use.

Keywords: Salbutamol-ipratropium, anisocoria, inhalation

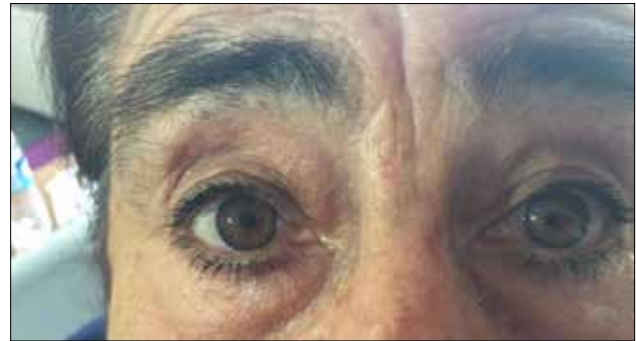

Figure 2.

[Abstract:0776] EPS-118 [Accepted: E-Poster] [Pediatric Pulmonary Diseases]

Evaluation of Quality of Life Questionnaire in Primary Ciliary Dyskinesia Patients

Almala Pınar Ergenekon¹, İbrahim Bingöl², Nilay Baş İkizoğlu¹, Emine Atağ¹, Yasemin Gökdemir¹, Ela Erdem Eralp¹, Bülent Taner Karadağ¹

¹Department of Pediatric Pulmonology, Marmara University School of Medicine, İstanbul, Turkey

²Department of Pediatrics, Marmara University School of Medicine, İstanbul, Turkey

Objectives: Primer ciliary dyskinesia (PSD) is a disease that adversely affects quality of life due to recurrent upper and lower respiratory infections. So we aimed to evaluate the factors affecting quality of life and quality of life in our patients with PSD.

Methods: Quality of life questionnaires (QOL-PCD) were administered to 30 PSD patients with primary ciliary dyskinesia adhering to our clinic. Patients with PSD diagnosed by electron microscopy were included in the study, and also patients with clinical and physical examination findings as well as patients with nasal NO abortion. Four different questionnaires were applied to the patient's, age group (6-12 year old child + parents, 13-17 year old adolescent, ≥ 18 year old adult). The questionnaire score was calculated via e-mail from the surveying team. The questionnaires included questions about physical functioning, emotional functioning, treatment burden, ears and hearing, respiratory symptoms, social functioning, role functioning, vitality, health perception, eating and weight.

Results: The mean age of the patients was 13.4 ± 3.7 years, 21 (70) % of the girls. The age distribution of the patients ranged from 7 to 20 years. The median age at diagnosis was 1.5 years. Median symptom onset age was 1 month and mean symptom duration was 11.5 ± 4.1 years. In 19 patients situs inversus totalis and dextrocardia were present. There was congenital heart disease accompanying a patient. Twenty-five patients had kinship between their parents. Adolescents treatment burden and parents' physical functioning were found to be the most affected parameters. There was no statistical difference among groups in terms of treatment burden and physical functioning (p values 0.791 and 0.068; respectively).

Conclusion: Treatment non convenience and severe treatment burden is usually seen in adolescent patients with PCD. Therefore, frequent physical examination and questioning for treatment convenience should be performed in this group of patients. Even though there was no statistical difference among groups in terms of treatment burden in our study, this was interpreted as a result of low number of patients. Our study is still in progress.

Keywords: Questionnaire, PCD, symptoms

Table 1. The sub-groups of quality of life scale in different age groups

parameter (n)	age 6-12 (11)	age 13-18 adolescent (12)	age over 18 adults (7)	parents of 6-12 years old patients (11)
evaluation of physical functions	53 (33/100)	69.5 (13/80)	77 (46/93)	46 (33/86)
evaluation of emotions	66 (50/83)	70.5 (33/100)	73 (53/93)	66 (44/100)
evaluation of treatment	60 (40/86)	49.5 (11/100)	58 (16/75)	50 (33/75)
evaluation of ears and hearing	66 (41/100)	87 (50/100)	83 (78/100)	88 (33/100)
evaluation of upper airway symptoms	66 (40/93)	60 (26/100)	61 (25/77)	66 (41/91)
evaluation of lower airway symptoms	61 (38/83)	66 (28/85)	53 (38/77)	66 (16/100)
evaluation of social functions	66 (26/100)	70.5 (33/91)	66 (33/83)	66 (22/88)
evaluation of social role		77 (33/100)	66 (50/77)	
evaluation of vitality		66 (33/100)	75 (44/83)	
evaluation of health perception			66 (41/83)	58 (41/93)
evaluation of nutritional status				77 (22/100)

[Abstract:0779] PS-124 [Accepted:Poster Presentation] [Clinical Problems - Pulmonary Vascular Diseases]

The Evaluation of Medication Adherence in Patients with Pulmonary Thromboembolism

Serap Argun Barış, Tuba Çiftçi, Serhat Özgün, Haşim Boyacı, İlknur Başyığıt

Department of Pulmonary Diseases, Kocaeli University School of Medicine, Kocaeli, Turkey

Objectives: Pulmonary thromboembolism (PTE) is a disease with high mortality and morbidity, and a risk of recurrence during clinical course. The aim of the study is to evaluate treatment adherence in PTE patients.

Methods: Seventy three of 102 patients diagnosed with pulmonary thromboembolism at the Kocaeli University Faculty of Medicine Pulmonary Diseases and who had been receiving treatment for the last 3 months were reached by phone. Morisky treatment adherence questionnaire, which included 8 questions, was recorded.

Results: A total of 73 patients (mean age 63.3 ± 13.3 years) were enrolled, 44 (60.3%) were female and 29 (39.7%) were male. Age distribution was similar between genders ($p=0.8$). PTE was symptomatic in 56 patients (76.7%) and incidental in 17 patients (23.3%). Fifty-one (69%) of the patients had comorbidities. The most frequent comorbidities were hypertension (28.8%) and malignancy (27.4%). Forty-nine (53.4%) of the patients were using LMWH, 30 of them (41.1%) were receiv-

ing rivaroxaban and 4 of them (5.5%) were using warfarin. According to the Morisky treatment adherence questionnaire, 60 patients (82.2%) had high, 8 patients (11%) had intermediate and 5 patients (6.8%) had low adherence. There was no significant difference between genders in terms of presence of comorbidities, having symptomatic or incidental embolism, medication used and treatment adherence. Thirty-eight of the cases (52.1%) were over 65 years old and comorbidities were significantly higher in these patients (84.2 vs 54.3%, $p=0.005$). There was a significant difference between patients over and under 65 years old in terms of medication used ($p=0.009$). The most of the patients over 65 years old were using rivaroxaban (55.3%) while there was no patient using warfarin. The mean Morisky questionnaire scores were similar by gender and age limit ($p=0.3$, $p=0.3$). There was no significant difference in treatment compliance according to education level ($p=0.3$). However, the mean Morisky questionnaire score in symptomatic PTE patients was significantly higher than in incidental PTE cases (7.7 ± 1.1 vs 6.9 ± 1.5 , $p=0.03$). Significant differences were also found in symptomatic PTE cases at 2. and 5. questions of Morisky questionnaire ($p=0.04$, $p=0.01$).

Conclusion: Treatment adherence was found to be lower in patients with incidental pulmonary thromboembolism and it is thought that treatment compliance should be closely monitored especially in this patient group.

Keywords: Adherence, morisky questionnaire, pulmonary thromboembolism, medication

[Abstract:0780] SS-085 [Accepted:Oral Presentation] [Pediatric Pulmonary Diseases]

Data of Cystic Fibrosis Patients in Turkey in the Last Year: First Data from the National Cystic Fibrosis Registry System

Deniz Doğru Ersöz¹, Erkan Çakır², Tuğba Şişmanlar Eyüboğlu³, Nazan Çobanoğlu⁴, Sevgi Pekcan⁵, Güzin Cinel⁶, Velat Şen⁷, Hadice Selimoğlu Şen⁸, Özlem Kesin⁹, Sevgi Bilgiç Eltan⁹, Ebru Yalçın¹, Nural Kiper¹, Derya Ufuk Altıntaş¹⁰, Şenay Şaşıhüseyinoğlu¹⁰, Lina Muhammed Al Shadfani², Hakan Yazan², Ömür Ercan⁵, Nihat Sapan¹¹, Şükrü Çekiç¹¹, Haluk Çokuğraş¹², Ayşe Ayzıt Atabek¹², Tuğba Ramaslı Gürsoy¹³, Ayşe Tana Aslan¹³, Ayşen Bingöl¹⁴, Abdurrahman Erdem Başaran¹⁴, Ali Özdemir¹⁵, Mehmet Köse¹⁶, Melih Hangül¹⁶, Gökçen Tuğcu¹, Nagehan Emiralioglu¹⁷, Fazıl Orhan¹⁸, Zeynep Gökçe Gayretli Aydın¹⁹, Erdem Topal²⁰, Demet Can²¹, Cem Murat Bal²², Zeynep Tamay²³, Ayşe Süleyman²³, Uğur Özçelik¹

¹Department of Pediatric Pulmonology, Hacettepe University School of Medicine, Ankara, Turkey

²Department of Pediatric Pulmonology, Bezmialem University School of Medicine, İstanbul, Turkey

³Department of Pediatric Pulmonology, Dr Sami Ulus Maternity and Children Training and Research Hospital, Ankara, Turkey

⁴Department of Pediatric Pulmonology, Ankara University School of Medicine, Ankara, Turkey

⁵Department of Pediatric Pulmonology, Necmettin Erbakan University Meram School of Medicine, Konya, Turkey

⁶Department of Pediatric Pulmonology, Ankara Children's Hematoloji Oncology Training and Research Hospital, Ankara, Turkey

⁷Department of Pediatric Pulmonology, Dicle University School of Medicine, Diyarbakır, Turkey

⁸Department of Pulmonology, Dicle University School of Medicine, Diyarbakır, Turkey

⁹Department of Pediatric Allergy, Gaziantep University School of Medicine, Gaziantep, Turkey

¹⁰Department of Pediatric Allergy and Immunology, Çukurova University School of Medicine, Adana, Turkey

¹¹Department of Pediatric Allergy and Immunology, Uludağ University School of Medicine, Bursa, Turkey

¹²Department of Pediatric Allergy and Pulmonology, İstanbul University Cerrahpaşa School of Medicine, İstanbul, Turkey

¹³Department of Pediatric Pulmonology, Gazi University School of Medicine, Ankara, Turkey

¹⁴Department of Pediatric Allergy and Immunology, Akdeniz University School of Medicine, Antalya, Turkey

¹⁵Department of Pediatric Pulmonology, Mersin Maternity and Children Hospital, Mersin, Turkey

¹⁶Department of Pediatric Pulmonology, Erciyes University School of Medicine, Kayseri, Turkey

¹⁷Department of Pediatric Pulmonology, Gaziantep Cengiz Gökçek Maternity and Children Hospital, Gaziantep, Turkey

¹⁸Department of Pediatric Allergy, Karadeniz Technical University School of Medicine, Trabzon, Turkey

¹⁹Department of Pediatric Infectious Disease, Karadeniz Technical University School of Medicine, Trabzon, Turkey

²⁰Department of Pediatric Allergy, İnönü University School of Medicine, Malatya, Turkey

²¹Department of Pediatric Pulmonology, Balıkesir University School of Medicine, Balıkesir, Turkey

²²Department of Pediatric Pulmonology, Atatürk Regional Training and Research Hospital, Erzurum, Turkey

²³Department of Pediatric Allergy, İstanbul University School of Medicine, İstanbul, Turkey

Objectives: Registries are the systems that periodically collect data about clinical and epidemiological characteristics, care and life span to record, compare, and monitor time-varying epidemiology in a center, country or region of a particular group of patients. The National Cystic Fibrosis Registry System (NCFRS) was established for this purpose and aims to know the number, clinical and demographic characteristics of the patients with cystic fibrosis (CF) in our country. In this study, we aimed to present the data of CF patients in 2107 who were recorded to NCFRS.

Methods: User name and password were given to the CF centers and data entry was completed for the NCFRS, which is an electronic patient registration system that operates on the internet. Demographic data (age, age, gender, mutations, pancreatic insufficiency) of the patients were recorded. The results of FEV1%, sputum culture, complications, treatments, transplantation needs and death causes of dead patients were entered into the system and frequency analysis was performed.

Results: A total of 21 centers recorded 940 patients. 433 (46%) of the patients were female. Median age at diagnosis was 5.9 years for girls and 4.4 years for boys. 186 (19%) patients were diagnosed with neonatal screening and 48 patients had meconium ileus. 43 patients were over 18 years old. 306 patients were able to perform PFTs, FEV1 values were found to be $\leq 40\%$ in 105 patients, 41-59% in 26, 60-79% in 46, and $>80\%$ in 129. The most frequent mutation was deltaF508 in 224 (20%) allele and it was followed by N1303K, G542X, 1677delTA, G85E, 2183AA->G mutations. Chronic *S.aureus* was found in 136 (14%), chronic *Pseudomonas aeruginosa* was found in 60 (6%) and chronic *Burkholderia cepacia* complex was found in 7 patients. The most common complication was pseudo-bartter syndrome (30%), followed by sinusitis, chronic liver disease and gastroesophageal reflux. Of the patients, 698 (74%) were using rhdnase, 105 inhaled antibiotics, 53 hypertonic saline, 38 inhale mannitol and 22 noninvasive mechanical ventilation. There were 774 (82%) patients using pancreatic enzyme. 449 (47%) patients were receiving enteral nutrition, and 4 patients had gastrostomy. 6 patients were decided to suitable for transplantation and 10 patients died.

Conclusion: The NCFRS includes valuable information about demographic data and final status of our CF patients, identification of patients who will benefit from the new course of treatment and data collection for scientific studies. Therefore, increasing patient data would be useful for CF patients in our country.

Keywords: Cystic fibrosis, registry, national

[Abstract:0781] PS-088 [Accepted:Poster Presentation] [Pulmonary Rehabilitation and Chronic Care]

Comparison of Anaerobic Exercise Capacity, Pulmonary Functions, Respiratory Muscle Strength and Endurance and Peripheral Muscle Strength in Children with Primary Ciliary Dyskinesia with and without Prenatal Cigarette Exposure

Merve Firat¹, Meral Boşnak Güçlü², Tuğba Şişmanlar Eyüboğlu³, Ayşe Tana Aslan⁴

¹Ahi Evran University, School of Physical Therapy and Rehabilitation, Kırşehir, Turkey

²Department of Physiotherapy and Rehabilitation, Gazi University School of Health Sciences, Ankara, Turkey

³Department of Pediatric Pulmonology, Dr. Sami Ulus Maternity and Children Research and Training Hospital, Ankara, Turkey

⁴Department of Pediatric Pulmonology, Gazi University School of Medicine, Ankara, Turkey

Objectives: Primary ciliary dyskinesia (PCD) is an autosomal recessive disorder that is the result of the structure and dysfunction of moving cilia. 38% of patients with PCD have DNAH5 or DNAI1 mutation. Smoking exposure affects the DNAI1 gene. Exposure to prenatal cigarettes causes long-lasting/permanent structural changes on developing lungs and reduced pulmonary function. In chronic lung diseases, deterioration of pulmonary function causes decrease of peripheral muscle strength and exercise capacity. In literature, no study comparing of anaerobic exercise capacity, pulmonary functions, respiratory muscle strength and endurance and peripheral muscle strength in children with PCD with and without prenatal cigarette exposure. In this study, we aimed to compare anaerobic exercise capacity, pulmonary functions, respiratory muscle strength and endurance and peripheral muscle strength in children with PCD with and without prenatal cigarette exposure.

Methods: Totally 27 children with PCD; 10 (11.10 \pm 4.43 years, 7F, 3M) with prenatal cigarette exposure and 17 (10.53 \pm 3.86 years, 9F, 8M) without were included. Anaerobic exercise capacity using three-minute step test (3-MST), before and after the test vital findings, dyspnea and fatigue using Modified Borg scale (MBS), pulmonary functions using spirometer, respiratory muscle strength (MIP and MEP) using mouth pressure measuring device, respiratory muscle endurance using incremental threshold loading test, breathing depth using tape measure and peripheral muscle strength using portable digital dynamometer were evaluated.

Results: MIP (p=0.021), Δ axillary (p=0.013), Δ epigastric (p=0.005), shoulder abductor (right) (p=0.031), shoulder abductor (left) (p=0.043), elbow flexor strength (right) (p=0.031) was significantly, respiratory muscle endurance (%) (p=0.060) close to significance lower in children with PCD with prenatal cigarette exposure compared children without exposure. 3-MST total

number of steps, Δ vital findings, Δ dispnea, Δ fatigue, pulmonary functions, MEP, Δ subcostal, knee extension and hand grip strength were similar in groups ($p>0.05$).

Conclusion: Respiratory muscle strength and endurance, shoulder abductor and elbow fleksor muscle strength, chest expansion are more impaired in children with PCD with prenatal cigarette exposure. Anaerobic exercise capacity, pulmonary functions, hand grip and lower extremity strength are similarly affected in children with PCD with and without prenatal cigarette exposure. In both groups, it is expected that deterioration of pulmonary function with age and consequently decrease in exercise capacity. For this reason, children with PCD should be included in appropriate pulmonary rehabilitation programs.

Keywords: Exercise capacity, prenatal cigarette exposure, primary ciliary dyskinesia

[Abstract:0783] EPS-057 [Accepted: E-Poster] [COPD]

Clinical Characteristics of Patients with Bronchiectasis Disease and COPD

Sevda İbrahim Mustafayeva, Gülzar Rafiq Aliyeva

Department of Pulmonology, Research Institute of Lung Diseases, Baku, Azerbaijan

Objectives: There is an increasing interest to understand the interaction between existing comorbidities. The presence of comorbid conditions make the management of diseases difficult. The aim of the research is to study the peculiarities of clinical course of the diseases in patients with coexisting bronchiectasis and COPD.

Methods: There are 33 patients (age 38-62 years old; 27 men, 5 women) with bronchiectasis and COPD were investigated. All patients underwent a comprehensive examination including laboratory blood tests, microbiological sputum analysis, X-ray and CT scan of chest organs, spirometry, ECG, Echocardiography.

Results: Anamnesis collection revealed that during the childhood the 13 patients had the infectious diseases, 11 patients had pneumonia and 15 patients had chronic inflammatory diseases of the upper respiratory tract. There were a long-term smoking in 26 out of cases and passive smoking in 3 out of cases. In 8 of cases, the fact of prolonged work in harmful production was revealed. The clinical picture of the disease was characterized by a severe course in 18 patients and there was a moderate course of the diseases in 12 patients. Frequent infectious exacerbations -more than 5 times a year - were observed in 14 of cases, and the symptoms of severe dyspnea, difficult to separate purulent sputum on the background of severe bronchial obstructive syndrome were permanent in 17 of cases. Radiological examinations revealed signs of emphysema in 24 patients, pneumosclerosis in 16 patients. All patients have bronchiectasis and the kind of bronchoectatic changes in the lungs were predominantly mixed. One-sided nature of the lesion was found in 11 of cases, in other cases, bronchoectatic changes were bilateral, multiple and grouped in several segments of the lungs. Spirometry shows significant decreasing of functional parameters, all patients have FEV1<40% of predicted volumes. P-pulmonale in ECG and increased SPAP (35mmHg) in Echocardiography was determined in 28 and 21 patients respectively.

Conclusion: The study of the clinical course of the disease and the analysis of the results of a comprehensive examination of patients with coexisting bronchoectatic disease and COPD will allow to choose a more rational and effective approach to the treatment, as well as the prevention of exacerbations and complications of the diseases.

Keywords: Bronchiectasis, COPD, comorbidity

[Abstract:0784] PS-126 [Accepted:Poster Presentation] [Clinical Problems - Pulmonary Vascular Diseases]

Complications Chain after Paliperidone; Atypical Neuroleptic Malignant Syndrome Followed by Venous Thromboembolism

¹Department of Chest Diseases, Kırıkkale University School of Medicine, Kırıkkale, Turkey

²Department of Psychiatry, Kırıkkale University School of Medicine, Kırıkkale, Turkey

There is a known increased risk of venous thromboembolism (VTE) in elderly patients treated with conventional antipsychotic drugs. Paliperidone is a new atypical antipsychotic with less extrapyramidal symptoms, and acute effect for schizo-affective disorder (SAD). We report a rare case with SAD, who developed VTE following atypical neuroleptic malignant syndrome (NMS) after a single injection of intramuscular paliperidone.

A 33-year-old male patient with multiple sclerosis, had been under treatment with immunosuppressive agent (fingolimod 0.5 mg/day) for 16 years. He had been hospitalized because of persecution ideas, increased talking, pressure of speech, elevated mood, increased self-esteem and grandiosity and indicated antipsychotic (quetiapine 400mg/day) for early-onset SAD. However, he was given paliperidone 150 mg/wk. as a shot into muscle, since he was in compliant with oral therapy and agitated. Afterwards, he had weakness, trouble speaking, feeling sleepy that were expected side effects, but also got inefficient oral nutrition, and mobilisation. On the 6th day of injection, he had atypical NMS occurred with hyperthermia, mild muscle rigidity, altered mental status, dyskinesia, elevated creatine kinase (1194 U/L), but no autonomic instability or progression to fulminance. He was admitted to intensive care unit for close monitoring, and treatment of supportive therapy. Physical examination revealed hypotension (90/60 mmHg), tachycardia (110/min), tachypnea (25/min), oxygen desaturation (85%), wheezing and rhonchi, muscle weakness of lower extremity (right 3+/5, left 2+/5). He had elevated leucocytes (14.000/uL), serum c-reactive protein (117mg/dL) and sedimentation (93/hr). Serum d-dimer was 35µg/mL (upper limit 0.5µg/mL). P-A chest x ray showed infiltration on the left lower zone. Thorax computed tomography (CT) angiography was reported as VTE in the lingula and left lower lobe pulmonary arteries, left pleural effusion-12mm-, and consolidation on the lower right lobe parenchyma. Low extremity colour doppler ultrasonography showed VTE in the right femoral/popliteal venous. Treatments were started for VTE as anti-coagulation with low molecular-weight-heparin (LMWH), for hospital acquired pneumonia as antibiotics with moxifloxacin, meropenem, and bronchodilators, for NMS as bromocriptine (12.5mg/day). VTE risk factors were negative including genetic thrombophilia screening tests. His symptoms and abnormal physical findings improved after 15 days of hospitalization. Treatment with antipsychotics discontinued. However, interestingly, symptoms of mood episode were improved. VTE in pulmonary, and low extremity were completely resolved after 6 months of oral anti-coagulation therapy. He began to have physical rehabilitation for his walking disability.

VTE and NMS risk factors in this patient were suggested as paliperidone's adverse events. Even though atypical NMS is not a potentially fatal symptom complex, its complication VTE may be a concomitant serious medical problem. This case indicates that patients with NMS treated with antipsychotic drugs may be at an increased risk of VTE which requires assessment, and thrombo-prophylaxis.

Keywords: Antipsychotic, neuroleptic malignant syndrome, pneumonia, thromboembolism

[Abstract:0788] EPS-114 [Accepted: E-Poster] [Lung and Pleura Malignancies]

A Case with Multiple N2 Disease in Whom Complete Remission Was Observed After Undergoing Chemoradiotherapy and Surgery Following It

Sercan Dadaş, Akın Öztürk, Murat Kavas, Cansel Atinkaya, İrfan Yalçınkaya

HSU Süreyyapaşa Chest Diseases and Chest Surgery Education and Research Hospital, İstanbul, Turkey

Introduction: Lung cancer is the most common reason of mortality from cancer. Non-small cell lung cancer (NSCLC) constitutes 80-85% of all lung cancers. Almost one third of NSCLC cases are diagnosed at locally advanced stage (Stage 3). Stage 3 includes heterogeneous patient group. Therefore it is the group having the most controversial treatment and still there is not any standard approach in definitive treatment. Neoadjuvant chemoradiotherapy (CT-RT) increases success rate of surgery. The case presented here is clinical N2 and she is a case in whom almost complete response was obtained after CT-RT.

Case Presentation: A 60-year-old female patient had diagnoses of COPD, hypertension and hashimoto's thyroiditis. She presented with the complaints of cough, chest pain and shortness of breath. She had a history of 40 packs/year and was ex-smoker for ten years. She had bilateral rhonchus in her respiratory system examination and her other systemic examinations were normal. Her laboratory findings were within normal range. A non homogeneous well-circumscribed

density in the left upper zone was observed in the chest radiography. A nodular lesion with the size of 30x22 mm was detected in the upper left lobe posterior segment in the simultaneously performed thoracic computed tomography (CT). No mass was detected in cranium with diffusion magnetic resonance imaging (MRI). In PET-CT, a 29 mm hypodense mass lesion in left lung upper lobe apicoposterior segment at subpleural distance (SUDmax:23,0), 14 mm lesion in the left suprahilal region with the neighborhood of left pulmonary artery (SUDmax:20,8), and a hypodense nodular lesion in the left upper prevascular region (SUDmax:19,5) were reported. An involvement was observed in the region (SUDmax:4,5) that is in the sacroiliac joint neighborhood in the left hemipelvic bones. No lesion was detected in the examination of pelvis MRI. Flexible bronchoscopy was performed for the purpose of histopathologic verification, it was observed that endobronchial system was normal. Epithelial cells and alveolar macrophages were observed in bronchial lavage cytology. CT- guided Tru-cut biopsy was conducted. The result of pathology was reported as non-small cell lung carcinoma. 4L and 7 lymph node stations were sampled in the mediastinoscopy. The result of pathology was reported as reactive hyperplasia and anthracosis. The patient was evaluated in the council. The decision of simultaneous CT-RT was made. Partial remission was observed in the control tomography performed after 31 sessions radiotherapy and 6 sessions of chemotherapy. The decision of surgery was made in the assessment after neoadjuvant therapy. Left upper lobectomy was performed. These cells may be the ones displaying reactive atypia belonging to normal alveolar structures which were squeezed in fibrosis after neoadjuvant chemoradiotherapy. It was reported that there was benign reactive hyperplasia in the removed lymph nodules numbered 6, 7, 8, 10; benign reactive hyperplasia in lymph nodule numbered 5, and atypical view in one or two cells. It was also reported that in the forefront these findings made us consider necrotising carcinoma metastasis.

Conclusion: Surgery was performed in our case, having locally advanced disease, whom we followed with multiple N2 involvement after provision of partial remission macroscopically with neoadjuvant chemoradiotherapy. No tumoral tissue was detected in both primary tumoral tissue pieces and in the pieces belonging to lymph node stations in which preoperative malignant involvement was observed. In our case presentation we aimed to share a case with multiple N2 disease in whom complete response was obtained in the surgery performed following neoadjuvant chemoradiotherapy.

Keywords: Lung cancer, neoadjuvant chemoradiotherapy, remission

[Abstract:0789] EPS-146 [Accepted: E-Poster] [Respiratory Failure and Intensive Care]

ARDS Case due to Severe Influenza A Infection

Emine Güzey¹, Murat Bıçakçioğlu², Mehmet Burak Öztürk¹, Murat Yalçınsoy¹, Zeynep Ayfer Aytemur¹

¹Department of Chest Diseases, İnönü University School of Medicine, Malatya, Turkey

²Department of Anesthesiology and Reanimation, İnönü University School of Medicine, Malatya, Turkey

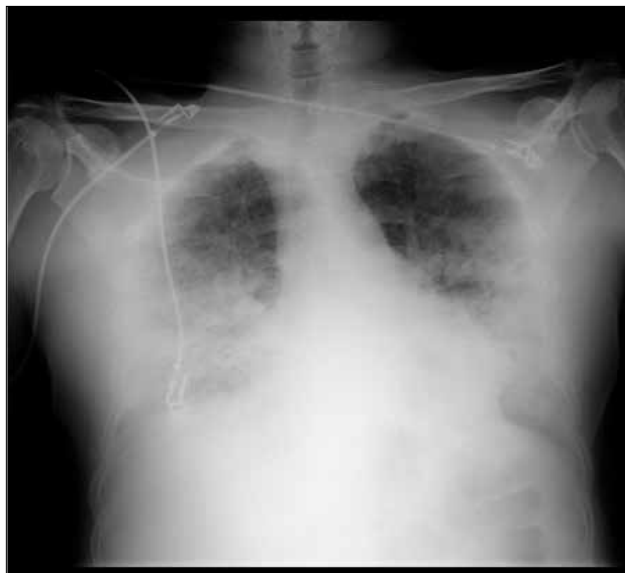

Figure 1. Chest X-ray at Admission

Some cases of influenza pandemic patients require treatment in intensive care unit, and cases with ARDS table have been observed. These serious reports have been reported frequently in patients with comorbidities. We aimed to present an influenza patient who referred to our emergency department, The patient has no known illness. A 60 years old male patient referred to our center with respiratory distress, weakness and cough. Complaints of cough, fever, nasal discharge started 1 week. The patient has no known illness, 10 packet/year smoking history. He has not been smoking for 15 years. The patient had tachypnea, dyspnea and hypoxemic respiratory failure. Patient's chest X-ray showed extensive infiltrates bilaterally in middle and lower zones (Figure 1). Computerized thorax tomography showed consolidations involving bilateral air bronchograms (Figure 2). The PaO₂ / FiO₂ in the application was 175. The patient received non-invasive mechanical ventilator support, oseltamavir, broad-spectrum antibiotherapy and prednisolone 1 mg/kg/day. Influenza A (H1N1) positive was detected in the respiratory viral panel. There was no reproduction in

other cultures. Clinically significant response was obtained on the 5th day of treatment. The patient's mechanical ventilation requirement is over. Antibiotherapy was completed in 1 week. Prednol therapy was planned to be cut off and discharged (Figure 3). The patient who is still following us has not complained for 2 months. As a result, it is necessary to consider viral factors in consideration of seasonal conditions among the causes of pneumonia causing ARDS.

Non invasive mechanical ventilator should be attempted in cases where the ARDS is given in close agreement at an early stage and mildly, but in order to avoid complications that may pose a life-threatening risk due to the invasive mechanical ventilation, compatible and treatment should be attempted in cases that can respond quickly.

Keywords: ARDS, influenza, NIMV

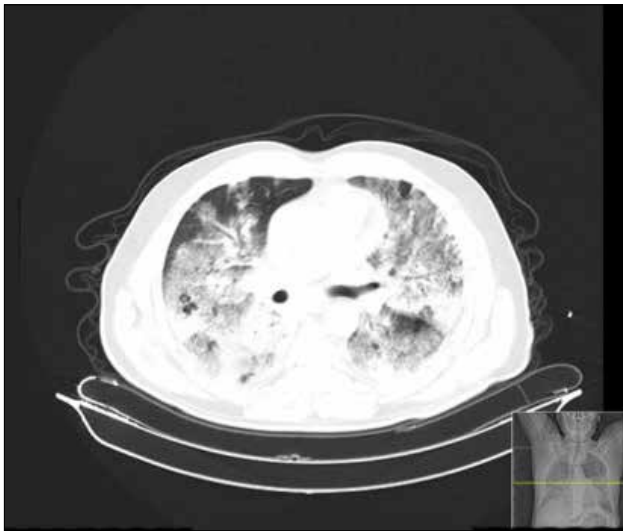


Figure 2. CT at Admission

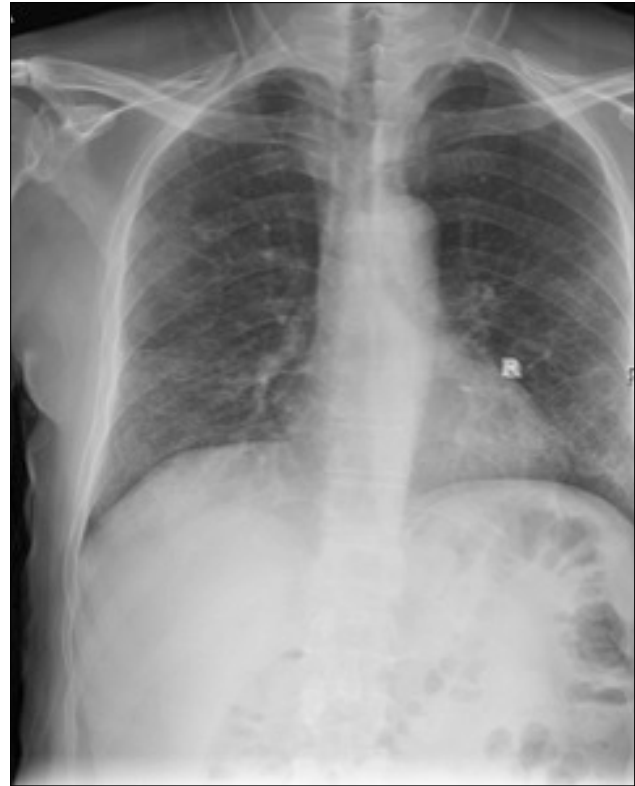

Figure 3. After Treatment X-ray

[Abstract:0796] PS-005 [Accepted:Poster Presentation] [Clinical Problems - Diffuse Parenchymal Lung Disease]

Comorbid Conditions in IPF Patients; Their Frequencies and Impacts on Survival

Aysu Sinem Koç, Burcu Uysaler, Nesrin Moğulkoç

Department of Chest Diseases, Ege University School of Medicine, İzmir, Turkey

Objectives: The majority of patients with IPF have comorbidities, which affect functional status, quality of life, treatment and survival. Our study aim was to analyse comorbidities in our series of 379 IPF patients.

Methods: We retrospectively examined the range of comorbidities documented in our cohort of patients with IPF. These patients were seen in our interstitial lung disease clinic between May 2008 and January 2018. All had a diagnosis of IPF based on clinical assessment and high resolution CT scan; one third underwent a surgical lung biopsy.

Results: Median age at diagnosis was 65.6 years. 74% of patients are male (n=281). Systemic hypertension, latent TB and diabetes mellitus were the most frequent comorbidities (Table). However, the comorbidities with the greatest impact on survival were the development of lung cancer, respiratory failure and pulmonary hypertension (PH).

Conclusion: Some comorbidities have a major adverse impact on survival. IPF management requires a comprehensive approach, which includes the identification and treatment of comorbid conditions. The protective effect of obesity we have examined elsewhere. The apparent protective effect of latent TB needs to be further explored.

Keywords: Comorbidity, idiopathic pulmonary fibrosis, survival

Table 1. Frequencies of comorbidities, significance and hazard ratios

Condition	Frequency	Significance	Hazard ratio
Pulmonary hypertension	68 (17.6%)	0.000	2.116
Emphysema	38 (10%)	0.179	1.478
Respiratory failure	70 (18.5%)	0.000	2.889
Lung carcinoma	22 (5.6%)	0.001	3.461
Systemic hypertension	141 (53.4%)	0.534	0.890
Coronary artery disease	72 (19%)	0.764	1.073
Gastro-oesophageal reflux disease	65 (17.2%)	0.216	0.728
Obesity	59 (15.6%)	0.053	0.585
Diabetes mellitus	83 (21.9%)	0.843	1.044
Thyroid dysfunction	24 (6%)	0.176	0.538
Depression	22 (5.8%)	0.683	0.870
Latent TB	92 (24%)	0.002	0.420

[Abstract:0799] SS-005 [Accepted:Oral Presentation] [Asthma and Allergy]

Investigation and Validation of MicroRNAs and Target Genes That are Effective in The Pathogenesis of Allergic Asthma

Ender Coşkunpınar¹, Engin Aynacı², Aysun Aynacı³, Sevgi Kalkanlı Taş¹, Burcu Hastürk¹, Şeyma İş¹, Betül Çiçek Akçeşme¹

¹Department of Medical Biology, Health Sciences University School of Medicine, İstanbul, Turkey

²Department of Chest Diseases, İstanbul Medipol University School of Medicine, İstanbul, Turkey

³Division of Chest Diseases, Health Sciences University, Kanuni Sultan Süleyman Education and Research Hospital, İstanbul, Turkey

Objectives: Allergic asthma is a complex disease characterized by chronic airway inflammation as a result of encounters with various agents and includes epigenetic changes due to the interaction of genetic and environmental factors. As a result of inflammation, an immune response is created using cytokines, chemokines, and other mediators. In recent years, however, the number of studies on exosomes of extracellular vesicles playing a role in intercellular communication has increased. Recent studies indicate that miRNAs can be used as potential non-invasive markers for diagnosis, new generation diagnosis and treatment of obstructive airway diseases. Various scientific studies investigate miRNAs and target genes that are likely to play a role in the pathogenesis of allergies and asthma. However, the number of studies that identify the genes affected and targeted by miRNAs is very small. With this research, we aim to determine both the molecular pathways of the miRNA candidates of allergic asthma, which has become a serious public health problem, and the genes affected by these miRNAs, to validate these and to introduce new biomarkers into the literature.

Methods: Our research is a case-control study in which 40 patients diagnosed with allergic asthma and 40 healthy volunteers are included. Total RNA and microRNA isolation was performed from the peripheral blood of the participants. miRNA gene expression profiles were identified by Custom array plates used in PCR Array (Qiagen-SABioscience PCR Array) method. Target genes in the genome were determined by bioinformatics analysis. mRNA expression levels of target genes were identified by the Real-Time PCR method with determined threshold values and were analyzed in terms of expression difference by relative quantification method.

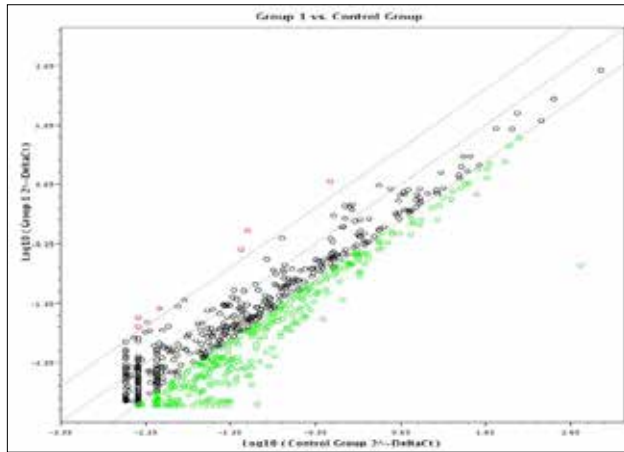


Figure 1. Scatter Plots for Control and Patients Groups

Results: Our study in which microRNA profiling performed by PCR array method revealed that 7 miRNA are upregulated. Genes influenced by these miRNAs were determined after performing bioinformatic analysis.

Conclusion: In this study, deregulated miRNAs are determined by miRNA profiling. Also, complementary genes to these miRNAs are determined by bioinformatic analysis. This is a validation study in which mRNA expression profiles of all these genes are investigated in patients with allergic asthma. Preliminary results will be shared after completion of the experiments.

Keywords: Allergic asthma, extracellular microRNA, miRNA, mRNA, gene expression, biomarker

[Abstract:0800] EPS-296 [Accepted: E-Poster] [Tuberculosis]

Pulmonary Tuberculosis in The Case Followed with Lung Cancer

Aysen Evkan¹, Berna Eren Kömürçüoğlu¹, Zeynep Öndeş¹, Zekiye Aydoğdu²

¹Department of Chest Diseases, HSU Dr Suat Seren Chest Diseases and Chest Surgery ERH, İzmir, Turkey

²Department of Chest Pathology, HSU Dr Suat Seren Chest Diseases and Chest Surgery ERH, İzmir, Turkey

A 47-year-old male patient was examined on the complaints of cough, weight loss and hemoptysis. In his physical examination respiratory sound was evaluated to decrease in the right side. His infection related values were increased in laboratory analyses. Chest radiography was evaluated as “opaque right lung”. There was no chronic disease and smoking in his medical history. In his thoracic computed tomography (CT) loculated fluid and subtotal atelectasis were observed in the right hemithorax. Diagnostic thoracentesis was performed in the patient. His pathology was reported as adenocarcinoma metastasis. The patient in whom bone metastasis was detected in his screenings was evaluated as stage 4 lung cancer. Systemic pemetrexed–cisplatin chemotherapy was initiated in the patient who was ECOG 0. He was consulted with medical oncology on detection of almost complete regression in his control after 6 months. pemetrexed maintenance therapy was decided. The treatment was completed in 1 year. Genetic mutation analyses by making cell-block were requested from the patient in whom pleural-based mass, pleural fluid, acid formation in the abdomen and relapse were detected in the 14th month of his treatment. Exon 19 mutation was detected.

1*150 mg erlotinib goal-directed therapy was initiated for the patient. Under treatment, his symptoms and acid in the abdomen were rapidly lost. Bilateral nodular lesions were present in the 3rd month CT of the patient who had no active complaint.

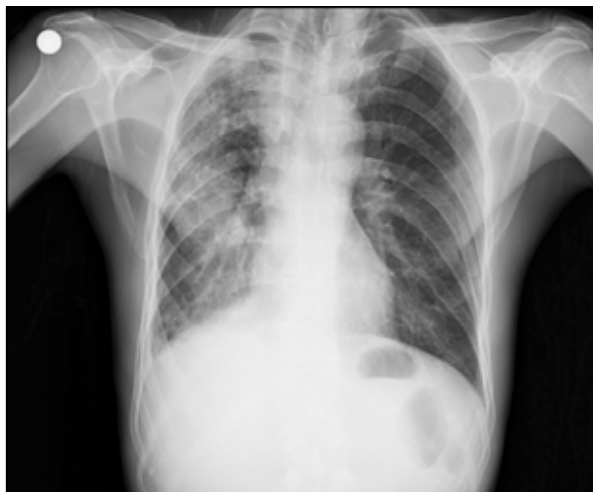

Figure 1.

In PET-CT, these lesions were evaluated as slightly increased FDG involvement from the neighboring tissue in infiltrations (SUVmax2.1). Sputum analysis was requested with the pre-diagnosis of tuberculosis. Bronchoscopy was conducted for the patient who could not provide sputum analysis. Endobronchial lesion was not observed. PCR examination of bronchial aspiration was reported as *M. tuberculosis*. Quadruple anti-tuberculosis therapy was initiated for the patient. More than half of the lung cancer cases are diagnosed at the locally advanced or advanced stages due to the fact that it does not have a specific symptom and screening method. Survival time is limited with 8-9 months with standard systemic chemotherapies in the advanced stage. Longer survival times are seen with goal-directed therapies. However, risk of secondary infections such as tuberculosis increases due to immunosuppression caused by the cancer. Incidence of lung cancer in pulmonary tuberculosis changes between 1.9 and 4%. Lung cancer and pulmonary tuberculosis may mask each other since they have similar radiological and

clinical findings. Treatment of both diseases is prolonged and their side effects and morbidities are high. Goal directed therapies such as erlotinib can cause impairments in respiratory function tests. Our case is presented since the two diseases coexist rarely and there are treatment limitations.

Keywords: Lung Cancer, pulmonary tuberculosis, erlotinib

[Abstract:0802] PS-311 [Accepted:Poster Presentation] [Respiratory Infections]

Factors Influencing Vaccine Uptake in Risk Population

Özge Aydın Güçlü¹, Nilüfer Aylin Acet Öztürk², Aslı Görek Dilektaşlı³, Ezgi Demirdöğen Çetinoğlu³, Esra Uzaslan³

¹Department of Chest Disease, Gürsu Cüneyt Yıldız State Hospital, Bursa, Turkey

²Department of Chest Disease, Gemlik State Hospital, Bursa, Turkey

³Department of Chest Disease, Uludağ University School of Medicine, Bursa, Turkey

Objectives: Vaccines have proved their ability to prevent illness, disability and death from vaccine-preventable diseases. Although vaccination is recommended for people at increased risk, sales data indicate that vaccination rate remains low in Turkey. We aim to evaluate vaccination status and factors influencing vaccine uptake in Bursa.

Methods: We included volunteers participating in events for World COPD day in 2017 in Bursa, Turkey. Sociodemographic features, smoking characteristics, comorbidities, influenza and pneumococcal vaccination status, the use of antibiotics in the last 1 year were recorded.

Results: We analyzed data from 248 volunteers with 47.7±16 years of age. Study population consisted of 130 (52.8%) males and 80 (32.5%) ever smokers. Most common comorbid diseases were asthma (16.1%), hypertension (9.3%), diabetes mellitus (6.5%), coronary artery disease (3.2%), COPD (2%) and lung cancer (1.2%). Hospital admissions, emergency admissions and labor loss in the last three months among participants were 4.4%, 4%, and 6.3 respectively. 14.8% of the subjects were vaccinated with influenza vaccine and 5.4% of the cases were vaccinated with pneumococcal vaccine. 49.6% of subjects had antibiotic use last year due to upper airway infection. Gender, educational status and smoking habit didn't differ between vaccinated and unvaccinated participants for both influenza and pneumococcal vaccination. %37 of the participants older than 65 years old were vaccinated against influenza. However, pneumococcal vaccination rate was found to be significantly lower in cases over 65 years (%2 vs %6, p=0.036). Although participants with comorbid diseases showed a tendency to use more antibiotics in prior year (p=0.001), their pneumococcal and influenza vaccination rates were comparable with healthy participants (8% vs 5%, p=0.96 and 25.2 %vs 13.6%, p=0.15). Participants with labor loss in the last three months and effort restraint due to respiratory symptoms had higher vaccination rates for influenza (53% vs 20%, p=0.03 and 31% vs 18%, p=0.04).

Conclusion: Although the most effective strategy for preventing influenza and pneumococcal infection for risk groups is annual vaccination, we found low vaccination rates in Bursa especially in risk groups and elderly people. Country wide survey to determine the knowledge and attitude of family physicians toward influenza and pneumococcal vaccination, planning educational workshops accordingly to make the positive behavior of the people may help increase the vaccine uptake and lower antibiotics use.

Keywords: Vaccination status, pneumococcal vaccine, influenza vaccine

[Abstract:0804] EPS-117 [Accepted: E-Poster] [Lung and Pleura Malignancies]

Investigation of The Effects of miR-219-1 Gene Variants on The Risk of Disease Formation in Non-Small Cell Lung Cancer Patients

Sevgi Kalkanlı Taş¹, Pınar Yıldız², Mustafa Tükenmez³, Tuba Köse⁴, Mesut Bayraktaroğlu², Derya Öztürk⁴, Ender Coşkunpınar⁴

¹Department of Immunology, Health Sciences University School of Medicine, İstanbul, Turkey

²Division of Chest Diseases, Health Sciences University, İstanbul Yedikule Chest Diseases and Chest Surgery Training and Research Hospital, İstanbul, Turkey

³Department of General Surgery, İstanbul University School of Medicine, İstanbul, Turkey

⁴Department of Medical Biology, Health Sciences University School of Medicine, İstanbul, Turkey

Objectives: Lung cancer is the first leading cause of death cancer among worldwide. Non-small cell lung cancer (NSCLC) constitutes for approximately %80 to %85 of all lung cancer cases. The majority of NSCLC patients are at the advanced stage of the disease at instant diagnosis. Therefore, the prognosis in patients is quite severe. Various cancers with Genome Length Association Studies (GWAS), show that miRNAs may be directly related to cancer progression and progression. miRNAs are short, non-coding, short RNA sequences that act as gene regulators in transcriptional and post-transcriptional levels. According to the literature, several variants of the miR-219-1 gene are among the first genes associated with the NSCLC prognosis. In order to better understand the role of miRNAs in cancer, we need to know in more detail the mechanisms of genomic organization, biogenesis, target molecule recognition. Although there are many biomarker screening studies done in non-small cell lung cancer patients, they have not yet been routinely practiced in the genetics. This is because miRNAs do not reveal what direction and degree they affect the genetic expression in the genome. We aim to reveal the mechanisms of the pathways involved in the process of the disease formation and to serve as biomarkers (s) used in the routine of miRNAs detected.

Methods: The study had been diagnosed with non-small cell lung cancer patients and 100 healthy volunteers, 150 volunteer subjects were included in a total of 250 individuals. Genomic DNAs was isolated from blood samples collected from EDTA hemograms and their concentrations were measured. Then, the samples were genotyped by Real-Time PCR method. Statistically significant polymorphisms were evaluated for disease susceptibility or protection.

Results: Preliminary results will be shared when experiments are completed.

Conclusion: The results suggest that changes in the mir219-1 gene may be effective in NSCLC development.

Keywords: Non-small cell lung cancer, microRNA, miR-219-1, biomarker, genotyping

[Abstract:0805] PS-283 [Accepted:Poster Presentation] [Respiratory Failure and Intensive Care]

The Intensive Care Unit Outcome and Long-term Follow-up of Hypoxemic Acute Respiratory Failure Patients with Noninvasive Mechanical Ventilation

Nezihe Çiftaslan Gökşenoğlu, Sinem Güngör, Emine Aksoy, İlim Irmak, Eylem Tunçay, Birsen Ocaklı, Gökay Güngör, Feyza Kargın, Huriye Berk Takır, Zuhul Karakurt

Respiratory Intensive Care Unit, Süreyyapaşa Chest Diseases and Thoracic Surgery Training and Research Hospital, Health Sciences University, İstanbul, Turkey

Objectives: Noninvasive mechanical ventilation (NIMV) is not as successful as in hypercapnic acute respiratory failure as hypoxemic acute respiratory failure (ARF) during intensive care unit (ICU). Nevertheless NIMV is often used in hypoxemic ARF in the ICU. In this study we aimed to defined the reasons and predictors of NIMV failure in patients with hypoxemic ARF who were treated by very experienced intensivist team in the ICU.

Methods: Retrospective cohort study was conducted in a tertiary teaching 58 bed ICU of a respiratory based university hospital between 2016-17. Patients were enrolled if arterial blood gases (ABG) showed hypoxemic ARF (PaO₂/FiO₂ ratio <250 and PaCO₂ <45 mmHg) and NIMV was applied. NIMV failure was defied as intubation for invasive mechanical ventilation (IMV) or death during NIMV. Patients demographics, reasons of hypoxemic ARF, ICU data, reasons of NIMV failure, ICU stay, ICU mortality and mortality after 12 month follow up were recorded from electronic system. NIMV failure and successful patients were compared with recorded data. Kaplan Meier Survival analysis was used for long term survival.

Results: In study period 263 patients were enrolled. NIMV Failure rate (50.6%) and the failure hours were 63 (24-144). When NIMV failure group was compared with NIVM successful ones; the median value of age (68 vs 70 year, p>0.27), gender (male 72% vs 65% p>0.23) were similar. APACHE II score (26 vs 20, p<0.001) and PaO₂/FiO₂ (102 vs 130, p<0.003) were significantly worse in NIMV failure patients. When logistic regression analysis of risks for NIMV failure was analysed, malignancy,

interstitial lung diseases, acute renal failure, higher APACHE II score, culture positive infection were shown to cause NIMV failure. Diabetes, COPD, Congestive heart failure decreased NIMV failure risk. The ICU mortality rate was 47.9% among NIV failure was 95%. Overall one year mortality was 69%; one year mortality of NIMV success and failure groups were 40% and 98% respectively. The Cox regression analysis showed that NIMV failure (HR:10.45, CI 6.73-16.25, $p<0.001$) and any malignancy (HR:1.45, CI:1.01-2.07, $p=0.043$) had increased mortality risk in one year follow-up from time of ICU admission.

Conclusion: Hypoxemic ARF still leads to half chance for NIMV successful independent reasons of ARF in the ICU. Lung cancer, lung parenchymal end stage diseases, very severe acute critical illness are major NIMV failure risks factors in hypoxemic ARF patients. NIMV failure or having malignancy Increased risk of mortality for one year survival.

Keywords: Hypoxemic acute respiratory failure, nimv failure, risc of mortality

[Abstract:0807] SS-003 [Accepted:Oral Presentation] [Asthma and Allergy]

Are Elderly and Aged Asthma Different Diseases? Results of a Multicenter Study

Ebru Çelebioğlu¹, Özge Öztürk Aktaş¹, Bilun Gemicioğlu², Nafiye Yılmaz³, Fulsen Bozkuş⁴, Vehbi Ayhan⁵, Füsün Kalpaklıoğlu⁶, Ferda Öner Erkekol⁷, Yavuz Havlucu⁸, Fuat Erel⁹, Ömur Aydın¹⁰, Aydanur Ekici¹¹, Ayşe Baççioğlu⁶, Serap Argun Barış¹², Gözde Koycu Buhari⁷, Berrin Ceyhan¹³, Özlem Göksel¹⁴, Mehmet Köse⁹, Adile Berna Dursun⁵, Füsün Yıldız¹², Arzu Yorgancıoğlu⁸, Sacide Rana Işık¹⁵, Dane Ediger¹⁶, İpek Kıvılcım Oğuzülgen¹⁷, Gül Karakaya¹, Ali Fuat Kalyoncu¹

¹Department of Chest Diseases, Division of Allergy and Clinical Immunology, Hacettepe University School of Medicine, Ankara, Turkey

²Department of Chest Diseases, İstanbul University Cerrahpaşa School of Medicine, İstanbul, Turkey

³Department of Chest Diseases, Atatürk University School of Medicine, Erzurum, Turkey

⁴Department of Chest Diseases, Sütçü İmam University School of Medicine, Kahramanmaraş, Turkey

⁵Department of Chest Diseases, Recep Tayyip Erdoğan University School of Medicine, Rize, Turkey

⁶Department of Chest Diseases, Division of Allergy and Clinical Immunology, Kırıkkale University School of Medicine, Kırıkkale, Turkey

⁷Department of Allergy, Atatürk Chest Diseases and Thoracic Surgery Research Hospital, Ankara, Turkey

⁸Department of Chest Diseases, Celal Bayar University School of Medicine, Manisa, Turkey

⁹Department of Chest Diseases, Balıkesir University School of Medicine, Balıkesir, Turkey

¹⁰Department of Chest Diseases, Division of Allergy and Clinical Immunology, Ankara University School of Medicine, Ankara, Turkey

¹¹Department of Chest Diseases, Kırıkkale University School of Medicine, Kırıkkale, Turkey

¹²Department of Chest Diseases, Kocaeli University School of Medicine, Kocaeli, Turkey

¹³Department of Chest Diseases, Pendik Research and Training Hospital, Marmara University, İstanbul, Turkey

¹⁴Department of Chest Diseases, Ege University School of Medicine, İzmir, Turkey

¹⁵Department of Chest Diseases, Yedikule Chest Diseases and Thoracic Surgery Training and Research Hospital, İstanbul, Turkey

¹⁶Department of Chest Diseases, Division of Allergy and Clinical Immunology, Uludağ University School of Medicine, Bursa, Turkey

¹⁷Department of Chest Diseases, Gazi University School of Medicine, Ankara, Turkey

Objectives: Previous studies showed that asthma prevalence among people aged over 65 years and late onset asthma, in which the latter is reported to be more severe and less atopic. Asthma onset at later ages (elderly asthma) may be a different disease than asthma that begins early in life and carries over to older ages (aged asthma, early onset asthma). The aim of the present study was to evaluate asthma in the elderly population, and to compare disease characteristics between patients diagnosed <60 and ≥ 60 years of age.

Methods: Study was designed as prospective, multicenter, crosssectional type. Between October 2015 and 2017, a questionnaire was filled out by the treating physician to patients 60 years of age and over, that have been followed for asthma at least 3 months. Morisky Medication Adherence Questionnaire, and Asthma Control Test (ACT) was filled out and inhaler device technique assessment was performed. Demographic and disease characteristics of patients were evaluated and patients with elderly asthma and aged asthma were compared.

Results: In total 445 patients were analyzed and 399 included. Of the patients 331 (83%) were women, mean age, mean asthma diagnosis age, and disease duration were 67.11 (±5.72), 52.29 (±12.54), and 14.98 (±12.31) years, respectively. Diagnosis was established based on history, early reversibility, late reversibility, PEF variability, and nonspecific bronchial challenge in 33.8%, 32.6%, 23.6%, 5.5%, and 4.5%, respectively. At least one asthma related comorbidity was present in 299 (74.9%) patients, and mean FEV1% was 78.95 (±23.59), systemic corticosteroid use in previous year was 40%. Half of the patients (50.4%) had an ACT score of >19, medication adherence was high in 24.8%, and inhaler device technique was correct in

37%. In total 147 (36.8%) patients were diagnosed ≥ 60 years of age. Table 1 shows the comparison of disease characteristics between patients diagnosed <60 and ≥ 60 years of age.

Conclusion: This is the first multicenter and largest study in Turkey that shows the characteristics of asthma in patients >60 years of age. We saw that elderly, and aged asthma have different characteristics. Although elderly asthma patients more commonly have asthma related comorbidities, their education level, level of asthma control and medication adherence were higher. Patients with aged asthma were using more drugs, and had more asthma medication related side effects.

Keywords: Elderly asthma, Late onset asthma, asthma phenotypes, atopic asthma

Table 1. Comparison of disease characteristics between patients diagnosed <60 and ≥ 60 years of age

n (%)	Diagnosis age ≥ 60 148 (100)	Diagnosis age <60 251 (100)	Total 399 (100)	p
Age, mean (SD)	68.66 (5.74)	66.20 (5.54)	67.11 (± 5.72)	<0.001
Duration of asthma (years) , mean (SD)	5.82 (7.93)	20.33 (11.22)	14.98 (± 12.31)	<0.001
Gender, M/F %	15/85	18.3/81.7	17/83	0.40
BMI, mean (SD) *	30.80 (6.07)	32.36 (6.67)	31.79 (6.49)	0.02
University degree	21 (%14.3)	4 (1.6)	25 (6.3)	<0.001
Ever smoker	24 (16.3)	44 (17.5)	68 (17)	0.77
Positive skin prick test [^]	36 (24.5)	64 (25.4)	100 (25.1)	0.11
Asthma related comorbidity	121 (82.3)	178 (70.6)	299 (74.9)	0.009
FEV1 % ^o , mean (SD)	79.81 (22.64)	78.44 (24.18)	78.95 (± 23.59)	0.58
Systemic corticosteroid use (previous year)	59 (40.1)	101 (40.1)	160 (40.1)	0.99
ACT >19	89 (60.5)	112 (44.4)	201 (50.4)	0.002
High drug adherence (Morisky score of 8)	55 (37.4)	44 (17.5)	99 (24.8)	<0.001
Correct device technique	62 (42.2)	86 (34.1)	148 (37.1)	0.1
Asthma medication related side effect	26 (17.8)	68 (27.2)	94 (23.7)	0.03
Low dose inhaler steroid+ LABA	40 (30.8)	35 (19.2)	75 (24)	0.02
Medium dose inhaler steroid + LABA	51 (39.2)	94 (51.6)	145 (46.5)	0.03
Add on montelukast	56 (38.1)	123 (48.8)	179 (44.9)	0.03
Add on theophylline	8 (5.4)	34 (13.5)	42 (10.5)	0.01

*recorded in 370, ^performed in 279 (%69.8) , °376 patients, 312 patients, BMI; body mass index, ACT; asthma control test, LABA; long acting beta2 agonist

[Abstract:0810] PS-012 [Accepted:Poster Presentation] [Clinical Problems - Diffuse Parenchymal Lung Disease]

The Effectiveness, Safety and Tolerability of Pirfenidon Therapy in Our Patients With Idiopathic Pulmonary Fibrosis

İsmail Hanta¹, Aykut Çilli², Can Sevinç³, Hülya Dirol², Kemal Can Tertemiz³

¹Department of Chest Diseases, Çukurova University School of Medicine, Adana, Turkey

²Department of Chest Diseases, Akdeniz University School of Medicine, Antalya, Turkey

³Department of Chest Diseases, Dokuz Eylül University School of Medicine, İzmir, Turkey

Objectives: Recently, antifibrotic therapy has been approved in idiopathic pulmonary fibrosis (IPF). In this study, we aimed to evaluate effectiveness, safety and tolerability of pirfenidon therapy in our patients with IPF.

Methods: In this retrospective study, we were evaluated 60 IPF patients who were taking pirfenidon at least for 6 months. IPF was diagnosed by clinical and radiology and/or histopathology. Patient characteristics, symptoms, pulmonary function tests (FVC, DLCO), 6-minute walk test (6-MWT) and effectiveness of therapy (stability or progression of the disease defined as

decline of FVC (%pred.) $\geq 10\%$) at baseline and after 6 months of drug therapy), side effects, any hospitalization and mortality were recorded.

Results: Of 60 IPF patients, 44 (73.4%) were male. While 46 (76.7%) IPF patients were stable during therapy course, 14 (23.3%) IPF patients had progressed according to decline in FVC $\geq 10\%$. During 6 months of antifibrotic therapy, in 9 (15.0%) IPF patients had exacerbation, and in 10 (16.7%) patients had all-cause hospitalization and one (1.7%) patient died. At least one side effect due to therapy were encountered in 33 (55.0%) IPF patients. Leading side effects were gastrointestinal symptoms (n=21, 35.0%) and photosensitivity (n=8, 13.3%). While in 16 (26.7%) patients, therapy dose was decreased, in only one (1.7%) patients therapy was discontinued due to intolerability.

Conclusion: We concluded that pirfenidone therapy for IPF was effective and tolerable, and also had relatively acceptable side effects in our patient with IPF.

Keywords: Idiopathic pulmonary fibrosis, pirfenidone, therapy

[Abstract:0814] EPS-233 [Accepted: E-Poster] [Thoracic Surgery]

Results of Dilatation in Children with Subglottic Stenosis

Serdar Onat¹, Ali Birak¹, Funda Öz¹, Fatih Meteroğlu¹, Menduh Oruç¹, Cihan Akgül Özmen², Refik Ülkü¹

¹Department of Chest Surgery, Dicle University School of Medicine, Diyarbakır, Turkey

²Department of Chest Surgery, Dicle University School of Radiology, Diyarbakır, Turkey

The most common cause of acquired tracheal stenosis is prolonged tracheal intubation. Tracheal stenosis is a serious life-threatening respiratory problem.

Tracheal stenosis leads to dyspnea, cough, stridor, wheezing respiration or frequent respiratory infections. Among these, severe dyspnea is the one that is the most urgent and should be intervened rapidly. Dilatation, laser, cryotherapy, local steroids and mitomycin-c are the alternative treatments besides resection which is the standard treatment in the treatment of tracheal stenosis. Dilatation at an early and appropriate time may prevent the tracheostomy and eliminate the need for surgery.

The records of patients who consulted to our clinic due to subglottic stenosis after prolonged intubation in pediatric clinic between the years of 2012 and 2017 were retrospectively reviewed. Six of the seven patients were male. The mean age of the patients was 4.8 (age range 1-14). All patients had severe respiratory distress. All patients had direct X-ray and four patients had computerized tomography.

Dilatation was performed in all patients with rigid bronchoscopy under general anesthesia and the granulation tissue was debrided. After dilatation with a rigid 2.5 mm bronchoscope at the first entry in three patients, the procedure was continued with 3.5, 4, and 5 mm bronchoscopes, respectively. Procedure was started with a 3.5 mm bronchoscope in four patients. Tracheal dilatation was performed with rigid bronchoscope at least 1 time and maximum 6 times. One patient underwent tracheal dilation twice with a day's break. Tracheal dilatation was performed in the other 3 patients 15 days later the earliest, and one month later the latest. In one patient, respiratory distress developed after tracheal dilatation and he/she was intubated. On the third day of the intubation, the patient was extubated. The average follow-up time was 28 months. The stenotic part was detected in the subglottic area in all of the patients. Surgical resection or tracheostomy was not required after tracheal dilatation in any patients.

Despite the technological innovations in intensive care units and increasing level of expertise in patient care, post-intubation tracheal stenosis remains an important clinical problem. The incidence of tracheal stenosis after laryngotracheal intubation and tracheostomy may increase up to 21%. The main cause of stenosis is that high cuff pressure causes mucosal ischemia during the long intubation period. Surgical procedure is at the foreground in the actual treatment of tracheal stenosis that is seen after intubation. However, bronchoscopic dilatation is an important tool in the treatment of tracheal stenoses. The success rate of bronchoscopic dilatation varies between 53% and 100%. In addition to the fact that dilatation provides definitive treatment, it eliminates the need for tracheostomy. It also increases the success rate of the surgical procedure and reduces the complication rate. Tracheostomy that is required to be performed in emergency conditions can save life; however, it may cause very serious complications and raise difficulties for the trachea surgery to be performed later. Therefore, dilatation with rigid bronchoscope should absolutely be considered prior to surgery or tracheostomy.

Keywords: Tracheal stenosis, child, dilatation

[Abstract:0815] EPS-247 [Accepted: E-Poster] [Thoracic Surgery]

A Rare Chest Wall Tumor Seen During Childhood: Rhabdomyoma

Ali Birak, Serdar Onat, Funda Öz, Fatih Meteroğlu, Menduh Oruç, Refik Ülkü

Department of Chest Surgery, Dicle University School of Medicine, Diyarbakır, Turkey

Rhabdomyoma is a rare soft tissue benign neoplasm. It constitutes only 2% of all tumors with skeletal muscle differentiation. These tumors can arise from cardiac or skeletal muscles. Rhabdomyomas can be cardiac and extracardiac. Cardiac rhabdomyomas are common primary tumors mostly seen in newborns and children. They are usually associated with tuberous sclerosis. Extra cardiac rhabdomyomas are divided into three according to clinical and histological subtypes: adult, fetal and genital. They constitute 50%, 40% and 10% of extracardiac rhabdomyomas, respectively. Of the extracardiac adult rhabdomyomas, 70-75% are seen in the head and neck region. It is most commonly seen in the pharynx, oral cavity, and larynx mucosa. The fetal subtype is again seen in children and adults, typically in the head and neck region. The genital subtype is a polypoid tumor seen in the vagina or vulva in middle-aged women. It was reported that these tumors rarely appeared in the chest wall, extremities, esophagus, stomach and mediastinum. Rhabdomyoma is a tumor that is rarely seen in the chest wall. We aimed to present a rhabdomyoma case in the anterior chest wall of a child and to emphasize that rhabdomyoma should not be ignored in the differential diagnosis of chest wall tumors.

A 7-year-old girl was admitted to our clinic with a complaint of swelling and pain which persisted in the anterior chest wall for about 2 years and tended to grow for the last 3 months. Chest computed tomography revealed a mass lesion that was 7,5x6,5 cm in diameter and extended from the left supraclavicular region to the infraclavicular region. It was found that the mass leant against the anterior segment of the left upper lobe extending to the thorax via the 1st rib and suppressing the subclavian artery in the infraclavicular area. Laboratory tests of the patient were within normal limits. Operation was planned for the patient with the cardiovascular surgery clinic. The mass was dissected from the chest wall through a 10 cm incision made in the infraclavicular area. The pathological diagnosis of the mass was reported as rhabdomyoma. The patient who was discharged on the 5th postoperative day has been under our follow-up for about 1 year.

Rhabdomyomas are extremely rare neoplasms that are usually seen between the ages of 40-70. They are more common in males than in females; the male-female ratio is about 3-6/1. They are usually located in the head and neck region. Rhabdomyoma is usually unifocal, but 15% of cases are multifocal.

These tumors usually cause symptoms by compressing on neighboring organs. The symptoms depend on the size and location of the lesion. Tumors grow slowly, and accordingly, clinical manifestations occur in late period. Diagnosis is made by histological examination of the tissue taken with fine needle biopsy or surgical biopsy. A complete resection is the preferred treatment method of rhabdomyoma. Tumor recurrence is usually associated with incomplete resection, so complete removal of the lesion is of vital importance. Patients should be followed up regularly after resection.

Rhabdomyoma, although rarely detected, should always be considered in the differential diagnosis of chest wall tumors.

Keywords: Rhabdomyoma, child, rare

[Abstract:0818] PS-063 [Accepted:Poster Presentation] [Thoracic Surgery]

The Effect of Neoadjuvant Protocols Applied Due to Non-Small Cell Lung Cancer on Postoperative Mortality and Survival

Çağrı Cemaller¹, Hasan Akın², Yaşar Sönmezoğlu², Mehmet Kılıç², Altan Ceritoğlu²

¹Department of Chest Surgery, Dr. Burhan Nalbantoğlu State Hospital, Nicosia, Cyprus

²Yedikule Chest Diseases and Chest Surgery Education and Research Hospital, İstanbul, Turkey

Objectives: The aim of our study is to determine the mortality and survival rates of the patients undergoing multimodal therapies consisting of surgical procedure after neoadjuvant treatment and to compare the results of protocols.

Methods: Forty-eight patients who were operated after neoadjuvant treatment for NSCLC between Jan 01, 2008 and Jan 01, 2017 in the 2nd Surgical Clinic and Medical Oncology Clinic of Yedikule Chest Diseases and Chest Surgery Training and Research Hospital were investigated. The data were retrospectively analyzed from the data set that was prospectively generated for these patients.

Results: The mean age of the 48 patients included in the study was 56.25 (49-72) and the gender distribution was 7 female and 41 male patients. There was no statistically significant difference in terms of survival between the patients (21 patients) in whom neoadjuvant treatment was performed, and who were operated after the tumor invasion regressed and the patients (27 patients) in whom neoadjuvant therapy was performed due to lymph node involvement and who were operated after it was proved that there was no lymph node involvement ($p=0.902$). Resection types performed in the patients include pneumonectomy and lobectomy, and chest wall resections performed with lobectomy. Twenty-six (54%) of 48 patients underwent lobectomy, 16 (33%) underwent chest wall resection with lobectomy and 6 (13%) underwent pneumonectomy. It was found that the applied surgery did not have a statistical effect on the survival of the patients ($p=0.124$). Tumor histopathology of the patients was compared and their effects on survival were evaluated. Survival was statistically significantly higher in the patients whose tumor histopathology was squamous cell carcinoma than in the patients whose tumor histopathology was adenocarcinoma ($p=0.034$). According to pathologic staging, 22 of the patients undergoing surgery after neoadjuvant were in stage T0, 10 were in stage T1, 5 were in stage T2, and 11 were in stage T3. The change in cT and pT scores was found to be statistically significant ($p < 0.001$). While 18 patients were in stage N0 and 30 patients were in stage N2 before the neoadjuvant treatment, 39 of the patients who underwent surgery after neoadjuvant treatment were stage N0, 3 were stage N1 and 6 were stage N2. The change in cN and pN scores were found to be statistically significant ($p < 0.001$). The neoadjuvant treatment protocols used for the patients include only chemotherapy (17 patients) and chemoradiotherapy (31 patients) treatments. No statistically significant difference was observed in terms of survival between the two treatment protocols ($p = 0.330$).

Conclusion: Neoadjuvant CRT and neoadjuvant CT treatment protocols did not have superiority to each other in terms of survival. Thanks to the neoadjuvant treatment protocols applied to stage III NSCLC patients, the disease can be made suitable for surgical treatment by providing local control and tumor down-staging, and positive changes can be achieved in survival with this multimodal therapy approach. When a resection is performed, the most possibly minimized anatomical resection should be preferred. However, as indicated in the study, multimodal therapy approach which includes surgical treatment can contribute to survival in cases requiring pneumonectomy as well, and the type of surgical resection has no effect on survival and mortality. In our study, the adenocarcinoma type in the NSCLC was found to be worse than squamous cell carcinoma in terms of survival.

Keywords: Small cell lung cancer, neoadjuvant treatment, surgical mortality and survival

[Abstract:0822] PS-225 [Accepted:Poster Presentation] [COPD]

The Importance of Venous Blood Gas Analysis in Acute Exacerbation of COPD

Ali Kadri Çırak, Serpil Tekgöl, Yelda Varol, Zeynep Öndeş, Görkem Vayısoğlu Şahin, Ali Korkmaz, Sami Deniz, Gülistan Karadeniz, Aydan Mertoğlu, Dursun Alizoroğlu, Melih Büyüksirin, Enver Yalnız

Health Sciences University, Suat Seren Chest Diseases and Surgery Training and Research Hospital, İzmir, Turkey

Objectives: Obtaining acute respiratory failure is essential for determining the initial treatment of acute exacerbation of Chronic Obstructive Pulmonary Disease (AECOPD). Although guidelines suggest using arterial blood gas analysis in order to obtain respiratory failure, it is difficult to practice and had a high complication risk. Venous blood gas analysis can be performed simultaneously in order to obtain other laboratory tests. In this study we aimed to obtain the importance of venous blood gas analysis compared to arterial blood gas analysis in AECOPD.

Methods: Demographic data, arterial and venous blood gas analysis (pH, pCO₂, PO₂, Saturation of O₂, HCO₃) performed simultaneously from 100 hospitalized patients with AECOPD. VAS pain score was performed to all patients after the procedure. Bland –Altman analysis was used to obtain the concordance of variables of arterial and venous blood gas analysis. Correlation coefficient was calculated for each variable by pearsonproduct-moment correlation.

Results: A total of 100 (31 female) patients were included in the study. The mean age was 64.8±11. Number of procedure (median 1.09 (1-2) -1.36 (1-4)) and VAS scores (median 3.12 (1-9) -4.85 (1-10)) was statistically significantly lower in venous blood gas analysis compared to arterial blood gas analysis ($p < 0.0001$ both). When we studied the accord of arterial and venous blood gas analysis parameters we determined that pH, pO₂, pCO₂, HCO₃ and SpO₂ values were similar statistically.

(pH; median difference: -0.04 (-0.04 and -0.03 95% CI), pO₂ median difference: -24.20 (-29.20 and -20.40 95% CI), pCO₂; median difference: 5.70 (3.70 and 8.00 95% CI), HCO₃; median difference: -0.35 (-0.60 and -0.20 95% CI), SpO₂; median difference: -20.20 (-24.00 and -14.90 95% CI) respectively).

Conclusion: In this study we obtained a statistically significant compatibility between arterial and venous blood gas analysis parameters pH, pO₂, pCO₂, HCO₃, SO₂. In conclusion we believe that venous blood gas analysis can be used to obtain respiratory failure with other clinical and laboratory findings instead of arterial blood gas analysis in AECOPD patients.

Keywords: Arterial blood gas analysis, COPD, venous blood gas analysis

[Abstract:0823] EPS-182 [Accepted: E-Poster] [Thoracic Surgery]

A Different Cause of Respiratory Distress; Diaphragm Diseases

Selçuk Gürz¹, Ayşen Taslak Şengül¹, Yasemin Bilgin Büyükkarabacak¹, Burçin Çelik¹, Necmiye Gül Temel¹, Mehmet Gökhan Pirzirenli², Ahmet Başoğlu¹

¹Department of Thoracic Surgery, Ondokuz Mayıs University School of Medicine, Samsun, Turkey

²Şanlıurfa Training and Research Hospital, Şanlıurfa, Turkey

Objectives: The diaphragm is the basic respiratory tract that is stimulated by the phrenic nerve. Congenital defects and evantration of the diaphragm may cause loss of respiratory function in later ages. In this study, we aimed to retrospectively evaluate non-traumatic diaphragmatic diseases surgically treated in our clinic.

Methods: Forty-two patients who underwent surgical treatment for non-traumatic diaphragm pathology at Ondokuz Mayıs University Medical Faculty Chest Surgery Clinic between 2007 and 2017 were retrospectively studied. The data were evaluated in terms of age, gender, complaint, pathology, respiratory function, radiology, surgery, comorbidity score and mortality.

Results: From the 42 patients with a mean age of 59.8±15.5 included, %64.3 (n=27) were female and %35.7 (n=15) were men. On the radiological scanning, 40.5% of the patients were found to be Morgagni, 9.5% were Bochdalek and 11.9% were Hiatal Hernia. 38.1% of the patients under went surgical treatment due to diaphragm evantration. The most common symptom was respiratory distress (52.4%) and the most common pathology was diaphragm in the left side (52.4%). Surgically, 26.2% of the patients had a plication due to evantration. 92.3% of the diaphragmatic defects were repaired primary suturation and 7.7% were repaired using a prosthesis. Morbidity rate was 4.8% and mortality was seen in 2 patients.

Conclusion: Congenital diaphragm hernia is a congenital anomaly with a defect in the diaphragm. Diaphragm evantration is the permanent rise of all or part of the diaphragm leaf with intact scars and organ connections, and is rarely seen in adults. Both diaphragm pathologies may also manifest with respiratory distress. Surgical treatment options for diaphragm, especially in patients with symptoms, increase quality of life by reducing patient complaints.

Keywords: Diaphragm, evantration, hernia, respiratory

[Abstract:0828] PS-010 [Accepted:Poster Presentation] [Clinical Problems - Diffuse Parenchymal Lung Disease]

Two Cases with Gastric Sarcoidosis

Selma Aydoğan Eroğlu¹, Dildar Duman¹, Birsen Ocaklı¹, Reyhan Yıldız¹, İpek Erdem¹, Fatma Tokgöz Akylı², Tülin Sevim¹

¹Department of Chest Diseases, Health Sciences University, Süreyyapaşa Chest Diseases and Thoracic Surgery Education and Research Hospital, İstanbul, Turkey

²Department of Chest Diseases, Çanakkale State Hospital, Çanakkale, Turkey

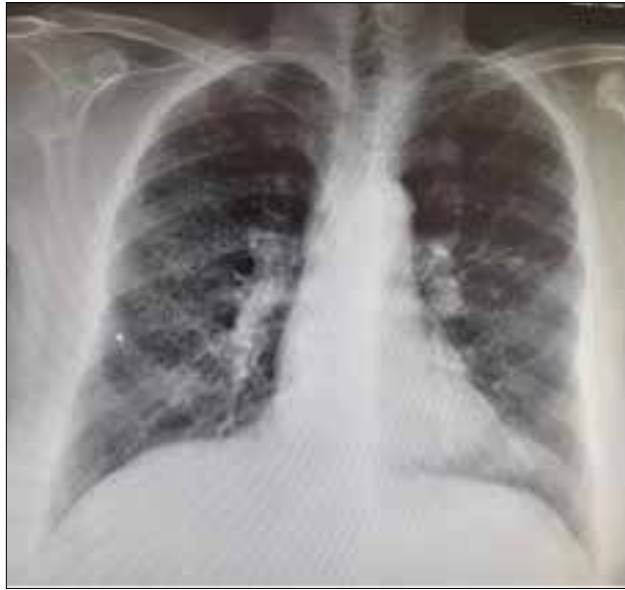

Figure 1. Case 1 PA Chest Radiography

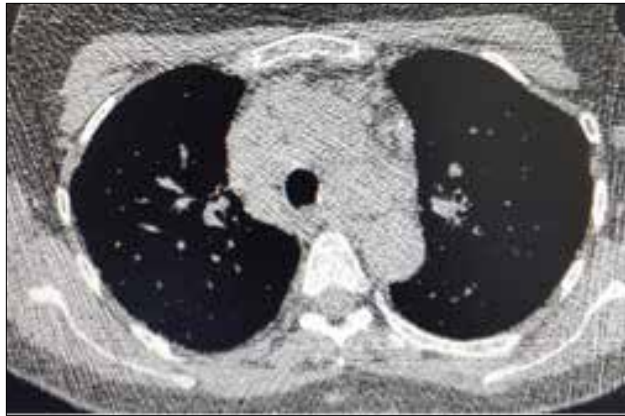

Figure 2. Case 2 Thoracic CT

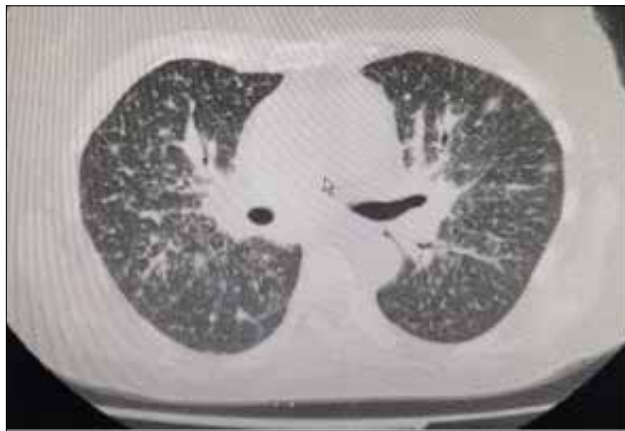

Figure 3. Case 2 Thoracic CT

Introduction: Gastrointestinal (GIS) involvement is a rare condition in sarcoidosis. Stomach antrum involvement is most common in GIS. Complaints are nonspecific, the most common is nausea and epigastric pain. In our sarcoidosis polyclinic we detected 2 cases of gastric sarcoidosis.

Case 1: A 43-year-old female patient underwent fiberoptic bronchoscopy (FOB) with suspicion of pulmonary and lymph node sarcoidosis. The result of mediastinoscopy was consistent with non-necrotizing granulomatous inflammation. The patient was followed up at our polyclinic with the diagnosis of sarcoidosis. Because of sudden weight loss, anemia and moderate elevation of liver enzymes, patient was directed to the gastroenterology polyclinic. Gastroscopy and liver tru-cut biopsies were performed and pathology was reported as chronic active gastritis, focal granulomas, granulomatous gastritis and liver biopsy as well as non-necrotizing granulomatous hepatitis involving lobules and portal sites. 40 mg steroid treatment was started with the diagnosis of gastric sarcoidosis. Patient who had three times recurrence while under steroid treatment was stopped and methotrexate treatment was given. He has been stable for 1 year.

Case 2: A 69-year-old female patient underwent transbronchial biopsy due to nodular infiltrates in both lungs and pathology was reported as non-necrotizing granulomatous inflammation and BAL findings were also consistent with sarcoidosis. and the patient was followed up at our polyclinic. The patient who was referred to the gastroenterology polyclinic because of the swallowing difficulty developing in her follow-up, gastroscopy performed and pathology was reported as non-necrotizing granulomatous inflammation. 40 mg steroid treatment was started with the diagnosis of gastric sarcoidosis. Treatment is ongoing.

Conclusion: Although gastric involvement is a rare in sarcoidosis, it should be kept in mind in patients with sarcoidosis, especially with chronic epigastric complaints. The majority of patients respond well to steroid therapy.

Keywords: Sarcoidosis, gastric involvement, granuloma

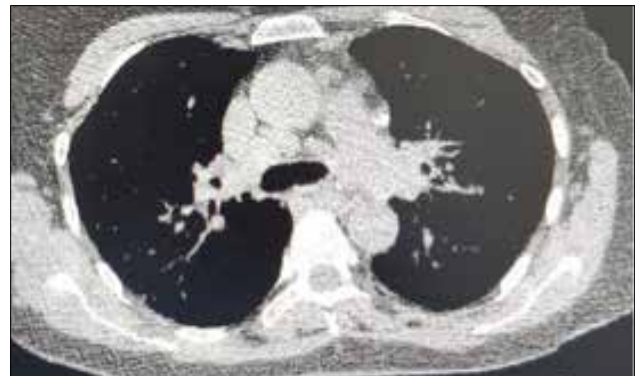

Figure 4. Case 2 Thoracic CT

[Abstract:0831] PS-141 [Accepted:Poster Presentation] [Clinic Problems - Others]

Bronchial Artery Embolization in Our Cases with Hemoptysis

Department of Chest Diseases, Health Sciences University Yedikule Chest Diseases and Thoracic Surgery Training and Research Hospital, Istanbul, Turkey

Objectives: Bronchial artery embolization was first described in 1973 by Remy et al., and is an effective and reliable method of treatment for massive hemoptysis. Today, even in the case of moderate or even slight bleeding, embolization is performed and success is achieved. In this study, bronchial artery embolization was evaluated retrospectively for massive or non massive hemoptysis in our clinic.

Methods: Thirty-four patients (8 female, 26 male) who underwent bronchial artery embolization for hemoptysis between 2012 and 2016 were screened retrospectively. Patients' diagnoses and hemoptysis were recorded as recurrences and recurrences in which diagnostic groups.

Results: The mean age of the patients was 53.35. Major bleeding occurred in 5.9% of patients, submassive hemorrhage in 73.5% and massive hemorrhage in 20.6% of patients. 11.8% of the patients were idiopathic; 47.0% had sequel tuberculosis, 23.5% had bronchiectasis, 14.7% had malignancy, 5.9% had active tuberculosis and 3% had aspergilloma. Twenty-six of our 34 patients (76.5%) who underwent embolisation had their bleeding controlled during admission. There were recurrences after embolization in 21 patients (61.8%) from 34 patients who underwent embolisation. 9.5% of patients with recurrence were idiopathic; 57.1% had sequel tuberculosis, 28.6% bronchiectasis, 4.8% malignancy, 4.8% active tuberculosis and 4.8% aspergilloma.

Conclusion: Bronchial artery embolization was observed to be most frequent in sequel tuberculosis and recurrence after embolization was more common in this group. Our postoperative success rate (76.5%) was high and recurrence rate was high (61.8%). However, we think that this method is effective and alternative to surgery in both massive hemoptysis and nonmassive hemoptysis.

Keywords: Bronchial artery embolization, hemoptysis, sequel tuberculosis

Table 1. Etiological Diagnosis of Patients with Embolization

Etiological diagnosis	Number of patients	%
idiopathic	4	11.8
Sequel Tuberculosis	16	47.0
Bronchiectasis	8	23.5
Malignancy	5	14.7
Active Tuberculosis	2	5.9
Aspergilloma	1	3.0

Table 2. Etiologic diagnosis of recurrences after embolization

	Number of patients	%
idiopathic	2	9.5
Sequel Tuberculosis	12	57.1
Bronchiectasis	6	28.6
Malignancy	1	4.8
Active Tuberculosis	1	4.8
Aspergilloma	1	4.8
Postembolization Recurrence	21	61.8

[Abstract:0832] SS-018 [Accepted:Oral Presentation] [COPD]

Does The Body Composition Changes from GOLD Categories A to D in Patients With COPD ?

Funda Elmas Uysal¹, Alev Gürgün¹, Hatice Uluer²

¹Department of Chest Diseases, Ege University School of Medicine, İzmir,Turkey

²Department of Biostatistics and Medical Informatics, Ege University School of Medicine, İzmir,Turkey

Objectives: One of the most important comorbid conditions determining the prognosis of COPD patients is body composition. We aimed to investigate the changes in body composition, exercise capacity and quality of life according to GOLD A, B, C, and D categories.

Methods: In this prospective study; symptoms were measured by COPD Assessment Test (CAT) and the modified Medical Research Council (mMRC) scale. Shuttle walk test and SGRQ were performed. Bioelectrical impedance was used for the measurement of body mass (BMI) and fat free mass indexes (FFMI).

Results:123 patients (103 male, age 67.5±7.83 yrs, FEV1% 57.18±19.21) with COPD were classified into group A (32.5%), group B (35.8%), group C (5.7%) group D (26.0%). CAT and mMRC scores, walking distances and all parameters of SGRQ were statistically different in categories A, B, C, and D (p<0.001) ; walking distances were highest in groups

A, C, B and D, respectively (466.25, 412.86, 301.59, 280.31m). Symptom, effect, activity and total scores of SGRQ were higher in group B than in group C and similar to group D. There was no difference between the groups in terms of BMI (26.25 ± 5.47 , 26.13 ± 5.19 , 27.18 ± 5.06 , 25.07 ± 5.59 , $p=0.752$) and FFMI (19.37 ± 2.67 , 19.18 ± 2.21 , 20.97 ± 2.42 , 19.25 ± 2.62 ; $p=0.266$). CAT and mMRC scores, walking distances and all parameters of SGRQ were not statistically different when the cases were grouped according to VKI ($<25 \text{ kg/m}^2$, $25\text{-}30 \text{ kg/m}^2$, $>30 \text{ kg/m}^2$). Mean FEV 1% was lowest in the group $<25 \text{ kg/m}^2$ were the lowest (51.99 ± 19.43). The group with VKI $25\text{-}30 \text{ kg/m}^2$ had the highest FEV1% and mean resting saturation whereas patients with BMI $>30 \text{ kg/m}^2$ had the lowest resting saturation (95.08 ± 2.8 , 95.59 ± 2.13 , 93.35 ± 3.46 , $p=0.008$, respectively).

Conclusion: BMI and FFMI were not significantly different among the groups and BMI was lowest in group D, followed by groups B, A and C respectively. The decrease in exercise capacity and quality of life was not parallel to the categorization of COPD (A to D). The patients in group B had similar features with the patients in Group D. Additionally, resting lower oxygen levels were found in the obese group which may remind OSAS component and this may cause early development of cor pulmonale. In conclusion, obesity as well as cachexia has a prognostic effect on the prognosis in COPD.

Keywords: COPD, body mass index, hypoxemia

[Abstract:0833] PS-136 [Accepted:Poster Presentation] [Clinical Problems - Pulmonary Vascular Diseases]

Rapidly Progressing Wegener's Granulomatosis Case

Özlem Ataoğlu, Pınar Yıldız Gülhan, Fuat Aytekin, Merve Erçelik, Öner Abidin Balbay

Department of Chest Diseases, Düzce University School of Medicine, Düzce, Turkey

Introduction: Wegener's granulomatosis (WG) is an autoimmune vasculitis whose etiology is unknown, which involves especially the upper respiratory tract, lungs and kidneys and which is characterized by necrotizing granulomatous vasculitis. The diagnosis is made on the basis of clinical findings, cytoplasmic antineutrophil cytoplasmic antibody (cANCA) positivity and histological findings. We presented a massive progressive WG case who consulted with the complaint of hemoptysis, and in whom the cause of chronic renal failure (CRF) was investigated for 2 months.

Case Presentation: A 59-year-old male patient was admitted to our outpatient clinic with the complaint of dyspnea, hemoptysis and 13 kg weight-loss within 2 months. The patient was examined for the etiology of CRF at an external center for 2 months. There were COPD and Rheumatoid Arthritis (RA) diagnoses in his anamnesis. He irregularly used oral methylprednisolone and prequanel for 1 year for the diagnosis of RA. Posteroanterior chest X-ray (PA-CXR) showed diffuse heterogeneity in the left middle and the lower zones (Figure 1). The laboratory testes showed the values as hemoglobin 9, WBC 27000 μl , CRP 12 mg/dl and creatinine 2 mg/dl. He had 3 positive hematuria in his urine. With these findings, the patient was hospitalized with the pre-diagnoses of malignancy, pneumonia, and renopulmonary syndrome. Nonspecific antibiotic therapy was started. On the 4th day of hospitalization, hemoglobin levels fell to 5 gr/dL. It was observed in his control PA-CXR that infiltrations increased and were bilateral (Figure 2). Because the c-ANCA value of the patient with increased respiratory distress was positive, 500 mg of methylprednisolone was administered with the diagnosis of WG, and the patient whose saturation values did not rise and general condition did not improve was entubated. A plasmapheresis treatment was recommended to the patient in consultation with the department of internal medicine. Since our hospital did not have the possibility for plasmapheresis treatment, the patient was referred to an external center, and it was found out that the patient died there.

Conclusion: WG can manifest itself with very different clinical pictures. There may be a delay in the diagnosis because the symptoms are not specific. In the study for the etiology of hemoptysis, it should not be forgotten that complete urine examination is often useful in terms of vasculitis in the initial period and that lung involvement of WG may be massive. Since morbidity and mortality are high, it is important to establish the diagnosis early.

Keywords: Hemoptysis, chronic renal failure, Wegener's granulomatosis

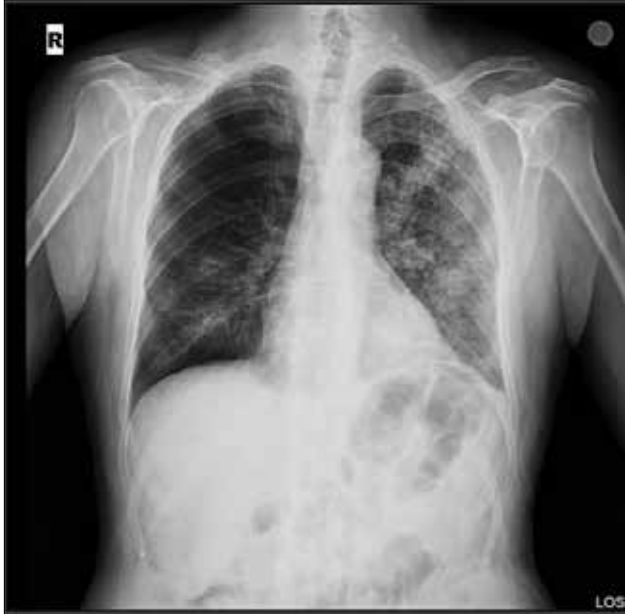

Figure 1. Heterogeneous appearance in the left middle and lower zone

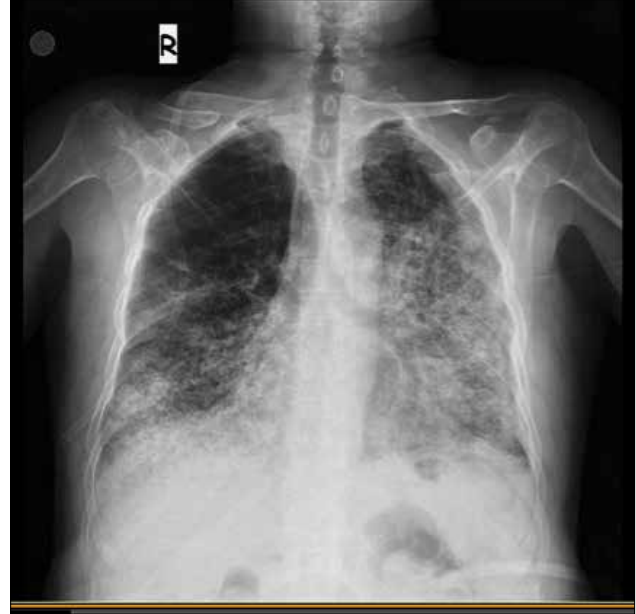

Figure 2. Heterogeneous image in the right lower and left middle-lower zone

[Abstract:0834] EPS-255 [Accepted: E-Poster] [Thoracic Surgery]

Bronchopleural and Oesophageal Fistula Which Developed at Different Locations in a Patient Who Was Operated Due to NSCLC Two Years Ago

Selime Kahraman¹, Cansel Atınkaya¹, Abdurrahim Gördebil¹, Murat Kavas², Şenol Ürek¹, Çağatay Tezel¹, İrfan Yalçınkaya¹, Akın Öztürk³

¹Department of Chest Surgery, Süreyyapaşa Chest Diseases and Chest Surgery Education and Research Hospital, Chest Surgery Clinic, İstanbul, Turkey

²Department of Chest Surgery, Süreyyapaşa Chest Diseases and Chest Surgery Education and Research Hospital, Chest Diseases Clinic, İstanbul, Turkey

³Department of Chest Surgery, Süreyyapaşa Chest Diseases and Chest Surgery Education and Research Hospital, Chest Surgery Clinic, Medical Oncology, İstanbul, Turkey

A 57-year-old male patient who underwent right pneumonectomy two years ago consulted with the complaint of fluid coming from the mouth while coughing in the third postoperative month. A level decrease was seen in PA chest X-ray of the patient, and FOB was applied. When minimal fistula was observed in the bronchial stump, tube thoracostomy closed underwater drainage was performed and antibiotic therapy was applied. The patient was discharged with a Heimlich valve, and the drainage was terminated approximately 2 months after the polyclinic control and ambulatory follow-up. The patient who received chemotherapy in the following period was interned again with the diagnosis of empyema and bronchopleural fistula at the end of the first postoperative year. Tube thoracostomy was performed, and antibiotherapy was started. Irrigation was performed with Clagett method. The tube was removed and the patient was discharged without any problems.

In the second postoperative year, the patient was admitted to the hospital with the complaint of fluid coming from the mouth for one month, and tube thoracostomy procedure was applied to the patient for the third time because of level decrease in the x-ray and fistula suspicion. Thorax CT was taken, and FOB was applied. An approximately 5-mm fistula mouth was observed at the lateral end in the bronchial stump. The drainage of the patient was purulent, and irrigation was started. When the food eaten at the time of admission was observed coming in the chest tube, oral intake was stopped. Fiberoptic esophagoscopy was performed in the patient; a fistula was observed in the 34th cm, and a stent was placed in the esophagus.

Keywords: Bronchopleural fistula, tracheoesophageal fistula, empyema

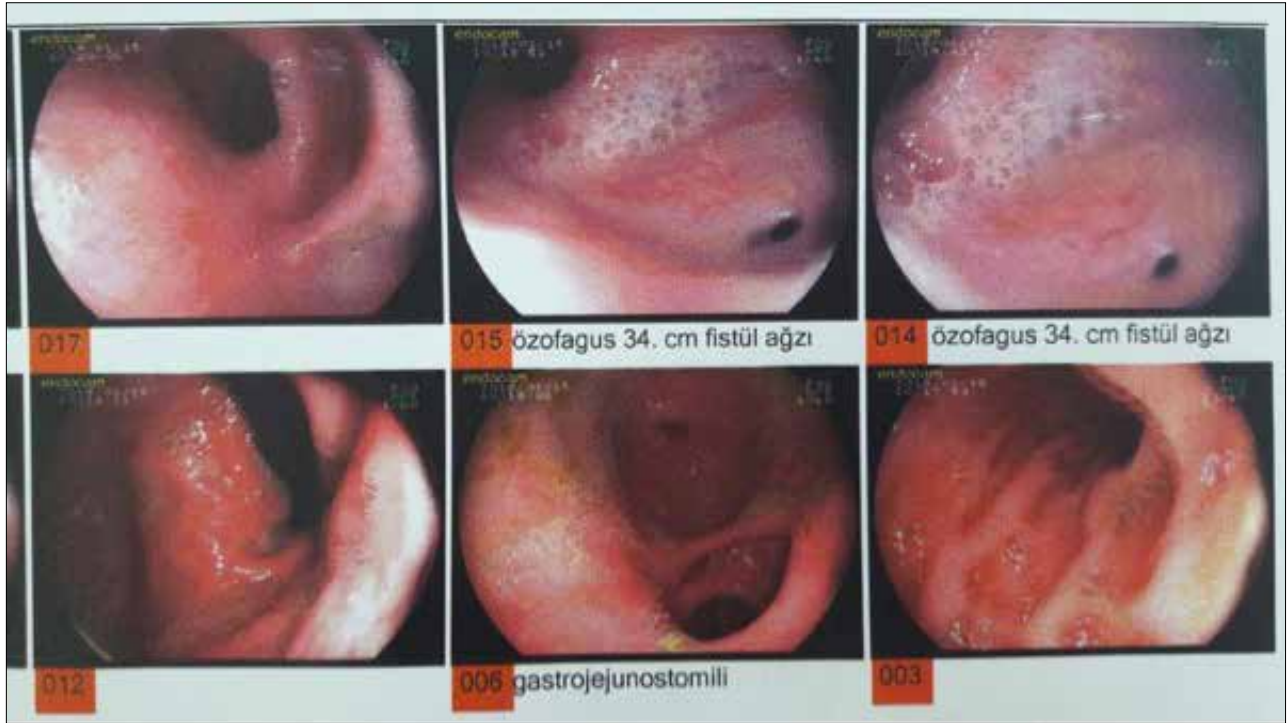

Figure 1. Esophagoscopy

[Abstract:0835] PS-001 [Accepted:Poster Presentation] [Clinical Problems - Diffuse Parenchymal Lung Disease]

False-positive PET-CT Scan Secondary to Interstitial Pneumonitis Mimicking Malignancy in Fire Eater's Lung

Ayşe Baççioğlu, Dilek Eraslan, Şule Halıcı, Ayşe Füsün Kalpaklıoğlu

Department of Pulmonary and Allergic Diseases, Kirikkale University, Kirikkale, Turkey

Fire eater's lung (FEL) is an interstitial pneumonitis, which is caused by accidental inhalation of flammable derivatives. These oily hydrocarbons rapidly diffuse throughout the bronchial mucosa and alveoli leading to inflammation. Herein, a case presenting as lung mass but compliant with interstitial pneumonitis in lung biopsy is reported.

A 70-year-old-male patient was admitted with progressive dyspnoea, mild fever, haemoptysis, cough, and sputum for 6 weeks. Physical examination revealed fine crackles on the right side of thorax, and O₂ sat: 94%. He was an active smoker for 25packet/years, and had coronary artery disease. He had performed fire-eating show 6 weeks ago which he had been doing rarely in his younger days. Chest x-ray showed irregular opacity localized on the right lower zone adjacent to infrahilar and pericardial area. Thorax computed tomography (CT) reported mass lesion (12x11x4mm) with a malign appearance located in the medial and right lower lobe, surrounded the middle lobe bronchus and pulmonary vein, invades to the hilar area, and diaphragm. There were also multiple nodules (<25mm) in the right lower lobe, and a linear density as a fibrotic sequela in the lingual segment. A treatment with antibiotic (moxifloxacin) was given against pneumonia since he had leucocytosis (12,910/ml), elevated procalsitonin (0.071ng/ml) and sedimentation (111/hr). Bronchodilators were started for dyspnoea. After antibio-therapy positron emission tomography (PET) -CT was performed and resulted as right paratracheal 11x13mm (maximum standardized uptake value -SUVmax-: 2.9) and hilar (19x22mm, SUVmax: 5), lymphadenopathy, and mass in the medial lobe and right lower lobe with satellite nodules and ground glass opacity (53x77x49mm, SUVmax: 8.7). Diagnostic bronchoscopy revealed erythema and narrowing of the entrance of medial lobe. Bronchial lavage (BL) was negative for any pathogens. Cytological study of BL fluid was negative for malignancy. Bronchial mucosa biopsy was reported as chronic inflammation. Transthoracic needle lung biopsy was performed since the mass's SUVmax was higher than 2.5, and was consistent with "interstitial pneumonitis". Corticosteroid treatment was started as 1mg/kg/day-methylprednisolone-, and gradually tapered in 3 months. Finally, his symptoms, and physical findings were improved, as well as radiologic abnormalities.

Even though the patient was a fire eater, the diagnosis of interstitial pneumonitis was delayed since there was a mass with malign appearance with high SUVmax in PET-CT, and no demonstration of lipid laden macrophages in BL. This case illustrates the importance of considering interstitial pneumonitis in fire eaters even some findings are inconspicuous.

Keywords: fire eater's lung, interstitial pneumonitis, malignancy

[Abstract:0837] PS-288 [Accepted:Poster Presentation] [Respiratory Failure and Intensive Care]

Expectation for HIV Patients with Intensive Care with Respiratory Failure: Case Series of 16 HIV Patients

Eylem Tunçay, Özlem Yazıcıoğlu Moçin, Emine Aksoy, Sinem Güngör, İlim Irmak, Nezihe Çiftaslan, Cüneyt Saltürk, Feyza Kargın, Gökay Güngör, Zühal Karakurt

Health Sciences University, Süreyyapaşa Chest Diseases and Thoracic Surgery Training and Research Hospital, İstanbul, Turkey

Introduction: Despite the development of antiretroviral drugs in the last decade, acute respiratory failure (ARF) and admission to the intensive care unit (ICU) due to the "Human Immunodeficiency Virus" (HIV) and pneumonia are observed in HIV infected patients. The aim of the study was to investigate the causes of ARF, ICU follow-up and mortality in 16 HIV infected patients admitted to ICU.

Method: The retrospective case series study was conducted at the Level 3 ICU, which provided an education in 2008-2016. The demographic characteristics, ARF causes (pneumonia, pneumothorax), ICU severity scores, mechanical ventilation usage, arterial blood gas values (ABG), complete blood count and biochemistry values, radiological findings, microbiological data on antiretroviral therapy, days of ICU stay and ICU, hospital and long term mortality were recorded.

Results: HIV positive sixteen patients (13, male) were included in the study. The age and BMI of the patients were 42 (38-48) years and 21 (18-24) kg /m² as median (25-75%), respectively. Antiretroviral therapy was also given to the 13 (81%) patients in the ICU who were diagnosed as HIV. Most frequent reason for admission to ICU was pneumonia (15/16), only one patient admitted to the ICU for pulmonary tuberculosis. Bilateral interstitial infiltrates on chest x-ray were detected in 14/16 patients. Spontaneous pneumothorax developed in 5/16 patients during the ICU stay and thoracostomy was performed. 2/16 of the patients had high flow oxygen, 9/16 had noninvasive mechanical ventilation, 4/16 had invasive mechanical ventilation. Infection agents were *P. jirovecii* (6/16), and cytomegalovirus (CMV, 7/16). 12/16 of the cases were given anti-fungal therapy, 7/16 of the cases used specific antiviral treatment according to microbiological culture results. Median intensive care hospitalization day was 8 (2-21). The cumulative mortality rates in intensive care, hospital and long term follow-up were 25% (N=4), 31% (N=5) and 55% (N=9), respectively. The median follow-up time was 142 (90-525) days after discharge.

Conclusion: Based on the study data, it can be concluded that in HIV patients, more effective diagnosis of acute respiratory insufficiency with the use of advanced diagnostic methods and antiretroviral therapy could lead to more favorable results in the future with the shortened days of intensive care stay and expected low mortality values.

Keywords: HIV, intensive care unit, mortality

[Abstract:0839] EPS-021 [Accepted: E-Poster] [Clinical Problems - Diffuse Parenchymal Lung Disease]

Antisynthetase Syndrome Presented with Lung Involvement

Umut Dilegelen¹, Çağıl Önal Sis², İlyas Ercan Okatan³, Aydın Çiledağ¹, Gökhan Çel,ik¹

¹Department of Chest Diseases, Ankara University School of Medicine, Ankara, Turkey

²Department of Internal Diseases, Ankara University School of Medicine, Ankara, Turkey

³Department of Rheumatology, Ankara University School of Medicine, Ankara, Turkey

Antisynthetase syndrome is a disease characterized with myositis, Raynaud's phenomenology, fever, interstitial lung disease, mechanical hand and arthropathy and associated with antibody presence against tRNA synthetase and anti-JO-1.

A 41-year-old male patient with no additional disease other than hypertension was examined in terms of pneumonia and tuberculosis at an external center due to dyspnea on exertion which started 1.5 months ago, cough, myalgia and arthralgia. He was treated due to pneumonia but dyspnea continued. PaO₂ was found as 53 mm Hg and sO₂ as 89% when he consulted to our clinic. Postero-anterior chest x-ray showed infiltration in both lower zones. There were moderate restriction in the respiratory function test and a severe reduction in the carbonmonoxide diffusion capacity. Chest CT taken in the external center was reported as compatible with organizing pneumonia. The patient underwent bronchoscopy and bronchoalveolar lavage was removed. No pathology was detected in cytologic and microbiological examination, and flow cytometry revealed a decrease in lymphocytic alveolitis and CD4 / CD8 ratio. Anti-JO1 and RO-52 were found to be positive in the patient with positive antinuclear antibody, creatine kinase (CK) 13256 and elevated liver enzymes. The patient who was evaluated by Rheumatology and Neurology was accepted to have antisynthetase syndrome with EMG and muscle biopsy results. A decrease in CK and liver enzyme values was observed in the patient in whom 1 g/day methylprednisolone was started and who received pulse steroid for 3 days. Thereafter, the therapy was continued with 80mg / day methylprednisolone, tacrolimus and cyclophosphamide. Significant clinical, laboratory and radiological improvement was observed with the treatment.

As a result, the diagnosis of antisynthetase syndrome manifesting with pulmonary involvement and the cause of its rare incidence have been presented.

Keywords: Antisynthetase syndrome, Anti Jo 1, Ro 52

[Abstract:0840] EPS-196 [Accepted: E-Poster] [Thoracic Surgery]

Evaluation of Talc Pleurodesis with Pleural Drainage Catheter in Malignant Pleural Effusion

Selçuk Gürz, Burçin Çelik, Yasemin Bilgin Büyükkarabacak, Ayşen Taslak Şengül, Sezer Aslan, Merve Karabacak, Ahmet Başoğlu

Department of Thoracic Surgery, Ondokuz Mayıs University School of Medicine, Samsun, Turkey

Objectives: Malignant pleural effusion (MPE) is caused by the pleural metastases of lung and extrapulmonary malignancies. MPEs are generally drained by tube thoracostomy, catheter thoracostomy, video-thoracoscopy, and by performing a pleurodesis. Pleural drainage catheters, while being less invasive compared to tube thoracostomy, are not preferred in talc pleurodesis since they are easily clogged. In this study, we aimed to evaluate MPE patients who were administered pleurodesis and pleural drainage catheterization.

Methods: The success of pleurodesis in 40 patients who were inserted pleural drainage catheter (Pleurocan, B. Braun, Melsungen, Germany) and were administered talc pleurodesis for MPE in our clinic was evaluated retrospectively. Two-sided chest radiography was used to evaluate success. In the radiography, the procedure was regarded as fully successful if, on the side which received pleurodesis, the costodiaphragmatic sinus was open, while it was regarded as partially successful if the costodiaphragmatic sinus was closed, without a need for pleural drainage; and not successful if there is a need for pleural drainage due to recurring MPE. Patients with a survival time of less than 1 month were excluded from the study.

Results: Of the patients whose average age was 61.9±15.5, 24 were female and 16 were male. From the primary diagnosis perspective, 30% had lung cancer, 20% had breast cancer while 12.5% had lymphoma. In those patients who had a mean survival time of 7.43±7.6 months, the full success rate after pleurodesis was 50% and the partial success rate was 37.5%. Pleurodesis failed in only 5 patients.

Conclusion: Survival time is very short in MPE and a palliative intervention is required to alleviate and manage the symptoms. For palliative purposes, drainage of MPE and chemical pleurodesis are performed. Since pleural drainage catheters are small in diameter, they are less preferred in the chemical pleurodesis procedure compared to chest tubes. It was seen in our study that pleural drainage catheter, which is less invasive than tube thoracostomy, can safely be applied in chemical pleurodesis.

Keywords: Catheter, drainage, effusion, malignant, pleural, pleurodesis

[Abstract:0841] EPS-209 [Accepted: E-Poster] [Thoracic Surgery]

Parapneumonic Pleural Effusions From Exudative Phase to Decortication

Selçuk Gürz¹, Ayşen Taslak Şengül¹, Yasemin Bilgin Büyükkarabacak¹, Burçin Çelik¹, Mehmet Gökhan Pirzirenli², Volkan Yılmaz¹, Sezer Aslan¹, Caner İşevi¹, Ahmet Başoğlu¹

¹Department of Thoracic Surgery, Ondokuz Mayıs University School of Medicine, Samsun, Turkey

²Şanlıurfa Training and Research Hospital, Şanlıurfa, Turkey

Objectives: Parapneumonic pleural effusion is exudative or fibrinopurulent attributed pneumonia sourced liquid aggregation within pleural space. Conservative (antibiotics and drainage) as well as surgical (decortication) treatment methods are implemented. In this study, we aim to evaluate patients who were monitored and treated due to parapneumonic effusion.

Methods: In this retrospective study, 1346 pleural effusion patients, who are intervened by Ondokuz Mayıs University Medical Faculty Thoracic Surgery Clinic in recent 10 years (2007-2017), are analyzed. Surgical treatment implemented 221 patients diagnosed with parapneumonic pleural effusion are included in this study. Patients were grouped as exudative phase (Stage I), fibrinopurulent phase (Stage II), organized phase (Stage III). Statistical analysis is made based on age, gender, disease stage, diagnosis and treatment methods, comorbidity index scores and mortality rate of patients.

Results: 221 patients, whose average age is $57.05 \pm 17,8$, consisted of 63.8% (n=141) male and 36.2% (n=80) female. Biochemical and radiologic surveys show that 33.9% of patients were at Stage 1, 37.6% were at stage 2 and 28.5% were at stage 3. 20.9% of patients (33/158), at Stage 1 and 2, were conducted with thoracoscopic pleural biopsy for etiology. Tube thoracostomy was implemented for all patients at stage 2 and eksudatif phase. Surgical decorticaion was implemented to 77.8% (49/63) of patients at organization phase. It is identified that patients, who were implemented decortication, have mortality rate of 6.1%, while total mortality rate is 28.5%. Patient group with comorbidity index score is 4 or above shows increased mortality risk ($p < 0.05$).

Conclusion: In accordance with current guidelines and literature, parapneumonic pleural effusion treatment should be conducted taking into consideration of the stage of disease. Drainage in addition to appropriate antibiotics treatment should be implemented at stage 1 and 2 of disease. Pleural decortication at organization stage which causes reduction in respiratory functions, is a secure treatment method to improve health quality. Comorbidity factors must be evaluated absolutely at patients, who have pneumonia with high mortality rate and dekortikasyon planned at organization stage.

Keywords: Decortication, effusion, comorbidity, parapneumonic, pleural

[Abstract:0843] PS-262 [Accepted:Poster Presentation] [Diagnostic Methods]

A Case of Cystic Fibrosis Diagnosed During Adulthood

Hatice Selimoğlu Şen¹, Velat Şen², Müsemma Karabel²

¹Department of Chest Diseases, Dicle University School of Medicine, Diyarbakır, Turkey

²Division of Pediatric Chest Diseases, Department of Pediatrics, Dicle University School of Medicine, Diyarbakır, Turkey

Introduction: Cystic fibrosis (CF) is the most common inherited autosomal recessive disease in caucasian race. CF occurs in the result of the mutation in the Cystic Fibrosis Transmembrane Regulator (CFTR) gene located on the long arm of chromosome 7 encoding the CFTR protein, which is found in the epithelial cells of the airways, biliary system, intestines, vas deferens, sweat glands and pancreatic ducts.

Clinical findings are heterogeneous in CF because of multiple system involvement. Early diagnosis and subsequently, proper treatment reduce long-term morbidity. Although there are newborn screening programs in this concern, about 10% of the cases can still not be diagnosed. CF has a wide range of clinical findings and these findings show differences according to age groups. Pulmonary findings are the most common findings in all age groups, and this is followed by gastrointestinal findings. A CF case diagnosed at an adult age was presented with the aim of drawing attention to the fact that symptoms may begin at late ages.

Case Presentation: A thirty-three-year-old male patient consulted with the complaints of cough that periodically increased and decreased for the last 5 years, sputum and shortness of breath. He was using inhaler therapy due to the diagnosis of asthma. The patient was followed-up in an external center due to pancreatitis that recurred about 1 year ago. For the past year, there has been a history of sticky stool. The patient was married and the absence of vas deferens was detected in the patient due to the infertility problem. There was no significant pathology in routine laboratory examinations. In high-resolution thoracic computed tomography; centrilobular emphysema in both pulmonary apices, moderate bronchiectasis in both pulmonary perihilar regions, ground-glass appearance in the basal right lower lobe of the lung, patchy areas of consolidation in the anterior subpleural segments of both lung lobes and interlobular septal thickening were reported. Complete abdominal ultrasonography and CT were within normal limits. There was mild obstruction in the pulmonary function test. The first sweat test could not be evaluated because the patient did not sweat. A heterozygote c.2991G > C genetic change was detected in complete gene sequence analysis performed with the prediagnosis of cystic fibrosis. The patient was treated with cystic fibrosis and followed up.

Conclusion: Despite the fact that most cases are diagnosed in infancy or childhood, as the rates of diagnosis and awareness increase, cases that are diagnosed at adult ages are also reported. Cystic fibrosis should also be kept in mind in adult patients having bronchiectasis with recurrent respiratory symptoms and concomitant infertility.

Keywords: Cystic fibrosis, adult, bronchiectasis

[Abstract:0845] PS-144 [Accepted:Poster Presentation] [Clinic Problems - Others]

Is Preoperative Pulmonary Evaluation Necessary in Kidney Transplant Patients?

Fatih Gökhan Akbay¹, Nilay Orak Akbay², Süheyla Apaydın¹, Volkan Tuğcu³

¹Department of Nephrology, Bakırköy Dr Sadi Konuk Training and Research Hospital, İstanbul, Turkey

²Department of Chest Diseases, İstanbul University İstanbul Medical Faculty, İstanbul, Turkey

³Department of Urology, Bakırköy Dr Sadi Konuk Training and Research Hospital, İstanbul, Turkey

Objectives: Postoperative pulmonary complications prolong the length of hospital stay and increase morbidity and mortality. Patients with end-stage renal disease (ESRD) may be accompanied by various pulmonary diseases. The best known treatment for ESRD is kidney transplantation. In prevalent renal transplant guidelines, chest diseases consultation is not preoperatively recommended as a standard. Our aim in this study is to predict short and long term pulmonary complications that can develop after transplantation in patients evaluated with chest diseases consultation before transplantation.

Methods: Seventy-six patients who underwent renal transplantation in İstanbul Bakırköy Dr. Sadi Konuk Training and Research Hospital between the years of 2016 and 2017 were included in the study. Patients' gender, height, weight, dialysis history, dialysis duration, donor type, immunosuppressive treatment regimens, rejection history, smoking history, pulmonary disease and tuberculosis history, cardiovascular disease history, symptoms and examination records, chest radiography and pulmonary function tests were recorded. Low, moderate and high risks were recorded in chest diseases consultations of the patients. Recorded patient information was also assessed by a chest specialist from a different hospital and risk classification was made according to the pulmonary risk index. Pulmonary complications that developed in the patients during the postoperative one year were recorded. The relationship between postoperative complications and preoperative risks of the patients was statistically evaluated. Statistics were made with SPSS 22.0.

Results: Of the patients, 47 (61.8%) were male and 29 (38.2%) were female. The mean age was 40.8±13.4. Sixty-five (85.5%) of the transplantations were performed from living-donors. Three (4%) of the patients had a history of previous tuberculosis. Eleven patients (14.5%) had a history of lung diseases (4 with COPD, 2 with asthma, 2 with vasculitis, 1 with sarcoidosis, 1 with tuberculosis sequelae, 1 with lung nodule). According to NHYA functional classification, 68 (89.5%) patients were class 1, 7 (9.2%) patients were class 2, and 1 (1.3%) patients were class 3. The mean FEV₁ of the patients was 2.69±0.74 and the mean FEV₁% was 83.9±13.2. Twenty eight (36.8%) patients had a smoking history. The mean PPD of the patients was 8.6±6.6. All patients with a PPD value greater than 5 mm were given isoniazid prophylaxis for 9 months. Seventy (92%) of the patients had preoperative chest diseases consultation. Sixty six of the patients (94.2%) had low risk, 3 (4.2%) had moderate risk and 1 (1.4%) had high risk. When the risks were reevaluated in all patients, 71 (93.4%) of them had low risk, 4 (5.3%) had moderate and 1 (1.3%) had high risk. Six (7.8%) patients had a history of postoperative recurrent pneumonia, 2 (2.6%) had a history of pleural effusion, 1 (1.3%) had a history of hemoptysis, 1 (1.3%) had a history of pulmonary edema, and 1 (1.3%) had a history of hypoxemia. A statistically significant correlation was found between preoperative chest diseases consultation risk assessment and preoperative reevaluation (p: 0,0001 R: 0,65). There was no

statistically significant correlation between the development of postoperative complications and the risk assessment of both chest diseases in patients ($p: 0,43$, $p: 0,57$).

Conclusion: We conclude in our study that preoperative pulmonary evaluation may be insufficient to predict postoperative complication development in renal transplant patients. This may be because most of our patients are at low risk and transplantation is not performed in high risk patients, therefore they were not included in the study. In addition, the incidence of pneumonia may have decreased in moderate-risk patients since all patients received trimethoprim / sulfamethoxazole prophylaxis for eight months.

Keywords: Preoperative evaluation, kidney transplantation, consultation

[Abstract:0846] EPS-014 [Accepted: E-Poster] [Clinic Problems - Others]

Tracheal Bronchus: Two Cases

Ali Kadri Çırak, Melis Çaktu, Serpil Tekgöl

Health Sciences University, Suat Seren Chest Diseases and Surgery Training and Research Hospital, İzmir, Turkey

Tracheal bronchus (bronchus suis) is the separation of the right upper lobe bronchus from the trachea and is a rarely seen congenital anomaly. Although it is mostly asymptomatic; recurrent infections, persistent cough, and hemoptysis may occur.

Because of its rare incidence, we present two cases in whom we performed bronchoscopy with the prediagnosis of tuberculosis and lung cancer, and in whom we detected "tracheal bronchus".

Case 1: In the patient in whom we performed fiberoptic bronchoscopy when cavitory lesion and tracheal bronchus were found in the left upper lobe apicoposterior segment in the investigation of thorax computerized tomography and exertional dyspnea complaint; bronchial orifice was observed in the right lateral wall of the trachea about 1 cm before the main carina (Figure 1).

Case 2: FOB was performed in the patient diagnosed with COPD in PET-CT due to 40-mm mass lesion with malignancy suspicion in the right lower superior lobe and due to the presence of tracheal bronchus. A bronchial orifice was seen in 5 o'clock direction in the right lateral wall of the trachea about 1.5 cm before the main carina (Figure 2).

Keywords: Tracheal bronchus, anomaly, bronchoscopy, variation

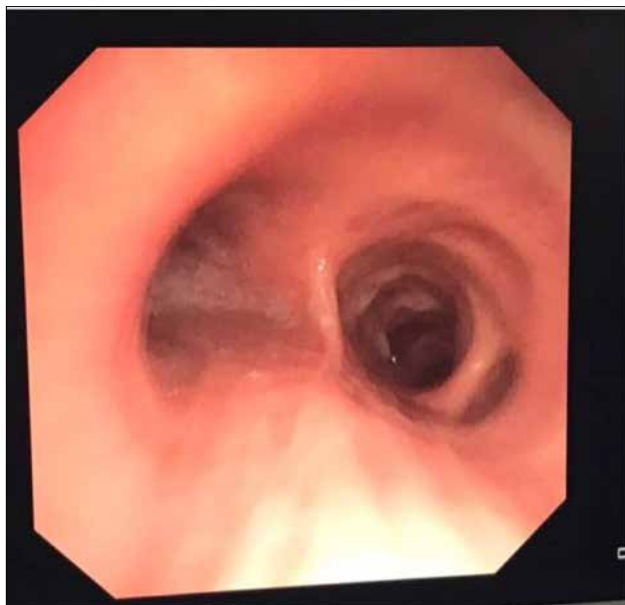

Figure 1. Tracheal bronchus in bronchoscopic examination

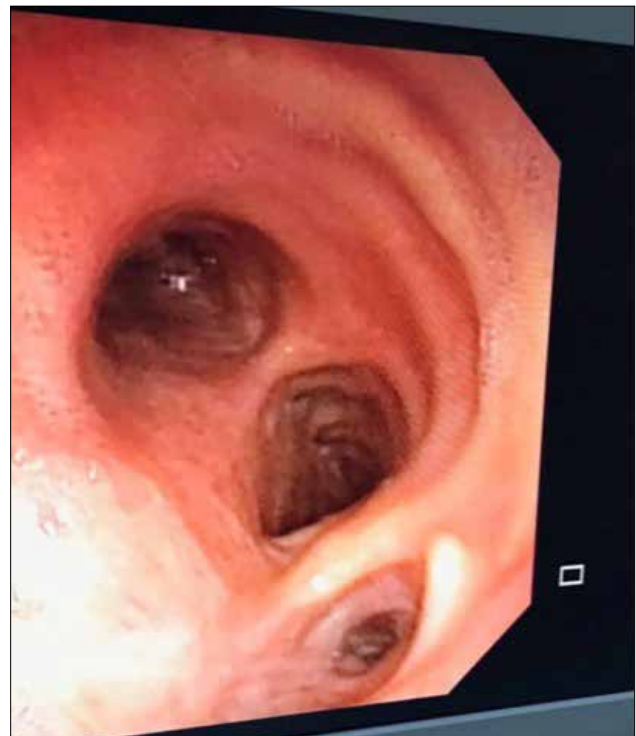

Figure 2. Tracheal bronchus in bronchoscopic examination case 2

[Abstract:0847] PS-036 [Accepted:Poster Presentation] [Clinic Problems - Others]

A Case with Alveolar Autoimmunity Associated with Autoimmune Polyglandular Syndrome Type 1

Nazan Bayram, Aybike Yurdadoğ, Ayten Filiz, Alper Şimşek, Dilan Zorlu

Department of Chest Diseases, Gaziantep University School of Medicine, Gaziantep, Turkey

Introduction: Autoimmune polyglandular syndromes are those in which two or more endocrine gland disorders are seen together or consecutively. Autoimmune polyglandular syndrome type 1 (APS-1) is a rare, monogenic and autosomal recessive picture. Hypoparathyroidism, Addison's disease and Candida infections involving skin/mucosae are the most common features. This syndrome is a disorder caused by mutations in the autoimmune regulator (AIRE) gene. Significant pulmonary disease has been observed in some APS-1 patients. Autoantibodies produced against the potassium channel regulatory protein (KCNKG) found in the epithelial cells of terminal bronchioles have been proposed as a marker for pulmonary disease in APS-1 patients. Here, we present a patient in whom alveolar autoimmunity developed associated with APS-1 and who had pulmonary involvement.

Case Presentation: A forty seven-year-old male patient was admitted to our outpatient clinic with the complaint of dyspnea on exertion that continued intermittently for two years and increased over the last 20 days. It is found out in his history that he used levothyroxine sodium and prednisolone 5 mg 1x1 due to Hashimoto and Addison diagnoses. In his physical examination SaO₂ was 86 (respiratory air), respiratory rate was 18/min, blood pressure was 130/80 mmHg, pulse was 95/min and fever was 36,7 °C. There were velcro rales in the bilateral middle-lower basals in auscultation, and there was no finger clubbing. Other system examinations were natural. In chest x-ray, there were reticulonodular opacities in bilateral mid-lower zones, more prominent on the right. In the HRCT, there were apparent subpleural reticulonodular opacities, interlobular septal thickening, peribronchovascular wall thickenings, bronchiectatic changes, infiltration, ground-glass appearance and marked honeycomb appearance bilaterally in the middle and lower lobes of the lungs. Respiratory function tests showed restrictive type of respiratory failure. Since the patient had a history of Addison and Hashimoto thyroiditis, the autoimmune polyglandular syndrome was considered and he was consulted to the department of endocrinology. The patient was considered to have autoimmune polyglandular syndrome type-1 by the endocrinology department. Since rheumatological examinations were negative and there was no organic or inorganic dust exposure; considering the differential diagnoses, it was determined that there were cases of alveolar autoimmunity accompanied by APS-1 in the literature. Methylprednisolone at 1 mg/kg/day was started in the patient. When an improvement was observed in the clinic and radiology, and oxygen saturation increased to 92%, the patient was discharged. Approximately 10 days later, the complaints of the patient who came to the polyclinic for control decreased and improvement was observed in PA X-ray. The treatment was continued by reducing methylprednisolone to 0.3 mg/kg/day, and polyclinic control was planned for 1 month later.

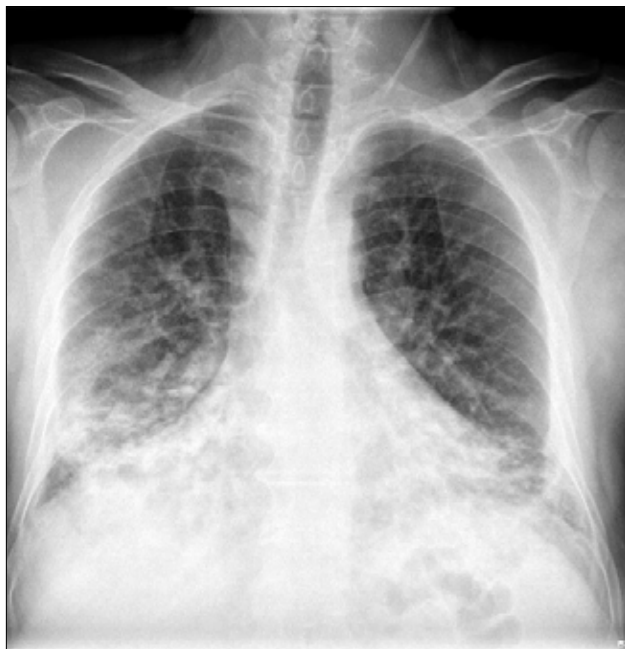

Figure 1. Case paag
Reticulonodular opacities in the bilateral middle-lower zones, apparently in the right side

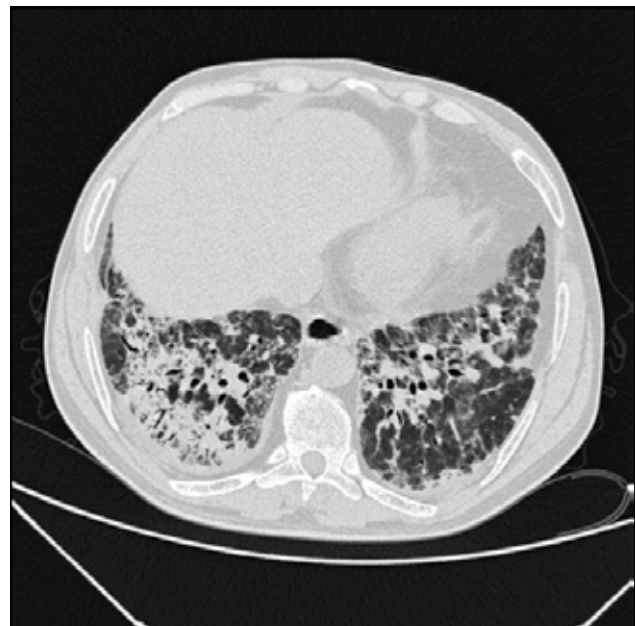


Figure 2. Case, thoracic CT section

Apparent subpleural reticulonodular opacities in bilateral middle and lower zones, interlobular septal thickenings, peribronchovascular wall thickenings, bronchiectasis changes, infiltration-ground glass densities

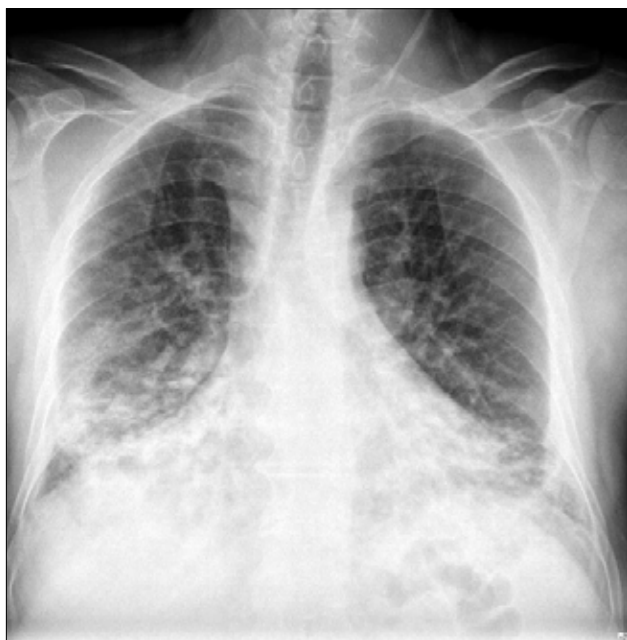

Figure 3. Case, control pa CR
Regression in the control radiography after treatment

Discussion: Patients with APS-1 are associated with multiorgan-associated autoimmunity with autoantibodies developing against autoantigens specific to target tissue. Although pulmonary symptoms are sporadically observed in these patients, an autoimmune mechanism for pulmonary involvement has not yet been elucidated. We defined an APS-1 patient in whom we considered autoimmune pulmonary disease, and we preferably predict potassium channel regulatory protein (KCNRG), which is expressed in the epithelial cells of the terminal bronchioles, as a target antigen. Mono or combination treatments such as prednisolone, mycophenolate mofetil, azathiopurine and IVIG were given in the cases described in the literature.

Conclusion: Autoimmune diseases are encountered at an incidence of 5-10% in the population. It has been shown that mutations in the AIRE gene are responsible for the APS syndrome and autoantibodies produced against KCNRG in some patients may be associated with pulmonary involvement. The number of studies carried out in this regard is extremely small.

Keywords: Interstitial, lung disease, autoimmune, polyglandular, syndrome

[Abstract:0852] EPS-237 [Accepted: E-Poster] [Thoracic Surgery]

Cooccurrence of Zenker's Diverticulum and Bronchial Carcinoma: A Rare Case

Kenan Can Ceylan¹, Arkın Acar¹, Yunus Türk¹, Şeyda Örs Kaya¹, İpek Ünsal², Ali Galip Yener³

¹Department of Thoracic Surgery, Health Sciences University, Dr Suat Seren Chest Diseases and Surgery Medical Practice and Research Center, İzmir, Turkey

²Department of Chest Diseases, Health Sciences University, Dr Suat Seren Chest Diseases and Surgery Medical Practice and Research Center, İzmir, Turkey

³Department of Pathology, Health Sciences University, Dr Suat Seren Chest Diseases and Surgery Medical Practice and Research Center, İzmir, Turkey

Introduction: Zenker's diverticulum is a pulsion type pharyngoesophageal diverticulum which is herniated from the weak area known as the Killian Triangle, which is between the oblique fibers of inferior constrictor pharyngeal muscle located in the posterior pharyngeal wall of pharyngeal mucosa and transverse fibers of cricopharyngeal muscle. The most common symptom is swallowing difficulty. There is no case reported which shows the concurrence of Zenker's diverticulum and bronchial carcinoma in the literature. A case which have both Zenker's diverticulum and left bronchial carcinoma is presented due to its rare occurrence.

Case Presentation: A mass in the left lung and Zenker's diverticulum were detected in a 65-year-old male patient who admitted to our hospital with coughing. Due to the preliminary diagnosis of bronchial carcinoma, the patient was first undergone left upper lobectomy via videothoracoscopy. Pathological staging of the patient who was diagnosed with squamous cell carcinoma was evaluated as T1bN0M0 - Stage 1A. The operation for the Zenker's diverticulum was planned and diverticullectomy + myotomy was performed with the cervical approach.

Conclusion: Zenker's diverticulum should be suspected in patients which are being evaluated for any reason medically with the symptoms such as difficulty in swallowing, restlessness of undigested foods, choking sounds in the throat, chronic cough and/or aspiration of food particles, weight loss and halitosis. Early stage bronchial carcinoma and Zenker's diverticulum can be fully cured by surgical treatment.

Keywords: Bronchial carcinoma, zenker's diverticulum, surgery

[Abstract:0857] EPS-278 [Accepted: E-Poster] [Thoracic Surgery]

Analysis of Patients with Multiple Trauma: 161 Cases

Funda Öz, Ali Birak, Serdar Onat, Fatih Meteroğlu, Menduh Oruç, Refik Ülkü

Department of Chest Surgery, Dicle University School of Medicine, Diyarbakır, Turkey

We aimed to analyze a total of 161 patients who were admitted to DUMF Emergency Department due to multiple traumas between the years of 2016 and 2017 and who had additional thoracic pathologies accompanying thoracic injuries.

Of the 161 patients, 137 came due to an exposure to blunt thoracic trauma and 24 as a result of an exposure to penetrating thoracic trauma. Tube thoracostomy was performed in 68 patients and 15 patients underwent surgery due to bleeding control and diaphragm injury.

The most common pathology accompanying thorax trauma was vertebral fracture (n: 48% 29.8). Among the accompanying extremity fractures, the most frequent was femur fracture (N: 17 10.5%) and the least common was metatarsal fracture (N: 5 3.1%). Intracranial pathology was detected in 28 patients. Intra-abdominal solid organ injury was observed in 56 patients.

The rate of mortality was found to be 8.6% with 14 patients in this series associated with extrathoracic pathologies. Almost all who died were the patients who were exposed to trauma due to blunt injuries. Morbidity was found to be 13% and the most frequent cause of morbidity was prolonged air leak.

The vast majority of organ injuries associated with thoracic trauma are treated with tube thoracostomy. A multidisciplinary approach is essential for the patients with multi-trauma due to thoracic trauma.

Keywords: Multitrauma, thorax, mortality

[Abstract:0860] EPS-084 [Accepted: E-Poster] [Lung and Pleura Malignancies]

Adverse Effects in Patients Receiving Stereotactic Body Radiotherapy for Lungs

Nilüfer Aykaç¹, Gül Alço¹, Osman Elbek², Tülay Ercan¹, Metin Barlan¹, Şefik İğdem¹

¹Gayrettepe Florence Nightingale Hospital, İstanbul, Turkey

²Kadıköy Florence Nightingale Hospital, İstanbul, Turkey

Objectives: In recent years importance of stereotactic body radiotherapy (SBRT) for primary and metastatic lung cancer is increased parallel to the technological developments.

We evaluated ratio of adverse effects requiring treatment in patients receiving SBR for lungs in this study.

Methods: Patients in whom SBRT was applied due to primary and metastatic lesions in the recent two years in our Radiation Oncology Department were retrospectively reviewed.

SBRT was employed with Truebeam STx Radiotherapy System by using 2-3 partial arc with 10 MV FFF photons.

Patients with stage II and over needing treatment were reported.

Results: SBR was employed to 44 different lesions to 38 patients. Of these patients, 29 was male, median age was 73 years (38-90). Patients received a median dose of 50 (24-60) Gy in median of 5 (1-8) fractions. Median BED 10 value was 105 (81.6-151) Gy and BED 3 was 217 (210-378) Gy. Only one patient was hospitalized after 3rd month of treatment due to grade 3 radiation pneumonia and in 2 patient grade 2 esophagitis was seen.

Conclusion: We found a very low ratio of adverse effects in our patients receiving SBRT for lungs which points out that it may be a safe choice of treatment.

Keywords: Malignancy, lung, radiotherapy, adverse effect

[Abstract:0861] PS-186 [Accepted:Poster Presentation] [Pediatric Pulmonary Diseases]

Comparison of Depression, Burnout, Caregiver Burden and Parent-Child Attitudes in Cystic Fibrosis and Primary Ciliary Dyskinesia Children's Mothers

Tuğba Şismanlar Eyüboğlu¹, Tuğba Ramaslı Gürsoy², Ayşe Tana Aslan², Nagehan Emiralioğlu³, Sevgi Pekcan⁴, Zeynep Büyükkaya⁴, Melih Hangül⁵, Mehmet Köse⁵, Şebnem Soysal⁶, Işıl İrem Budakoğlu⁷

¹Department of Pediatric Pulmonology, Dr Sami Ulus Maternity and Children Training and Research Hospital, Ankara, Turkey

²Department of Pediatric Pulmonology, Gazi University School of Medicine, Ankara, Turkey

³Department of Pediatric Pulmonology, Gaziantep Cengiz Gökçek Maternity and Children Hospital, Gaziantep, Turkey

⁴Department of Pediatric Pulmonology, Necmettin Erbakan University School of Medicine, Konya, Turkey

⁵Department of Pediatric Pulmonology, Erciyes University School of Medicine, Kayseri, Turkey

⁶Department of Pediatrics, Gazi University School of Medicine, Ankara, Turkey

⁷Department of Medical Education, Gazi University School of Medicine, Ankara, Turkey

Objectives: Both Cystic Fibrosis (CF) and Primary Ciliary Dyskinesia (PCD) are chronic lung diseases with acute exacerbations which require lifelong therapy. Children with chronic illnesses can lead psychological problems in caregivers and affect quality of life of families and care of children may be affected.

We aimed to investigate to compare CF and PCD patients' caregivers depression, burnout, caregiver attitude and caregiver burden. And all these parameters compared with patients' clinical status.

Methods: Primary caregivers of the CF and PCD patients were asked to complete a personal information form which includes social and educational status of the family. Beck Depression Scale, Maslach Burnout Scale, Zarit Caregiver Burden Scale and PARI Scale were applied in both groups. For comparing clinical status of the patients Schwahman Kulchisky clinical score was used. And results were compared between two groups.

Results: In CF group 122 and in PCD group 20 patients and primary caregivers were involved to the study. All primary caregivers were mothers in both groups. Mean age of CF patients was 8.01 and PCD patients was 11.6 ($p<0.05$). Hospitalization in last 6 months, total number and duration of hospitalization and frequency of acute exacerbation in the last year were higher in CF patients ($p<0.005$). Clinical scores of PCD patients were higher than CF patients. Depression, burnout and caregiver burden scores were higher in CF patients' mothers. Frequent hospital visits were related with depression, burnout, caregiver burden and overprotective attitude in CF patients' mothers ($p<0.05$).

Conclusion: Although both CF and PCD were chronic lung diseases, burnout and caregivers' burden were higher in CF patients' mothers. Frequent hospital visits, long and frequent hospitalization, and lower clinical scores affect psychological states of CF patients' mothers and overprotective attitudes of mothers affect care of the children.

Keywords: Cystic fibrosis, primary ciliary dyskinesia, caregiver burden, depression, burnout, parent-child attitude

[Abstract:0862] EPS-286 [Accepted: E-Poster] [Thoracic Surgery]

An Alternative Method for the Closure of Bronchopleural Fistula: Stent Application

Kenan Can Ceylan, Yunus Türk, Onur Fevzi Erer, Şeyda Örs Kaya

Dr. Suat Seren Chest Diseases and Chest Surgery Education and Research Hospital, Department of Chest Surgery, İzmir, Turkey

Introduction: Bronchopleural fistulas (BPF) are usually seen as postoperative complications, and treatment is a complicated, difficult and problematic issue. Although surgical treatment is preferential, less invasive procedures should be considered when surgery is not possible. BPF reduces the quality of life of the patient, prolongs hospitalization, and increases the risk of mortality. In the light of the literature, we aimed to present our patients in whom tracheobronchial silicone stent was applied for the treatment of BPF.

Case Presentation: Tube thoracostomy was applied with the diagnosis of empyema on the right in a 56-year-old male patient who underwent chemoradiotherapy due to inoperable NSCLC and was under oncology follow-up. Plenty of air leakage from the drain, abscess in right upper lobe and BPF fistula in right upper lobe entrance in bronchoscopic examination were detected in the patient whose general condition was seen to have worsened in the clinical follow-up. Silicone Y-stent was placed in the patient to close BPF with rigid bronchoscopy. After the stent was placed, it was seen that the air leak from the drain bottle ceased. The general condition of the patient has improved in the clinical follow-up, and he is still being followed up. The other case was a 67-year-old male patient who underwent left pneumonectomy operation due to NSCLC a year ago, and in whom subsequent brain metastasis developed, as well. Tube thoracostomy was performed in the patient with the diagnosis of empyema. It was seen through bronchoscopy that there was opening in the left pneumonectomy stump. Silicone stent was applied to close the BPF with rigid bronchoscopy in the patient who was clinically unfit for surgery. It was seen that the air leak ceased in the drain bottle of the patient and his general condition improved after the procedure.

Conclusion: Sudden onset of cough, sputum and respiratory failure are the symptoms of bronchopleural fistula. The majority of bronchopleural fistulas are associated with empyema. The presence of the empyema reduces the success rate of fistula closure. Surgical procedures performed directly for the fistula are more frequent in BPF treatment. We preferred to apply silicone stent to our patients who were unfit for surgery. In doing this, we aimed the air to pass directly to the lungs by bypassing the fistula and to cut off the connection of the infected empyema contents with the bronchial structures. Its greatest advantage is that it is less invasive compared to other methods, and cuts the air leak perfectly. In conclusion, stent application is an alternative method of BPF closure in patients for whom surgery is not considered and it has provided a good palliation.

Keywords: Bronchopleural fistula, stent, rigid bronchoscopy

[Abstract:0864] SS-087 [Accepted:Oral Presentation] [Pediatric Pulmonary Diseases]

Impacts of Long Term Azithromycin Use on the Audiological Functions of the Pediatric Population

Ayşe Ayzıt Atabek¹, Remzi Doğan², Özge Gedik³, Lina Al Muhammed Shadfan⁴, Meliha Başöz², Hakan Yazan⁴, Erkan Çakır⁴, Orhan Özturan²

¹Department of Pediatric Pulmonology, İstanbul University Cerrahpaşa School of Medicine, İstanbul, Turkey

²Department of Otorhinolaryngology, Bezmialem Vakıf University School of Medicine, İstanbul, Turkey

³Division of Audiology, Bezmialem Vakıf University School of Medicine, İstanbul, Turkey

⁴Division of Pediatric Pulmonology, Bezmialem Vakıf University School of Medicine, İstanbul, Turkey

Objectives: As a macrolide antibiotic, Azithromycin is being used for long periods especially in pediatric pulmonology. Although there is some knowledge about the impacts of azithromycin on the audiological function, long run impacts of use the medicine on the inner ear has not been clearly defined yet. In our study, post-treatment audiological functions of the cases which received azithromycin for at least 6 months, have been evaluated.

Methods: The study was conducted on the 47 closely monitored patients of our clinic who received azithromycin for 6 months. Routine examinations of ENT were made. Through the autoscopic examination, pathologies which can lead to transmission type hear losses were treated or either excluded from the study. The study also included 30 healthy volunteers (with no audiological complaints) from the same age group. Standard and as well as high frequency audiometry tests were carried out with all subjects. Results were statistically (independent T-Test) compared.

Results: 15 patients diagnosed with transmission type hear losses were excluded from the study. The remaining 32 patients (Group 1) were then included in the study. 17 of these 32 patients were female. Average age was 11.3 ± 0.56 . Within the patients, 23 (71 %) were under treatment for bronchiectasis, while 9 (29%) were under treatment for Bronchiolitis obliterans. Of the 30 healthy volunteers (Group 2) 18 were female and 12 were male, the average age within the group being 9.31 ± 3.07 . There is no meaningful age difference between the groups ($p > 0.05$). When compared standard audiometry value averages (respectively 21.56 ± 5.71 , 19.38 ± 6.27) there is no meaningful difference either. However, high frequency (10000 Hz, 12500 Hz, 16000 Hz) values of Group 1 (46.92 ± 59) were significantly higher than Group 2 (23.81 ± 06), ($p < 0.05$).

Conclusion: With our study, impacts of long-term azithromycin use on the inner ear in pediatric population were evaluated by utilizing standard and high frequency audiometry test for the first time in medical literature. According to our findings, Azithromycin has no adverse effect on hearing of standard frequencies. However, we consider that, the newly documented "sensorineural hearing loss" should be further investigated along with additional audiological parameters.

[Abstract:0866] EPS-029 [Accepted: E-Poster] [Clinical Problems - Diffuse Parenchymal Lung Disease]

A Case of Familial Pulmonary Fibrosis

Hasan Hasanzade¹, Özlem Kumbasar¹, Erdal Yekeler²

¹Department of Chest Diseases, Ankara University School of Medicine, Ankara, Turkey

²Department of Chest Surgery, High Specialization Training and Research Hospital, Ankara, Turkey

Introduction: Idiopathic pulmonary fibrosis (IPF), in which two or more members of the same family are affected, accounts for approximately 2 - 20% of all IPF patients. Although familial IPF cases may primarily occur at young ages, it may histopathologically show differences among individuals of the same family.

Case Presentation: A 20-year-old male patient consulted with the complaint of shortness of breath and cough. Thoracic computed tomography (CT) was performed in the patient when reticular appearance suggesting fibrosis was seen in posterior-anterior (PA) chest X-ray, forced vital capacity (FVC) was 74% in pulmonary function tests (PFT), and carbon monoxide diffusion was 46%. Centrilobular and paraseptal emphysematous areas affecting the upper zones in both lungs and fibrotic changes accompanying emphysema, especially in the peripheral areas of the lower zones, were seen in CT. In these areas, reticulation and tracheal bronchiectasis were seen to develop depending on fibrosis. Amorphous cystic lesions with relatively thick walls were seen in the emphysematous areas, more in the upper and middle zones, and it was thought that these changes could be consistent with accompanying langerhans cell histiocytosis. In the patient with smoking history, the findings suggested emphysema, fibrosis, and langerhans cell histiocytosis. Immunological marker results were found negative in the patient who did not have a history of animal,

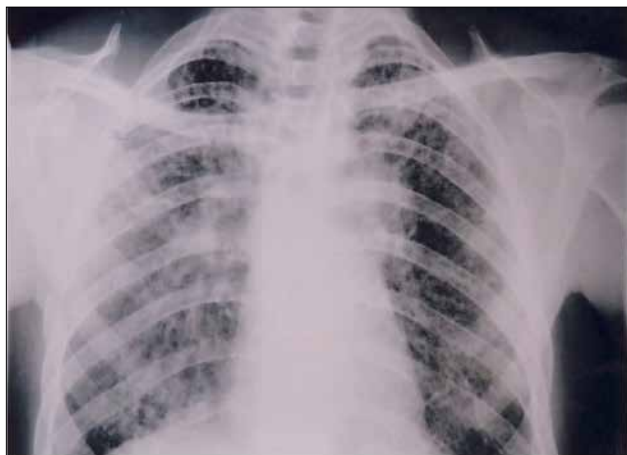


Figure 1. Findngs suggesting bilateral fibrosis

bird and occupational exposure. No rheumatologic disease was considered in the rheumatology consultation. The patient with a family history of pulmonary fibrosis in 7 cases was discharged with the recommendations that he should consult to genetic section for the examination of telomerase gene mutations and to our clinic again for performing fiberoptic bronchoscopy (FOB) and removing bronchoalveolar lavage (BAL).

Conclusion: Although genetic studies do not show a direct relationship (MUC5B, ATP11A, TOLLIP), the importance of telomerase maintenance (TERT, TERC) and epithelial (DSP) mutations in the development of IPF has been identified. In the follow-up of sporadic IPF cases, IPF is known to develop in consanguineous relatives after many years. For this reason, family history should be questioned in all IPF patients irrespective of age.

Keywords: Familial pulmonary fibrosis, combined pulmonary fibrosis and amphysema, IPF

[Abstract:0867] PS-128 [Accepted:Poster Presentation] [Clinical Problems - Pulmonary Vascular Diseases]

Granulomatosis Polyangiitis: A Case Report

Kübra Akyüz, Meltem Ağca, Reyhan Yıldız, Merve Örün, Soner Umut Küver, Tülin Sevim

Health Sciences University, Süreyyapaşa Chest Disease and Thoracic Surgery Research and Training Hospital, İstanbul, Turkey

Introduction: Granulomatosis polyangiitis (GP) is a necrotizing multisystem disease involving small and medium vessels. Pulmonary involvement is seen in 95% of patients. The kidney and upper respiratory tract are the other most commonly involved organs. Patients can admit to clinics with broad spectrum of symptoms; from flu like symptoms to alveolar hemorrhagy. We aim to present this case with pneumonia clinic.

Case Presentation: A 69-year-old man was admitted to our outpatient clinic with a complaint of cough and phlegm for about 2 months. There was no known systemic disease other than the gut. He was active smoker. Physical examination findings were normal. WBC: 15400, Hb: 8.6, urea: 53, creatine: 1.72, albumin: 2.6 and there was no pathology except for light sedimentation and elevation of CRP

The applicant had a non-homogeneous infiltration of irregular borders showing cavitation and covering the upper left zone near totally in the chest X-ray. When the patient's anamnesis was deepened. At thoracic CT that performed before the operation due to scleritis two months ago several parenchymal nodules with a size of 8.3 mm were seen in the left upper lobe apicoposterior segment. Control thoracic CT was performed; consolidation with air bronchogram around a wide cavitary lesion on the left upper lobe bordering major fissure. Three sputum ARB were negative. Proteinuria and hematuria were detected in the urine test. Paranasal sinus CT showed left frontal sinus hypoplasia and deviation in nasal septum. Rheumatological markers were examined and C-ANCA was found positive. Bronchoscopy revealed a vegetal mass that narrowing entrance of the anterior segment of the left upper lobe and it was seen that the upper lobe apicoposterior segment was opened in the cavity. Inflammatory cells were seen in the bronchial lavage cytology. The diagnosis of GP was made in the presence of this finding. Renal biopsy was performed because of the high level of creatinine, and the appearance of vasculitis was not observed as a result of cytology. Pulse steroid and cyclophosphamide treatment was started.

Conclusion: Cavitary pulmonary diseases are a group that should be evaluated multisystemically. Vasculitic diseases, particularly necrotizing granulomatosis polyangiitis should be remembered in the differential diagnosis.

Keywords: Cavitary, infiltration, granulomatosis polyangiitis, wegener

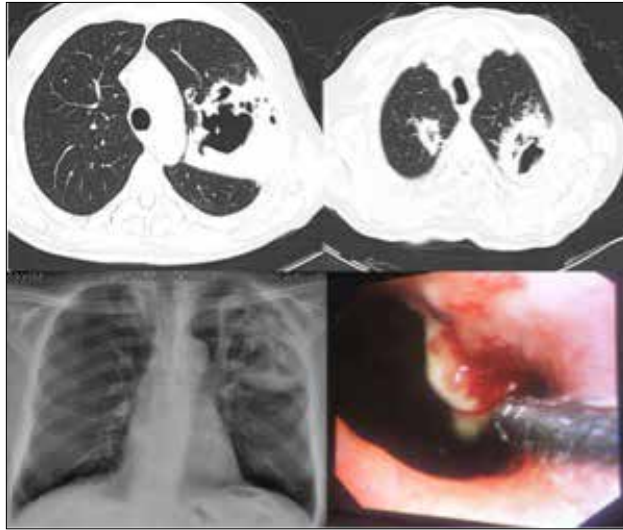


Figure 1. Thorax CT scans and chest X-ray showed cavitary lesion in the left upper lob. And appearance of lesion with bronchoscope

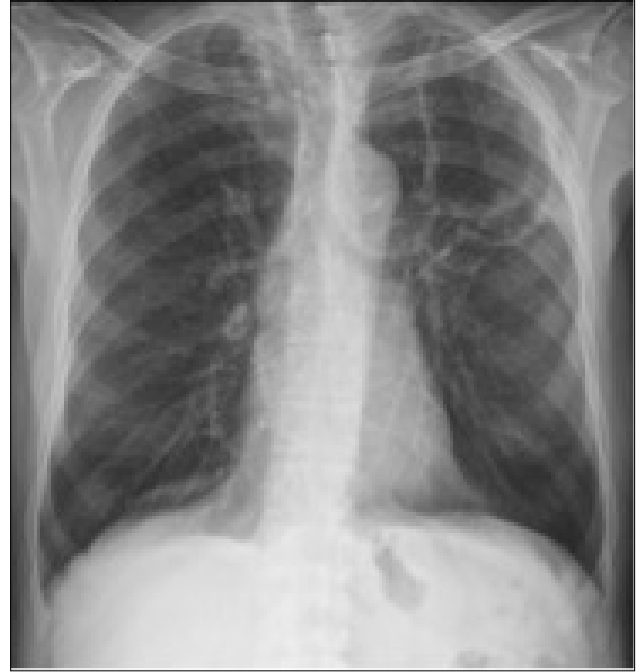

Figure 2. Control chest X-ray

[Abstract:0869] PS-319 [Accepted:Poster Presentation] [Lung Transplantation]

Pulmonary Transplantation and ECMO Experience in Kartal Koşuyolu High Specialization Training and Research Hospital Organ Transplant Center

Mustafa Vayvada¹, Sultan Sevkan Caner², Esin Erdem³, Emre Gürcü³, Atakan Erkilic³, Ali Yeğinsu¹, Ahmet Erdal Taşçı¹

¹Department of Thoracic Surgery, Kartal Koşuyolu High Specialization Training and Research Hospital, İstanbul, Turkey

²Department of Chest Diseases, Kartal Koşuyolu High Specialization Training and Research Hospital, İstanbul, Turkey

³Department of Anesthesiology and Reanimation, Kartal Koşuyolu High Specialization Training and Research Hospital, İstanbul, Turkey

Objective: Early period results of the patients who needed and did not need ECMO support during pulmonary transplantations performed at our center are presented.

Methods: We started to accept active patients starting as of December 2016. We have performed 30 pulmonary transplantations since then.

Results: The mean age of the patients was 44.5 (range 14 - 64 years). Of the patients, 26 were women, and four were men. Transplantation indications were interstitial lung disease and idiopathic pulmonary fibrosis in 11 patients, chronic obstructive pulmonary disease in 8 patients, bronchiectasis in 4 patients, cystic fibrosis in 2 patients, lepidic type adenocarcinoma in 2

Table 1. Features of Patients

	TOTAL N=30	NO ECMO N=13	ECMO N=17
Age	44.1 (14-62)	53.1 (39-62)	40.4 (14-60)
Gender F/M	4/26	1/12	3/14
BMI	23.5 (14-31.7)	25.4 (14.6-31.7)	22.5 (14-30.8)
Rest Oxygen Value (lt/h)	3.7 (2-10)	3.5 (2-4)	4.4 (2-10)
6MWT (below 150m)	21	8	13
FEV1	1.16 (0.44-2.48)	1.18 (0.68-2.11)	1.01 (0.44-2.48)
PA mean pressure	34.1 (16-95)	22 (16-42)	56 (21-95)
DIAGNOSIS			
IAH	5	2	3
IPF	7	5	2
COPD	7	3	4
Bronchiectasis	5	2	3
Cystic fibrosis	2	1	1
Cancer (lepidic adenoca)	2	-	2
Pleuroparenchymal fibroelastosis	1	-	1
Retransplantation	1	-	1

patients, retransplantation in one patient, sarcoidosis in one patient and pleuroparenchymal fibroelastosis in one patient. Single lung transplantation was performed in two patients, and bilateral lung transplantation was performed in 28 patients. ECMO support was needed in 17 patients (7 bridgings to lung transplantation, 10 perioperative ECMO uses). ECMO support was not needed in 13 patients. There was no mortality during the operations. Early period mortality was seen in 9 patients (30%). Twenty one patients were discharged and are followed up. While the mortality was 47% (8/17) in patients supported by ECMO, it was 7.6% (1/13) in patients not supported by ECMO. V-V ECMO was used in 7 patients for bridging to lung transplantation. Two of these patients died and the mortality was 28.5%.

Conclusion: Directing patients eligible for lung transplantation to transplantation clinics with appropriate timing will reduce the need for ECMO. Although lung transplantation is a safe and successful treatment modality in end-stage lung diseases, ECMO need of the patients is a situation that increases mortality.

Keywords: Lung transplantation, ECMO, mortality

[Abstract:0873] EPS-274 [Accepted: E-Poster] [Thoracic Surgery]

Approach to a Foreign Body Detected in Thorax Cavity Through VATS

Sevinç Çıtak, Onur Derdiyok, Serkan Bayram, Aysun Kosif, Selami Volkan Baysungur

Health Sciences University, Süreyyapaşa Hospital, Department of Chest Surgery, İstanbul, Turkey

Video assisted thoracic surgery (VATS) is a minimally invasive surgical technique that has become a standard therapy for many diseases of the lung and pleura. Along with the widespread use of the device and the increasing number of chest surgeons using it, the indications for its usage are also increasing. One of the rare indications for which VATS is used is the removal of intrathoracic foreign bodies.

A 31-year-old female patient consulted to the chest diseases department with the complaints of cough, sputum and weight loss. In the thorax computerized tomography taken when lung X-ray revealed opacity increase in the right upper lobe, it was observed that the right upper lobe had an appearance of a destructed lung and a nodule compatible with fungus ball was seen in the cavity in apex. No pathologic findings were detected in the fiberoptic bronchoscopy (FOB). After the Galactomannan test was negative, the examinations of the patient who was consulted to us were performed before the operation with the prediagnosis of Aspergilloma. Because the lung did not expand, on the 9th postoperative day, pezzet was placed through the apex in the patient who underwent upper lobectomy and right thoracotomy. Due to the fact that the air leak did not cease, the drainage in the apex could not be removed for 65 days. When the drain was removed, a cavitory space was observed in the drainage area. The drainage area was left to the secondary wound healing and the patient was discharged after recommending wound healing wrap. After the 3rd dressing performed at an external center, the patient consulted to our clinic because the wound healing wrap was dropped in the thorax. After preoperative evaluation, VATS was planned for the patient to remove the intrathoracic foreign body. The foreign body was removed entering through the existing wound site (Figure 1). Primer repair was performed in the wound site. The procedure was terminated by placing a chest tube through the healthy area. On the third day after the procedure, the drainage was terminated. The patient was discharged on the fifth day.

There are articles in the literature indicating that foreign bodies such as thoracocentesis cannula, spongioma and catheter have been removed with thoracoscopy. We think that the removal of foreign body with VATS in selected cases like this is a successful, minimally invasive and safe approach.

Keywords: VATS, foreign body, spongioma

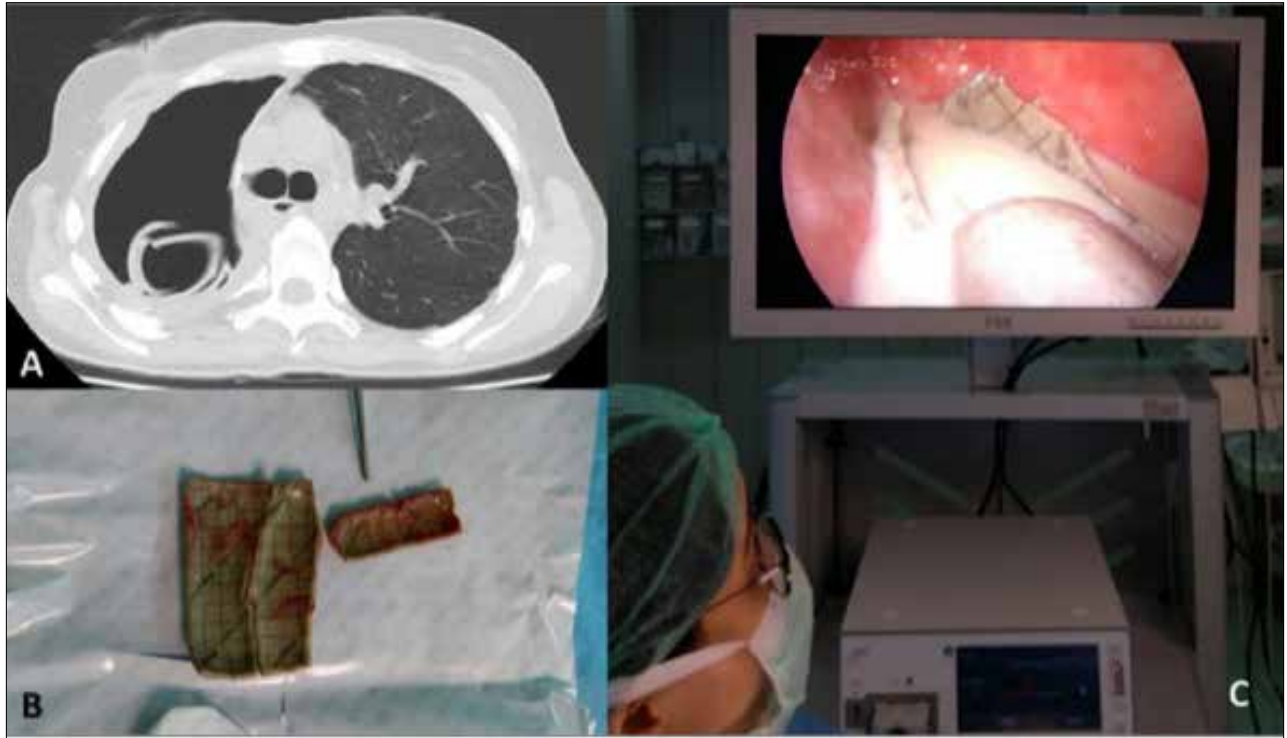


Figure 1. A- Foreign body in CT B-Removed foreign body C-perop surgery image

[Abstract:0875] EPS-200 [Accepted: E-Poster] [Thoracic Surgery]

A Rare Case: Thoracolithiasis

Selçuk Gürz, Yasemin Bilgin Büyükkarabacak, Volkan Yılmaz, Necmiye Gül Temel, Ahmet Başoğlu

Department of Thoracic Surgery, Ondokuz Mayıs University School of Medicine, Samsun, Turkey

Thoracolithiasis is present in the pleural space without any trauma, intervention, or pleurisy, with one or more moving pleural stones (calcified or without calcification). These have a reported incidence of less than 0.1% and are benign. Thoracolithiasis should be included in the differential diagnosis of single or multiple mobile peripheral pulmonary

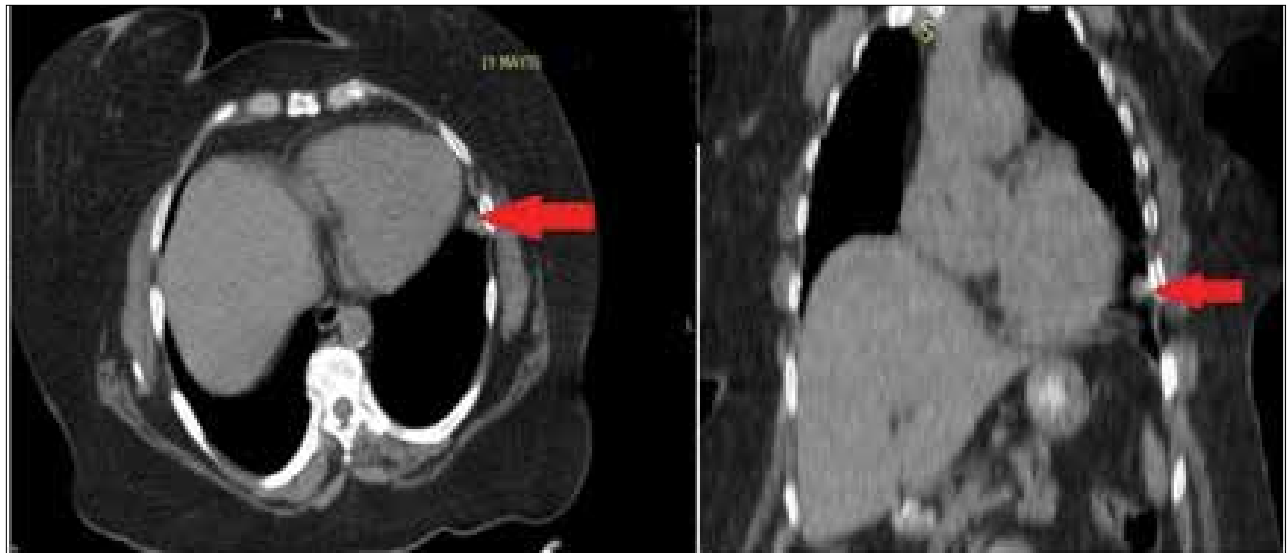


Figure 1. Thoracolithiasis CT scan

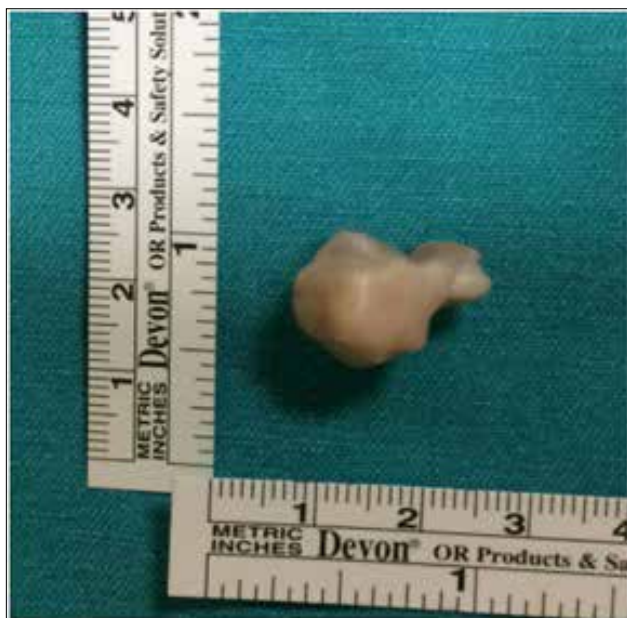

Figure 2. Thoracolithiasis

nodules. We reviewed the imaging and clinical features of a rare case with mobile thoracolithiasis. A 53-year-old woman with diabetes and hypothyroidism was admitted to us with complaints of recurrent oral bleeding and in computed tomography (CT) ; on lingular segment of the left lung in the paramediastinal and subpleural area to detect a well-defined nodular lesion containing approximately 8x10 mm calcification. In PET CT, FDG-negative soft tissue with microcalcifications in size 16x9 mm was observed in paracardiac fatty tissue adjacent to the anterobasal segment of the left lower lobe of the lung. Esophagoscopy was performed on the patient in terms of hematemesis; esophagus and stomach were naturally observed. Bronchoscopy was performed and no endobronchial formation and bleeding center were detected. Video assisted thoracic surgery (VATS) was performed and a free white 1x2 cm solid nodule in paracardiac fatty tissue was removed in the left pleural space. Pathology is compatible with thoracolithiasis; fibrous and calcified fibrotic nodule with areas that may be compatible with fat necrosis on the internal surface surrounded by calcified capsules. Thoracolithiasis is very difficult to diagnose preoperatively. If we know the radiological findings of this lesion well, we can continue with minimally invasive surgery like VATS for diagnostic

and therapeutic purposes. All thoracic surgeons and pulmonary medicine physicians should keep in mind the possibility of thoracolithiasis as a differential diagnosis of pulmonary calcified nodule.

Keywords: Benign, calcification, thoracolithiasis

[Abstract:0881] EPS-284 [Accepted: E-Poster] [Thoracic Surgery]

Rib Stabilization with Chest Orthosis; Its Effect on the Patient's Pain, Respiration, and Daily Life Activities

Gülay Oyur Çelik¹, Arife Yavaşer², Sinem Eskidemir¹

¹Department of Surgical Nursing, İzmir Katip Celebi University, Health Sciences Faculty, İzmir, Turkey

²Department of General Surgery, İzmir Katip Çelebi University Atatürk Training and Research Hospital, İzmir, Turkey

Chest orthosis is one of the conservative treatments that are administered in order to immobilise the fracture area.

In this sense, in this case, chest orthosis was applied in order to provide the patient's fracture area stabilisation and making him carry out daily life activities, to avoid the possible complications, and to reduce the cost by shortening the healing process.

Rib fracture was diagnosed by X-raying in the right 4-5 anterior area of the male case at the age of 47 who applied the emergency service for pain and respiratory distress as a result of battery and he was hospitalized. The respiratory rate (RR) of the patient in resting position was 18/m. Narcotic analgesic 2*1, Paracetamol 2*1 treatment was applied for the patient's pain management. When the pain scoring was carried out to the patient before the application; VAS value was 8,5.

It can be shaped fitting to the patient. It can be used for the same patient by reforming. It helps the patient do the daily life activities (DLA) easily and increases the patient's comfort by reducing the patient's disability.

Orthosis was applied to the patient after the necessary information was given and ethical consent was taken.

While the pain and satisfaction levels were evaluated by VAS before and after the application, RR and DLA were questioned. They were monitored in the 0, 2nd, 4th, 6th, 8th, and 10th hours for the first day and in every 6 hours (06:00, 12:00, 18:00, 24:00) for the next days during 10 days and they were questioned by contacting via telephone..

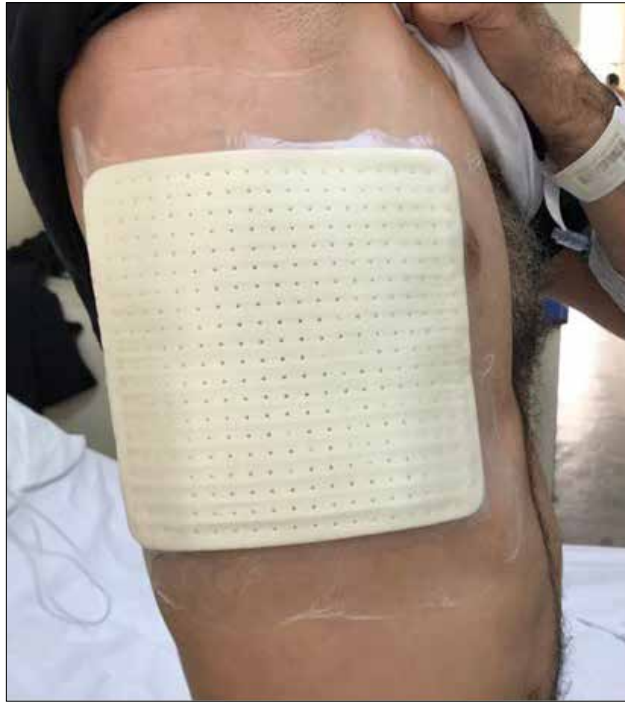

Figure 1. Application

While the score of the patient, whose pain level was evaluated by VAS just after the application (0.hour), was 8.5, it was 4.4 in the 2nd hour, was 2 in the 4th hour, was 1 in the 6th and 8th hours, and pain score was graded as 0 in the 10th hour.

The patient who stated that ‘NEVER WITHOUT HELP’ for daily life activities such as nutrition, excretion, moving and dressing, could do ‘WITHOUT HELP’ in the questionings in the 4th hour after the application.

As a result, analgesic need for the patient who was applied chest othosis for the stabilisation in rib fracture pain management was reduced to normal. It was a kind of application making the nurses carrying out the application. It will be useful to carry out this application with a larger sample.

Keywords: Rib fracture, conservative treatment, fracture stabilisation

[Abstract:0887] PS-181 [Accepted:Poster Presentation] [Pediatric Pulmonary Diseases]

Assessment of Right Heart Function in Children with Mild Cystic Fibrosis

Aynur Gulieva¹, Yilmaz Yozgat¹, Erkan Cakir², Hafize Otcu³, Ufuk Erenberk², Selcuk Uzuner², Lina Muhammed Al Shadfan², Kahraman Yakut¹

¹Department of Pediatrics, Division of Pediatric Cardiology, Bezmialem Vakif University School of Medicine, İstanbul, Turkey

²Department of Pediatrics, Division of Pediatric Chest Diseases, Bezmialem Vakif University School of Medicine, İstanbul, Turkey

³Department of Radiology, Bezmialem Vakif University School of Medicine, İstanbul, Turkey

Objectives: There are no studies in pulmonary hypertension, cor pulmonale and right ventricular (RV) deficiency associated with CF in children with mild cystic fibrosis (CF). In this study, we aimed to determine echocardiographic changes in pulmonary artery pressure, right ventricular anatomy and function in mild CF children.

Methods: The study group consisted of 40 pediatric patients with mild CF (FEV1>70% and Modifiye Shwachman-Kulczycki score >71) registered at the Pediatric Pulmonology outpatient clinic. The control group was 40 healthy children of the same age and sex. Right ventricular anatomy in patient and control groups; M-mode and right ventricular end-diastolic diameter (RVEDD), right ventricular anterior wall thickness (RVAW), right ventricular systolic functions; tricuspid annular plane systolic excursion (TAPSE), tissue Doppler peak systolic tricuspid annular velocity (ST), right ventricular fractional area change (RVFA), estimated pulmonary artery pressure in patients; right ventricular pre-ejection period (RPEP), right ventricular acceleration time (ACT), right ventricular ejection time (RVET), and their ratio to each other RPEP/RVET, ACT/RVET were evaluated. The obtained echocardiographic data were statistically compared in the patient and control groups.

Results: In the patient parameters showed statistically significant difference in right ventricular anatomic disorder (RVAW, RVEDD, and BSA ratios) and RV systolic functions (TAPSE, ST) and diastolic functions (tricuspid E-wave, A-wave, E/A ratio) compared to the control group. (p<0.001). However, no difference was found between the nomogram values for the age group (p>0.05).

In the patient group, parameters indicating elevation of pulmonary artery pressure (RVET, ACT, RPEP) and RVFA parameters used for measuring systolic function were different from control group and for age nomogram values (p<0.001).

Conclusion: Pulmonary artery pressure elevation, right ventricular failure, and cor pulmonale in children with mild CF begin early in childhood. In addition to routine echocardiographic measurements used in evaluating RV in children with mild CF, we recommend using RPEP, ACT, RVET echocardiographic parameters and RVFA, which are used to estimate pulmonary artery pressure.

Keywords: Cystic fibrosis, childhood age group, pulmonary hypertension, cor pulmonale, pulmonary function test

[Abstract:0892] EPS-251 [Accepted: E-Poster] [Thoracic Surgery]

Two Cases of Pio-Pneumothorax and Aspiration Pneumonia After Nasogastric Feeding Tube Insertion

Ahmet Nasır¹, Abidin Şehitoğulları¹, Rüçhan Anbar¹, Hikmet Çoban²

¹Clinic of Thoracic Surgery, Sakarya University Training and Research Hospital, Sakarya, Turkey

²Clinic of Chest Diseases, Sakarya University Training and Research Hospital, Sakarya, Turkey

Introduction: Nasogastric feeding tubes (NGFT) used for gastric decompression and feeding at the emergency services and intensive care units. Anatomic malformations, age, worsening of mental conditions due to primary disease or sedation, swallowing difficulties or depression of cough reflexes, intubation are the major risk factors. Tracheobronchial system is the most common reported disposition of NGFT. But intrapleural localization of the NGFTs are very rare. In our case we present a patient with a dispositioned NGFT via bronchial system.

Case 1: 75 years-old male patient with the diagnosis of ischemic cerebrovascular disease (2 years), epilepsy and COPD was consulted in emergency for dyspnea, high fever and confusion. Listen to the right, ral and ronküsü were available. Thorax CT showed NGFT in the right lower lobe bronchus and pneumonic infiltrates. NGFT terminated. Medical treatment was started to the patient who was taken to the intensive care unit.

Case 2: 93 years-old female patient with the diagnosis of ischemic cerebrovascular disease was consulted for acute dyspnea after NGFT insertion. She was unconscious, dyspneic with intercostal retractions. Breathing sounds were diminished at the right hemithorax. Distal part of the NGFT was seen at the pleural space via tracheobronchial system in chest X-ray. Pleural effusion and pneumothorax were also determined. NGFT was removed immediately and chest tube thoracostomy was applied. Medical therapy was rearranged due to the patients clinical situation. NGFT must be applied with care also chest X-ray controls may be helpful for prevention morbidity and mortality of malposition.

Keywords: Intrapleural, intrabronchial, nasogastric feeding tube

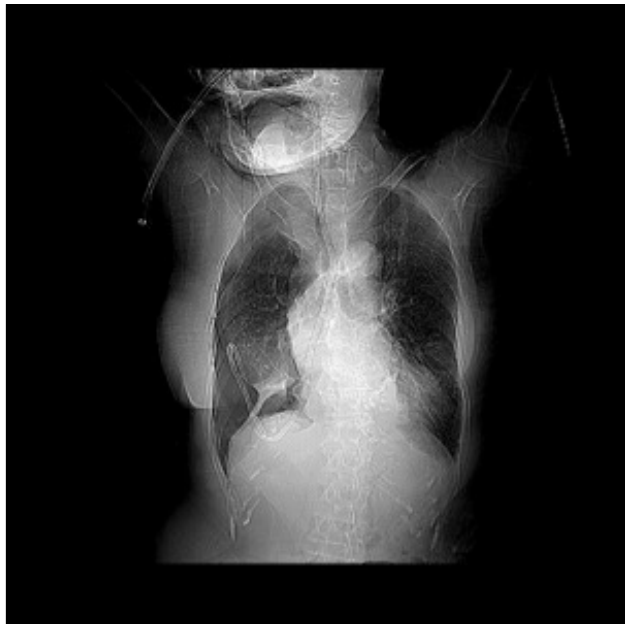

Figure 1. Nasogastric Feeding Tube extending to the pleural space

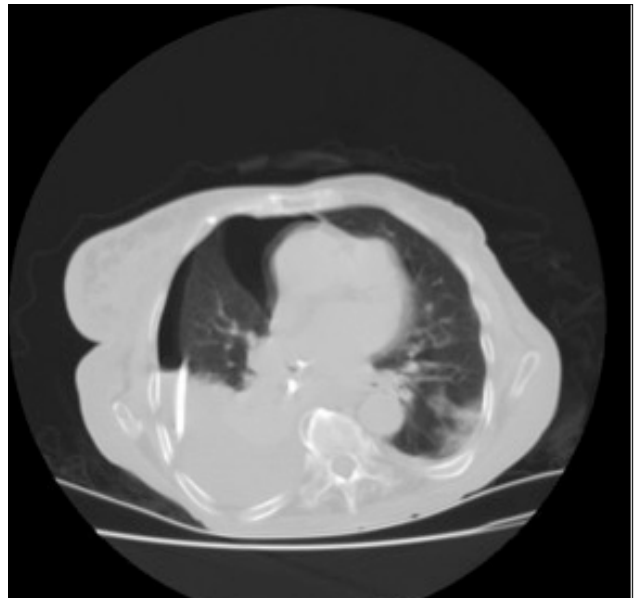


Figure 2. Intrabronchial, intrapleural NGFT which causes pneumothorax and pleural effusion in thoracic CT scans

[Abstract:0894] PS-206 [Accepted:Poster Presentation] [Asthma and Allergy]

Investigation of the Effects of Socioeconomic Level On Asthma Control

Nuran Gökbulut¹, Reyhan Yıldız², Leyla Pür Özyiğit³, Elif Altundaş Hatman⁴, Züleyha Bingöl¹, Feyza Erkan Krause¹

¹Department of Chest Diseases, İstanbul University İstanbul School of Medicine, İstanbul, Turkey

² Department of Chest Diseases, Health sciences University, Süreyyapaşa Chest Diseases and Thoracic Surgery Training and Research Hospital, İstanbul, Turkey

³Department of Chest Diseases, Özel American Hospital, İstanbul, Turkey

⁴Department of Public Health, İstanbul University İstanbul School of Medicine, İstanbul, Turkey

Objectives: In order to determine the socioeconomic level of the patients who were followed up with asthma diagnosis, the effects of socioeconomic level on asthma control were investigated by examining income levels, educational status, living conditions at home and working conditions.

Methods: Patients with asthma who consulted to the Chest Diseases Polyclinic of the İstanbul Medical Faculty between 2015 and 2016 were followed. Age, gender, body mass index (BMI), smoking history, living conditions at home, educational status, occupation, duration of asthma, medications, and respiratory function tests of the patients were recorded. Patients were asked to complete a socioeconomic information form including asthma control test (ACT), home life and working conditions, and to complete a questionnaire for the asthma knowledge level.

Results: A total of 335 patients participated in the triple-center study (university: 260 patients, education and research hospital: 68 patients, private health center: 7 patients). There were 264 women and 71 men, and the mean age was 51.84±13.45 years. Asthma follow-up duration was 16.87±10.7 years. There was smoking history in 27.3% of them (n = 90). The mean BMI was 29.73±5.57 (16.9-45.3) kg/m². The rate of the patients with ACT≤19 (uncontrolled ones) was 43.3% (N=145), it was 42.7% (n=143) for the patients with 20≤ ACT ≤24 (partially controlled ones), and was 14% (n=47) for the patients with ACT=25 (controlled ones). There was no relationship between ACT and gender. However, it was found that asthma control was worse in women. As monthly income increased (≥ 1500 TL), asthma control was observed to increase (p=0.038). The patients who were under complete or partial control for asthma were found to be less obese. Those with monthly income ≤1500 TL were found to be less obese. Passive smokers at home or workplace were found to be in the group of uncontrolled ones (p=0.001, p=0.043). Literacy status of uncontrolled patients with asthma was found to be lower (p=0.005). The patients with complete asthma control had a longer educational period than the others (10.4±3.9 vs 8.4±3.8). ACT values in patients with asthma control and a room number >1 were higher than the others (20.28±4.37 vs. 18.06±5.31, p=0.01). Those who lived in damp houses had lower ACT values (17.27±5.57 vs 18.98±5.23, p = 0.042). It was also found that asthma control rates also increased in those who regularly had doctor control (p <0.001). The psychological evaluation questionnaire was used to assess the psychological state of the patients and found that asthma control was worse in those who had frequent crying episodes without reason p=0.024.

Conclusion: Factors such as income, education, home and work life, and access to health services, which determine the socioeconomic level, have been found to play an effective role in asthma control.

Keywords: Asthma, socioeconomics, control

[Abstract:0895] PS-187 [Accepted:Poster Presentation] [Pediatric Pulmonary Diseases]

QT Prolongation After Receiving Short-Term Azithromycin Treatment in Children with Chronic Lung Disease

Yılmaz Yozgat¹, Erkan Cakir², Hafize Otcu³, Lina Muhammed Al Shadfan², Kahraman Yakut¹, Hakan Yazan², Ufuk Erenberk², Selcuk Uzuner²

¹Department of Pediatrics, Division of Pediatric Cardiology, Bezmialem Vakif University School of Medicine, İstanbul, Turkey

²Department of Pediatrics, Division of Pediatric Chest Diseases, Bezmialem Vakif University School of Medicine, İstanbul, Turkey

³Department of radiology, Bezmialem Vakif University School of Medicine, İstanbul, Turkey

Objectives: Azithromycin is prevalently used in pediatric patients who have Chronic lung disease (CLD) with asthma, and cystic fibrosis (CF) for its anti-inflammatory actions. Using long-term macrolides improve the life quality of CLD patients by boosting lung-function and decreasing the frequency of acute exacerbations. Acquired long QTc syndrome is defined as progression to ventricular arrhythmia (torsade de pointes (TDP) and ventricular fibrillation) due to the use of medication caused by the prolonged QTc interval in a patient's ECG. QTc interval prolonged and abnormal T wave morphology in the ECG is a crucial feature to identify this syndrome. In the literature, it is reported that azithromycin can cause TDP. In this study, we investigated the use of azithromycin prophylaxis, which is prevalently used in 3 and 6 months, and diagnosed with CLD regardless of their prolonged QTc intervals in ECG or not.

Methods: A total of 80 patients with CLD, use of azithromycin prophylaxis in 1,3 and 6 months, participated in this study. Forty-five patients met the criteria during their follow-ups. These patients' QTc intervals were calculated using azithromycin prophylaxis treatment in their 1,3 and 6 months during their follow ups and compared with before using prophylaxis.

Results: A total of 45 patients' median age was 11 years in this study (min 4-max 17), the group was agglomerated of 45 patients and 25 of them made up the women gender (55.5 % girls). A statistically significant difference was detected between the initial ECG before using prophylaxis and a month after the start of prophylaxis treatment with regard to QTc interval measurements (QTc 0.38 ± 0.03 and 0.42 ± 0.04 , $p<0.05$ ($p<0.05$)). However, a statistically significant difference (QTc 0.40 ± 0.03 , QTc 0.39 ± 0.03 , $p>0.05$) could not be found on the pediatric patients who used azithromycin prophylaxis more than 3 months compared with before using prophylaxis.

Conclusion: We suggested to the patients who were diagnosed with CLD and azithromycin prophylaxis in childhood, one month of follow up treatment is required to check on the QTc intervals in their ECG. When a patient has non prolonged QTc interval with azithromycin prophylaxis in the first month period, azithromycin prophylaxis can be safely used as a long term treatment.

Keywords: QT prolongation, azithromycin prophylaxis, chronic lung disease, childhood

[Abstract:0896] SS-025 [Accepted:Oral Presentation] [Pulmonary Rehabilitation and Chronic Care]

Effects of Upper Extremity Aerobic Exercise Training on Exercise Capacity, Dyspnea, Fatigue, Depression and Quality of Life in Patients with Pulmonary Arterial Hypertension

Burcu Camcıoğlu¹, Meral Boşnak Güçlü¹, Müşerrefe Nur Keleş¹, Gülten Aydoğdu Taçoy², Atiye Çengel²

¹Department of Physical Therapy and Rehabilitation, Gazi University, Faculty of Health Sciences,, Ankara, Turkey

²Department of Cardiology, Gazi University School of Medicine, Ankara, Turkey

Objectives: Pulmonary arterial hypertension (PAH) is a rare, chronic and progressive cardiopulmonary disease characterized by elevated pulmonary arterial pressure. Impaired exercise capacity, increased dyspnea and fatigue perception are very common symptoms and negatively affect activities of daily living, depression and quality of life in patients with PAH. The effects of various lower extremity exercise training methods on pulmonary and extrapulmonary impairments has been investigated in patients with PAH, however upper extremity aerobic exercise interventions are scarce. The aim of the study was to investigate effects of upper extremity aerobic exercise training (AET) on exercise capacity, dyspnea, fatigue, depression and health related quality of life in patients with PAH.

Methods: This is a prospective, randomized controlled, double-blinded study. Eleven patients diagnosed with PAH (35.00 ± 13.68 years, 1M/10F, PAP= 72.60 ± 25.59 mmHg, functional class (n/%) =II-III:4/36.4%- 7/63.6%) included in AET group and 11 patients in control group (40.18 ± 14.47 years, 1M/10F, PAP= 84.36 ± 31.30 mmHg, functional class (n/%) =I-II-III:1/9.1%- 5/45.5%- 5/45.5%). AET group applied upper extremity aerobic exercise training (55-75% of max-HR) 3 days/week and respiratory exercises for 7 days/week and control group applied alternating upper extremity exercises for 40 times/session, 3 session/day and respiratory exercises, for 7 days/week and 6 weeks. Pulmonary function (spirometry), exercise capacity (six minute walk test [6MWT]), dyspnea (modified "Medical Research Council" dyspnea scale [MMRC]), fatigue (Fatigue Severity Scale [FSS]), depression (Montgomery Åsberg Depression Rating Scale) and quality of life (Short Form 36 Health Survey [SF-36]) were evaluated before and after training.

Results: Baseline clinical and demographic characteristics were similar in groups ($p>0.05$). MMRC ($p<0.001$) and FSS ($p=0.05$) were significantly decreased in AET group compared with control group. 6MWT distance (52 m, 95%CI=3.65-93.24 m, power=34%) and 6% MWT were significantly and clinically increased and MMRC ($p<0.001$), FSS ($p=0.026$) and SF-36 role-physical ($p=0.017$), vitality ($p=0.018$) and social functioning ($p=0.027$) subscale scores were significantly improved within AET group, no significant improvement were present in control group. There were no significant difference in depression scores between and within groups ($p>0.05$).

Conclusion: Upper extremity aerobic exercise training improves functional exercise capacity and quality of life; decreases dyspnea and fatigue perception in patients with pulmonary arterial hypertension. It is safe and effective intervention and should be included in rehabilitation programs in PAH. New researchs investigating the effects of different intensity and duration of aerobic exercise training in patients with PAH are needed. More patients should be included to the future studies.

Keywords: Aerobic exercise training, dyspnea, exercise capacity, fatigue, pulmonary arterial hypertension, quality of life

[Abstract:0898] EPS-299 [Accepted: E-Poster] [Tuberculosis]

Pulmonary Tuberculosis Mimicking Legionella Pneumonitis; A Case Report

Ayşe Baççioğlu, Asiye Büşra Çimen, Ayşe Füsün Kalpaklıoğlu

Department of Chest Diseases, Kırıkkale University School of Medicine, Kırıkkale, Turkey

Introduction: Legionella pneumonia is a lung infection infected through water-containing media. Elderly people, people with chronic lung diseases, smokers, people who have a history of travelling are at risk for this disease. Here, we presented a patient who was prediagnosed with legionella pneumonia and then diagnosed with tuberculosis.

Case Presentation: A 62-year-old male prisoner was brought to the emergency service with the complaints of fainting, fatigue, shortness of breath, cough, mild bloody sputum, chills, shivering, fever and nausea-vomiting. The patient whose general condition was moderate had a confused consciousness, 38.5 °C of fever, 94% of oxygen saturation, and a cachectic appearance, and there were rough rales in lung basals in auscultation. When the neurological examination and the brain computerized tomography (CT) was normal in the patient who had a history of epilepsy and 30 p/year smoking, his clinic was considered to be secondary to hyponatremia (Na: 127 mEq / L) and infection. Serum c-reactive protein (CRP) was 195 mg/L, sedimentation was 22 mm/h, the levels of albumin, potassium, and sodium were low, and there was elevation in the levels of liver function tests (LFT) and lactate dehydrogenase (LDH). Complete urine examination was normal. The P-A x-ray revealed diffuse patchy infiltrations in the right upper-middle zone. In thoracic CT angiography of the patient whose serum d-dimer was 2.8 µg/mL and who had thromboembolic risk factors (immobile, elderly), it was seen that there was no emboli, there were conglomerate-like lymph nodes the biggest of which was 25x19 mm in size in the right hilar region, there were diffuse patchy ground-glass densities and consolidation areas in the right upper lobe, and a 4-cm-thick pleural effusion on the right. The patient with a Curb-65 score of 4 (confused, age> 65, RR> 30 min, DBP> 60 mmHg) was admitted to the hospital and empiric moxifloxacin was initiated with the prediagnosis of socially-acquired severe pneumonia. However, because his fever was high, cultures were taken and ceftriaxone was added. Blood, urine and sputum cultures showed no growth and ARB was negative. Pleural effusion was exudative, ADA was 39 U/L, ARB and culture were negative. In addition to the lung; because there were central nervous system and gastrointestinal system complaints, accompanying respiratory failure, hyponatremia in the serum, and radiologically patched infiltrates, legionella antigen was examined in the urine of the patient who was considered to have legionella pneumonia; however, the test was negative. After 15 days of antibiotic therapy; the patient was discharged when the complaints, serum CRP, elevation in LFT and LDH, mild hypoxemia, and the infiltrations in P-A x-ray completely regressed. However; mycobacterium tuberculosis reproduction occurred in the sputum culture of the patient 1 month later, and tuberculosis treatment was started in the patient, who was referred to another city, by Tuberculosis Control Dispensary.

Conclusion: When the patient with suspicion of legionella pneumonia due to lung clinic accompanied by extrapulmonary symptoms and laboratory findings was retrospectively examined; considering the risky environment –prison –, malnutrition and accompanying chronic pulmonary disease, he was thought to have adequate risk for tuberculosis, as well. Tuberculosis should not be ignored in the treatment of pneumonia in convicted patients.

Keywords: Pneumonia, tuberculosis, Legionella

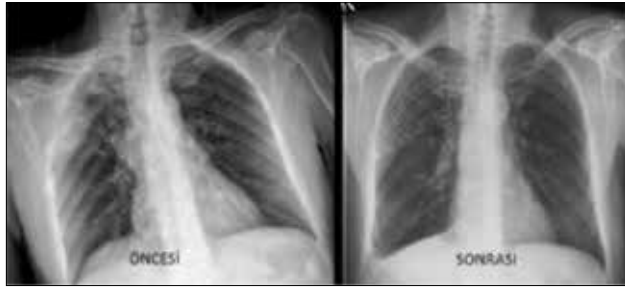

Figure 1. PAAG before and after

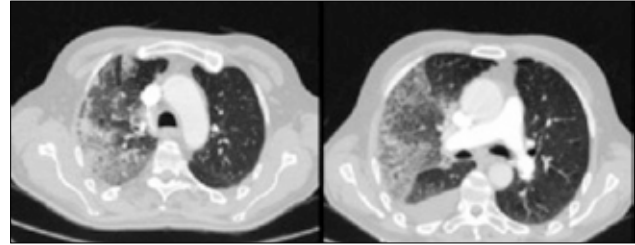


Figure 2. Patchy infiltration

[Abstract:0900] EPS-276 [Accepted: E-Poster] [Thoracic Surgery]

Migrating Tooth in the Bronchus: A Rare Case

Güntuğ Batıhan, Şaban Ünsal, Funda Cansun Yakut, Kenan Can Ceylan, Şeyda Örs Kaya

Department of Thoracic Surgery, Health Sciences University Dr. Suat Seren Chest Diseases and Thoracic Surgery Training and Research Hospital, İzmir, Turkey

Introduction: Foreign body aspiration (FBA), although more frequent in children, is a potentially life-threatening emergency that can occur at any age. Patients may be asymptomatic, have a choking event, cough attacks with inspiratory stridor, or symptoms may vary from trivial or chronic non-specific symptoms (dyspnea, cough, sputum, wheezing) and mimic other lung diseases. Bronchoscopy remains the gold standard for diagnosis and management of FB aspiration. We report a case of an unusual airway foreign body (tooth) that migrated preoperatively from one main bronchus to the other.

Case Presentation: A 69-year-old female was referred to our institute with cough attacks with inspiratory stridor. In addition patient describe tooth aspiration during procedure of dental extraction. The patient stated that the cough had been ongoing for the past 2 months but had worsened in severity over the last 2 weeks prior to admission. A chest x-ray posteroanterior view, available with the patient, revealed a radio opaque foreign body in the region of the right main bronchus. A CT scan of the chest showed endobronchial occlusion of the right main bronchus with radio opaque foreign body. General anesthesia was administered and the patient was intubated. Rigid bronchoscope no. 8 was introduced into the subglottis. After ensuring proper ventilation of the patient, the bronchoscope was advanced into the trachea. In contrast to what's supposed to be foreign body was visualized lying over the proximal part of left main bronchus. The foreign body was successfully removed with biopsy forceps, revealing a broken tooth piece, measuring 1.2×0.8×0.8 cm.

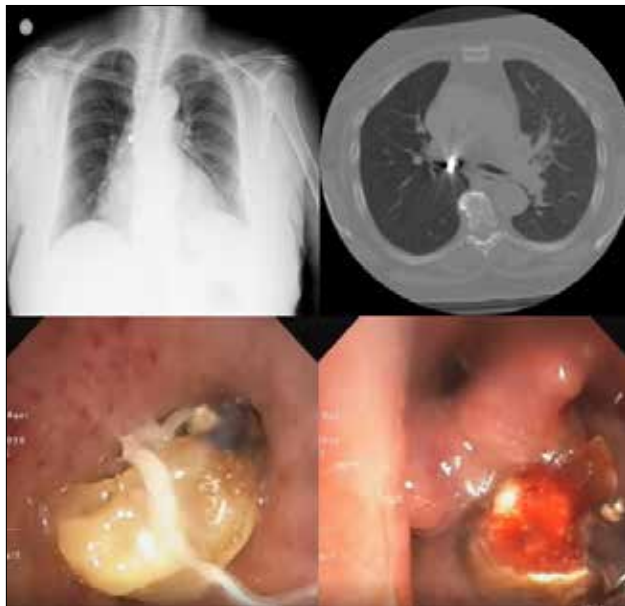


Figure 1. Foreign body was seen in left main bronchus via bronchoscopy in contrast to radiological images

Recovery was speedy and uneventful. Postoperative chest X-ray was clear. Subsequent follow ups have ensured the complete recovery and absence of any complication.

Conclusion: Foreign bodies may result in serious complications if left undiagnosed. Signs and symptoms are nonspecific which include cough, shortness of breath, wheezing, and/or hemoptysis. A chest X-ray is the initial standard work-up for a suspected foreign body aspiration. Treatment of respiratory foreign bodies is by Bronchoscopic removal. The rigid open tube bronchoscope is the preferred mode with the patient under general anaesthesia. The flexible fibreoptic bronchoscope too has been used. It is important that the migration potential of the foreign body always be considered and chest radiography should be performed just before the surgery. We aim to present a rare case of migrating foreign body in bronchus in context of the literature.

Keywords: Cough, foreign body aspiration, rigid bronchoscopy

[Abstract:0901] EPS-194 [Accepted: E-Poster] [Thoracic Surgery]

Astonishing Giant Tumor in the Mediastinum: Hamartoma

Ayten Güner Akbıyık¹, Halil İbrahim Yakar², Halil Tözüm¹, Nurver Özbay³, Tahir Şevval Eren¹

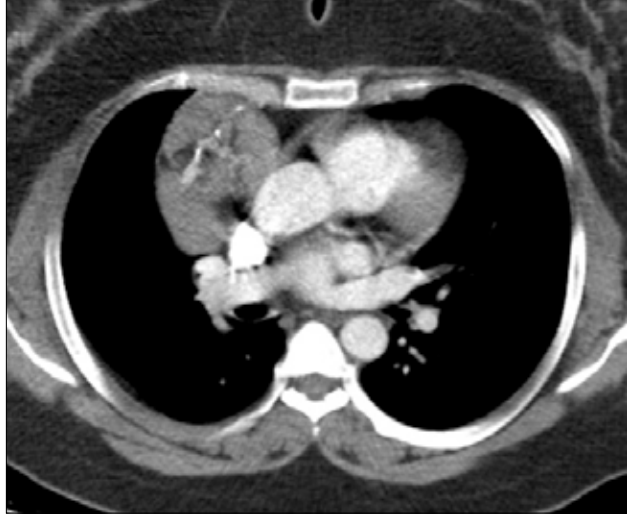

Figure 1. Axial image in CT

¹Department of Thoracic Surgery, İstanbul Medeniyet University Göztepe Training and Research Hospital, İstanbul, Turkey

²Department of Chest Diseases, İstanbul Medeniyet University Göztepe Training and Research Hospital, İstanbul, Turkey

³Department of Pathology, İstanbul Medeniyet University, Göztepe Training and Research Hospital, İstanbul, Turkey

Hamartomas are the most common benign tumors of the lung. The bronchus cartilage surrounded by the lining epithelium in the respiratory system includes fat and connective tissue, smooth muscle and fibrous tissue elements. They frequently appear as the peripheral solitary lung mass. It can be observed as endobronchial at a rate of 8-10%. Settlement in mediastinum is very rare. The mediastinal hamartoma is limited to a few cases in the literature. The case is remarkable due to a giant mediastinal hamartoma.

Keywords: Benign, giant, hamartoma, mediastenum, tumor

[Abstract:0902] EPS-232 [Accepted: E-Poster] [Thoracic Surgery]

Palliation with Endobronchial Therapy in Lung Cancer

Aysun Kosif, Sevinç Çıtak, Abdurrahim Gördebil, Serkan Bayram, Selami Volkan Baysungur

Department of Thoracic Surgery, Health Sciences Üniversitesi Süreyyapaşa Chest Diseases and Thoracic Surgery Training and Research Hospital, İstanbul, Turkey

Despite all treatment modalities, lung cancer has a high mortality and high morbidity rate with a survival rate of 16%. Bronchoscopy is usually used for the diagnosis and staging of lung cancer, but recently it has also been used for the purpose of palliation. Techniques such as mechanic, thermic, stent and radiotherapy have been developed in order to remove the manifestations of dyspnea, atelectasis and pneumonia resulting from the obstruction caused by endobronchial tumor and to open the obstructed airway rapidly. We present our case for the purpose of a contribution to the literature.

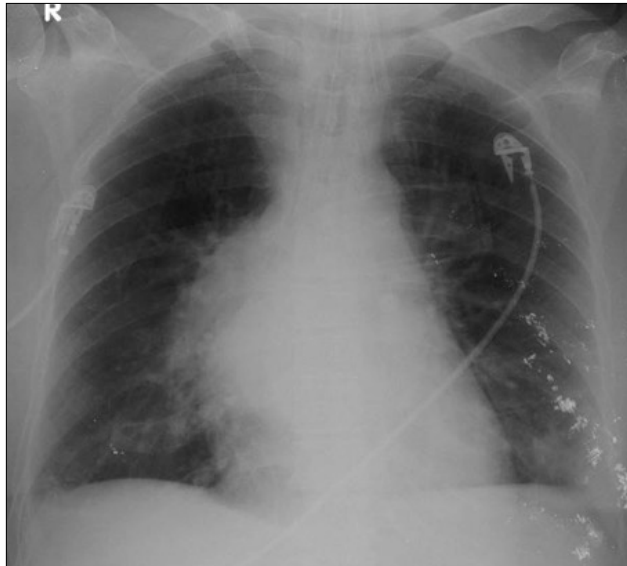

Figure 1. Lung radiography

A 64-year-old patient was admitted to an external center with the complaint of shortness of breath one month ago; in the positron emission computerized tomography that was taken due to the detection of a suspected mass in the right hilar region in the chest X-ray, a 6x5 cm mass with SUVmax 11.7 involvement was detected in the right upper hilar region, and there were breast and bone involvements, which was interpreted in favor of metastasis. The result of the biopsy taken from the endobronchial lesion with fiberoptic bronchoscopy was diagnosed as adenocarcinoma of the lung. The patient who was observed to have massive hemoptysis in the follow-ups was intubated. The patient who had undergone cardiac arrest 15 days ago was reanimated with applied cardiac massage. When first interned, the patient had stable vital findings, was sedated, and intubated (Figure 1). A vegetating bleeding mass starting at the 8th cm of the trachea, extending to both main bronchi, and obliterating the right main bronchus nearly totally and the left main bronchus partially was

seen in the rigid bronchoscopy that was performed. The bronchial system was cleaned up to sub-segment level by destructing the tumor with the aid of forceps. Hemostasis and cryotherapy were performed in the hemorrhagic areas. During the follow-up, bleeding was not observed in the endobronchial system and rapid recovery was achieved in ABG values. On the first day of brachytherapy, the patient was extubated and there was no haemoptysis and respiratory distress. On the second day after brachytherapy, the patient was taken to the service. On the 5th day after the procedure, the patient was extubated by taking appointment from the department of radiation oncology.

In nearly half of the patients diagnosed with lung cancer, some problems arising from airway obstruction due to endobronchial lesion are found in a period of the disease. With endobronchial brachytherapy (EBB), a complete recovery was achieved in 70-100% of patients; most of the symptoms recovered permanently. Rapid response can be received with EBB in the symptoms of dyspnea that occurs as a result of bronchial obstruction caused by endobronchial growth of the tumor, postobstructive pneumonia, atelectasis, cough, and hemoptysis.

Keywords: Brachytherapy, endobronchial therapy, palliation

[Abstract:0903] EPS-282 [Accepted: E-Poster] [Thoracic Surgery]

Bi-Portal Videothoracoscopic Resection in the Treatment of Congenital Pulmonary Disease in the Childhood Group

Sevinç Çıtak, Serkan Bayram, Onur Derdiyok, Rıza Serdar Evman, Çağatay Saim Tezel, Selami Volkan Baysungur

Department of Thoracic Surgery, Health Sciences Üniversitesi Süreyyapaşa Chest Diseases and Thoracic Surgery Training and Research Hospital, İstanbul, Turkey

Congenital cystic adenomatoid malformation (CCAM) is a congenital pulmonary anomaly that occurs in 25-30 thousand pregnancies, and is caused by abnormal branching of the dysplastic lung tissue from the immature bronchial tree. It is usually diagnosed and treated until the age of two. We aimed to present our case that was incidentally detected in advanced childhood through bi-portal videothoracoscopic right lower lobectomy with the literature of videothoracoscopic surgery in congenital lung diseases.

A 12-year-old male patient described a chest pain with effort and was admitted to the emergency service of an external center. The patient was cardiologically evaluated and no pathological findings were found. Chest computed tomography of the patient in

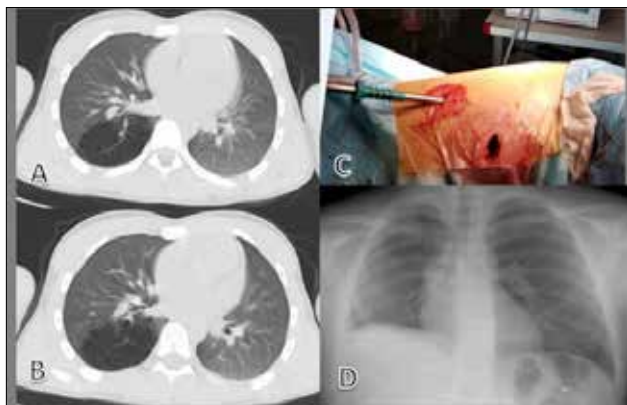


Figure 1. A-B Lesion image in CT C-Videothoroscopic incisions D-Chest radiography at discharge

whom no pathology was detected in the chest X-ray was reported as: global density decrease due to hyperinflammation in a 77x45x110 mm area in the the upper right lobe superior segment and millimetric cystic areas within and adjacent to this area were observed, and the findings were consistent with malformation of the congenital airways. Thereupon, the patient who was referred to us was examined with the prediagnosis of congenital cystic adenomatoid malformation type 2. FEV1 was 95% (2.87lt) in the patient who had no features in his history and laboratory values. Surgery was planned for the patient. Right lower lobectomy was performed with VATS in the left lateral decubitus position. The drainage was terminated on the third postoperative day and the patient was discharged on the fourth postoperative day. There was no problem in the first month post-discharge control, and the follow-up process is continued (Figure 1).

Key words: Congenital cystic adenomatoid malformation, VATS

[Abstract:0904] EPS-184 [Accepted: E-Poster] [Thoracic Surgery]

A Rare Case of Mediastinal Epithelioid Hemangioendothelioma

Abidin Şehitoğulları¹, Ahmet Nasır¹, Rüçhan Anbar¹, Fuat Sayır², Yusuf Aydemir³

¹Department of Chest Surgery, Sakarya University School of Medicine, Sakarya, Turkey

²Department of Chest Surgery, Yüzüncü Yıl University School of Medicine, Van, Turkey

³Department of Chest Diseases, Sakarya University School of Medicine, Sakarya, Turkey

Mediastinal epithelioid hemangioendotheliomas are among hemangiomas and angiosarcomas that are rarely seen, and in the group of vascular tumors. They are malignant tumors arising from medium and large veins. Complete surgical resection alone usually results in long-term survival.

A 67-year-old female patient consulted with the complaint of chest pain. Respiratory sounds were normal in the examination. Chest X-ray showed opacity in the upper mediastinum on the left. In the upper mediastinum, thorax computerized tomography revealed a heterogeneous mass lesion which was approximately 3.5x3 cm in size and whose borders could not be distinguished from the left innominate vein (Figure 1). Increased FDG involvement was detected in PET-CT (SUV-max value 6). Transthoracic biopsy result was reported as epithelioid hemangioendothelioma. Robotic surgery was performed in the patient. The mass was completely released from the surrounding tissues. The mass was associated with the left innominate vein. The connection was cut off by placing 2 hemoclips in this region and it was completely excised (Figure 2). The oncologic council decided that radiochemotherapy was not necessary.

In the study for mediastinal epithelioid hemangioendothelioma; no published articles were found in the literature. Epithelioid hemangioendothelioma is found in the literature as a primary pulmonary case and a liver case. They are very rare and long-term survival can be achieved with surgery.

Keywords: Mediastinum, epithelioid hemangioendothelioma, surgical treatment

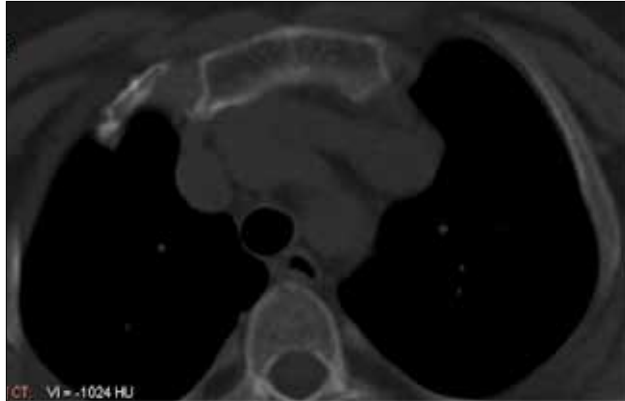

Figure 1. Thoracic CT image of tumor

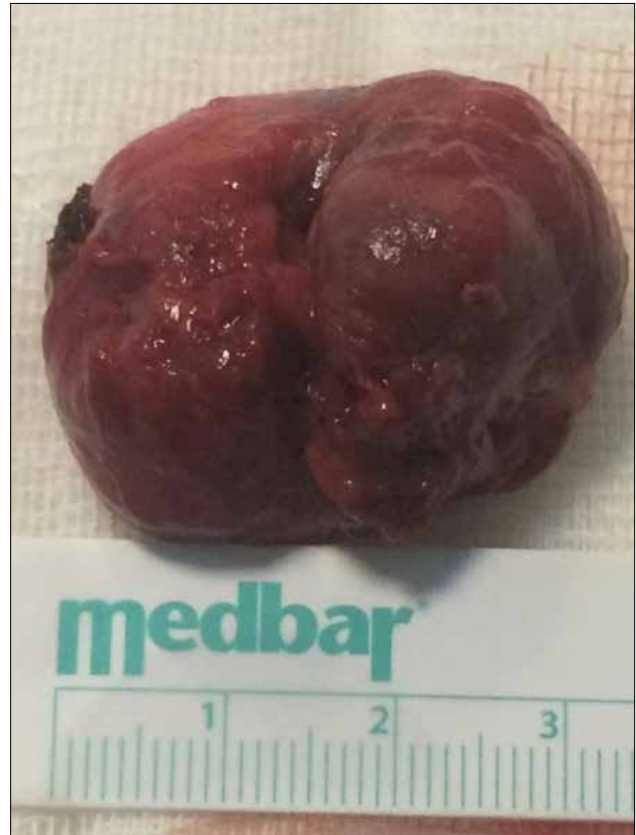

Figure 2. Macroscopic view of removed tumor

[Abstract:0907] PS-182 [Accepted:Poster Presentation] [Pediatric Pulmonary Diseases]

Evaluation of Cystic Fibrosis Cases Diagnosed Through Newborn Screening Program at Dicle University

Velat Şen¹, Rıdvan Doğan², Müsemma Karabel¹, İsmail Yıldız³

¹Department of Pediatric Chest Diseases, Dicle University School of Medicine, Diyarbakır, Turkey

²Department of Pediatrics, Dicle University School of Medicine, Diyarbakır, Turkey

³Department of Biostatistics, Dicle University School of Medicine, Diyarbakır, Turkey

Objectives: Cystic fibrosis (CF) is a genetic disorder that shows autosomal recessive inheritance. Although prevalence varies among populations, it is 1 in an average of 2000 - 3500 live births. However, the incidence and prevalence of the disease in our country is still not clearly defined. The incidence is expected to be higher than estimated due to the high prevalence of consanguineous marriage in our country. Our aim in this study is to determine the incidence considering the patients diagnosed through CF screening in Diyarbakır and to evaluate the patients who were admitted from the neighboring cities and diagnosed through the screening program.

Methods: The patients diagnosed with newborn screening program between 01 January, 2015 and Dec 31, 2017 at the Dicle University Pediatric Chest Diseases Clinic were evaluated retrospectively.

Results: According to the data of Turkish Statistical Institute, 43507 live births took place in Diyarbakır in 2015. Of the 222 patients with a high IRT value, definite diagnosis of CF was made for 9 through sweat test and clinical evaluation. In 2015, the incidence of CF for Diyarbakır was 2.1/10.000 and the frequency was 1/4834. In addition, definite diagnosis was also made for 9 of the 499 patients who were admitted from the neighboring cities. In 2016, there were 42816 live births in Diyarbakır and definite diagnosis was made for 12 of the 386 patients who consulted with IRT elevation. In 2016, the incidence of CF in Diyarbakır was 2.8 / 10.000 and the frequency was 1/3.568. Seven of the 499 patients who were admitted from outside Diyarbakır were diagnosed. In 2017, among 42150 live births, definite diagnosis was made for 10 of the 230 patients who consulted with IRT elevation. The frequency for 2017 was calculated as 1/4215. Eighteen of the 421 patients who consulted from the neighboring cities were diagnosed.

Conclusion: With this study, we found the incidence of CF in Diyarbakır between 2015-2018. We believe that determining the frequency of the disease in our country will contribute to the importance of the newborn screening program in the health care system and to the efficient use of the resources of our country.

Keywords: Cystic fibrosis, newborn screening program, incidence

[Abstract:0910] PS-054 [Accepted:Poster Presentation] [Lung and Pleura Malignancies]

Pulmonary Mucinous Cystic Neoplasm, Which is One of the Rare Tumors of the Lung: A Case Report

Hilal Köşük¹, Serkan Bayram², Onur Derdiyok², Aysun Kosif², Esra Usta Bülbül³, Volkan Baysungur²

¹Department of Anesthesiology, Süreyyapaşa Chest Diseases and Thoracic Surgery Training and Research Hospital, İstanbul, Turkey

²Department of Thoracic Surgery, Süreyyapaşa Chest Diseases and Thoracic Surgery Training and Research Hospital, İstanbul, Turkey

³Department of Chest Diseases, Süreyyapaşa Chest Diseases and Thoracic Surgery Training and Research Hospital, İstanbul, Turkey

Introduction: Cystic mucinous tumor of the lung is the tumor whose histology differs from most lung adenocarcinomas and which represents the malignant potential spectrum. One of the main reasons is that it is very rare in the literature. In this study, a case diagnosed with primary mucinous cystic tumor of the lung was presented as a contribution to the literature.

Case: A 61-year-old male patient consulted to our clinic due to hemoptysis complaints. There weren't any particular features in his physical examination and history. No abnormality was detected in laboratory parameters. A nodule was detected in thorax computerized tomography (CT). Positron emission tomography (PET / CT) was taken. A 12-mm subpleural nodule without FDG involvement was detected in the right upper lobe (Figure 1). Fiberoptic bronchoscopic (FOB) examination revealed a bleeding area in the right upper lobe. However, endobronchial lesions were not seen and it was evaluated as normal. No pathology was found in the bronchial lavage material. Transthoracic fine needle aspiration was performed, but no diagnosis could be obtained. Agglutinin tests performed for hydatid cysts were negative. The patient was followed up for two years due to pulmonary nodule and surgical decision was made due to hemoptysis complaints. A pulmonary nodule approximately 1 cm in diameter was palpated in the right upper lobe during the thoracotomy. After the pathological examination of the frozen material was reported as a benign lesion, the lesion was totally removed with wedge resection. Pathology was reported as a primary mucinous cystic tumor of the lung (Figure 2). No pathology was detected in the 6-month follow-up of the patient.

Discussion: Mucinous cyst tumor is a restricted tumor. This restriction forms a partial fibrous capsule. There is a cystic change associated with mucin and the neoplastic mucinous epithelium grows along the alveolar walls. In such cases, the epithelium may be over-differentiated and sometimes the tumor cells float in the mucin pools. Mucinous cystadenoma is defined as "a localized cystic mass filled with mucin and surrounded by a fibrous wall lined by well-differentiated columnar mucinous epithelium". The differential diagnosis of pulmonary mucinous cystic tumor includes mucous gland adenoma, mucoepidermoid carcinoma, mucinous bronchioloalveolar carcinoma and metastatic mucinous carcinoma. Mucus gland adenomas and

mucoepidermoid carcinomas are endobronchial lesions of primary mucinous cystic tumors of the lung located at the peripheral site. While mucus gland adenomas exhibit mucinous glands that grow as a cyst protruding into the bronchial lumen, mucoepidermoid carcinoma consists of mucin-producing cells mixed with squamous and intermediate cells. Clinically, it is mostly asymptomatic. Although rare, symptoms of shortness of breath, chest pain and persistent cough have been reported. Surgical decision was made due to hemoptysis complaints of the patient. Studies have shown that the optimal treatment of pulmonary mucinous cystic tumors is lobectomy or complete surgical resection. The role of adjuvant treatment is uncertain. However, there are studies on limited chemotherapy in the literature. Resection was performed also in our case with tumor thoracotomy. As a result; primary mucinous cystic tumors should be kept in mind in the differential diagnosis of lung tumors.

Keywords: Mucinous cyst tumor, rare lung tumor, thoracic surgical approach

[Abstract:0911] PS-321 [Accepted:Poster Presentation] [Lung Transplantation]

Pulmonary Transplantation and Infection

Sinan Türkkan¹, Ayşe Yasemin Tezer Tekçe², Fatmanur Çelik Başaran¹, Mahmut Subaşı¹, Alkın Yazıcıoğlu¹, Mehmet Furkan Şahin¹, Ahmet Güngör¹, Hülya Özey³, Mustafa Bindal³, Hija Yazıcıoğlu³, Sema Turan³, Erdal Yekeler¹

¹Department of Thoracic Surgery and Lung Transplantation, Health Sciences University Turkey High Specialization Training and Research Hospital, Ankara, Turkey

²Department of Infectious Diseases, Health Sciences University Turkey High Specialization Training and Research Hospital, Ankara, Turkey

³Department of Anesthesiology and Intensive Care, Health Sciences University Turkey High Specialization Training and Research Hospital, Ankara, Turkey

Objectives: Infections are the cause of significant mortality and morbidity both in the early period and in the late period after pulmonary transplantation (PT). At our center, we examined the microbiological data, infection onset time and infection factors of 42 PT patients in terms of prophylaxis and treatment strategies, and evaluated in terms of the effects on mortality and chronic process.

Methods: We retrospectively investigated all infective episodes that 42 PT patients had with respect to time and etiology. We also retrospectively assessed donor-borne microbiological data and their clinical effects in the postoperative acute phase.

Results: Forty two PT patients with an average age of 46.8 years and a follow-up duration ranging from 1 to 58 months were evaluated. The most common donor-borne infectious agents are *S. aureus* (13), *Candida* species (12), *A. baumannii* (8) and *P. aeruginosa* (7). During early post-op period, bacterial infections were seen most frequently and fungal infections followed. *A.baumannii* was detected in 9 patients in the first month. In 3 patients, sepsis developed due to *A. baumannii* (microorganism was detected in catheter, BAL, and peripheral blood), and the patient in whom re-transplantation was performed died due to multiorgan failure. In the first month; comorbidities occurred in patients in whom *A. baumannii* was found in the chronic period follow-up such as chronic rejection in 2 patients, vanishing bronchus in 1, MAC infection in 1, and post-transplant lymphoproliferative disease in 1 patient; 3 of them died due to various reasons during the prolonged postoperative intensive care (including the patient who died due to sepsis). In our own clinical observations, we did not encounter candidemia symptom which is reported in the literature to be seen frequently in the first 3 months. *Candida* results found in our clinic were interpreted as colonization. CMV infection is the most commonly encountered in middle and long term. CMV infection was seen in 16 of our patients (most frequently between 4 and 12 months) and 3 of them were in the pneumonitis clinic. We found that patients with recurrent CMV infection had underlying triggering causes or co-infections, such as vanishing bronchitis, fungal infection, and MAC infection. Severe aspergillus infection (ulcerative tracheobronchitis, pseudomembranous tracheobronchitis and anastomotic infection, invasive aspergillosis) was observed in 3 patients. Mortality was observed due to infectious causes in a total of 2 patients after prolonged post-op intensive care.

Conclusion: PT is the procedure in which infection and rejection are most commonly seen in solid organ transplantation. Infections are important causes of morbidity and mortality. In lung transplantations in which cadaveric donors are used, we choose an appropriate antibiotic prophylaxis considering donor-borne infections in the post-op period. The presence of donor-borne resistant pathogens such as acinetobacter and pseudomonas suggests that colonization and endemicity with these pathogens in intensive care units are more frequent in our country. We added inhaled colistin to antibiotherapy prophylaxis to find a solution for this problem. Early post-op infections with resistant microorganisms were effective in mortality and morbidity. We observed that CMV and fungal infections were alarming in terms of rejection, co-infection and other chronic clinical problems.

Keywords: Pulmonary Transplantation, acute rejection, bacterial infection, CMV infection, chronic rejection, fungal infection

[Abstract:0912] PS-236 [Accepted:Poster Presentation] [Tobacco Control]

Comparison of psychological symptoms compared to daily cigarette consumption in smokers

Askin Gülsen¹, Bülent Uygur²¹Department of Pulmonary Diseases, Research Center Borstel, Borstel, Germany²Department of Psychiatry, Private Medifema Hospital, İzmir, Turkey

Objectives: Smoking tobacco has been found to be common among patients with psychiatric disorders like anxiety, depression, schizophrenia and affective disorders. Our aim in this study is to compare psychiatric symptoms with the daily amount of cigarette consumption and degree of nicotine addiction.

Methods: A cross-sectional study was designed. Group-1: 124 healthy active-smokers (66F/58M) and group-2: 127 healthy non-smokers (61F/66M) were recruited. The SCL-90-R (Symptom check list) and Fagerstrom Test (FT) was used to assess psychological symptoms and nicotine addiction level. Smoker was divided into 3 groups, light smokers (0-9), medium smokers (10-19) and heavy smokers (>20 cigarettes/day). Though SCL-90R shows significant relationships with the associated DSM-III-R/DSM-IV symptom disorders. The scores on the nine-symptom dimensions are expressed as a profile of symptoms, and scores >1 are suggestive of possible psychopathology. The global severity index (GSI) for SCL-90 is calculated as the average score of the 90 items of the questionnaire.

Results: Daily amount of cigarette consumption appears to a positive correlation with somatization, obsession, depression, and hostility (Figure-1). Nicotine addiction level shows a positive correlation with all psychological symptoms.

Conclusion: This study showed that, especially in patients with heavy smoker have increased psychiatric symptoms such as somatization, depression, hostility and paranoidideation. For this reason, we recommend that routinely perform these tests on patients who want to quit smoking.

Keywords: Psychological symptoms, SCL-90r, daily cigarette consumption, heavy smokers

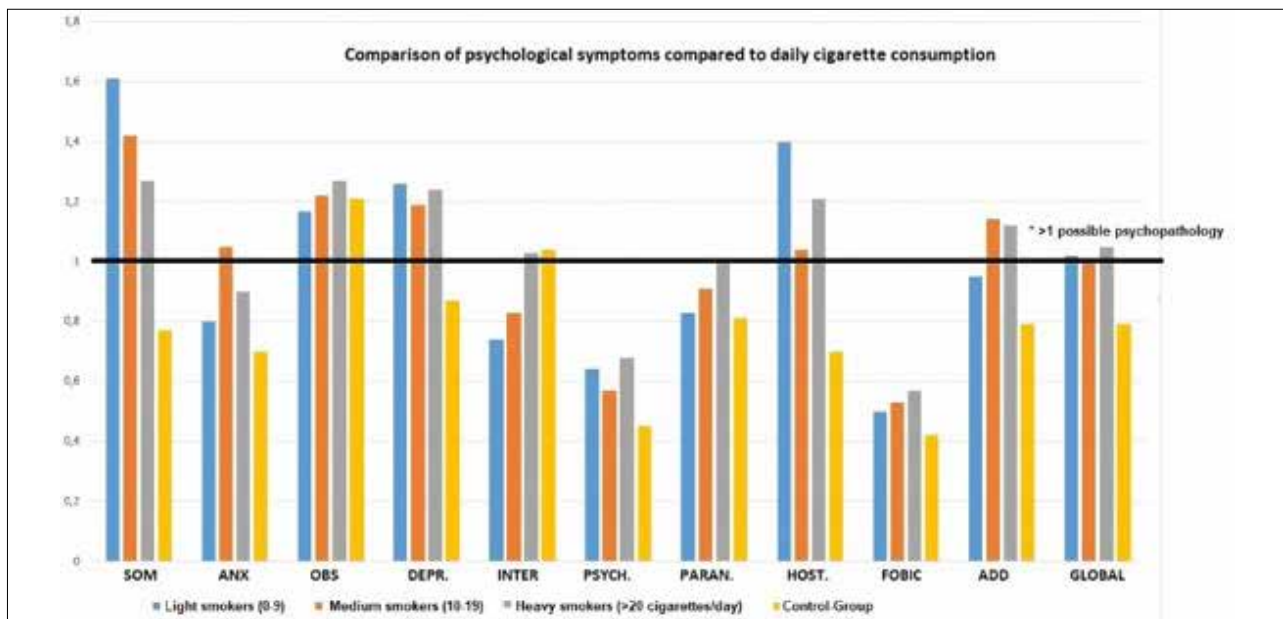


Figure 1. Comparison of psychological symptoms compared to daily cigarette consumption

[Abstract:0915] SS-147 [Accepted:Oral Presentation] [Tuberculosis]

Place and Importance of Genexpert MTB/RIF Test in Rapid Diagnosis of Tuberculosis and Rifampin Resistance

Şeref Özkara, İsmail Ceyhan, Müjgan Güler, Güngör Dulkar

Atatürk Chest Diseases and Thoracic Surgery Training and Research Hospital, Ankara, Turkey

Objectives: Rapid, highly sensitive and specific tests are important in tuberculosis (TB) diagnosis and drug resistance detection. Molecular methods are in the forefront today. Approved by WHO, GeneXpert test (GX) does not require molecular laboratory infrastructure; is approved by WHO and valuable in detecting *M. tuberculosis* complex (Mtb) and showing rifampin resistance (RR). Aim of this study is to (a) compare results of GX test and smear microscopy (SM), (b) analyse GX positive cases with RR in a laboratory of drug resistant TB treatment center.

Methods: Laboratory registers and patient files were examined retrospectively in Ankara Atatürk Chest Disease Hospital. Data are not patient based but are sample based. SM results compared with GX are the results at the same sample. In RR cases, patient based detailed evaluation was done.

Results: Results of 5,962 samples with GX results in the laboratory between February 2014-January 2018 are shown in Table 1. Results of samples which are GX positive, RR and susceptible compared by SM are shown in Table 2. Detailed results of 90 RR cases show better knowledge than individual sample results; drug resistance treatment decision was given in 73 cases with GX and although all SM results were negative TB diagnosis was established only by GX in 19 cases.

Conclusion: In cases of RR samples, GX helps to early bacteriological diagnosis, also early initiation of drug resistant TB treatment. With sample based evaluation GX detected TB bacilli in 270 SM negative samples; and in 96 SM positive case GX results were negative. Some of the SM positive, GX negative samples were non-TB Mycobacteria. GX test makes an important contribution to TB control by detecting Mtb and RR early so preventing transmission of the bacilli and helping initiation of appropriate treatment earlier.

Keywords: Tuberculosis, genexpert MTB/RIF, smear microscopy

Table 1. Comparison of GeneXpert results with Ehrlich Ziehl Neelsen (EZN) smear results

	Xpert positive	Xpert negative	Total
EZN positive	641	96	737
EZN negative	270	4.955	5.225
Total	911	5.051	5.962

Table 2. Comparison of rifampin resistant and susceptible samples found in GeneXpert test and smear microscopy Ehrlich Ziehl Neelsen (EZN) results

	Xpert positive, Xpert rifampin susceptible	Xpert positive, Xpert rifampin resistant	Total
EZN positive	641	96	737
EZN negative	270	4.955	5.225
Total	911	5.051	5.962

[Abstract:0920] EPS-295 [Accepted: E-Poster] [Tuberculosis]**Tuberculosis Among the Students**

Halina Baradzina

Belarusian State Medical University, Minsk, Belarus

Objectives: Tuberculosis in students of Minsk is observed rarely. The aim – identify the features and trends of tuberculosis incidence in the students of Minsk.

Methods: A total retrospective study of peculiarities of tuberculosis in students (n=22) in 2015-2016 was performed compared with a total group of 560 patients with tuberculosis. The structure of student's incidence rate of tuberculosis has been analyzed.

Results: Gender differences were revealed between students (m/f-10/12) and the general group of tuberculosis patients (m/f-394/66; $\chi^2=4.390$, $p=0.036$). The girls were slightly dominant in the group of students. Among the students, there were no persons under the age of 21 (mean age-24.2±1.1), although 50% of them studied at the 1st and 2nd courses. They entered the universities not immediately after graduation, but had the experience of previous work. The largest number of patients studied at the Technical University (18.4%). There weren't connection of the disease with low social-economic status, smoking in contrast to the general group of patients. Smoking among students (18.4%) was less common than in general group ($\chi^2=5.817$, $p=0.016$). Infiltrative tuberculosis dominated in both groups, there was no difference in incidence of bacterial excretion ($\chi^2=0.882$, $p=0.348$). 5 from 22 had family contact with tuberculosis, which more often than in the general group (52 of 560, $\chi^2=3.972$, $p=0.46$). Students without family tu-

berculosis contact were mostly male, studied in technical colleges (2nd course), lived in a hostel, had their own families, combined study with work (12 out of 17) and were smokers (4 out of 17). The difficulties of adapting to study in another city, combining study with work contributed to the endogenous reactivation of the pathogen. Multydrug resistant tuberculosis (MDR-TB) was observed in 9 of 17 cases. Students who have been exposed to tuberculosis, studied at different courses in various universities. In this subgroup, 4 out of 5 students were female ($\chi^2=0.714$, $p=0.134$), no one smoked, no one was married ($\chi^2=0.472$, $p=0.492$), did not work ($\chi^2=1.642$, $p=0.200$), all lived with their parents; MDR-TB was observed in 4 patients ($\chi^2=0.069$, $p=0.792$).

Conclusion: The results of the study provide a scientific basis for the further development of a set of measures aimed to improvement the diagnosis of tuberculosis among the students.

Keywords: Tuberculosis, students, incidence

Abstract:0923] PS-030 [Accepted:Poster Presentation] [Clinical Problems - Diffuse Parenchymal Lung Disease]

Demographic Analysis of Diffuse Paranchemal Lung Diseases Following Interstitial Lung Diseases Outpatients Clinics Between 2003-2018 Years

Güngör Çamsarı, Elif Yelda Özgün Niksarlıoğlu, Ayse Yeter, Gülşah Günlüoğlu, Gülcihan Ozkan, Nur Dilek Bakan, Gülten Emel Taş, Nagehan Orhan Ozer

Clinic of Chest Diseases, Yedikule Chest Diseases and Thoracic Surgery Training and Research Hospital, İstanbul, Turkey

Objectives: Diffuse parenchymal lung diseases (DPLD) include over 200 diseases. In this study, we aimed to investigate the demographic data, diagnostic methods and distribution of diseases that cases followed in the interstitial disease outpatients clinics between 2003 and 1818.

Methods: Between 2003 and 1818, 716 patients with diagnosis of DPLD were retrospectively reviewed. The age, gender, diagnosis and diagnostic methods of the patients were recorded and the distribution ratios were calculated.

Results: Of the 716 patients (age range 16-88 years) who were diagnosed with DPLD, 360 (50.2%) were female and 356 (49.8%) were male, sarcoidosis was the most common disease in our study group. The distribution of all patients according to diagnosis is as follows:

Sarcoidosis 251 (168 Female, 83 Male): 35%
 İdiopathic pulmonary fibrosis: 116 (34 Female, 82 Male): 16.2%
 Unclassified DPLD: 74 (35 Female, 39 Male): 13.3%
 Hipersensitivity pneumonistis: 68 (31 Female, 37 Male): 9.5%
 Collagen vascular diseases related DPLD: 57 (40 Female, 17 Male): 8%
 Pneumoconiosis: 47 (47 Male): 6.5%
 Other idiopathic ILD: 30 (16 Female, 14 Male): 4.2%
 Vasculitis: 14 (6 Female, 8 Male): 2%
 Drug related DPLD: 8 (4 Female, 4 Male): 1.1%
 Eosinophilic pneumonia: 7 (5 Female, 2 Male) : 1%
 Autoimmunity related ILD: 6 (4 Female, 2 Male): 0.8%
 P. alveolar microlithiasis: 4 (2 Female, 2 Male): 0.5%
 Palveolar proteinosis: 4 (2 Female, 2 Male): 0.5%
 Diffüse pulmonary ossification: 2 (1 Female, 1 Male): 0.3%

In all cases, diagnosis was made using different diagnostic methods and 98 cases (12.1%) were diagnosed by open lung biopsy or thoracoscopic biopsy.

Conclusion: Sarcoidosis was found to be the most common disease in our study group and it was compatible with the epidemiological data of our country. We think that rare diseases like DPLD might be follow in specific interstitial lung diseases outpatients clinics for close follow-up.

Keywords: Diagnosis, distribution, interstitial lung diseases

[Abstract:0926] SS-114 [Accepted:Oral Presentation] [COPD]**Disease-Cost Analysis in a Chest Disease Hospital**Ümit Tutar¹, Nejat Altıntaş², Fatma Esra Tutar³¹Department of Pulmonology, Health Sciences University Samsun Training and Research Hospital, Samsun, Turkey²Department of Chest Diseases, Tekirdag Namık Kemal University School of Medicine, Tekirdağ, Turkey³Samsun Health Department, Samsun, Turkey

Objectives: Our hospital is a branch hospital of thoracic diseases and thoracic surgery with a total capacity of 160 beds, including 13 intensive care units. This provides a more specific examination for respiratory diseases than the non-branch hospitals. In the literature, there is not any extensive cost analysis which is made in Turkey and in our hospital. Therefore, it was aimed to investigate the costs of hospitalized patients.

Methods: Hospital information management system's records of our hospital between 2005 and 2016 were retrospectively reviewed. Hospitalized patients were included in the study. Costs per patients were divided into three groups as drug, non-drug and total cost. Daily average costs were found by dividing each patient by the number of days of hospitalization, drug, and total costs. The days of hospitalization of all inpatients and diagnostic groups were collected and the total bed occupation day was found. Patients, whose total admission time was less than one day, whose diagnosis and any other demographic values were missing, the total cost of admission was not determined, and the total daily admission cost was less than 30 TL (Only the Social Security Institution's hospital daily admission fee was 30 TL).

Results: The average number of hospitalization days in the 45748 patients who were included in the study was 11. Their ages ranged from 13 to 107 and the mean of ages was 64 (Table 1). During study period, 467 (1.02%) patients were transferred out of institution due to developed additional diseases and/or complications and 698 (1.52%) patients lost their lives. Among all the inpatients, the number of COPD was 25141 (54.96%), Their total beds occupation day was 277.394 days and their cost was 50.924.982,15 TL (57.31% of total cost). Patients with pneumonia had the highest daily average drug cost with a value of 63,95 TL. Sarcoidosis had the highest non-medicinal cost value of 164,81 TL. Interstitial Lung Disease had the highest daily average total cost with a value of 221.95 TL. All groups and cost values are given in Table 2.

Conclusion: The COPD group was the cost leader of study with a total number of patients, total bed occupation day and total cost. All average cost values were above the study average costs. The percentage of referral and exitus were also highest in the COPD group. Although asthma was ranked second in the study, the number of patients, all average costs and average days of hospitalization (10 days) were below the study values. In our study, lung tuberculosis was the group with the highest total hospitalization day (21 days). The diagnoses of COPD, asthma and pneumonia accounted for approximately 88% of all studies.

Keywords: Asthma bronchiale, chest disease, daily cost, copd, pneumonia, TL

Table 1. The Distribution of Patients According to Years

Disease	Total Number	Average Age	Average Hospital Day	Male (%)	Female (%)	Total Percentage (%)
Lung Tuberculosis	2604	46	21	4,08	1,61	5,69
Asthma Bronchiale	9106	60	10	2,64	17,26	19,90
Bronchiectasis	677	54	11	0,72	0,76	1,48
Interstitial Lung Disease	332	65	11	0,39	0,34	0,73
COPD	25141	69	11	47,10	7,86	54,96
Pleural Effusion	1023	59	11	1,42	0,82	2,24
Pneumonia	6243	58	10	8,51	5,14	13,65
Pulmonay Thromboembolism	537	60	10	0,47	0,70	1,17
Sarcoidosis	85	52	12	0,03	0,15	0,18
Total	45748	64	11	65,36	34,64	100

Table 2. Cost Table by Disease Diagnosis (TL)

Disease	Number of Patients	Average Hospital Day	Total Admission Date and Percentage	Daily Average Drug Cost	Non-medicinal Cost	Daily Average Total Cost
Lung Tuberculosis	2604	21	54561 (% 10,68)	17,71	88,20	105,91
Asthma Bronchiale	9106	10	87414 (% 17,12)	58,62	123,40	182,02
Bronchiectasis	677	11	7697 (% 1,57)	60,61	118,99	179,60
Interstitial Lung Disease	332	11	3636 (% 0,71)	59,38	162,57	221,95
COPD	25141	11	277394 (% 54,31)	60,34	130,72	191,06
Pleural Effusion	1023	11	11127 (% 2,18)	55,55	152,61	208,15
Pneumonia	6243	10	62293 (% 12,20)	63,95	147,77	211,72
Pulmonay Thromboembolism	537	10	5591 (% 1,09)	52,17	149,89	202,06
Sarcoidosis	85	12	1031 (% 0,20)	41,57	164,81	206,37
Total	45748	11	510744	57,82	130,00	187,82

[Abstract:0928] EPS-093 [Accepted: E-Poster] [Lung and Pleura Malignancies]

A Rare Cause of Posterior Mediastinal Mass: Adenoid Cystic Carcinoma Metastasis

Özgür İşgörücü¹, Necati Çıtak¹, Selçuk Köse¹, Barış Açıkmeşe²

¹Department of Chest Surgery, Bakırköy Dr. Sadi Konuk Training and Research Hospital, İstanbul, Turkey

²Department of Chest Diseases, Bakırköy Dr. Sadi Konuk Training and Research Hospital, İstanbul, Turkey

Introduction: Adenoid cystic carcinomas (ACCs) usually originate from the major and minor salivary glands. Although local recurrence is reported in 10% of cases, bones and lungs are the areas of distant metastases. Here, we present our case diagnosed with extrapulmonary ACC metastasis localized in posterior mediastinum.

Case Presentation: Posterior mediastinal mass was detected in the examination performed due to back pain in the 49-year-old female patient. Three years ago, she was operated on due to adenoid cystic carcinoma originating from parotid. The SUV max value of the mass was 1.4 in the patient who underwent PET CT scan. The mass that was resected using videothoracoscopy was found to be extrapulmonary. Pathology was reported as a solid pattern of adenoid cystic carcinoma. Subsequently, chemoradiotherapy was performed in the patient in whom the complication of postoperative horner syndrome developed. There was no recurrence during the 15-month follow-up.

Conclusion: The most common causes of posterior mediastinal masses are neurogenic tumors or the pathologies of posterior mediastinal structures. The most common metastasis sites of adenoid cystic carcinoma are the lung and bone. Primary and metastatic ACCs invading the mediastinum secondary to peripheral lung or trachea localisation have been reported in the literature. In our extrapulmonary ACC case with posterior mediastinal localization, the metastasis may have occurred via the direct invasion of the metastatic neck structures, neurogenic spread, or hematogenous spread. Radical surgical resection is recommended in ACC. Careful clinical and radiological evaluation is necessary to treat such rare mediastinal masses.

Keywords: Posterior mediastinum, adenoid cystic carcinoma, metastasis

[Abstract:0929] PS-279 [Accepted:Poster Presentation] [Sleep-related Disorders]

OSAS in a Case with Mucopolysaccharidosis

Nurgul Naurzvai, Nilgün Yılmaz Demirci, Nurdan Köktürk, Oğuz Köktürk

Gazi University School of Medicine, Ankara, Turkey

Mucopolysaccharidosis (MPS) is a lysosomal storage disease that is autosomal recessively inherited and characterized by the accumulation of mucopolysaccharides in cells as a result of the inability to produce or inadequate production of some enzymes in the body. Seven subtypes which are grouped according to deficient or inadequate enzymes have been defined. MPS Type III or in other words, Sanfilippo has four subtypes as A, B, C and D. The difference among these four types stems from the mutations occurring in different regions of the gene that enables specific enzymes to be produced. Sanfilippo Type B occurs due to the mutation in the gene that produces the enzyme alpha-N-acetylglucosaminidase which is required to break down the mucopolysaccharide structure. Too much mucopolysaccharide accumulates in the body of these patients. It is seen in the society at a frequency of 1-9/1000000. The mean life span of Sanfilippo type B patients is 23.43±9.47 years. Patients have a normal appearance at birth but as the number of damaged cells increases, signs and symptoms of the disease begin to appear. The indications are progressive and are divided into stages depending on the time of occurrence. In the first stage, speaking skills delay in a child affected by the disease and changes begin to appear in the face. In the next stage, hyperactivity, uneasiness, insomnia, and difficulty in movement occur. Speaking and understanding deteriorate over time. In most patients, advanced mental retardation develops towards the age of 6. The movements of children who get this disease until the age of ten become very restricted. In the last stage, the child becomes motionless and unresponsive to stimuli in general. Respiratory infections, primarily pneumonia, are the most common causes of death at early ages in patients. Obstructive sleep apnea syndrome (OSAS) developing due to craniofacial abnormalities and MPS accumulation in the upper and middle airway soft tissues is frequently reported in these patients who usually die because of various complications before reaching adult ages. However, it does not come to mind in the foreground. A 22-year-old female patient diagnosed with Sanfilippo type B was brought by her mother because of wheezy breathing that increased especially at nights and

insomnia. Upper and lower respiratory tract diseases and cardiovascular system diseases in the patient were excluded by specific laboratory tests, ECHO and lung tomography. Except for the post nasal discharge, no pathology was found in the patient who was examined by the otolaryngology department in terms of aspiration. The patient who had advanced mental retardation due to the progression of the disease and who had no other known disease history except for cholecystectomy 2 years ago was suspected to have OSAS disease due to typical facial and short neck structure, and PSG test was performed in the patient. The patient in whom AHI 9.5 was detected was diagnosed with OSAS. This rare case was presented with the reason that it was interesting.

Keywords: Sanfilippo type B, mucopolysaccharidosis, OSAS, lysosomal storage disease

[Abstract:0932] SS-067 [Accepted:Oral Presentation] [Health Policies]

Determination of Attitudes of Turkish Thoracic Society Members on Exposure to Sexist Approach and Sexism in Business Life

Birsen Ocaklı¹, Arzu Yorgancıoğlu², Füsün Topçu³, Nurdan Köktürk⁴, Hilal Altınöz¹, Yeşim Yasin⁵, İlknur Genç Kuzuca⁶, Serap Duru⁶, Elif Özari Yıldırım¹, Tülin Sevim¹, Eylem Acartürk Tunçay¹, Sinem Güngör¹, Başak Göktaş⁷, Yeşim Yiğiter Şenol⁷, Cansel Atinkaya Öztürk¹, Ipek Özmen¹, Yeşim Yasin⁵, Çağla Pınar Taştan⁸, Yelda Varol⁹, Esra Uzaslan¹⁰, Fatma Erboy¹¹, Bilun Gemicioğlu¹², Bülent Karadağ¹³, Özlem Erçen Diken¹⁴, Elif Yelda Niksarlıoğlu¹⁵, Emine Aksoy¹⁶, Seyhan Dülger¹⁷, Feride Taşkın Yılmaz¹⁸, Yasemin Karabacakoğlu¹⁹, Serap Duru²⁰, Hülya Yolaçan²¹, Pınar Yıldız Gülhan²², Nursel Dikmen²³, Olcay Ayçiçek²⁴, A. Füsün Topçu²⁵, Şebnem Yosunkaya²⁶, Nursel Türkoğlu²⁷, Gülru Polat²⁸, Buğra Kerget²⁹, Rabia E. Ünver³⁰, Münevver Mertsoylu³¹, Ayşegül Güzel³², Adalet Demir³³, Gülay Özbilim³⁴, Pınar Çelik³⁵, Füsün Yıldız³⁶, Fatma Erboy³⁷, Ahmet Uğur Demir³⁸, Salih Topçu³⁹, Göksel Altınışik⁴⁰, Neşe Dursunoğlu⁴¹, Nagehan Emiralioğlu⁴², Lütfiye Kılıç⁴³, Ali Kocabaş⁴⁴, Füsün Ö. Eyüboğlu⁴⁵, Ezgi Özyılmaz⁴⁶, Gaye Ulubay⁴⁷, Serir Özkan⁴⁸, Pelin Duru Çetinkaya⁴⁹, Pınar Pazarlı⁵⁰, Sebahat Genç⁵¹

¹University Health Sciences İstanbul Sureyyapaşa Chest Diseases and Thoracic Surgery and Training Hospital, İstanbul, Turkey

²Department of Chest Diseases, Celal Bayar University School of Medicine, Manisa, Turkey

³Department of Chest Diseases, Dicle University School of Medicine, Diyarbakır, Turkey

⁴Department of Chest Diseases, Gazi University School of Medicine, Ankara, Turkey

⁵Department of Public Health, Acıbadem University School of Medicine, İstanbul, Turkey

⁶Atatürk Chest Diseases and Thoracic Surgery and Training Hospital, Ankara, Turkey

⁷Department of Public Health, Akdeniz University School of Medicine, Antalya, Turkey

⁸Bakırköy Doctor Sadi Konuk Education and Research Hospital, İstanbul, Turkey

⁹Dr. Suat Seren Chest Diseases Hospital, İzmir, Turkey

¹⁰Uludağ University, Bursa, Turkey

¹¹Zonguldak Bülent Ecevit University, Zonguldak, Turkey

¹²İstanbul Cerrahpaşa Medical Faculty, İstanbul, Turkey

¹³Marmara University, Pendik Education Research Hospital, İstanbul, Turkey

¹⁴Hitit University School of Medicine, Çorum, Turkey

¹⁵Health Sciences University, Yedikule Chest Diseases and Thoracic Surgery Training and Research Hospital, İstanbul, Turkey

¹⁶Health Sciences University İstanbul Süryapaşa Chest Diseases and Chest Surgery Training And Research Hospital, İstanbul, Turkey

¹⁷Şevket Yılmaz Training and Research Hospital, Bursa, Turkey

¹⁸Cumhuriyet University School of Medicine, Sivas, Turkey

¹⁹Department of Chest Diseases, Antalya Training and Research Hospital, Antalya, Turkey

²⁰Health Sciences University Dışkapı Yıldırım Beyazıt Research and Training Hospital, Ankara, Turkey

²¹Eskişehir Yunus Emre State Hospital, Eskişehir, Turkey

²²Tosya State Hospital, Kastamonu, Turkey

²³Mustafa Kemal University, Hayat, Turkey

²⁴Dr. Ali Menekşe Chest Diseases Hospital, Giresun, Turkey

²⁵Dicle University School of Medicine, Diyarbakır, Turkey

²⁶Necmettin Erbakan University, Meram Medicine Faculty, Konya, Turkey

²⁷Antalya Training and Research Hospital, Antalya, Turkey

²⁸Health Sciences University, Dr Suat Seren Chest Disease and Thoracic Surgery Research and Training Hospital, İzmir, Turkey

²⁹Erzurum Nihat Kitapçı Chest Diseases and Thoracic Surgery Hospital, Erzurum, Turkey

- ³⁰Orhangazi State Hospital, Bursa, Turkey
³¹Kayseri Medical Palace Chest Diseases Hospital, Kayseri, Turkey
³²Ondokuz Mayıs University School of Medicine, Samsun, Turkey
³³Department of Thoracic Surgery, İstanbul University School of Medicine, İstanbul, Turkey
³⁴Akdeniz University Hospital, Antalya, Turkey
³⁵Manisa Celal Bayar University School of Medicine, Manisa, Turkey
³⁶Kocaeli University School of Medicine, Kocaeli, Turkey
³⁷Zonguldak Bülent Ecevit University, Zonguldak
³⁸Hacettepe University School of Medicine, Ankara, Turkey
³⁹Kocaeli University School of Medicine, Kocaeli, Turkey
⁴⁰Pamukkale University School of Medicine, Denizli, Turkey
⁴¹Pamukkale University School of Medicine, Denizli, Turkey
⁴²Health Sciences University, Yedikule Chest diseases and Thoracic Surgery Training and Research Hospital, İstanbul, Turkey
⁴³Health Sciences University, Yedikule Chest diseases and Thoracic Surgery Training and Research Hospital, İstanbul, Turkey
⁴⁴Çukurova University School of Medicine, Adana Turkey
⁴⁵Başkent University School of Medicine, Ankara, Turkey
⁴⁶Çukurova University School of Medicine, Adana Turkey
⁴⁷Başkent University School of Medicine, Ankara, Turkey
⁴⁸Health Sciences University, Dr Suat Seren Chest Disease and Thoracic Surgery Research and Training Hospital, İzmir, Turkey
⁴⁹Adana Numune Training and Research Hospital, Adana, Turkey
⁵⁰Sakarya University Health Faculty and Medicosocial Center, Sakarya, Turkey
⁵¹Dokuz Eylül University School of Medicine, İzmir, Turkey

Objectives: Like every field, approaches leading to discrimination based on gender in medicine; may affect vocational and academic career, physician/physician, patient/physician, other healthcare worker/physician relations and social life. The aim of this study is to determine the opinions of the Turkish Thoracic Society (TTS) Members in Gender Context and To Examine The Gender Discrimination Using Quantitative Methods

Methods: A cross-sectional study. Study population are TTS members working at pulmonology, other medical fields and thoracic surgery. Questionnaires were sent to TTS members through social network between January 14th and February 2nd of 2018. The questionnaire was taken from a physician thesis, at the Akdeniz University School of Medicine, Public Health Division, the section titled "Suggestions about the situation of the research assistants on exposure to Sexuality in Work Life". There were 37 questions in the survey. the queries related to exposure to sexism in the workplace are dependent and the socio-demographic characteristics and features related to work life are independent variables.

Results: The survey was shared with 3454 members and filled out by 209. The participation rate was 6.05%. 69.38% were male, 77.5% were married, 22.5% were single and 64.6% were 44 years of age or younger. The 71.77% worked in pulmonology, 20.16% in thoracic surgery and 8.13% in other internal medical sciences. Female physicians reported higher rates of gender-based discrimination in work life compared to male (86.4% vs 13.5%). For the suggestion that women may not be successful in surgical fields it was shown that the male participation was higher. Female and male physicians participated to a large extent (66.5%), that social roles are in no small measure in choosing the specialty of female physicians. Both sexes have participated in high ranks (female physicians 93.1%, male physicians 70.3%) to emphasize that housework is a burden for female physicians. Other findings were; the physical characteristics affected medical profession and the female physicians are obliged to sacrifice in the work life, because of their gender.

Conclusions: The fact that female physicians have more gender-based family roles than males, puts pressure on their role in the workplace and can be decisive in the academic career of female physicians. Although the female physicians do not have legal obstacles in choosing surgical branches that men are dominant, it is striking that their specialty areas are sexually indexed. These results are preliminary for our work relating to the gender inequality.

Keywords: Gender, gender inequality, medical profession, female physician, sex

[Abstract:0933] SS-108 [Accepted:Oral Presentation] [Clinical Problems - Diffuse Parenchymal Lung Disease]

The Comparison of GAP Score and Six Minute Walk Test in Patients with Interstitial Lung Disease; Lets Look Closer to Six Minute Walk Test

Elif Yıldırım, İpek Özmen, Meral Karakış, Reyhan Yıldız, Tülin Sevim, Lale Sertçelik, İpek Erdem, Armağan Hazar, Murat Kavas, Sibel Boğa, Özlem Soğukpınar, Baran Gundoğu, Hatice Türker, Esin Sonkaya, Fatma Özbaki, Tülay Törün

Health Sciences University, İstanbul Süreyyapaşa Chest Disease and Thoracic Surgery Training and Research Hospital, İstanbul, Turkey

Objectives: Physiopathologic events that occur in interstitial lung disease (ILD) are limited endurance exercise capacity, of which clinical reflection is decrease in the expected walking distance in the six minute walk test (6MWT). Despite frequent use in clinics, the prognostic value of 6DYT is limited. In this study, we aimed to investigate the association between the first desaturation of the 6MWT and Gender-Age-Physiology (GAP) Index in patients with ILD.

Methods: The 6MWT, of patients with ILD who were followed by different clinics, were performed in pulmonary rehabilitation unit. walking distances, O₂ saturation, desaturation during 6MWT and GAP index recorded between 2016-2017 were evaluated retrospectively.

Results: A total of 69 patients, 57 % male with the mean age 62±10 were enrolled in the study. The mean FVC 2.26±0.8 (% 73±16.3) and DLCO were 55.04±21.25 %The GAP index was 2±1, the mean walking distance was 411±107m, the mean distance that first desaturation during the test, was recorded was 124.8±120m. There was a strong correlation between the distance that first desaturation during the test and GAP index ($p \leq 0.0001$).

Conclusion: As a result, when the data obtained with 6MWT is elaborated, important markers can be obtained in determining the prognosis. In this regard, the distance when the first desaturation was recorded may be a stronger determinant instead of total walking distance.

Keywords: Interstitial lung disease, six minute walk test, gap score

[Abstract:0934] EPS-231 [Accepted: E-Poster] [Thoracic Surgery]

Lung Adenocarcinoma with Multiple Foci Radiologically Mimicking Miliary Tuberculosis

Volkan Yılmaz, Sezer Aslan, Ayşen Taslak Şengül, Ahmet Başoğlu

Department of Thoracic Surgery, Ondokuz Mayıs University, Samsun, Turkey

In this case, miliary tuberculosis and thyroid carcinoma metastasis were considered who has cough and haemoptysis complaints 9 months after thyroidectomy due to papillary thyroid carcinoma. Conventional diagnostic procedures and trans-bronchial biopsy did not provide definitive diagnosis. We present a patient with a solid patterned dominant multifocal lung adenocarcinoma with videothoroscopic wedge resection. A 62-year-old hypertensive female patient with thyroidectomy diagnosed with papillary thyroid carcinoma underwent RAI and presented with cough and hemoptysis at 9th postoperative month. Chest X-ray and thorax CT showed multiple nodules 1 cm in diameter in both lungs (Figure 1). Endobronchial pathology was not detected on bronchoscopy and bilateral distal biopsy and cytology reported as tumor negative and tuberculosis PCR reported negative. Chest X-ray of the patient 1 year before was evaluated as normal (Figure 2). PET CT showed the largest 23x18 mm SUVmax 3.0-8.8 multiple metastatic nodule widely distributed in the miliary style in both lungs. SPECT CT reported as all body scan findings without iodine positive focus (There is no stimulated Tg positivity or iodine positive focus favorably on thyroid Ca) and the patient underwent left lung lingular segment wedge resection with videothoracoscopy for diagnostic purposes (Figure 3). Pathology of the discharged patient on the third postoperative day was reported as pulmonary adenocarcinoma with multiple foci predominantly aciner pattern. In the Oncology Council, Cyber Knife and Erlotinib treatment decision was taken for patient who was found to have a lesion compatible with the metastasis. Metastasis was not observed in control Brain MR of the patient after Cyber knife. On the postoperative 6th month follow-up of the patient who continued regularly with Erlotinib treatment, PET CT showed suspicious areas (residual malignancy?) in terms of micronodensity in both lungs. The activity of the left lower paratracheal lymph node was assessed as decreased. There have been reports in the literature of organizing pneumonia, pulmonary fibrosis, multiple cavitory lesions, interstitial lung disease. In our case, bilateral multiple nodular lesions were observed and pathology was adenocarcinoma. Parenchymal biopsy with videothoracoscopy is required to obtain larger material at the definite diagnosis. As a result, clinical suspicion is very important in the diagnosis of pathologies with common bilateral pulmonary involvement that may interfere with many benign diseases and should be the result without avoiding invasive diagnostic methods.

Keywords: Adenocarcinoma, lung, miliary, tuberculosis

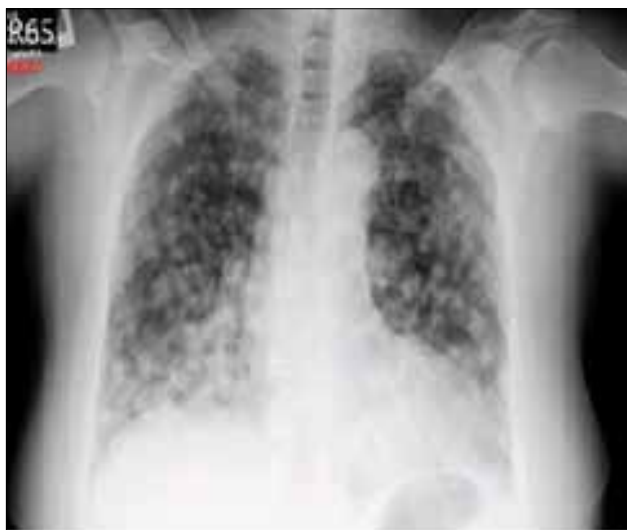

Figure 1. Multifoci nodul chest X-Ray

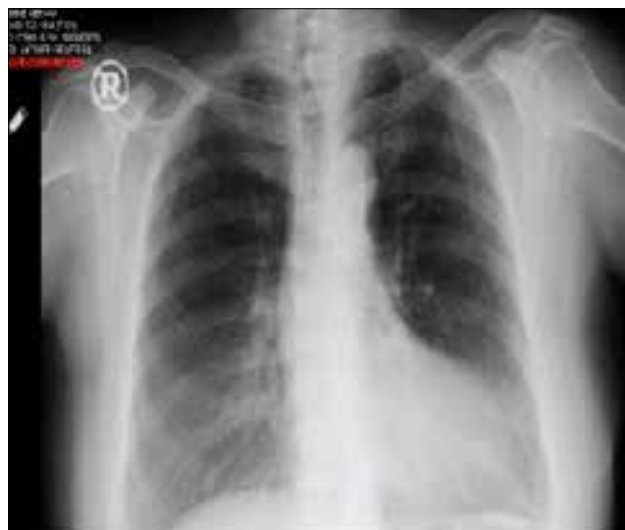

Figure 2. A year ago chest X-Ray scan

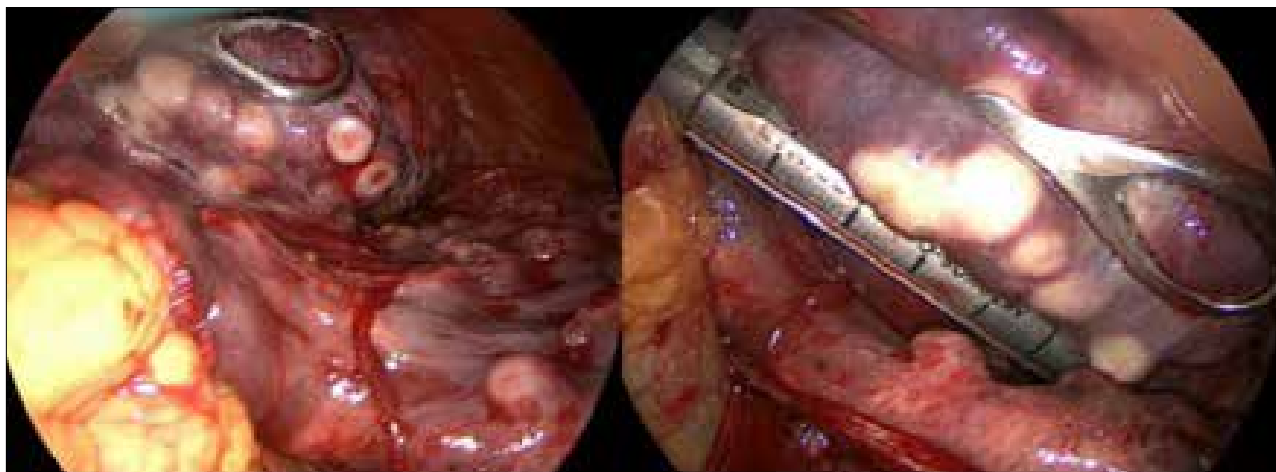


Figure 3. Thoracoscopic images of nodules

[Abstract:0937] PS-224 [Accepted:Poster Presentation] [COPD]

Differences in Medication Adherence in Chronic Obstructive Pulmonary Disease Associated with Beliefs on Medications

Hüseyin Arkan¹, Dildar Duman², Zeynep Uslu¹, Derya Kocakaya¹, Emel Eryüksel¹

¹Department of Pulmonary and Critical Care Medicine, Marmara University School of Medicine, İstanbul, Turkey

²Health Sciences University, Süreyyapaşa Chest Diseases and Chest Surgery Training and Research Hospital, İstanbul, Turkey

Objectives: Medication adherence is crucial for symptom control in chronic obstructive pulmonary disease (COPD). This study examines the association between medication-related beliefs and self-reported compliance in patients with COPD.

Methods: Patients who were diagnosed with COPD and who were on medication for COPD for at least one year were included in the study. Participants in the study completed a questionnaire including the Belief on Medicines Questionnaire (BMQ) and the Morisky Medication Adherence Scale (MMAS). BMQ consists of two parts, specific and general. The specific part measures the patients' "need" and "concern" about the medications. The general part measures "overuse" and "harm" considerations.

Results: 182 patients participated in the study and 144 (79.1%) of them were male. The average age was found as 62.9±10.6. Full compliance with the medications was 11% with 20 patients and low compliance with 100 patients was 54.9%. There

was a positive correlation between the specific-necessity score of BMQ scale and medication adherence ($r=0.219$, $p=0.003$). There was a negative correlation between the specific-concern score of the BMQ scale and drug compliance ($r=-0.2$, $p=0.007$). There was no correlation between general subgroups of the BMQ scale and drug compliance.

Conclusion: Findings from this study suggest that patients' beliefs about the necessity of medications are an important changeable target to improve medication adherence in patient-doctor consultations.

Keywords: COPD, medication adherence, beliefs

[Abstract:0939] PS-195 [Accepted:Poster Presentation] [Pediatric Pulmonary Diseases]

Respiratory Papillomatosis and Immunodeficiency

Şükrü Nail Güner¹, Sevgi Pekcan², İsmail Reisli¹, Sevgi Keleş², Eda Zeynep Büyükkaya¹

¹Department of Pediatrics, Necmettin Erbakan University Meram School of Medicine, Konya, Turkey

²Department of Pediatric Chest Diseases, Necmettin Erbakan University Meram School of Medicine, Konya, Turkey

We reported the relationship between immunodeficiency and juvenile laryngeal papillomatosis in patients of pediatric age group. A 5-year-old girl was referred from the external center with the suspicion of bronchiectasis. Tomography was reported as fibrotic changes due to necrotizing pneumonia. Atypical facial appearance and bilateral rales and rhonchi were observed in the physical examination. It was found out that she had frequent upper respiratory tract infections. Immunological tests were performed due to the history of recurrent lung infection. Flexible bronchoscopy was performed under general anesthesia, showing that both vocal cords and the upper 1/3 of the trachea were normal. The papillousicular lesions extended from the trachea to the right main bronchus. Some parts of the lesions looked like bunches. Swab and lavage samples were examined for HPV6 and HPV-11. Sweat and nasal saccharin tests were performed. The result of sweat test was 24 mEq / L (>60 mEq/L positive). Bitter taste was obtained with nasal saccharin test in five minutes. In peripheral blood lymphocytes, the numbers of CD 16 (+) and CD 56 (+) lymphocytes and immunoglobulins, especially IgG3 (11 mg/mL) were found to be low in immunologic tests. Intravenous immunoglobulin therapy was initiated and the patient was investigated for immunodeficiency and genetics. From the patient's lavage sample, HPV PCR was sent to the external center. The result is being waited for. Acyclovir treatment was started in this process. Juvenile laryngeal papillomatosis can manifest itself with cough, stridor, coarse voice or dysphagia and pneumonia. Laryngeal papillomatosis is the most common benign laryngeal tumor in children. It is usually diagnosed before the age of five. It is thought that human papilloma virus (HPV) is infected through vertical transmission from the infected mother during birth. Genetic variability associated with the immune system can be one of the most effective factors in the development of HPV. We found this case interesting because of the presence of papilloma and immunodeficiency.

Keywords: Papilloma, HPV, immunodeficiency

[Abstract:0948] EPS-016 [Accepted: E-Poster] [Clinic Problems - Others]

Postoperative Care: The Most Common Pulmonary Problems, Causes and Solutions

Fatma Erboy, Bülent Altınsoy, Müge Meltem Tor

Department of Pulmonary Medicine, Bulent Ecevit University School of Medicine, Zonguldak, Turkey

Objectives: As well as preoperative evaluation and surgery, postoperative care also affects surgical success, recovery time, complication risk, mortality and morbidity. In this study, we aimed to analyze the patients consulted for postoperative pulmonary complications in our hospital and discuss the most frequent postoperative pulmonary problems and their solutions.

Methods: Data of patients consulted for postoperative pulmonary complications between June 2017 and December 2017 within postoperative 10 days were analyzed retrospectively. Age, gender, consulting department, type of surgery, postoperative day for consultation, laboratory data, diagnosis of pulmonary physician, comorbidities were recorded. Consecutive consultations of same patient were assumed as continuation of the initial consultation. Primary pulmonary problem was identified according to pulmonary physician's consultation note. Data were recorded to SPSS 18.0 and analyzed.

Results: In study period, 76 patients were consulted for pulmonary problems within postoperative 10 days. 52.6% of patients were males (n=40/76) and the mean age was 61.77 ± 16.44 (min 19, max 92). Mean period for the consultation was 2.68 ± 2.14 (min 0, max 8) days postoperatively. Most common reason for consultation was hypoxia and/or desaturation (n=37/76, 48.7%), followed by dyspnea and/or respiratory distress (n=17/76, 22.4%). After pulmonary physician's initial evaluation, 37 patients were noted to have fluid overload which is further noted as major cause of pulmonary symptoms in 34 patients (44.7%). In total, 17 patients had infectious problems (22.3%) including 2 patients with upper respiratory tract infection, 13 patients with pneumonia and 2 patients with non-pulmonary sepsis. In 10 patients (13.1%) asthma or COPD exacerbation was recorded but bronchospasm was also recorded in 8 patients with infection and excessive pulmonary secretion (10.5%). 6 patients had atelectasis and 3 patients had pulmonary embolism. Two most frequent consulting departments were general surgery and orthopedic surgery. Major cause of postoperative pulmonary problems was fluid overload for general surgery patients (n=13/24, 54.2%). In orthopedic surgery patients causes of postoperative pulmonary problems were fluid overload (n=6/16, 37.5%) followed by pulmonary secretion, atelectasis and pulmonary contusion. Surprisingly, 55.3% of 76 patients had no pulmonary consultation preoperatively. These patients were thought to have low or no risk of perioperative pulmonary problem but they were not.

Conclusion: Postoperative care is as important as surgical procedure. A balanced fluid therapy according to need of patient and avoiding from fluid overload will reduce postoperative pulmonary complications. Continuation of bronchodilator treatment, respiratory physiotherapy, breathing exercises, pain control, infection control and appropriate antibiotherapy should be important components of postoperative care, starting from the preoperative period.

Keywords: Postoperative care, pulmonary complication, surgery, fluid overload