





## Case Report

# COVID-19 Pneumonia and Idiopathic Pulmonary Fibrosis: A Novel Combination

Fatma Işıl Uzel , Sinem İliaz , Ferhan Karataş , Benan Çağlayan 

Department of Pulmonology, Koç University Hospital, İstanbul, Turkey

**Cite this article as:** Uzel FI, İliaz S, Karataş F, Çağlayan B. COVID-19 pneumonia and idiopathic pulmonary fibrosis: A novel combination. Turk Thorac J 2020; 21(6): 451-3.

## Abstract

Coronavirus disease 2019 (COVID-19) has become a game changer in many aspects of clinical practice. Acute exacerbations of idiopathic pulmonary fibrosis (IPF) are known as serious events, which can reach a mortality rate of 50%, where viral infections may play a role. We describe the case of a 64-year-old male patient with a diagnosis of IPF under antifibrotic treatment for 1 year; the patient tested positive for COVID-19 with polymerase chain reaction test of the nasopharyngeal swab, and his chest computed tomography results were compatible with COVID-19 pneumonia described in the literature as well as the findings compatible with interstitial lung disease. The patient was successfully treated in the pulmonology ward according to official guidelines about COVID-19 along with antifibrotic treatment and required only a short course of oxygen therapy. We experienced no drug interactions, serious side effects, or complications during treatment. The patient was discharged after 1 week, and he is still in a good condition after 3 weeks. COVID-19 pneumonia in a patient with IPF who survived under antifibrotic treatment without serious deterioration is a new experience. Such cases will probably change our perspective in treating patients with IPF.

**KEYWORDS:** COVID-19, idiopathic pulmonary fibrosis, exacerbation

**Received:** May 30, 2020

**Accepted:** September 14, 2020

## INTRODUCTION

Idiopathic pulmonary fibrosis (IPF) is a specific form of chronic, progressive, fibrosing interstitial pneumonia of unknown cause. It occurs primarily in older adults, is limited to the lungs, and is defined by the histopathologic and/or radiologic pattern of usual interstitial pneumonia (UIP) [1]. It is a disease with a generally unpredictable course worsened by acute exacerbations, where treatment options are limited. The optimal management of IPF is often complex and requires a multidimensional approach [2]. There are currently no available data about the management of patients with IPF experiencing coronavirus disease 2019 (COVID-19) pneumonia. There are only some recommendations for patients with IPF in case they encounter with COVID-19 infection [3]. Suggestions relying on the experience with severe acute respiratory syndrome (SARS) and Middle East respiratory syndrome (MERS) are drawn to guide the way to optimally follow up with patients who recover from COVID-19 pneumonia [4], but no patients with IPF are yet included in such studies.

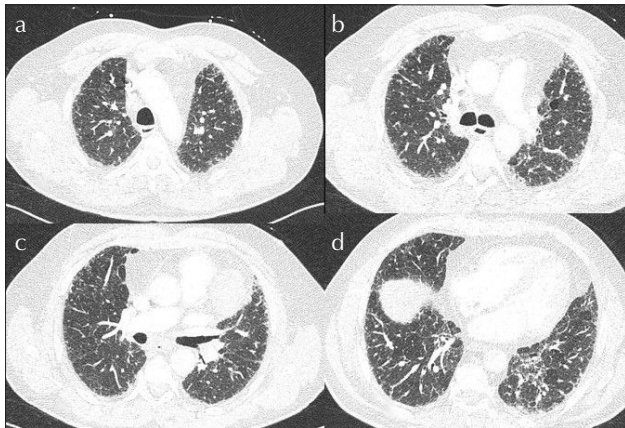
## CASE PRESENTATION

Here we describe a case of a 64-year-old male patient who presented to our pulmonology clinic in January 2019 with complaints of dry cough and shortness of breath, which continued for 4 months despite antibiotic treatment. He had no history of atopy and previous lung disease. His smoking history was 20 pack-years, and he had stopped smoking 28 years before. He described no indoor exposure to chemicals and organic material. He had hypertension and was using candesartan with hydrochlorothiazide. His physical examination revealed clubbing in both hands and bilateral "Velcro-type" crackles. Forced vital capacity (FVC) was 60%, and diffusion capacity for carbon monoxide was 63%. He walked 434 m in the 6-min walking test with a drop in oxygen saturation from 97% to 91%. Antinuclear antibody, antineutrophil cytoplasmic antibodies profile, and anticyclic citrullinated peptide results were negative. In the multidisciplinary discussion for diagnostic decision making, high-resolution computed tomography (CT) features of the patient were found compatible with those of the UIP pattern with septal thickening, honeycombing, tract, bronchiectasis, and no ground-glass opacities (Figure 1. a-d), and the diagnosis of IPF was accepted. He was found suitable for antifibrotic therapy, and nintedanib treatment of 150 mg twice daily was started in March 2019. He experienced diarrhea as a side effect, and this was controlled with short-term course of lopermid. After completion of the first year of treatment, FVC was 62%, and the criteria for the continuation of treatment were fulfilled; therefore, we continued treatment with 150-mg nintedanib twice daily. The first case of COVID-19 in Turkey was reported on March 11, 2020. On March 27,

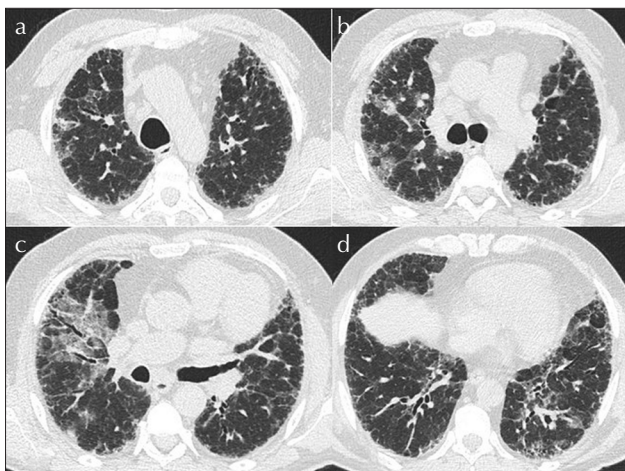
**Address for Correspondence:** Fatma Işıl Uzel, Department of Pulmonology, Koç University Hospital, İstanbul, Turkey

E-mail: uzelisil@gmail.com

©Copyright 2020 by Turkish Thoracic Society - Available online at [www.turkthoracj.org](http://www.turkthoracj.org)



**Figure 1. a-d.** Thoracic HRCT showing septal thickening, Traction bronchiectasis and honeycombing but no ground glass opacities at the time of IPF diagnosis



**Figure 2. a-d.** Thoracic HRCT showing ground glass densities that are more prominent in the right lung upper lobe in both lungs (compatible with Covid-19 pneumonia described in the literature) plus findings compatible with interstitial lung disease (UIP pattern).

2020, the patient attended our emergency department with complaints of fever (38.4°C) and worsening dyspnea and cough for 3 days. He was undergoing nintedanib treatment. He was in a good condition with a respiratory rate of 18/min and oxygen saturation of 96% while breathing the room air. Bilateral basilar “Velcro-type” crackles were present. He had no tachycardia and arrhythmia and was normotensive. The corrected QT interval was 425 ms. His chest CT revealed ground-glass densities that were more prominent in the right lung upper lobe in both the lungs (compatible with COVID-19 pneumonia described in the literature) as well as findings compatible with interstitial lung disease (UIP pattern) in both the lungs (Figure 2a-d). Nasopharyngeal swab

for reverse transcription polymerase chain reaction (PCR) for severe acute respiratory syndrome coronavirus 2 was obtained. The swab test for influenza resulted negative. The patient’s poor prognostic laboratory parameter results were as follows: D-dimer=750 mcg/L, lymphocytes=800 K/mL, ferritin=793 ng/mL, lactate dehydrogenase=397 U/L, and C-reactive protein=29 mg/L. Nintedanib treatment was continued, and hydroxychloroquine, azithromycin, and enoxaparin were added to the patient’s regimen, according to the COVID-19 guidelines of the Turkish Ministry of Health [5] while waiting for the COVID-19 PCR results. The dosage of hydroxychloroquine was 2’400 mg on day 1, which was then decreased to 2’200 mg. The patient was given a 500-mg dose of azithromycin on day 1, which was then decreased to a dosage of 250 mg per day for 4 consecutive days. Enoxaparin 0.4 cc subcutaneously per day was administered as thrombosis prophylaxis. PCR test was reported as positive on the next day. His fever continued during the first 3 days when he was observed, without oxygen treatment. On day 4, his oxygen saturation levels dropped to 89%, and he was supported with 1-2 L/min oxygen via nasal cannula. On day 5, he was still receiving oxygen, and we decided to prolong hydroxychloroquine treatment to 7 days. Azithromycin treatment was stopped after 5 days according to the guidelines. On day 7, the clinical condition and laboratory parameters of the patient improved dramatically. We detected no drug interactions or side effects. His oxygen saturation level was over 93% on breathing room air, and he was discharged. He was followed up weekly through telephone calls, reported to be in good condition, and his PCR tests were negative 2 times in the fourth week after discharge. His informed consent was taken for publication.

## DISCUSSION

The course of IPF can be unpredictable with episodes of rapid respiratory deterioration, known as acute exacerbations [2], which may be triggered by viral infections. Currently, there is no information about the management of patients with IPF who experience COVID-19. We do not know if it is suitable to withdraw or continue antifibrotic treatment during such an episode. As there is no specific antiviral drug to treat COVID-19, clinical applications differ between countries. The British Thoracic Society states that an interruption of antifibrotic treatment for 4-8 weeks may not cause any harm in case a patient with IPF on antifibrotic drugs is diagnosed with COVID-19 [3]. There are no data to support this interruption. Our patient was on antifibrotic treatment for more than 1 year when he was diagnosed with COVID-19. We continued nintedanib treatment and applied the medications approved by our official guidelines with close monitoring. We did not observe any cardiac complications or drug interactions. The patient only needed a short course of oxygen support with nasal cannula. Rajasurya et al. [6] reported a fatal case of COVID-19 in a patient with IPF who also was on nintedanib treatment and was lost because of multiorgan failure despite rigorous treatment. Therefore, we were unable to comment on the role of nintedanib as a tyrosine kinase inhibitor on the course of COVID-19. We were unable to find any literature on patients using pirfenidone and experiencing COVID-19. Although we are in the

## MAIN POINTS

- IPF is a rare disease with a rather poor prognosis.
- COVID-19 may cause pneumonia in IPF patients and may mimic other infections as well as exacerbation of disease.
- This case illustrates that continuing antifibrotic therapy along with COVID-19 treatment may be a safe option.

acute phase of the pandemic, we will be confronted with its short-term and probably even long-term sequela. Individuals who are recovering from COVID-19 infection will be evaluated for long-term or permanent lung damage, including fibrosis, as is seen with SARS and MERS infections [4]. This will be another challenge for the patients with IPF and their physicians who will probably set a new follow-up program, new imaging findings throughout the course, and new cutoff levels for continuing or withdrawing antifibrotic treatment. Our patient was successfully treated with the drugs approved by our official guidelines along with antifibrotic therapy. The functional and radiologic follow-up of such patients will help us to build a new way in optimal management of patients with IPF in COVID-19 era.

**Informed Consent:** Written informed consent was obtained from the patient.

**Peer-review:** Externally peer-reviewed.

**Author Contributions:** Concept - F.I.U, B.Ç.; Design - F.I.U, B.Ç.; Supervision - F.I.U, B.Ç., S.İ., F.K.; Resources - F.I.U.; Materials - F.I.U.; Data Collection and/or Processing - F.I.U.; Analysis and/or Interpretation - F.I.U, B.Ç., S.İ., F.K.; Literature Search - F.I.U, B.Ç., S.İ., F.K.; Writing Manuscript - F.I.U.; Critical Review - F.I.U, B.Ç., S.İ., F.K.

**Conflict of Interest:** The authors have no conflicts of interest to declare.

**Financial Disclosure:** The authors declared that this study has received no financial support.

## REFERENCES

1. Raghu G, Remy-Jardin M, Myers JL, et al. An official ATS/ERS/JRS/ALAT Clinical Practice Guideline: Diagnosis of idiopathic pulmonary fibrosis. *Am J Respir Crit Care Med* Vol 2018;198:44-68. [\[CrossRef\]](#)
2. Wuyts WA, Wijsenbeek M, Bondue B, et al. Idiopathic pulmonary fibrosis: Best Practice in monitoring and managing a relentless fibrotic disease. *Respiration* 2020;99:73-82 [\[CrossRef\]](#)
3. Available from: <https://www.brit-thoracic.org.uk/media/455101/bts-management-advice-for-ild-patientsv10-23-march-2020.pdf>.
4. Hosseiny M, Kooraki S, Gholamrezanezhad A, et al. Radiology Perspective of Coronavirus Disease 2019 (COVID-19): Lessons from severe acute respiratory syndrome and Middle East Respiratory Syndrome. *AJR* 2020;214:1078-82. [\[CrossRef\]](#)
5. Covid-19(SARS-CoV-2 infection) directory -Science Committee Work [https://covid19bilgi.saglik.gov.tr/depo/rehberler/COVID-19\\_Rehberi.pdf](https://covid19bilgi.saglik.gov.tr/depo/rehberler/COVID-19_Rehberi.pdf) (Turkish)
6. Rajasurya V, Gunasekeran G, Damarla V, Kolluru A. A Fatal case of Coronavirus Disease 2019 (COVID-19) in a patient with idiopathic pulmonary fibrosis. *Cureus* 2020;12:e8432. [\[CrossRef\]](#)