





## Case Report

# Pneumothorax: A Rare Entity During Pregnancy

Önder Kavurmacı<sup>1</sup> , Tevfik İlker Akçam<sup>2</sup> , Seda Akgün Kavurmacı<sup>3</sup> , Kutsal Turhan<sup>2</sup> , Ufuk Çağırıcı<sup>2</sup> 

<sup>1</sup>Clinic of Thoracic Surgery, University of Health Sciences İzmir Bozyaka Training and Research Hospital, İzmir, Turkey

<sup>2</sup>Department of Thoracic Surgery, Ege University, School of Medicine, İzmir, Turkey

<sup>3</sup>Clinic of Obstetrics and Gynecology, Katip Çelebi University Atatürk Training and Research Hospital, İzmir, Turkey

**Cite this article as:** Kavurmacı Ö, Akçam Tİ, Akgün Kavurmacı S, et al. Pneumothorax: A Rare Entity During Pregnancy. Turk Thorac J 2019; 20(3): 206-8.

## Abstract

Pneumothorax is a rarely seen condition during pregnancy, when changes in the respiratory physiology can sensitize the mother and fetus to the signs of hypoxia. Symptoms of pneumothorax, such as dyspnea, tachypnea, and chest pain, can also be attributed to pregnancy and complications with pregnancy and this can lead to misdiagnoses. The limitations in the use of diagnostic tests, such as chest X-ray and computed tomography, make treatment more difficult. Here, we report of two cases admitted to our hospital due to spontaneous pneumothorax during pregnancy. The diagnosis of pneumothorax was made based on a thorax ultrasonography in both patients, whereas a chest X-ray was used in the follow-up period, without the need for a thorax tomography. While one patient was treated via a tube thoracostomy, the other was treated via video-assisted thoracoscopic surgery.

**KEYWORDS:** Pneumothorax, pregnancy, thoracic surgery

**Received:** 23.09.2018

**Accepted:** 17.12.2018

**Available Online Date:** 09.04.2019

## INTRODUCTION

The occurrence of spontaneous pneumothorax (SP) with pregnancy is rare, although it can lead to serious problems for both the mother and the fetus [1,2]. Most of the studies in the literature are presented as case reports and number <100 [1,2]. Alterations in the respiratory physiology and the limitations on the use of tests, such as chest X-rays and computed tomography (CT), during pregnancy make the treatment of these patients more difficult.

We report of two cases admitted to our hospital with SP during pregnancy to highlight the importance of the use of alternative radiological imaging modalities and treatment options for pneumothorax.

## CASE PRESENTATIONS

### Case 1

A 30-year-old woman on gestational week 5 (gravida 2/parity 1) was admitted with a complaint of chest pain. The patient had a smoking history of 5 packs/year in addition to a tube thoracostomy due to SP 6 months previously in her medical history. On physical examination, decreased respiratory sounds in the right hemithorax were observed. Her blood pressure was 110/68 mmHg, heart rate was 78 beats/min, and respiratory rate was 18 breaths/min. Blood oxygen saturation was obtained as 98%. Biochemical test results were within normal limits, and  $\beta$ -human chorionic gonadotropin was 33.562 mIU/mL, which was consistent with the gestational week. The patient was further evaluated using a transvaginal ultrasonography (USG) by the obstetrician and gynecologist, the findings of which were consistent with the gestational week. A thoracic USG showed findings that were compatible with a right-sided pneumothorax. The patient was followed up with nasal oxygen therapy. On day 3 of follow-up, the patient complained of increased chest pain, and on physical examination, decreased respiratory sounds from the right hemithorax were found. The patient was subsequently evaluated using a chest X-ray with lead shield protection (Figure 1). On detection of the progression of pneumothorax, video-assisted thoracoscopic surgery (VATS) was recommended to the patient. However, the patient refused the surgery, and a right tube thoracoscopy was performed. The patient experienced no additional problems during follow-up, and the thoracic drainage tube was removed on day 5. The patient was discharged from the hospital without event. During follow-up, pregnancy was terminated on her own request, and no recurrent pneumothorax developed during 1 year of follow-up.

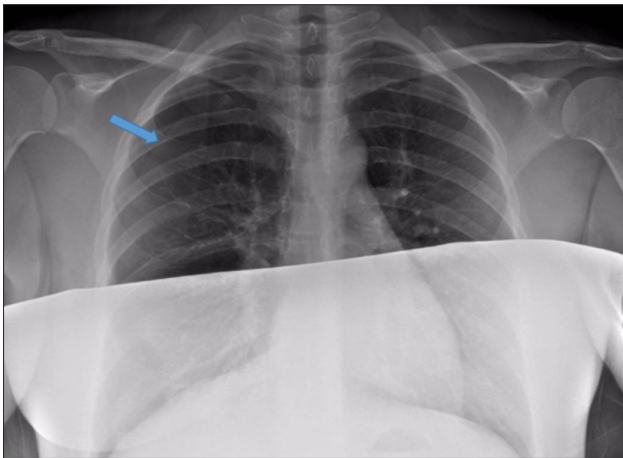
**Address for Correspondence:** Önder Kavurmacı, Clinic of Thoracic Surgery, University of Health Sciences İzmir Bozyaka Training and Research Hospital, İzmir, Turkey

E-mail: doctor\_onder@hotmail.com

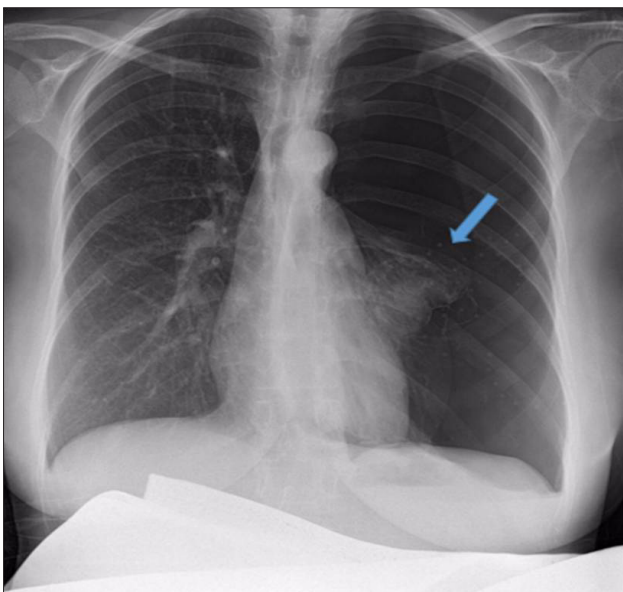
©Copyright 2019 by Turkish Thoracic Society - Available online at www.turkthoracj.org

### Case 2

A 28-year-old woman on gestational week 22 (gravida 2) was admitted with a complaint of sudden-onset chest pain on the left side. She had no smoking history or lung disease. On physical examination, respiratory sounds were found to be decreased in the left hemithorax. Her blood pressure was 126/88 mmHg, pulse rate was 68 beats/min, and respiratory rate was 16 breaths/min. Blood oxygen saturation was obtained as 97%. On biochemical examinations, no pathology other than mild anemia (hemoglobin: 11.9 mg/dL) was found. The findings of a thoracic USG were compatible with a left-sided pneumothorax. The patient was evaluated using a transvaginal USG by the obstetrician and gynecologist, and the findings were found to be consistent with the gestational week. A left tube thoracostomy was performed without any additional diagnostic test. The patient experienced no additional problems during follow-up. The thoracic drainage tube was removed on day 5, and the patient was discharged. After 1 week, the patient was re-admitted with a complaint of ipsilateral chest pain. Since the findings of thoracic USG were found to be compatible with pneumothorax, the patient was diagnosed with recurrent pneumothorax. A surgical treat-



**Figure 1.** Right subtotal pneumothorax line with protective material



**Figure 2.** Left total pneumothorax with protective material

ment (videothoroscopic wedge resection) decision was chosen for the patient, and she was evaluated using a chest X-ray before the operation (Figure 2). A total pneumothorax was detected, and the patient underwent a problem-free videothoroscopic wedge resection. The patient was re-evaluated by the obstetrician and gynecologist pre- and postoperatively, and no additional problems were observed in the patient or fetus. The thoracic drainage tube was removed on postoperative day 4, and the patient was discharged without event. The patient gave birth to a male infant weighing 3025 g on gestational week 39 under spinal anesthesia. No recurrent pneumothorax was detected during the follow-up period of around a 1-year period.

Informed consent was obtained from the cases who participated included in the study.

### DISCUSSION

Spontaneous pneumothorax during pregnancy is an extremely rare clinical condition that warrants cautious management. The limitations on the use of tests, such as chest X-rays and CT, as the standard diagnostic tools and the changes in the respiratory physiology during pregnancy increase the importance of the condition.

The increase in the demand for oxygen during pregnancy is approximately 20%, increasing to 50% during delivery [2,4], and this demand is supplied by several complex physiological changes. Minute ventilation increases by a rate of 30%–50% due to the direct stimulation of the respiratory center by progesterone, and this increase is related primarily with the increase in tidal volume [2-4]. Although the diaphragm is pushed upwards by the enlarged uterus, the subcostal angle reaches 103° from 68° by increasing at a rate of 50%, and an increase in the tidal volume is achieved [3]. An impairment in this complex physiological process causes easier hypoxia than in non-pregnant women, and this can have undesired effects on the fetus [3,4]. Therefore, the rapid treatment of pneumothorax detected during pregnancy is of vital importance.

The definite differential diagnosis in this special patient group is the initial challenge that must be overcome. Dyspnea and chest pain are the most common symptoms in patients with pneumothorax during pregnancy [1,2], and these symptoms can be misdiagnosed as pregnancy-related dyspnea-as a physiological event that affects 75% of pregnant women [1,3,4]. In pregnancy, cardiac diseases may also cause diagnostic confusion due to their presentation with dyspnea and chest pain. Congenital anomalies, such as undiagnosed heart valve failure and atrial septal defects, may become symptomatic during pregnancy, and severe acute cardiac pathologies, such as myocardial infarction and aortic dissection, may also present with chest pain and shortness of breath [5,6]. Pulmonary embolisms, which may be encountered frequently during pregnancy and can cause severe maternal and fetal complications, are another disease that should be considered in a differential diagnosis [5,6]. In addition to these diseases, pneumonia, asthma attack, and tuberculosis reactivation may also appear with dyspnea and chest pain [7]. The limited use of radiological tests complicates the condition, although a

detailed medical history can be helpful at this stage. The history of a recent pneumothorax in Case 1 was helpful in our diagnosis; however, Case 2 had no previous lung disease, which complicated the diagnosis.

As rapid neuronal development and migration occur during organogenesis (between gestational weeks 3 and 8) and the early fetal period (up until gestational week 15), the fetus is very sensitive to the teratogenic effects of radiation [8]. Despite this classical knowledge, a review of the literature revealed that chest X-rays were used for diagnosis in the majority of cases [1,2,9]. In our cases, we opted for a thoracic USG to circumvent the teratogenic effects of radiation as the initial diagnostic test. USG is widely used in pregnancy as it has no maternal or fetal side effects and is also common in invasive procedures, such as amniocentesis and fetal blood transfusions, both in the detection of pregnancy and during pregnancy [10]. The idea of using this harmless examination in pregnant patients with thoracic pathologies appears plausible. The literature contains studies reporting the use of USG in patients with pneumothorax with high sensitivity and specificity [11]. In line with this information, we opted to use ultrasound as much as possible in our patients. However, as secondary etiologies, such as the level of pneumothorax, and parenchymal pathologies cannot be clearly determined via a thoracic USG, we also evaluated our patients using a chest X-ray in case an operation was considered. At this stage, magnetic resonance imaging (MRI), and the lack of associated fetal and maternal side effects, can be discussed. MRI is known to cause no side effects in the mother or fetus and has been used in the treatment of lung disease during pregnancy [12]. In the present study, we opted for a chest X-ray due to the low cost, the immediate application, and for practical reasons.

There are different approaches to the treatment of pneumothorax during pregnancy. The British Thoracic Society states that recurrent pneumothorax is seen at an increased rate in pregnant women and should be treated with conservative approaches with Grade C recommendations [13]. It has also been emphasized that VATS should be considered following pregnancy [13], although there have been several studies recommending surgical treatment for patients in whom prolonged air leak or recent recurrence is present during pregnancy [2,9]. Case 1 had a history of pneumothorax, and conservative treatment, including oxygen and observation, was performed. During follow-up, the patient refused VATS, despite the progression of the pneumothorax, and so a tube thoracostomy was performed. Case 2 was treated initially with a tube thoracostomy, although the condition recurred approximately 1 week later, at which point VATS was performed. The patient was subsequently discharged without event. Prior to undergoing a cesarean section, the patient was examined, and no finding related to pneumothorax was noted. Following the cesarean surgery, the patient was re-evaluated using a chest X-ray, and no radiopathological findings were observed.

In conclusion, pneumothorax during pregnancy is a clinical condition that should be diagnosed and treated with the collaboration of specialists of chest disease, chest surgery, obstetrics, and gynecology. In addition to this multidisciplinary approach, a detailed medical history and a USG performed

by an experienced radiologist can be helpful in the differential diagnosis. Although following up with conservative methods and tube thoracostomy can provide satisfactory results, VATS should not be avoided in the event of prolonged air leak and recent recurrences. A cesarean section under epidural anesthesia would appear to be a safe choice for delivery in this patient population.

**Informed consent:** Written informed consent was obtained from all of the patients who participated in the case.

**Peer-review:** Externally peer-reviewed.

**Author Contributions:** Concept – Ö.K., T.İ.A.; Design – U.Ç., K.T.; Supervision – Ö.K., S.A.K.; Resources – S.A.K.; Materials – Ö.K.; Data Collection and/or Processing – S.A.K.; Analysis and/or Interpretation – T.İ.A.; Literature Search – T.İ.A.; Writing Manuscript – U.Ç., K.T.; Critical Review – U.Ç., Ö.K.

**Conflict of Interest:** No conflict of interest was declared by the authors

**Financial Disclosure:** The authors declared that this study has received no financial support.

## REFERENCES

- Garg R, Sanjay, Das V, et al. Spontaneous pneumothorax: an unusual complication of pregnancy—a case report and review of literature. *Ann Thorac Med* 2008;3:104-5. [\[CrossRef\]](#)
- Akçay O, Uysal A, Samancılar O, et al. An unusual emergency condition in pregnancy: pneumothorax. Case series and review of the literature. *Arch Gynecol Obstet* 2013;287:391-4. [\[CrossRef\]](#)
- Bobrowski RA. Pulmonary physiology in pregnancy. *Clin Obstet Gynecol* 2010;53:285-300. [\[CrossRef\]](#)
- Crapo RO. Normal cardiopulmonary physiology during pregnancy. *Clin Obstet Gynecol* 1996;39:3-16. [\[CrossRef\]](#)
- Grewal J, Silversides CK, Colman JM. Pregnancy in women with heart disease: risk assessment and management of heart failure. *Heart Fail Clin* 2014;10:117-29. [\[CrossRef\]](#)
- Sahni G. Chest pain syndromes in pregnancy. *Cardiol Clin* 2012;30:343-67. [\[CrossRef\]](#)
- Mehta N, Chen K, Hardy E, et al. Respiratory disease in pregnancy. *Best Pract Res Clin Obstet Gynaecol* 2015;29:598-611. [\[CrossRef\]](#)
- Woitek R, Prayer D, Hojreh A, et al. Radiological staging in pregnant patients with cancer. *ESMO Open* 2016;1:e000017. [\[CrossRef\]](#)
- Nwaejike N, Aldam, P, Pulimood T, et al. A case of recurrent spontaneous pneumothorax during pregnancy treated with video assisted thoracoscopic surgery. *BMJ Case Rep* 2012;13: pii:bcr0520114282. [\[CrossRef\]](#)
- Benson CB, Doubilet PM. The history of imaging in obstetrics. *Radiology* 2014;273(2 Suppl):S92-110. [\[CrossRef\]](#)
- Volpicelli G. Sonographic diagnosis of pneumothorax. *Intensive Care Med* 2011;37:224-32. [\[CrossRef\]](#)
- Schloß M, Heckrodt J, Schneider C, et al. Magnetic resonance imaging of the lung as an alternative for a pregnant woman with pulmonary tuberculosis. *J Radiol Case Rep* 2015;9:7-13. [\[CrossRef\]](#)
- MacDuff A, Arnold A, Harvey J; BTS Pleural Disease Guideline Group. Management of spontaneous pneumothorax: British Thoracic Society pleural disease guideline 2010. *Thorax* 2010;65(Suppl 2):ii18-31. [\[CrossRef\]](#)