

CASE REPORT

A Rare Cause of Hemoptysis in Childhood: Tracheal Capillary Hemangioma

Mehmet Akif Özgül¹, Elif Tanrıverdi¹, Şule Gül¹, Zehra Yaşar Asuk², Murat Acat³, Kenan Abbaslı¹, Neslihan Akanıl Fener⁴, Erdoğan Çetinkaya¹

¹Clinic of Chest Diseases, Yedikule Chest Diseases and Chest Surgery Training and Research Hospital, İstanbul, Turkey

²Department of Chest Diseases, Abant İzzet Baysal University School of Medicine, Bolu, Turkey

³Department of Chest Diseases, Karabük University School of Medicine, Karabük, Turkey

⁴Clinic of Pathology, Yedikule Chest Diseases and Chest Surgery Training and Research Hospital, İstanbul, Turkey

Cite this article as: Özgül MA, Tanrıverdi E, Gül Ş, et al. A Rare Cause of Hemoptysis in Childhood: Tracheal Capillary Hemangioma. Turk Thorac J 2017;18:131-3.

Abstract

Hemangiomas are benign tumors most frequently seen in childhood and are mostly associated with cutaneous and mucosal surfaces. Tracheal capillary hemangiomas are extremely rare. The most common presenting symptom is hemoptysis, ranging from minor to major and chronic cough. We present the case of a 12-year-old boy with recurrent hemoptysis due to tracheal capillary hemangioma, who was treated with interventional bronchoscopy.

KEYWORDS: Hemoptysis, capillary hemangioma, trachea

Received: 11.05.2016

Accepted: 15.05.2017

Available Online Date: 21.07.2017

INTRODUCTION

Primary tumors of the trachea are extremely rare, with an estimated incidence of approximately 2.7 new cases per million per year, and usually malignant in adults [1]. Lobular capillary hemangioma (LCH) is a benign tumor, more commonly seen in children, with a distinctive lobular arrangement of capillaries in edematous and fibroblastic stroma [2]. The usual sites of tumor are the lips, nose, oral cavity, and tongue. It typically presents with nonspecific clinical symptoms, such as cough and hemoptysis. Stridor is observed with subglottic localization of the tumor. Radiologic studies and bronchoscopy are usually sufficient for diagnosis. Interventional bronchoscopic techniques can treat these lesions and avoid aggressive surgical approaches. Mills et al.[3] reviewed 639 cases of vascular lesions of the oral cavity and upper respiratory tract. They found only 73 cases with LCH and no case with localization in or below the larynx. There is very limited literature on tracheal LCH [1]. We present here the diagnosis and management of a rare case of tracheal LCH that was successfully treated with interventional bronchoscopy.

CASE PRESENTATION

A 12-year-old boy was admitted to our clinic due to recurrent hemoptysis. His symptoms started 2 years ago with approximately 100 mL of hemorrhage in a day after coughing. He also mentioned that a small amount of hemoptysis recurred whenever he had a respiratory tract infection. There was nothing in his history to indicate causes of hemoptysis, such as tuberculosis, recurrent lower respiratory tract infections, intravenous or oral drug use, or antibiotic therapy. He had no pets. Physical examination showed no abnormalities. His hematologic parameters were as follows: activated partial thromboplastin time: 24.7 sc; prothrombin time:15.2 s-58.2%, INR: 1.22; within normal limits). Other chemical laboratory test results were normal, as were chest radiography findings (Figure 1). Sputum acid-fast bacilli and Löwenstein-Jensen cultures were negative. Thorax computed tomography showed a polypoid lesion on the left lateral wall of the proximal trachea (Figure 2). Rigid bronchoscopy revealed a reddish polypoid lesion with a smooth surface on the left lateral wall localized in the proximal one-third of the trachea. The lesion was attached to the tracheal wall with a short pedicle (Figure 3a). The lesion was excised with electrocautery snare and was taken using biopsy forceps. The tracheal wall was coagulated with argon plasma coagulation (APC) (Figure 3b). Histologic examination revealed a subepithelial lobular arrangement of proliferating capillary vessels, dilatation, and congestion; thus, the diagnosis of LCH was confirmed (Figure 4a, b). Upon follow-up, the patient had no hemoptysis episodes. On bronchoscopic examination at the 6-month follow-up, no relapse or other abnormality was observed except for a small scar on the previous biopsy site (Figure 3c). Written informed consent was obtained from the parents of the patient for this case presentation.

Address for Correspondence: Şule Gül, Clinic of Chest Diseases, Yedikule Chest Diseases and Chest Surgery Training and Research Hospital, İstanbul, Turkey

E-mail: suleeyhan@gmail.com

©Copyright 2017 by Turkish Thoracic Society - Available online at www.turkthoracj.org



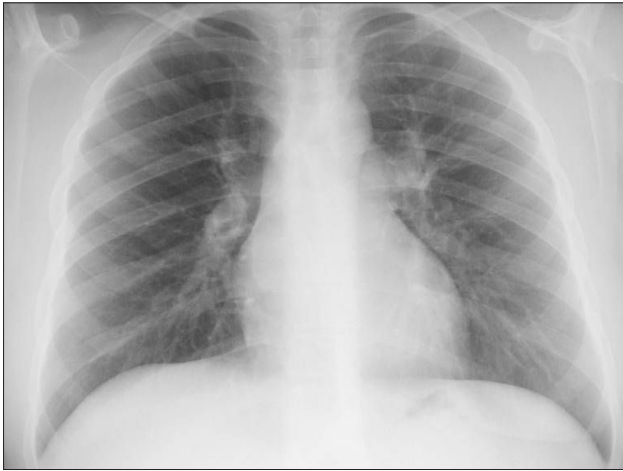

Figure 1. Normal chest X-ray of patient

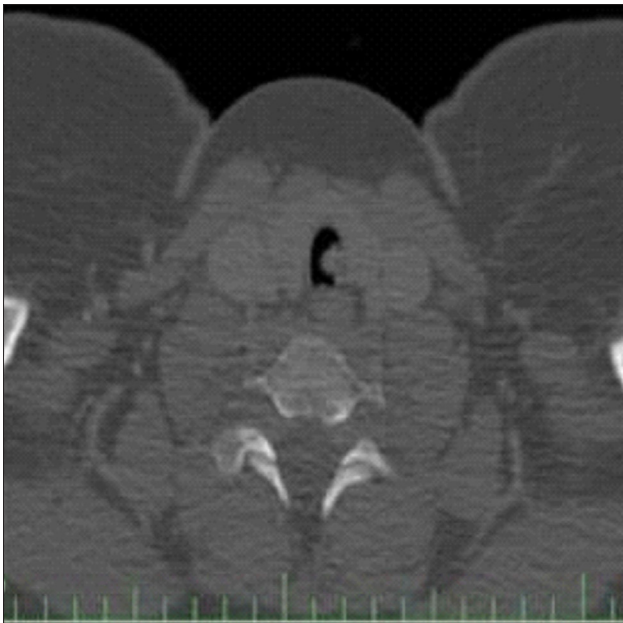

Figure 2. Tracheal lesion was observed on thorax computed tomography

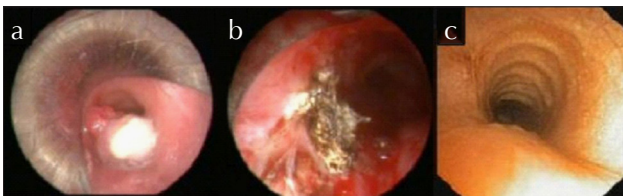


Figure 3. a-c. Tracheal polypoid lesion (a), appearance of lesion after bronchoscopic treatment (b), appearance of trachea after 6 months of treatment (c)

DISCUSSION

The most frequent causes of hemoptysis are infectious diseases, malignant tumors, cardiovascular diseases, and other inflammatory disorders in adults. LCH has seldom been reported in the English literature [4]. Chest X-ray findings are generally normal. LCH is frequently diagnosed while researching etiology of cough and hemoptysis with thorax CT and bronchoscopy [5]. Bronchoscopic appearance is also nonspecific and mimics adenoid cystic carcinoma, tracheal adenoma, and carcinoid tumors [6]. Definitive diagnosis is made with bronchoscopic biopsy. Our patient was an adoles-

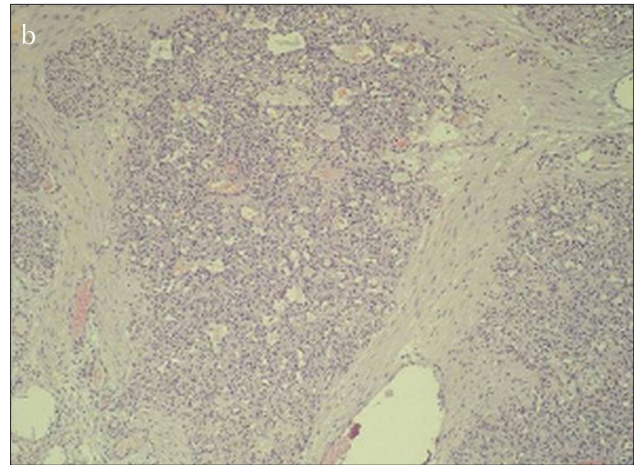
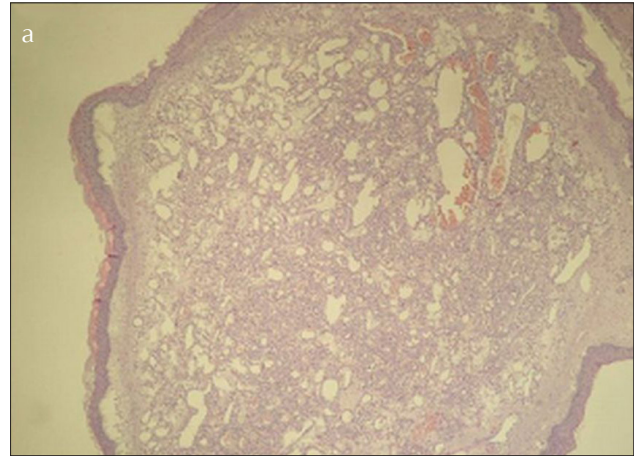


Figure 4. a,b. Respiratory epithelial surface showing squamous metaplasia, proliferating and dilated capillary structures in stroma (H&E $\times 40$)

cent whose chest X-ray findings were normal, but he had tracheal lesion on thorax CT, that was taken to determine the etiology of hemoptysis.

Pathogenesis of capillary hemangiomas (CH) is unknown. Bartonella infections are implicated in CHs of the skin. Minor trauma, such as endotracheal intubation and tracheostomy, has been reported to play a role in the etiology, but it is not clear because of the small number of cases in the literature [7]. There is no trauma history in our case. CHs can be successfully treated with various methods such as cryotherapy, yttrium aluminium garnet (YAG) laser, topical or intralesional steroids or neoplastic agents (vincristine), oral propranolol, and surgical excision. However, these treatments are mostly used for cutaneous, oral, and subglottic hemangiomas [8,9]. Although case reports are limited in number, successful results with different bronchoscopic techniques were obtained in the treatment of tracheal CHs.

Rameau et al.[10] successfully treated children presenting with symptomatic large tracheal hemangioma using K-potassium titanyl phosphate laser ablation, and they suggested this method for tracheal lesions. Excision of tumor with bronchoscopic forceps has also been reported as a successful method [2,4,5,7]. In our case, after the tracheal lesion was excised with electrocautery snare, excised tumor was taken with forceps and tracheal wall of the lesion was cauter-

ized using APC. After six months, control bronchoscopy revealed minimal scarring with no sign of recurrence.

In conclusion, we would like to remind that tracheal CH is an extremely rare cause of hemoptysis and radiological findings may be normal. So, it should be kept in mind for differential diagnosis. These exceptionally rare tumors also can successfully treated with interventional bronchoscopic methods.

Informed Consent: Written informed consent was obtained from the parents of the patients who participated in this case.

Peer-review: Externally peer-reviewed.

Author Contributions: Concept - M.A.O., E.T., E.Ç.; Design - M.A.O., E.T., E.Ç.; Supervision - E.Ç.; Materials - E.T., Ş.G.; Data Collection and/or Processing - E.T., Ş.G., Z.Y.A., N.A.F.; Analysis and/or Interpretation - E.T., Z.Y.A.; Literature Review - E.T., M.A., K.A.; Writer - M.A.O., E.T., Ş.G.; Critical Review - M.A.O., E.Ç.; Other - M.A., K.A., N.A.F.

Conflict of Interest: No conflict of interest was declared by the authors.

Financial Disclosure: The authors declared that this study has received no financial support.

REFERENCES

1. Prakash S, Bihari S, Wiersema U. A rare case of rapidly enlarging tracheal lobular capillary hemangioma presenting as difficult to ventilate acute asthma during pregnancy. *BMC Pulm Med* 2014;14:41. [\[CrossRef\]](#)
2. Irani S, Brack T, Pfaltz M, et al. Tracheal lobular capillary hemangioma: a rare cause of recurrent hemoptysis. *Chest* 2003;123:2148-9. [\[CrossRef\]](#)
3. Mills SE, Cooper PH, Fechner RE. Lobular capillary hemangioma: the underlying lesion of pyogenic granuloma. A study of 73 cases from the oral and nasal mucous membranes. *Am J Surg Pathol* 1980;4:470-9. [\[CrossRef\]](#)
4. Porfyridis I, Zisis C, Glinos K, et al. Recurrent cough and hemoptysis associated with tracheal capillary hemangioma in an adolescent boy: a case report. *J Thorac Cardiovasc Surg* 2007;134:1366-7. [\[CrossRef\]](#)
5. Strausz J, Soltesz I. Bronchial capillary hemangioma in adults. *Pathol Oncol Res* 1999;5:233-4. [\[CrossRef\]](#)
6. Madhumita K, Sreekumar K, Malini H, et al. Tracheal haemangioma: case report. *J Laryngol Otol* 2004;118:655-8. [\[CrossRef\]](#)
7. Ozyilmaz E, Yunsel D, Hanta İ, et al. Endobronchial capillary hemangioma: a very rare cause of massive hemoptysis. *Tuberk Toraks* 2011;60:78-80. [\[CrossRef\]](#)
8. Bedard MS, Boulanger J. Treatment of lobular capillary hemangioma with the Nd:YAG laser: retrospective case series of 25 patients. *J Cutan Med Surg* 2009;13:181-2. [\[CrossRef\]](#)
9. Truong MT, Perkins JA, Messner AH, et al. Propranolol for the treatment of airway hemangiomas: a case series and treatment algorithm. *Int J Pediatr Otorhinolaryngol* 2010;74:1043-8. [\[CrossRef\]](#)
10. Rameau A, Zur KB. KTP laser ablation of extensive tracheal hemangiomas. *Int J Pediatr Otorhinolaryngol* 2011;75:1200-3. [\[CrossRef\]](#)